

# IJMA

## INTERNATIONAL JOURNAL OF MEDICAL ARTS



*Volume 3, Issue 3 [Summer (July-September) 2021]*



<http://ijma.journals.ekb.eg/>

Print ISSN: 2636-4174

Online ISSN: 2682-3780

## About IJMA [last updated July, 1<sup>st</sup>, 2021]

- ✓ International Journal of Medical Arts is the Official Journal of the Damietta Faculty of Medicine, Al-Azhar University, Egypt
- ✓ It is an International, Open Access, Double-blind, Peer-reviewed Journal
- ✓ Published four times a year
- ✓ The First Issue was published in July 2019
- ✓ Published under the following license: Creative Commons Attribution-ShareAlike 4.0 International Public License (CC BY-SA 4.0). It had updated from the Creative Commons license [CC BY] in volume 2, Issue 4, October 2020 About IJMA
- ✓ The Egyptian Knowledge Bank hosts the web site of IJMA
- ✓ The Egyptian Knowledge Bank supports IJMA
- ✓ IJMA follows the regulations of the International Committee of Medical Journal Editors
- ✓ IJMA is indexed in the "Directory of Open Access Journals" [15 January 2021].
- ✓ IJMA is indexed in JGate [29-6-2021]
- ✓ IJMA is a member of the International Society of Managing and Technical Editors
- ✓ Listed in "Index Copernicus", "Publons", "Academic resource index [ResearchBib]", "Electronics journal library", "Eurasian Scientific Journal Index", and "Citefactor"
- ✓ IJMA introduced to the search engine [BASE] through DOAJ

Click image to reach the page



Egyptian Knowledge Bank

DOAJ



INDEX COPERNICUS INTERNATIONAL



ESJI Eurasian Scientific Journal Index  
www.ESJIndex.org





Available online at Journal Website  
<https://ijma.journals.ekb.eg/>  
Main subject [Radiology] \*



## Original Article

# Role of Magnetic Resonance Imaging and Ultrasonography in Evaluation of Chronic Non osseous Shoulder Pain.

Abdelrahman Nabil Abdelati Hassan <sup>[1]</sup>, Mostafa M Shakweer <sup>[1]</sup>, Ahmed Yahia Ahmed Ashour <sup>[1]</sup>, Ahmed Abdelfattah Mahmoud Abo Rashid <sup>[2]</sup>.

<sup>1</sup> Department of Radiology, Damietta Faculty of Medicine, Al-Azhar University, Egypt.

<sup>2</sup> Department of Radiology, Faculty of Medicine, Al-Azhar University, Egypt.

**Corresponding author:** Abdelrahman Nabil Abdelati Hassan.

Email: [ganna\\_050@hotmail.com](mailto:ganna_050@hotmail.com).

Submission date: April 26, 2021; Revision date: June 30, 2021; Acceptance date: June 30, 2021.



DOAJ

DOI: [10.21608/IJMA.2021.74120.1307](https://doi.org/10.21608/IJMA.2021.74120.1307)

## ABSTRACT

**Background:** Chronic shoulder pain is a common clinical presentation. It is of osseous or non-osseous origin. In non-osseous shoulder pain, proper diagnosis is critical. Magnetic resonance imaging [MRI] is the standard diagnostic modality. However, it is expensive and not available in many medical centers. Thus, the availability of cheap alternative is crucial.

**Aim of the work:** The current research aimed to assess the diagnostic performance of ultrasonography versus conventional MRI in different causes of chronic non-osseous shoulder pain.

**Patients and Methods:** Fourty patients with chronic shoulder pain due to different causes were participated in the current work. They were selected from Al-Azhar University Hospital [Damietta]. All were assessed on clinical basis [history, physical examination and laboratory investigations]. Then, all were submitted to radiological investigations [Plain X-ray, shoulder ultrasound, and Magnetic resonance imaging]. The diagnostic value of ultrasound was estimated versus that of magnetic resonance imaging.

**Results:** by ultrasound, tendinosis was reported in 55.0%, partial thickness tear in 27.5%, articular surface in 20.0%, full thickness tear in 12.5%, bursal surface [7.5%], neoplastic [2.5%] and infraspinatus tendon full thickness tear [2.5%]. Ultrasound able to diagnose supraspinatus tendinopathy [91.7%], full thickness complete tear [83.3%], supraspinatus impingement [85.3%], subacromial subdeltoid bursitis [92.0%] and long head biceps tenosynovitis [84.2%]. Otherwise, ultrasound specificity is over its sensitivity power for partial thinness tear on articular [80.0%] or bursal surfaces [85.3%], full thickness complete tear [94.1%], shoulder joint effusion [92.3%], LHB tenosynovitis [85.7%] and labral tears [100.0%].

**Conclusion:** Shoulder ultrasound could be considered as a reasonable alternative to magnetic resonance imaging in the diagnosis of different causes of chronic shoulder pain. However, its value widely different from condition to another. Thus, it could be used as a rapid screening tool, and the use of MRI could be ascribed for specific conditions [cases with lower ultrasound sensitivity].

**Keywords:** Chronic Shoulder Pain; Ultrasound; Tendinosis; Bursa; Non-Osseous.

This is an open-access article registered under the Creative Commons, ShareAlike 4.0 International license [CC BY-SA 4.0] [<https://creativecommons.org/licenses/by-sa/4.0/legalcode>].

**Citation:** Hassan ANA, Shakweer MM, Ashour AYA, Abo Rashid AAM. Role of Magnetic Resonance Imaging and Ultrasonography in Evaluation of Chronic Non osseous Shoulder Pain. IJMA 2021; 3 [3] July-September: 1642-1650 [DOI: [10.21608/IJMA.2021.74120.1307](https://doi.org/10.21608/IJMA.2021.74120.1307)].

\* Main subject and any subcategories have been classified according to the research topic.

## INTRODUCTION

Among musculoskeletal disorders, shoulder pain is a common complaint [represents about 20.0%] and usually associated with disability <sup>[1]</sup>. Shoulder pain is described as a chronic condition when it lasts for more than six months, irrespective of seeking previous treatment or not <sup>[2]</sup>.

Shoulder pain is of osseous and non-osseous origins. Rotator cuff, acromioclavicular joint [ACJ] and glenohumeral joint [GHJ] conditions are among the commonest non-osseous causes of shoulder pain <sup>[3]</sup>. Causes of shoulder pain usually affected by patient age. Younger patients are usually present with shoulder instability or mild rotator cuff disease [impingement, tendinopathy], whereas older patients are at usually presented by advanced chronic rotator cuff conditions [partial or complete tear], adhesive capsulitis, or glenohumeral osteoarthritis. The age of 40 years old is the cut off point for determination for younger and older subjects <sup>[4]</sup>.

Imaging studies for shoulder disorders generally include plain radiographs, ultrasonography, computed tomography scans and magnetic resonance imaging. Plain radiographs may help diagnose shoulder instability, and shoulder arthritis <sup>[5]</sup>.

Once satisfactory radiographs have been gained to exclude bone disorders, high-resolution ultrasound [HRUS] should be the first modality in the evaluation of shoulder disorders <sup>[6]</sup>.

Ultrasonography is a cheap, fast, and provides dynamic abilities to examine the patient in multiple scanning planes without specific positions or movements of the arm. In addition, ultrasound had the ability to focus the examination on the accurate region with a maximum discomfort <sup>[7]</sup>. Therefore, Ultrasound should be the primary diagnostic and screening modality of shoulder pain. It is cost-effective and fast <sup>[8]</sup>.

Magnetic resonance imaging [MRI] is currently the reference standard imaging modality for shoulder disorders. MRI had the potential to assess areas not accessed by ultrasound such as the bone marrow, labral cartilage, and deep parts of various ligaments, capsule, and areas masked by bone <sup>[9]</sup>.

MRI is an ideal modality for different shoulder pathologies and significantly influences the clinician's diagnostic decisions for shoulder lesions. MRI permits free access to the different imaging planes. It also suppresses the fat signal and increase imaging speed, sensitivity and specificity of the shoulder <sup>[10]</sup>.

In cases of non-osseous shoulder pain, the definite diagnosis is of utmost importance. Early diagnosis usually leads to a better outcome. However, there is no consensus on the ideal diagnostic modality [other than MRI, which is expensive and not available in all medical centers] in such cases. Here, we intended to investigate the role of two imaging modalities; the ultrasonography and magnetic resonance imaging. We propose that, if ultrasound could perform like or near MRI, it may represent a reasonable, rapid, readily available alternative, which could help in good prognosis of cases with non-osseous shoulder pain.

## AIM OF THE WORK

The aim of this study is to evaluate the role of ultrasonography versus conventional magnetic resonance imaging in the diagnosis of different causes of chronic non-osseous shoulder pain.

## PATIENTS AND METHODS

The current work was designed as a prospective, cross sectional study, where 40 patients with chronic shoulder pain of non-osseous causes were recruited. They were referred from the orthopedic or rheumatology outpatient clinics, Al-Azhar University Hospital [Damietta]. Patients were selected from March 2020 to February 2021.

All patients, of both sexes were eligible for participation in the current work if they had a clinical suspicious chronic non-osseous shoulder pain. On the other side, patients with osseous causes, previous surgery at shoulder joint, shoulder pain duration less than 6 months and patients who were known to have contraindication for MRI [e.g., implanted magnetic device, pacemakers, etc.] were excluded from the study.

After the approval of the institutional review board [IRB] [IRP number: #00012367-20-02-010], and obtaining patient consent, all participants were inquired about their medical history in full details. The results of the clinical examination by referring physician and results of necessary investigations were reviewed. Then, all patients were examined by plain-X ray [anteroposterior, lateral and axial views to exclude osseous origin of should pain]. After that, ultrasound examination of the shoulder had been performed by ultrasound machine using superficial 7-10 MHz transducer [GE Voluson 6], according to the protocol described by Jacobson <sup>[11]</sup>.

Ultrasound [US] assessment of rotator cuff had been completed by an experienced radiologist [general radiologist of more than 15 years of experience] using high frequency small part probe ultrasound machine. Finally, MRI

examination had been performed after the removal of all metallic objects with the patient. The machine used was [Philips, Achieva 1.5 Tesla-XR-Netherlands 2010 magnet was used -surface coil-]. The procedure completed as described by Farber *et al.* [12].

The MRI was evaluated by the same radiologist after concealment of patient name and any data refer to his/her identity.

*Statistical analysis of data:* IBM SPSS statistics [V. 25.0, IBM Corp., USA, 2017-2018] was used for data analysis. All collected data expressed as relative frequency and percent distribution [categorical variables]. The performance of ultrasound in the light of MRI as a standard diagnostic modality had been calculated by equations, where sensitivity measure measures the proportion of positives that are correctly identified and equals to the true positive [TP] divided by true positive plus false negative [FN]. In addition, sensitivity refers to the true negative rate and equals true negative [TN] divided by true negative plus false positive [FP]. Positive predictive value [PPV] = TR/TR +FP; Negative predictive value [NPV]= TN/TN+FN. The overall test accuracy = TP+TN/TP+TN+FP+FN.

**RESULTS**

Regarding age, the mean age of all studied patients was

58.6 ± 8.4 years with minimum age of 20 years and maximum age of 70 years. There were 12 males [30%] and 28 females [70%]. Of all patients, 16 [40%] had pain 7–9 months, 12 patients [30%] had pain 10 – 12 months and 12 patients [30%] had pain > 12 months. DM was reported in 26 patients [65%]. The dominant side was right side among 30 patients [70%] and 10 patients [25%] were left-side dominant. The history of heavy use of the affected shoulder, 22 patients [55%] had positive history [Table 1].

Regarding ultrasound findings, tendinosis was reported in 55.0%, partial thickness tear in 27.5%, articular surface in 20.0%, full thickness tear in 12.5%, bursal surface [7.5%], neoplastic [desmoid tumor at the back of the shoulder] [2.5%] and infraspinatus tendon full thickness tear [2.5%] [Table 2].

As regards diagnostic performance of shoulder ultrasound in comparison to MRI, it was found that, ultrasound able to diagnose supraspinatus tendinopathy [91.7%], full thickness complete tear [83.3%], supraspinatus impingement [85.3%], subacromial subdeltoid bursitis [92.0%] and long head biceps tenosynovitis [84.2%]. Otherwise, ultrasound specificity is over its sensitivity power for partial thinness tear on articular [80.0%] or bursal surfaces [85.3%], full thickness complete tear [94.1%], shoulder joint effusion [92.3%], LHB tenosynovitis [85.7%] and labral tears [100.0%] [Table 2].

**Table [1]:** Demographic data & risk factors of all studied patients.

Variable	Statistics	
Age [mean±SD; minimum – maximum]	58.6 ± 8.4; 20- 70	
Sex	Male	12[30.0%]
	Female	28[70.0%]
The duration of pain	7-9 months	16[40.0%]
	10-12 months	12[30.0%]
	> 12 months	12[30.0%]
Diabetes mellitus	26 [65.0%]	
Dominant side	Right	30[75.0%]
	Left	10[25.0%]
History of heavy use of the affected shoulder	22[55.0%]	

**Table [2]:** Distribution of studied sample according to patient’s US Findings [more than finding may be detected in same case such as joint effusion and LHB tenosynovitis].

US Findings	Number	percentage
Tendinosis	22	55%
Full thickness tear	5	12.5%
Partial thickness tear	11	27.5%
Articular surface	8	20%
Bursal surface	3	7.5%
neoplastic [Desmoid tumor at back of shoulder]	1	2.5%
Infraspinatus tendon full thickness tear	1	2.5%
Total	40	100%

**Table [3]:** Diagnostic performance of U/S in comparison to MRI results as regard supraspinatus tendinopathy.

Ultrasound	MRI				Sensitivity	Specificity	PPV	NPV	Accuracy
	TP	TN	FP	FN					
Supraspinatus tendinopathy	22	14	2	2	91.7%	87.5%	91.7%	87.5%	90.0%
Partial thickness tear on articular surface	8	20	5	7	53.3%	80.0%	61.5%	74.1%	70.0%
Partial thickness tear on bursal surface	3	2	5	3	50.0%	85.3%	37.5%	90.6%	80.0%
Full thickness complete tear	5	32	2	1	83.3%	94.1%	71.4%	96.9%	92.5%
Supraspinatus impingement	7	22	6	5	85.3%	78.6%	53.9%	81.5%	72.5%
Sub-acromial subdeltoid bursitis	23	12	3	2	92.0%	80.0%	88.5%	85.7%	85.7%
Shoulder joint effusion	3	24	2	11	21.4%	92.3%	60.0%	68.6%	67.5%
Long head biceps tenosynovitis	16	18	3	3	84.2%	85.7%	84.2%	85.7%	85.0%
Labral tears	0	34	0	6	0.0%	100.0%	0.0%	85.0%	85.0%

Here, we presented investigation of some patients; the first is 47-year-old female [Figure 1] patient complains of right shoulder pain for 7 months.

Ultrasound examination revealed mild OA changes of the Acromio-clavicular joint [white arrow] [A], the right supraspinatus tendon shows inhomogeneous texture denoting mild degenerative changes, yet no definite tears seen [black arrow] [B].

The dynamic examination showed narrowing of the subacromial tunnel with limited movement on raising arm up. MRI examination revealed OA changes of the Acromio-clavicular joint [black arrow] and the supraspinatus tendon shows focal increase intra substance signal on T2WI with no evidence of tear [white arrow] [C], and minimal fluid in the subacromial-sub deltoid bursa [red arrow] [D].

The diagnosis was acromioclavicular joint arthropathy with supraspinatus impingement, supraspinatus tendinopathy, and subacromial-subdeltoid bursitis.

The second patient [Figure 2] was 62-year-old male diabetic patient, complains of right chronic shoulder pain and inability to fully abduct his right arm for two years. Ultrasound examination revealed OA changes of the acromio-clavicular joint [black arrow] [A]; and a full thickness tear of the right supraspinatus tendon is noted with a 5 mm gap filled with fluid [B].

MRI revealed full thickness tear of the supraspinatus tendon with retraction of its fibers medially forming large fluid

filled gap 5 mm, associated superior migration of the humeral head [C], sub-coracoid bursitis [black arrow] [D], and mild joint effusion [black arrow] [E].

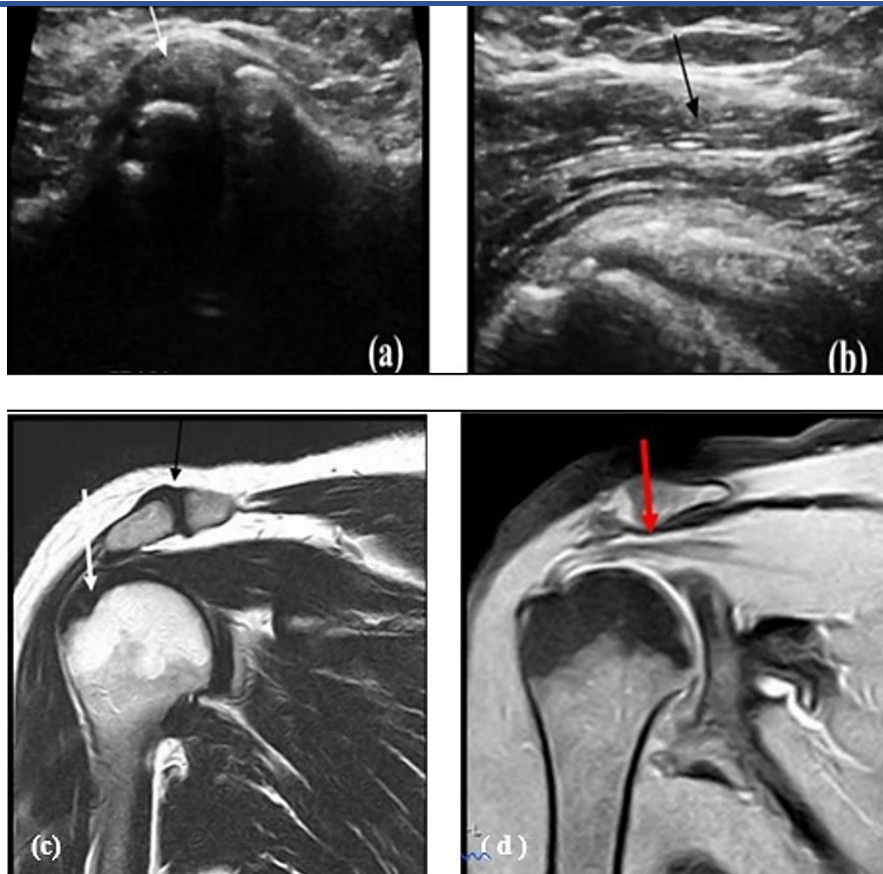
The diagnosis was a full thickness tear of the supraspinatus with tendon retraction, no muscle atrophy, ACJ osteoarthritis, mild shoulder joint effusion, and sub-coracoid bursitis.

The third patient [Figure 3] was a female patient, a 68-year-old, complaint of chronic right shoulder pain for 7 months. She had left breast cancer, and on chemotherapy.

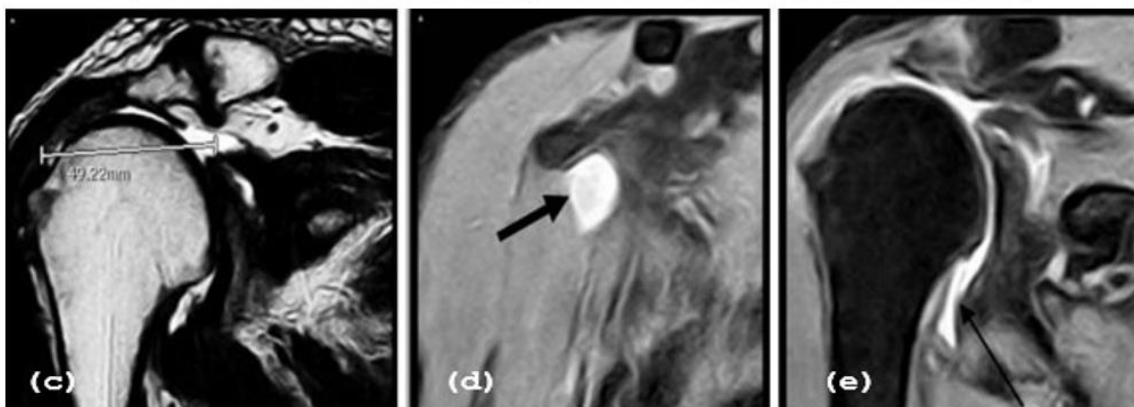
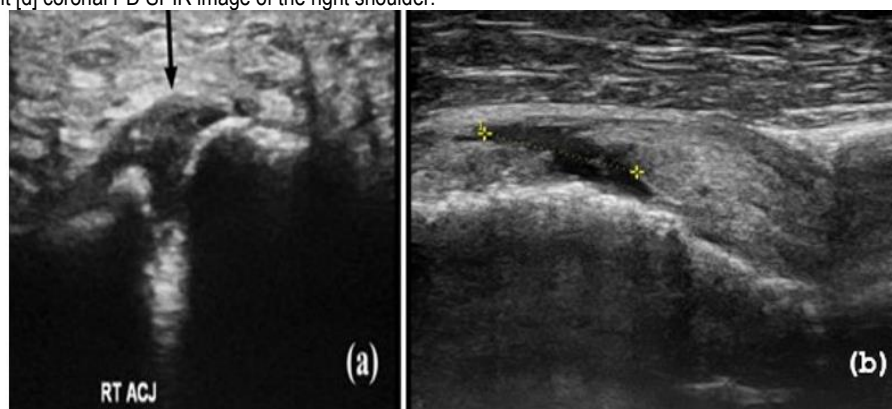
Ultrasound examination revealed marked effusion at long head of biceps tendon sheath, marked edema involving the surrounding muscles [A], acromioclavicular joint capsule hypertrophic changes [B] and marked synovial thickening with increase in vascularity associated with marked glenohumeral joint effusion [C and D].

MRI images revealed bone marrow shows altered SI involving, neck, proximal shaft of humerus, also glenohumeral effusion and thickened synovium [e], post contrast areas of abnormal enhancement of bone marrow of humeral head, synovium [F], and mild effusion at the axillary recess with synovial thickening [G].

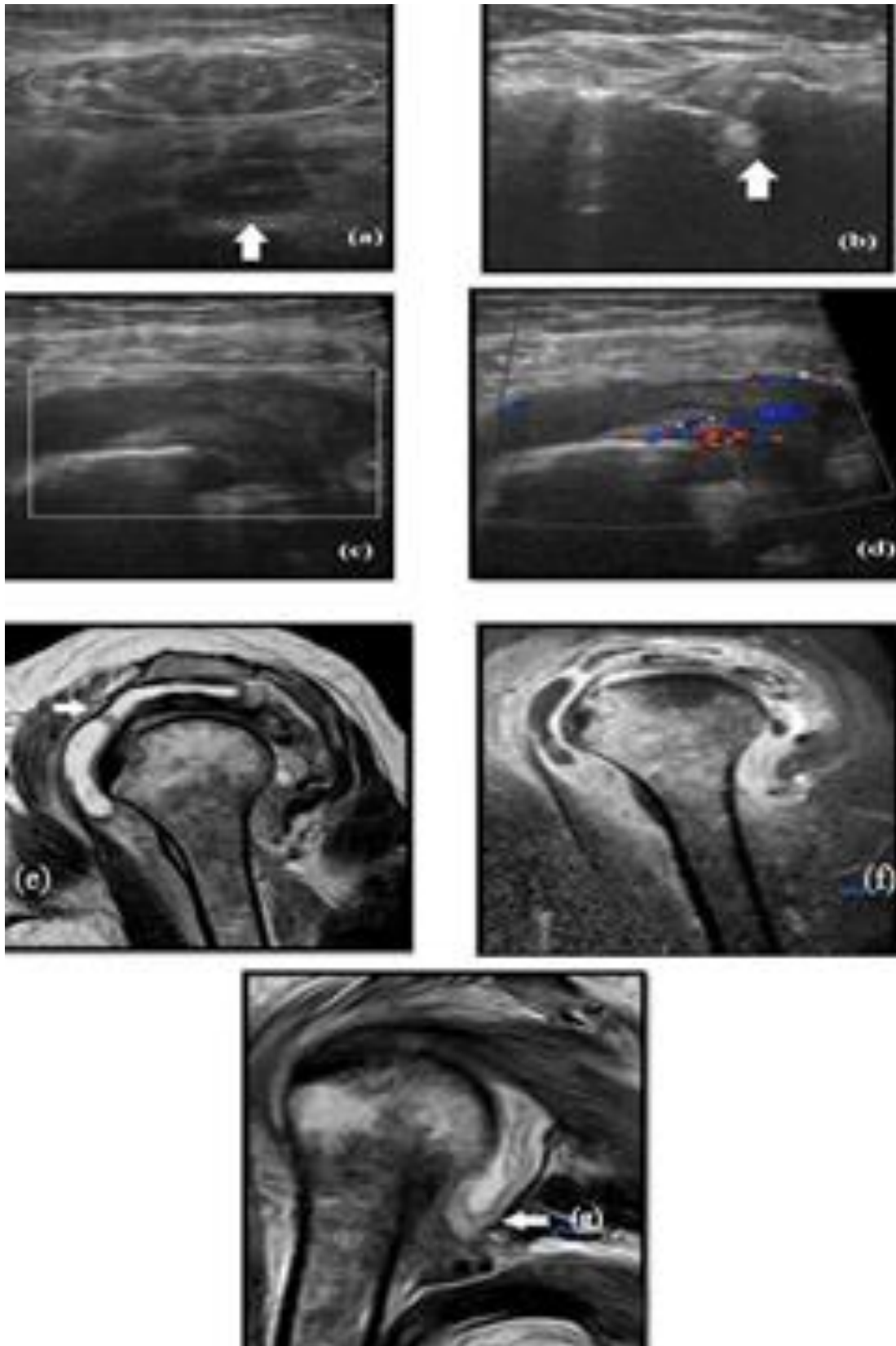
The diagnosis was bone marrow post chemotherapy changes, glenohumeral synovitis with joint effusion, and ACJ osteoarthritis.



**Figure [1]:** [a] Ultrasound image of the right Acromio-clavicular joint [b] Supraspinatus muscle tendon [c] Coronal T2 weighted image of the right shoulder joint [d] coronal PD SPIR image of the right shoulder.



**Figure [2]:** [a] US image of the right ACJ [b] US image of the right supraspinatus tendon [c] Coronal T2 weighted image of the supraspinatus muscle and gap defect. [d] Coronal PD SPIR image Sub-coracoid bursa [black arrow]. [e] coronal PD SPIR of the joint [black arrow].



**Figure [3]:** [a] the long head of biceps tendon sheath [white arrow], the surrounding muscles [white circle]. [b] Acromioclavicular joint capsule [c] glenohumeral joint [d] Doppler assessment. [e] Sagittal T2WI, humeral head, neck, proximal shaft; white arrow points glenohumeral joint, synovium. [f] T1WI post contrast show humeral head, neck, proximal shaft. [g] Coronal T1WI post contrast, arrow points axillary recess.



## DISCUSSION

Tendinopathy of the supraspinatus muscle was the commonest diagnoses [n = 24, 60 %]. Then, partial thickness tear of the same muscle [n = 21; 52 %] followed by a full thickness tear of the supraspinatus [n = 6; 15%]. Among other diagnoses subacromial-subdeltoid bursitis was most common and effusion of the bicep's tendon sheath [BTS] as will be thoroughly discussed.

The commonest cause of referral to radiological investigation in the current study was rotator cuff pathologies which was found to agree with Vijayan *et al.* [13] and Singh *et al.* [14]

Supraspinatus tendon was the commonest affected tendon in the current work. Concordant to our study, studies done by Vijayan *et al.* [13], Singh *et al.* [14], and Netam *et al.* [15] have also demonstrated supra-spinatus to be the commonest tendon involved and the tendon of teres minor was the least one.

US detected 22 patients to have tendinopathy of supraspinatus and 24 patients on MRI. Thus, ultrasound was 91.7% sensitive, 87.5 % specific had 91.7% PPV, 87.5 % NPV and was 90 % accurate in diagnosing supraspinatus tendinopathy which are in line with Singh *et al.* [14] who stated that US had 78.72% sensitivity, 100% specificity, 100% PPV, 80.9% NPV, and 82.35% of overall accuracy in the diagnosis of tendinosis. These findings are also concordant with Khanduri *et al.* [16] who stated that for supraspinatus tendinosis, US had a sensitivity, specificity, PPV, NPV, and accuracy of 62.5%, 91.3%, 62.5%, 91.3%, and 85.9%, respectively.

In the current trial, MRI was used as a reference standard, and supraspinatus partial thickness tears of were found to be more common than full thickness tears. This agrees with the Vijayan *et al.* [13], Netam *et al.* [15] and Thakker *et al.* [17]

In our study among 21 patients with supraspinatus tendon partial thickness tears [n = 21] as diagnosed by MRI, ultrasound correctly picked up 11 cases [eight had articular surface tendon tear whereas three had bursal surface tendon tear]. This shows that the articular surface tear was more common than the bursal surface tear.

Similar results were reported by Vijayan *et al.* [13] and Netam *et al.* [15].

For partial thickness tears articular surface our results show sensitivity and specificity 53.3% and 80% respectively

had 61.5 % PPV, 74.1% NPV and was 70% accurate in diagnosing partial tendon tear articular surface.

Vijayan *et al.* [13] show Sensitivity, Specificity, Positive Predictive Value [PPV] and Negative Predictive Value [NPV] of US in evaluating rotator cuff tendons partial tears is 64.5%, 95.8%, 66.6% and 96.4% respectively. On US there were 5 false positive cases that were normal on MRI probably due to anisotropy related artefacts.

A total of five patients had complete tendon tear on US where another one had complete tendon tear on MRI. Thus, US was 83.3% sensitive, 94.1% specific, had 71.4% PPV, 96.9% NPV, and was 92.5% accurate in the diagnosis of complete tear which in line with studies performed by Vijayan *et al.* [13] who show for complete tears 70.4% Sensitivity, 100% Specificity, 100% PPV and 97.2% NPV.

It is also closely agreed with Singh *et al.* [14], who reported results of US having a sensitivity of 88.9%, specificity of 100%, PPV of 100% and NPV of 98.07% in recognition of full thickness tears.

The results of our study were in correspondence to the meta-analysis done by Netam *et al.* [15] who observed that US showed a sensitivity of 91% and specificity of 93 % for full thickness tears.

On US there were two false positive cases that were normal on MRI probably due to anisotropy related artefacts. The overall accuracy of US in the identification of any tear was above 80%. Ultrasound is accurate when used for the identification of full thickness tears; although sensitivity is lower 53.6 % for the diagnosis of partial thickness tear, specificity remained high in both conditions, being above 80%. These were concordant with Khanduri *et al.* [16].

Relation of US and MRI with clinical diagnosis revealed that clinical diagnosis failed to identify the tears, especially supraspinatus impingement which was later identified as full/partial thickness tear and tendinosis by MRI and ultrasound. Thus, these imaging modalities helped to recognize the underlying pathologies in a clearer way. However, MRI diagnosed shoulder pathologies in relatively a greater number as compared to ultrasound.

Ultimately, MRI was more sensitive and specific for most underlying pathologies than ultrasound. The specificity and sensitivity for supraspinatus impingement by ultrasound was 58.3% and 78.6 % respectively, NPV 81.5% and PPV of 53.9% with accuracy 72.5% which in line with Biswas *et al.* [3] who showed that, ultrasound had sensitivity of 66.67%, specificity of 94.12%, positive predictive value of 50% and negative predictive value of 88.89%.

Six cases of our study show false positive due to inaccurate measuring of distance by posterior shadow of acromioclavicular joint which is seen clearly by MRI, however in some cases, ultrasound has clear advantages over MRI about dynamic imaging. These include situations where a specific maneuver or position is needed to provoke symptoms. Many such abnormalities are not seen with static MRI. With ultrasound, virtually any dynamic maneuver can be assessed in real time as tolerated by the patient.

A total of 23 patients had fluid in the subacromial-subdeltoid [SASD] bursa on ultrasound whereas 25 were confirmed to have fluid in SASD bursa on MRI. This showed that, ultrasound had 92% sensitivity, 80% specificity and 88.5% PPV, 85.7% NPV, and 87.5 % accuracy in identification of SADB fluid in comparison to MRI; which is in line with Singh *et al.* [14] who reported that US showed a sensitivity of 90% and specificity of 88 % in the diagnosis of SASD. Hence, MRI proved to be a better modality in detection of bursal effusion.

Joint effusion was seen in 14 cases in MRI, with 3 cases only diagnosed by US thus, 11 cases false negative cases could not be assessed by ultrasound because the patients could not maintain the position for examination. Our study revealed that, the sensitivity and specificity for the detection of joint effusion were lower being 21.4% and 92.3% respectively.

Our results are in agreement with Bruyn *et al.* [18] study that was performed on 10 patients examined by 11 observers to compare ultrasound and MRI while the sensitivity and specificity for the detection of joint effusion were lower being 35% and 92% respectively.

Our results were not concordant with those of Maravi *et al.* [19] study in assessing sonography vs. MRI in detection of glenohumeral effusion, the study documented effusion at the glenohumeral area in 26 cases on MRI, of them 19 were identified on ultra-sound. The sensitivity, specificity, PPV, and NPV of US were 73.1%, 100%, 100%, and 26.9% respectively. The study shows glenohumeral joint effusion can be identified by a reliable ultrasound but only in a few places.

The most reliable site to identify effusion was the posterior recess of the glenohumeral joint space with external rotation of the upper arm. The recognition rate of effusion by ultrasound in this study shows sensitivity of 73.1% compared to only 21.4 % in our study which could be attributed to most of the patients were unable to attain the position for examination.

Tendon sheath effusion along the bicep's tendon was the second most common imaging finding in association with the rotator cuff tears on US. This was pertaining to the synovial sheath of the biceps as an extension of the glenohumeral synovial membrane. Out of 19 patients who were detected to have fluid in BTS on MRI, 16 patients were correctly detected to have fluid in BTS on US. In our results showing the specificity and sensitivity for BTS effusion by US as sensitivity and specificity 84.2 % and 85.7% respectively, negative predictive value of 85.7 % and positive predictive value of 84.2 % with 85 % accuracy. Our results are agreed with Singh *et al.* [14] reported that US had 90% sensitivity, 83 % specificity and 55 % PPV, 100% NPV. Yet, Maravi *et al.* [19] who reported Sensitivity, specificity, PPV, and NPV of US for identification of biceps tendon sheath effusion were 37.5%, 100%, 100%, and 92% respectively with accuracy 92%.

Six cases of suspected labral derangements were diagnosed by MRI but were not detected by US as they were involving the anterior labrum and to evaluate the glenoid labrum, which is not located superficially and is surrounded by the rotator cuff musculature, and to diagnose anterior labral tears, experience in shoulder US is required. MRI is superior in detection of labral tears with accuracy as high as 85 % which is well correlated with the study conducted by Netam *et al.* [15] which stated an accuracy of 98 %.

**The value of the current study:** the results of the current work reflected the ability of ultrasound to diagnose with high sensitivity different non-osseous conditions of chronic shoulder pain [e.g., supraspinatus tendinopathy, full thickness complete tear, supra-spinatus impingement, subacromial subdeltoid and long head biceps tenosynovitis]. In conditions with lower sensitivity, it provides high specificity, where it could be used to exclude such conditions [e.g., partial thickness tear on articular [80.0%] or bursal surfaces [85.3%], full thickness complete tear [94.1%], shoulder joint effusion [92.3%], LHB tenosynovitis [85.7%] and labral tears [100.0%]. The current trial is unique in its nature as it addressed many non-osseous causes of chronic shoulder pain, where previous studies addressed a single condition. However, the small number of included subjects represented a limiting step of the current study. Thus, future wide scale studies are recommended.

#### **Financial and Non-financial Relationships and Activities of Interest**

None

## REFERENCES

1. Gimarc DC, Lee KS. Shoulder magnetic resonance imaging Versus Ultrasound: How to Choose. *Magn Reson Imaging Clin N Am.* 2020 May;28[2]:317-330. [DOI: 10.1016/j.mric.2019.12.012].
2. Aytona MC, Dudley K. Rapid resolution of chronic shoulder pain classified as derangement using the McKenzie method: a case series. *J Man Manip Ther.* 2013 Nov;21[4]:207-12. [DOI: 10.1179/2042618613Y.0000000034].
3. Biswas S, Kanodia N, Tak R, Agrawal S, Roy KS. Correlation of clinical examination, ultrasound, magnetic resonance imaging and arthroscopy as diagnostic tools in shoulder pathology/ *IJORO.* 2020 Mar;6[2]: 247-251. [DOI: 10.18203/issn.2455-4510.IntJResOrthop20200473].
4. Bargon GM. The association of body representation and nociceptive sensitivity measures with shoulder pain and disability prior to and twelve months after shoulder surgery. *Curtin Theses 2019*; pp 3-10. Available from <http://hdl.handle.net/20.500.11937/77265>
5. Soler F, Fallone JC. Shoulder imaging evaluation. In: *Arthroscopy and Sport Injuries; Application in high level athletes.* Volpi P [ed], Springer International Publishing Switzerland 2016, chapter 15. p: 109-119.
6. Piccolo CL, Galluzzo M, Ianniello S, Trinci M, Russo A, Rossi E, et al. Pediatric musculoskeletal injuries: role of ultrasound and magnetic resonance imaging. *Musculoskelet Surg.* 2017; 101 [Suppl 1]:85-102. [DOI: 10.1007/s12306-017-0452-5].
7. Passmore E, Lai A, Sangeux M, Schache AG, Pandy MG. Application of ultrasound imaging to subject-specific modelling of the human musculo-skeletal system. *Meccanica* 2017; 52: 665–676. [DOI: 10.1007/s11012-016-0478-z].
8. Lau BC, Motamedi D, Luke A. Use of Pocket-Sized Ultrasound Device in the Diagnosis of Shoulder Pathology. *Clin J Sport Med.* 2020 Jan; 30 [1]:20-24. [DOI: 10.1097/JSM.0000000000000577].
9. Barreto RPG, Braman JP, Ludewig PM, Ribeiro LP, Camargo PR. Bilateral magnetic resonance imaging findings in individuals with unilateral shoulder pain. *J Shoulder Elbow Surg.* 2019 Sep; 28 [9]:1699-1706. [DOI: 10.1016/j.jse.2019.04.001].
10. Sheehan SE, Coburn JA, Singh H, Vanness DJ, Sittig DF, Moberg DP, et al. Reducing Unnecessary Shoulder MRI Examinations Within a Capitated Health Care System: A Potential Role for Shoulder Ultrasound. *J Am Coll Radiol.* 2016 Jul;13[7]:780-7. [DOI: 10.1016/j.jacr.2016.03.015].
11. Jacobson JA. Shoulder US: anatomy, technique, and scanning pitfalls. *Radiology.* 2011 Jul;260[1]:6-16. [DOI: 10.1148/radiol.11101082].
12. Farber A, Fayad L, Johnson T, Cascio B, Shindle M, Neubauer P, Khanna AJ. Magnetic resonance imaging of the shoulder. Current techniques and spectrum of disease. *J Bone Joint Surg Am.* 2006; 88 Suppl 4:64-79. [DOI: 10.2106/JBJS.F.00583].
13. Vijayan D, Shanmugam V, Aiyappan S, Chidambaram P. Diagnostic Accuracy of High-Resolution Ultrasonography in Comparison with MRI for Evaluation of Rotator Cuff Pathologies. *Int J Contemporary Med Surg Radiol.* 2020; 5 [2]: B8-B12. [DOI: 10.21276/ijcmsr.2020.5.2.3].
14. Singh AP, Rao A., Devaru S, Rama A. Role of Ultrasound in Evaluation of Shoulder Injuries: A Comparative Study of Ultrasound and MRI *Int J Anatomy, Radiol Surg.* 2017; 6[1]: RO12-RO1812. [DOI: 10.7860/IJARS/2017/24542:2224].
15. Netam SB, Kumar S, Jain V, Singh A, Singh RK and Jain V. Role of Ultrasonography in Evaluation of Rotator Cuff in Patients of Chronic Shoulder Pain in Comparison to Magnetic Resonance Imaging. *Int J Sci Study* 2017; 5[3]: 291-296. [DOI: 10.17354/ijss/2017/316].
16. Khanduri S, Raja A, Meha T, Agrawal S, Bhagat S, Jaiswal G. Comparative study of the diagnostic ability of ultrasonography and magnetic resonance imaging in the evaluation of chronic shoulder pain. *Int J Sci study* 2016; 4[1]: 266-272. [DOI: 10.17354/ijss/2016/230].
17. Thakker VD, Bhuyan D, Arora M, Bora MI. Rotator Cuff Injuries: Is Ultrasound Enough? A Correlation with MRI. *Int J Anatomy Radiol Surg.* 2017; 6[3]: RO01-RO07. [DOI: 10.7860/IJARS/2017/28116:2279].
18. Bruyn GA, Pineda C, Hernandez-Diaz C, Ventura-Rios L, Moya C, Garrido J, et al. Validity of ultrasonography and measures of adult shoulder function and reliability of ultrasonography in detecting shoulder synovitis in patients with rheumatoid arthritis using magnetic resonance imaging as a gold standard. *Arthritis Care Res [Hoboken].* 2010 Aug; 62[8]: 1079-86. [DOI: 10.1002/acr.20175].
19. Maravi P, Khadiya A, Kaushal L, Goyal S, Patil P. Role of high-frequency USG in rotator cuff injury and its comparison with MRI. *Int J Med Res Rev.*2020;8[6]:440-450. [DOI: 10.17511/jmrr.2020.i06.12].

# International Journal

The background of the cover is a light blue gradient. It features a faint, semi-transparent graphic of a stethoscope on the left side, a globe in the center, and a white ECG (heart rate) line running across the bottom. The overall theme is medical and global.

<https://ijma.journals.ekb.eg/>

Print ISSN: 2636-4174

Online ISSN: 2682-3780

# of Medical Arts