

## CHANGES IN MASTICATORY MUSCLES FOLLOWING ORTHOGNATHIC SURGERY AFTER MANDIBULAR PROGNATHISM CORRECTION

Ahmed S. Naguib\*, Abdelbadia A. Abdelmabood\* and Rania S. Naguib\*\*

### **ABSTRACT**

**Aim:** To evaluate the postoperative electromyographic changes of temporalis and masseter muscles activity, in patients with orthognathic surgery BSSO,for correction of mandibular prognathism.

**Material and Methods:** Eight adult patients, their ages ranged from 22-45 years, five females and three males, suffering from mandibular prognathism. underwent BSSO, for performing mandibular setback. EMG examinations(peak to peak amplitude, for detection of the strength of contraction of both temporalis and masseter muscles) were done presurgical and twelve months postoperatively.

**Results:** Significant increase in peak-to-peak amplitude values of both temporalis muscles was founded. Moreover, an increase in peak-to-peak amplitude values of both masseter muscles was found,.No significant differences were found in the mean frequency score (as one of the variables of the EMG measurement) of the masseter muscles before bilateral sagittal split osteotomy and that undertaken 12 months after bilateral sagittal split osteotomy ( $P = 0.06$ ). An increase in the mean peak to peak amplitude score for the right and left temporalis muscle was found, with significant differences between the measurement found 12 months after bilateral sagittal split osteotomy, and that measured before bilateral sagittal split osteotomy fig (6) ( $P = 0.002,0.0001$  respectively)

**Conclusion:** No change in the strength of contraction of both temporalis and masseter muscle had detected after performing BSSO for correction of mandibular prognathism ,as detected by EMG examination.

**KEYWORDS:** *EMG: Electromyography, BSSO: Bilateral Sagittal Split Osteotomy, RI: Magnetic Resonance Image and CT: computerized tomogram.*

\* Assistant Professor Oral & Maxillofacial Surgery, Faculty of Oral and Dental Medicine, Zagazig University

\*\* Assistant professor Neurology, Faculty of Medicine, Zagazig University

## INTRODUCTION

The purpose of orthognathic surgery is to improve the occlusal relations, improve the facial aesthetics and to maintain the long-term stability of the newly created jaw relationship <sup>(1)</sup>. There is variable response of the mandibular muscles to the surgical jaw repositioning procedures that may be related to the muscular insertion and movement task of each masticatory muscle <sup>(2)</sup>.

However, the results of orthognathic surgery are not always stable. Sometimes relapse may occur early within weeks after jaws repositioning. Skeletal relapse may occur if the muscles fail to adapt structurally and functionally to the altered skeletal form. <sup>(3)</sup>.

The success of surgical treatment can be evaluated subjectively by detection of patients' satisfaction, as the patient can detect the improvement in both aesthetic and function of his stomatognathic apparatus. However, the subjective judgements cannot be easily quantified <sup>(4)</sup>.

The outcome of orthognathic surgical procedures can be judged objectively by comparing preoperative and postoperative photographs and radiographs (to evaluate the facial morphology), plaster models (to evaluate the occlusal relationship) and EMG to evaluate the muscles which represents the functional component of the stomatognathic apparatus <sup>(5)</sup>.

The functional anatomy of the lower jaw muscles can be classified into two groups: elevator muscles (masseter, temporalis and medial pterygoid muscles) and depressor muscles (lateral pterygoid muscle and suprahyoid muscles) <sup>(6)</sup>

There are several methods can be used to evaluate the changes in dimensions of the orofacial muscles, including computerized tomography and magnetic resonance image. However, CT and MRI are not considered as the best modality to evaluate the changes that occurs in the muscles following orthognathic surgical procedures due to their high-cost and exposure of the patient to high dose of radiation <sup>(7)</sup>.

However, EMG is a part of patient assessment in dentistry and provides useful information both before and after surgical, physical, and dentomaxillofacial orthopedic treatments, as it enables the evaluation of the muscular changes that occurs following the orthognathic surgical procedures <sup>(8)</sup>.

## AIM OF THIS STUDY

To evaluate the postoperative changes of the right and left temporalis and masseter muscles activity, after performing BSSO with performing mandibular setback for correction of mandibular prognathism in patients with class III malocclusion, by using electromyographic records.

## MATERIAL AND METHODS

Eight adult patients, their ages ranged from 22-45 years, including 5 females and 3 males were enrolled in this study . All the included patients had features of a mandibular prognathism and treated by performing bilateral sagittal split osteotomy.

All patients received and managed in the Department of oral and Maxillofacial Surgery, Faculty of Dentistry Tanta University.

All the selected patients were informed about the steps of surgery, the steps of evaluation and they gave their approval consent to participate in this study, after listening to a detailed explanation of all EMG procedures.

This prospective cohort study was carried out in a period between May 2015 and June 2020.

## Preoperative management

Patient interview and medical history had been taken for all the selected cases for listening properly to the patient's aesthetic and functional complaints. Clinical examination through intraoral and extraoral examination and standardized clinical photographs had been performed for all the selected cases *fig (1)*. Orthodontic preparation for performing dental alignment and incisor

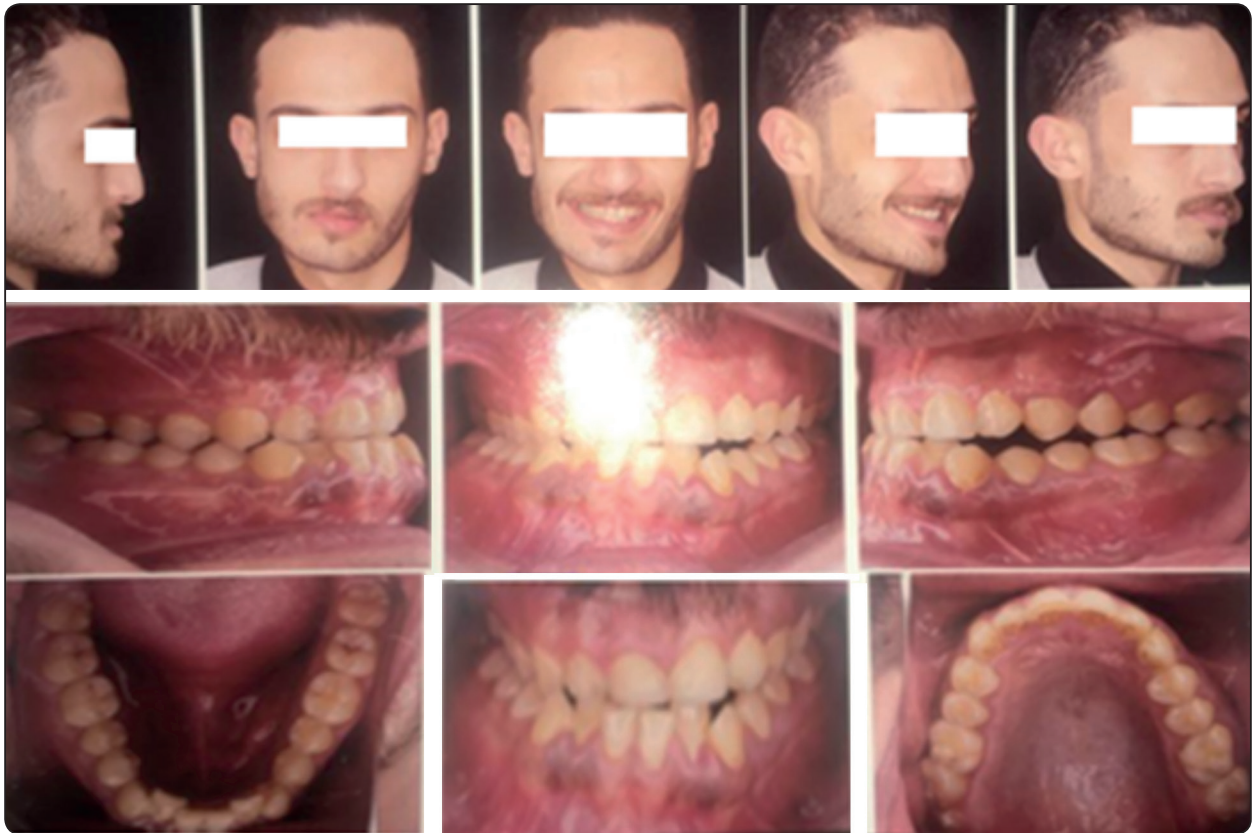

Fig (1) Preoperative extraoral and intraoral clinical photographs, case no.3, showing aesthetic problem and presence of occlusal discrepancy.

decompensation was performed for the purpose to obtain maximum intercuspal interdigitation postoperatively. Radiographic evaluation including orthopantograms *fig (2)*, Lateral cephalometric view (to detect properly the distance of bone set back that was needed) *fig (3)* and computerized tomograms (Axial, coronal and 3D scan were performed for all patients) *fig (4)*. These radiographs facilitate the treatment plan and to detect properly the accurate cut site and accurate bone set back to obtain proper jaw relations postoperatively. Electromyographic examination was performed for both temporalis and masseter muscles by utilizing the EMG device (*Nemus, Biomedica, 00655, Galileo NT software version 3.71/00, Italy*) which amplified, digitized, and digitally filtered the analogue EMG signal. The electromyograph was connected to a computer for data storage and subsequent analysis.

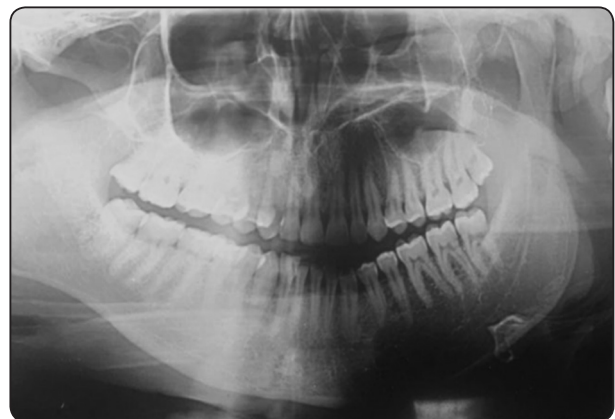

Fig. (2) Preoperative orthopantogramic view, case no. 3, showing presence of skeletal discrepancy of the lower jaw.

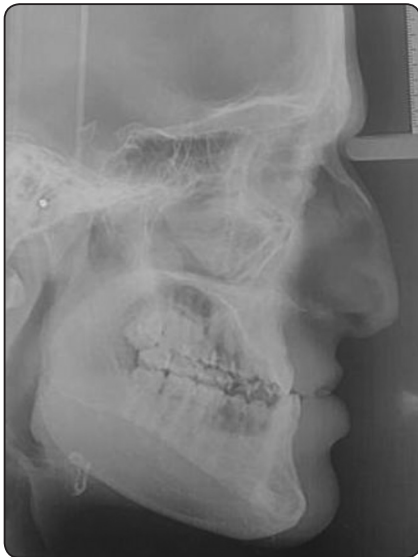

Fig. (3) Preoperative lateral cephalometric view, case no.3, showing skeletal class II malocclusion.

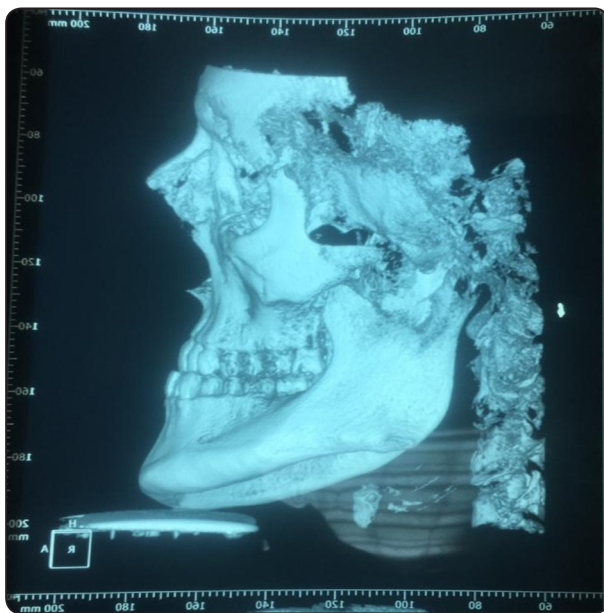


Fig. (4) preoperative 3 dimensional computerized tomogram showing mandibular prognathism

### Surgical technique

Two gram cefotaxime and 0.5 mg/kg dexamethasone administered intravenously.

All patients were operated under general anaesthesia with nasoendotracheal intubation. The surgical field was scrubbed using concentrated *Betadine* (Bovine iodine 1%, the Nile Co. for pharmaceuticals and chemicals industries, Cairo, A.R.E.) and draped with surgical towels.

*Mepivacaine* Hcl 2% with 1/20000 norepinephrine (Alexandria Co. for pharmaceuticals and chemical industries, Egypt) was injected at the incision lines for performing hemostasis and to facilitate separation of tissue planes. The BSSO technique was carried out according to *Hunnsucks modification*<sup>(8)</sup>

An incision and mucoperiosteal flap performed in the region of the planned osteotomy. Stripping of the insertion of temporalis muscle was done to facilitate performing exposure of the medial aspect of the ramus, then enter the periosteal elevator subperiosteally above the mandibular foramen.

The inferior alveolar nerve was identified at the lingula, and great care was taken not to overstretch the inferior alveolar nerve.

The medial horizontal osteotomy cut was made by Lindeman bur, just above the lingula and parallel to the occlusal plane of the lower Jaw.

Then perform the oblique and buccal cuts by the same Lindeman bur, then the lower border of the mandible was cut with the Lindeman bur.

The same procedure was performed on the opposite side. So now the mandible was separated into two segments, proximal and distal segments *fig. (5)*.

After performing mandibular setback, according to the preoperative planned distance, a thin inter-occlusal acrylic splint (wafer) was placed with an intermaxillary wire fixation. Bone segments were



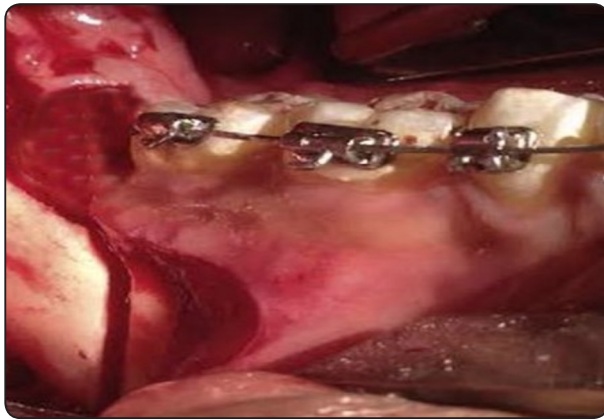


Fig. (5) Intraoperative clinical photograph showing the buccal osteotomy cut of BSSO.

stabilized with titanium miniplates Synthes 2 mm (synthes, Gm6H, Solotharn, Switzerland.monocortical screws.

### Postoperative management

- All patients were given 1 gram cefotriaxone sodium as Cephaxone 1 gm (*Kahira Pharmaceutical and chemical industries co. Egypt*).
- Intravenously twice daily for one week.
- All patients were given 100 mg Diclofenac potassium (*Egyptian international pharmaceutical industries co. 10<sup>th</sup> of Ramadan City, Egypt*) intra muscularly twice daily for one week. Alpha chemoptrypsin (*Amoun Pharmaceutical industries Co. Elobour City, Cairo*) was administered for all patients intramuscularly twice daily for 72 hours.
- All patients instructed to maintain proper oral hygiene, by performing proper tooth brushing and oral irrigation with a mixture of saline 0.9% and povidine iodine mouthwash 4 times days.
- The patients admitted in the hospital on the day of the operation and then discharged after 24 hours postoperatively.
- Removal of the sutures was performed 7 days after the operation.

### Electromyographic examination

The electromyographic study of both right and left masseter and temporalis muscles during rest and maximum voluntary contraction of the teeth were done using concentric needle electrodes <sup>(9)</sup>. The needles were autoclaved before use in each subject.

The EMG activity of the both masseter and temporalis muscles were recorded with an electromyographic device (*Nemus, Biomedica, 00655, Galileo NT software version 3.71/00, Italy*) which amplified, digitized, and digitally filtered the analogue EMG signal. The electromyograph was connected to a computer for data storage and subsequent analysis. The muscle activity was recorded in microvolts ( $\mu\text{V}$ ) and in seconds.

The electromyographic examination was performed for all cases both preoperatively (first examination to obtain the baseline data one week before surgery) fig (6) and 12 months postoperatively fig (7) , to verify the modification to base line data of both temporalis and masseter muscles after orthognathic surgery.

The postoperative EMG recordings were done 12 months after surgery, this time span is considerable to be adequate for the patients to adapt properly to their newly created occlusal relationship. Patient of which all electromyographic examinations were not available and/or did not attend the follow up examinations were excluded.

The patients were in the resting position, sitting on the chair with head supported and their feet flat on the floor. They were asked to relax completely.

In each patient, the test was performed without changing the electrodes or moving the cables. Before placing the EMG electrodes on the patient, the skin covering the temporalis and masseter muscles was cleaned properly with alcohol.

Regarding the masseter muscle, the concentric needle electrodes were placed on the cross point of a line from the external canthus of the eye to the

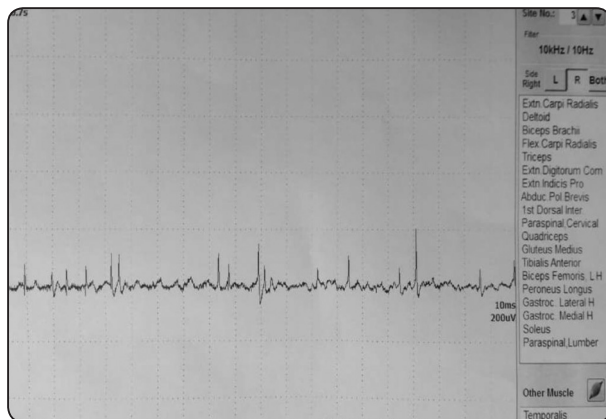


Fig. (6) Preoperative electromyographic photograph, case no.3, showing the base line data of right temporalis muscle

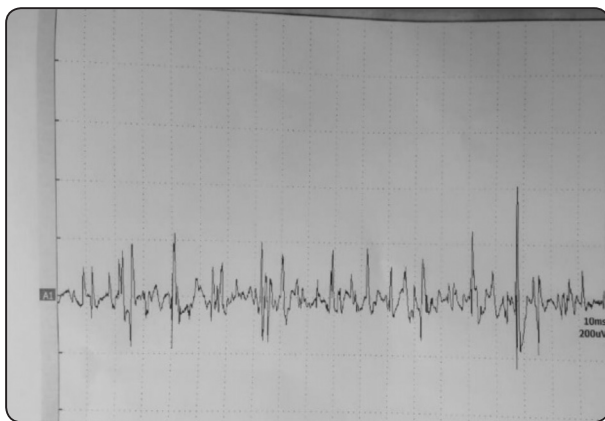


Fig. (7) Postoperative electromyographic photograph, case no.3, showing an increase in the peak-to-peak amplitude score of right temporalis muscle.

angle of the mandible and a line from the center of the tragus to the corner of the mouth. This was the thickest part of the masseter muscle which becomes more prominent when subjects were asked to bite harder on their posterior teeth.

As regard to the temporalis muscle, the concentric needle electrodes were placed about 1 cm above the zygomatic arch and 1.5 cm behind the orbital border. Care was taken to prevent injury to superficial temporal artery. Also, the orbicularis oculi muscle was avoided.

The ground electrode was placed on the side of the neck at C5 level. The electromyographic instrument utilizes this electrode as a reference

eliminating part of all background noises. So, the ground electrode can be considered as a first filter to abolish interferences.

The EMG activity of the masseter and temporalis muscles was recorded both at rest and during maximum voluntary contraction.

When recording at rest, the subjects were asked to sit comfortably, maintain a natural erect position, and wait without moving their jaws. In this resting situation of the examined muscles, EMG must record a straight line indicating no noise.

When recording in maximum voluntary contraction, the subjects were asked to bite as hard as possible and do not swallow during the recording. The maximum voluntary contraction of the masseter and temporalis muscles was obtained by biting on a 10-mm thick cotton dental roll positioned on the mandibular second premolars and molars. The subject was asked to clench as hard as possible for 5 seconds. To prevent muscle fatigue from disrupting EMG activity, a rest period of at least 5 minutes was allowed between each recording. The mean of three measurements taken at rest and in maximum voluntary contraction were calculated.

The following parameters were considered for the measurement of electromyographic activity:

- Peak to peak amplitude corresponds to the electrical activity of the muscle fibers. Peak to peak amplitude is the change between peak (highest amplitude value) and trough (lowest amplitude value). High levels of peak-to-peak amplitude mean muscular hyperactivity. Low levels of peak-to-peak amplitude mean muscle hypoactivity.
- The frequency of the motor response depends on the recruitment of electrical impulses generated by the motor neurons. Frequency means the number of cycles per second in which the temporalis and masseter muscles activity was measured.

**Statistical analysis**

All the obtained data both preoperatively and post operatively (after 12 months from surgery) collected and statistically analyzed using IBM the mean(m) and standard deviation (SD)were calculated for both preoperative and postoperative measurements of both masticatory (temporalis and masseter) muscles. The difference between the values of EMG variables were analyzed with paired t test for both preoperative and postoperative measurements of both temporalis and masseter muscles. p- value less than 0.05 considered as statistically significant.

**RESULTS**

The electromyographic study of both right and left masseter and temporalis muscles during rest and maximum voluntary contraction of the teeth were done using concentric needle electrodes. EMG examinations (peak to peak amplitude), for detection of the strength of contraction of both temporalis and masseter muscles were done preoperatively and twelve months postoperatively to detect the strength of contraction of both muscles.

TABLE (1) Summarized the EMG variables of the masseter muscle that was calculated for the 8 patients, enrolled in this study, both before and after bilateral sagittal split osteotomy (after 12 months from surgery)

Variables	Bilateral sagittal split osteotomy		P value
	Before	After	
Frequency (Mean ±SD)	4(±1)	5 (±1)	0.06
Right peak to peak amplitude Mean (±SD)	121 (±35)	157 (±37)	0.06
Left peak to peak amplitude Mean (±SD)	100 (±27)	118(±28)	0.21

No significant differences were found in the mean frequency score (as one of the variables of the EMG measurement) of the masseter muscles before bilateral sagittal split osteotomy and that undertaken 12 months after bilateral sagittal split osteotomy (P = 0.06).

However, an increase in the mean peak to peak amplitude score of the right and left masseter muscle was found, but with no significant differences between measurement found 12 months after bilateral sagittal split osteotomy, and that measured before bilateral sagittal split osteotomy (P = 0.06,0.21 respectively) (Table 1).

TABLE (2) Showed the EMG variables of the temporalis muscle that was calculated for the 8 patients, enrolled in this study, both before and after bilateral sagittal split osteotomy (after 12 months from surgery)

Variables	Bilateral sagittal split osteotomy		P value
	Before	After	
Frequency (Mean ±SD)	4 (±1)	5 (±2)	0.23
Right peak to peak amplitude Mean (±SD)	100(±138)	173 (±39)	0.002*
Left peak to peak amplitude Mean (±SD)	105 (±31)	195 (±30)	0.001*

*\*P -value is significant if P≤0.05.*

Although there was a decrease in the mean frequency score of the temporalis muscle, no significant differences were found in the measurement that obtained 12 months after bilateral sagittal split osteotomy in comparison with the measurements of the temporalis muscle before bilateral sagittal split osteotomy (P =0.23). An increase in the mean peak to peak amplitude score for the right and left temporalis muscle was

found, with significant differences between the measurement found 12 months after bilateral sagittal split osteotomy, and that measured before bilateral sagittal split osteotomy fig (6) ( $P = 0.002, 0.0001$  respectively) (Table 2).

## DISCUSSION

This study measured the baseline electromyographic (EMG) activity (frequency, and peak to peak amplitude) of the temporalis and masseter muscles (before surgery) to compare it with the EMG activity recorded at 12 months after orthognathic surgery in patients with class II malocclusion.

Various types of electromyographic electrodes have been used for recording EMG activity but concentric needle electrodes were selected for the current study because of many advantages such as only one electrode to be inserted, more accurate assessment, easy to place in a hairy region in the temporalis muscle and no interference in recording from the skin impedance. The method used for placing electrodes for masseter and temporalis muscles was similar to the one advocated by **Sandhu in 2013**<sup>(9)</sup>.

This study confirmed the presence of correlation between the morphology of the facial skeleton and the functionality (electromyographic activity) of both temporalis muscle and masseter muscle. This agrees with **Giannini et al., (2017)**<sup>(10)</sup>, who denoted presence of correlations between the facial skeletal morphology and the muscular function.

In the current study, no significant differences were found in the mean frequency of the electrical activity of both masseter and temporalis muscles. This result indicates no damage to the motor unit after orthognathic surgery. Moreover, a nonsignificant increase in peak-to-peak amplitude of both masseter muscles was found 12 months after the surgery. This result was similar and comparable to those reported by **Raustia and oikarinem (1994)** who investigated the effect of EMG activity after orthognathic

surgery<sup>(3)</sup>. They found that the mean electric activity in the masseter and temporalis muscles increased and was similar to the baseline values after 1 year after surgery.

Furthermore, the peak-to-peak amplitude of both temporalis muscle increased at 12 months post orthognathic surgery in comparison to the basal mean before surgery. This agrees with the finding of **Olivares et al., 2019**<sup>(11)</sup> who found that electromyographic activity was restored 6 months after the orthognathic surgery. In concordance with these results, **Frongiaet al., 2013**<sup>(12)</sup> found significant changes in the electromyographic activity of the temporalis and masseter muscles after orthognathic surgery. Also, they mentioned that evaluation of EMG activity after orthognathic surgery can be considered a sign of good adaptation of the neuromuscular system.

According to the obtained results of this study (peak to peak amplitude), The activity of temporalis muscle increased. This was in acceptance with **Trawitzki et al., (2006)**<sup>(13)</sup> who found that in patients presented with class II malocclusion and evaluated via EMG 6 and 9 months post orthognathic surgery that peak-to-peak amplitude increased. Therefore, orthognathic surgery improves the muscle activity in class II malocclusion patients.

Finally, according to the recorded postoperative EMG activity in this study, improvement in the masticatory muscles' activity has been detected. This result was in acceptance with **kawai et al**<sup>(14)</sup>, **2020**, who reported the occurrence of marked improvement in the activity of masticatory muscles after correction of the present skeletal deformity.

## CONCLUSION

No change in the strength of contraction of both temporalis and masseter muscle had detected after performing BSSO for correction of mandibular prognathism, as detected by EMG examination. The use of EMG evaluation for determining of the



activity of the masseter and temporalis muscles should be routinely used during patients follow up, to obtain more refined data about the rehabilitation process after orthognathic surgery of the lower jaw, as it considered as an easy and minimally invasive test.

## REFERENCES

1. Upadhyaya C, Baliga MandShetty P. (2013) soft tissue changes after orthognathic surgery. *OrthodJ.Nepal.* 1 (1): 47-51.
2. Coclici A, Hedesiu M, Bran S, Bacuit M, Dina C, Rotaru H and Roman R (2019): Early and long-term changes in the muscles of the mandible following orthognathic surgery. *J. of clinical oral investigation*, 23(9): 3437-3444.
3. Raustia AM andOikarinen KS. (1994): Changes in electric activity of masseter and temporal muscles after mandibular sagittal split osteotomy. *Int. J. Oral Maxillo- fac. Surg.* 23: 180-184.
4. Ettorre G, Weber M, Schaof H, Lowry JC, MommaertsYM and HowaldtH. (2006): Standards For digital Photography in Cranio Maxillofacial Surgery-Part I: basic views and guide lines. *J. Craniomaxillofacial surgery* 34(2): 65-73.
5. Sfoza C, peretta R, Grandi G, ferronato G and Ferrario VF (2008): Soft tissue facial planes and masticatory muscle function in skeletal class II patients before and after orthognahic surgical treatment. *J. oral & maxillofacial surgery* 66: 691-698.
6. Van Eijden TM and Turkwaski SJ. (2001): Morphology and physiology of masticatory muscle motor units. *Crit Rev. Oral Biol Med.*12:76-91.
7. Serra MD, Duarte Gaviao MB, and Dos Santos and Uchôa MN. (2008): the use of ultrasound in the investigation of muscles of mastication. *ultrasound Med. Biol.* 34(12) (1875 – 1884).
8. Hunsuck EE. (1968): A modified intraoral sagittal splitting technique for correction of mandibular prognathism. *J. Oral Surgery*, 26:250-253.
9. Sandhu SS, Utreja A, Prabhakar S, Sandhu N, Kashyap R.(2013): A study of electromyographic activity of masseter and temporalis muscles and maximum bite force in patients with various malocclusions. *J IndOrthod Soc.* 47(2):53-6.
10. Giannini L, Maspero C, Galbiati G, Kairyte L, Zanoni F, Farronato G. (2017): Orthodontic-surgical treatment: electromyographic and kinesigraphic evaluation in follow up period. *Stomatologija, Baltic Dental and Maxillofacial Journal*, 19: 35-43.
11. Olivares HG, Pérezl G, Saucedo FL, and Medina FA (2019): Electromyographic changes in the masseter and temporalis muscles before and after orthognathic surgery in patients with mandibular prognathism. *J craniofacial Surg.*30 :1539-1543.
12. Frongia G, Ramieri G, De Biase C, Bracco P and and Piancino MG (2013): Changes in electric activity of masseter and anterior temporalis muscles before and after orthognathic surgery in skeletal class II patients. *Oral Surg Oral Med Oral Pathol Oral Radiol.* 116:398–401.
13. Trawitzki LV, Dantas RO, Mello-Filho FV, Marques WJ (2006): Effect of treatment of dentofacial deformities on the electromyographic activity of masticatory muscles. *Int J Oral Maxillofacial Surg.* 35(2): 170–173.
14. Kawai N, Shibata M, Watanabe M, Horiuchi S, Fushima K and Tanaka E. (2020): effects of functional training after orthognathic surgery on masticatory function in patients with mandibular prognathism. *Journal of dental science*, 15(4):419-425.