

PRIMARY RECONSTRUCTION OF MANDIBULAR DEFECTS AFTER RESECTION OF AGGRESSIVE PEDIATRIC MANDIBULAR TUMORS BY SPLIT RIB BUNDLE BONE GRAFT. A RETROSPECTIVE STUDY

Ahmed M. Medra*, Essam M. Ashour** and Ehab Aly Shehata***

ABSTRACT

Background: A retrospective study was done to evaluate the success rate of immediate reconstruction by split rib bundle bone grafting after segmental resection of Aggressive Pediatric mandibular tumors.

Materials and Patients: The present study enrolled sixty-one pediatric patients with aggressive mandibular tumors that had been treated during the period from January 2008 to December 2018. All patients were examined clinically and radiographically by Orthopantomograms, CTs and CBCTs. Radical segmental resection with resultant mandibular continuity defects were thus created followed by immediate reconstruction with non-vascularized Split Rib Bundle Bone Graft (SRBBG). Patients were then rehabilitated by osseointegrated implants with fixed or removable partial dentures. Success of reconstruction was assessed by the percentage of complications, interincisal opening and patient satisfaction. Assessment was performed at 1,3,6 and 12 months postoperatively. All patients were followed up for 4-7 years.

Results: Successful reconstruction was accomplished in 55 patients (90.16%). Successful dental rehabilitation was accomplished in 49 patients (89%). Three patients had complete failure due to severe postoperative infection. Another three cases had partial resorption of the graft due to moderate infection to whom re-augmentation by another rib graft had been performed.

Conclusion: Pediatric aggressive mandibular tumors should be treated in an aggressive manner relative to its biologic behavior and immediate reconstruction is advocated. The Split Rib Bundle Bone Graft is an adequate alternative for mandibular reconstruction in the absence of microvascular surgery as it shows early revascularization thus permitting rehabilitation with successfully osseointegrated dental implants.

KEYWORDS: Segmental Resection, Immediate reconstruction, Split Rib Graft

* Professor of Cranio-Maxillofacial and Plastic Surgery, Faculty of Dentistry, Alexandria University, Egypt.

** Associate Professor of Oral and Maxillofacial Surgery, Faculty of Dentistry, October 6 University, Egypt.

***Assistant Professor of Cranio-Maxillofacial and Plastic Surgery, Faculty of Dentistry, Alexandria University, Egypt.

INTRODUCTION

Primary maxillofacial tumors in the pediatric population are generally rare in comparison to the adult population. However, tissue damage caused by these tumors is of great importance as they can modify facial growth and dental development in pediatric patients inflicting physical, esthetic, functional and psychological alterations ^[1].

Pediatric central jaw tumors are collectively classified into odontogenic and non-odontogenic groups of which odontogenic tumors are considered to be more common in children. Tumors and tumor-like growths arising from odontogenic origin represent a heterogeneous cluster of interesting lesions, as they display the numerous inductive interactions that sometimes occur among the embryologic components of the developing tooth germs ^[2].

Aggressive tumors can be defined based on known clinical presentation, biologic behavior and/or histopathologic type. They have a high incidence of recurrence after inadequate initial treatment, exhibit rapid growth, large size (>5cm), causing tooth displacement, root resorption, cortical bone expansion, thinning, or perforation ^[2].

The histopathological origin of these tumors is variable, but their local behavior is frequently aggressive, more often not matching their benign histologic appearance exhibiting rapid local growth with local invasion and massive tissue destruction ^[1]. Moreover, Pediatric tumors normally exhibit high recurrence potential owing in fact to the growth potential of their developing cells ^[3].

In spite of their rapid growth and destructive clinical behavior, pediatric lesions are commonly benign, however, treatment must be based on their biological and clinical behavior which is normally aggressive. Treatment objectives must therefore be directed towards radical resection to lesion-free margins with immediate reconstruction aiming to rejuvenate facial esthetics and restore organ function and whenever possible favoring growth of any affected anatomical structures ^[1-3].

Mandibular reconstruction possesses functional and aesthetic components; functionally its primary goal is furnishing and providing skeletal support for the lips, tongue and floor of the mouth for the purpose of oral functions as swallowing, speech and oral competence. Adequate mandibular reconstruction, furthermore should provide sufficient bone bulk and reserve facilitating oral rehabilitation by insertion of osseo-integrated dental implants or partial dentures. Moreover, it should target to regain and reconstruct the contour of the lower face avoiding readily apparent unnatural profile ^[4].

There are various techniques to reconstruct mandibular defects depending on; the extent and location of the defect, timing of reconstruction (immediate or delayed), the recipient site conditions (vascular, fibrosed, or irradiated bed), state of soft tissue (adequate or deficient), experience of the surgeon, and facilities present ^[4-6].

Non-vascularized bone grafts from the iliac crest ^[4] and split ribs ^[7] have been used for decades in primary mandibular reconstruction where there is good soft tissue coverage, and in secondary reconstruction after repair of soft tissue shortage.

With the increasing tendency and shift to early or primary reconstruction, utilization of free vascularized flaps is being increasingly adopted in primary mandibular reconstruction. Moreover, in patients with poorly vascularized beds as in severe infection or irradiation, vascularized flaps are also indicated ^[8].

Nowadays, free vascularized tissue transfer is considered the gold standard for the repair of large mandibular defects following radical resection of aggressive tumors^[8,9]. The surgery, however, is of long duration and requires facilities such as intensive care units' ICUs and surgical expertise in microvascular surgery which sometimes may not be available. Moreover, pediatric patients can be medically brittle when subjected to extended lengthy surgical procedures ^[10, 11].

There is another added problem in using vascularized flaps with contour restoration, that segmentalization for adequate contouring of the graft is difficult to achieve without jeopardizing the blood flow to the bone or to the soft tissues^[8, 10, 11].

It has been postulated by many authors that rib reconstruction in the absence of microvascular surgery is considered as an acceptable, sufficient and satisfactory alternative for primary mandibular reconstruction^[4, 7, 10].

A rib graft can provide good mandibular shape and configuration while maintaining a component of function. The costochondral part can also replace a missing or resected condyle allowing for further growth potential which is of prime importance for the growing pediatric population.

Moreover, it possesses the technical advantage of that the procedure is feasible, reliable and easy to perform with minimal donor side morbidity and postoperative complications^[7, 10-14].

Unfortunately, many of the old techniques for jaw reconstruction had been neglected and withdrawn out of modern clinical practice and young modern surgeons only have microvascular skills at their disposal.

This article defines and evaluates the authors' experience of utilizing autologous rib grafting through the "Split Rib Bundle Bone Graft Technique" in the immediate reconstruction of long span mandibular discontinuity defects following resection of aggressive pediatric mandibular tumors in our institutes focusing on the surgical technique adopted and the possible complications encountered and demonstrating long-term follow-up outcomes including dental rehabilitation, when needed.

This article represents an attractive address for surgeons to keep and cling to old skills and nearly neglected techniques along with the advance of modern practice to provide a more skilled, professional and clarified surgical technique.

MATERIALS, PATIENTS AND METHODS

The present study enrolled sixty-one pediatric patients with aggressive mandibular tumors that had been treated during the period from January 2008 to December 2018. Thirty-five patients were treated at the Department of Cranio-Maxillo-Facial and Plastic Surgery, Faculty of Dentistry, Alexandria University, while twenty-six patients were treated at the Oral and Maxillofacial Surgery Department, Faculty of Dentistry, October 6 University, Egypt. Appropriate ethical clearance was obtained from the ethical committee of both universities.

All patients were examined clinically for their complaints of pain, difficulty of mastication, facial swelling and disfigurement. Radiographic examination utilizing Orthopantomograms, Cone Beam C.Ts, C.T scans was undertaken for all patients. Magnetic resonance imaging was performed in selected cases, when indicated, according to the patient age and nature of the tumor encountered (Fig. 1-2) both to delineate and characterize the disease and for assistance during planning for reconstruction.

Aspiration together with incisional biopsies were performed for all patients and were subjected to histopathological examination before surgical intervention. All patients below the age of 16 years who were histologically diagnosed as having an intra-osseous Benign tumors or tumor-like lesions were included in the study. Tumors having malignant criteria were excluded. Tumors of the mandible were; Ameloblastoma and Ameloblastic Fibroma (23), Juvenile Ossifying Fibroma (11), Odontogenic Myxoma (9), Aneurysmal bone cyst (6), Central Giant Cell Tumor of the mandible (4), desmoplastic fibroma (5) and high flow vascular malformations (3). All patients were primarily reconstructed after tumor resection, and all had mandibular discontinuity defects. There was no soft tissue deficiency in these patients. For all patients, informed consent for accepting the treatment plan was obtained from parents before any surgical intervention.

Mandibular defects were as follows;

1. Hemi-mandibular defects including the body, ramus, condyle, and coronoid (27 patients).
2. Hemi-mandibular defects sparing the condyle after vertical subsigmoid osteotomy (21 patients).
3. Hemi-mandibular defects extending beyond the midline (13 patients).

In terms of resources, patients were medically brittle and there were no available facilities for microvascular reconstruction. Moreover, patients were young, debilitated, not well nourished and with diminished physiological reserve thus limiting and preventing prolonged and extensive microvascular surgical procedures.

All patients were treated using the same staged

protocol as follows: 1) 3D C.T was done in selected cases for virtual planning and 3D printing of a mandibular model in order to perform preoperative adaptation and contouring of the reconstruction plates and for proper dimensional planning during reconstruction of the residual bony defect. 2). Segmental resection with safety margins of at least one cm of normal bone (or one dental unit) beyond the radiographic tumor margins was performed with placement of a rigid mandibular mini or reconstruction plate, 3) Immediate reconstruction using a free non-vascularized split rib bundle bone graft (SRBBG) was performed for all patients. 4) Implant placement using the 2-stage surgical protocol 6 months after removal of the reconstruction plate and 5) Implant loading approximately 6 months after stage 4.

TABLE (1) Demographic Data showing line of treatment for each mandibular defect

	Tumors	Site	Number	Line of treatment
1	Ameloblastoma / Ameloblastic Fibroma	Posterior region of the mandible	16	Hemi-mandibular Defect including body, ramus, condyle and coronoid process
		Posterior region of the mandible	3	Hemi-mandibular defect sparing the condyle after vertical sub-sigmoid osteotomy
		Anterior + Posterior regions of the mandible	4	Hemi-mandibular Defect extending beyond midline
2	Ossifying Fibroma	Posterior region of the mandible	11	Hemi-mandibular Defect including body, ramus, condyle and coronoid process
3	Odontogenic Myxoma	Posterior region of the mandible	9	Hemi-mandibular defect sparing the condyle after vertical sub-sigmoid osteotomy
4	Aneurysmal Bone Cyst	Posterior region of the mandible	6	Hemi-mandibular defect sparing the condyle after vertical sub-sigmoid osteotomy
5	Central Giant Cell Tumor	Anterior region of the mandible	4	Hemi-mandibular Defect extending beyond midline
6	Desmoplastic Fibroma	Anterior region of the mandible	5	Hemi-mandibular Defect extending beyond midline
7	High flow vascular Malformation	Posterior region of the mandible	3	Hemi-mandibular defect sparing the condyle after vertical sub-sigmoid osteotomy

Surgical technique

Surgical Approach

Usually, the operation is done through a combined intra-oral and extended submandibular and Risdon incisions to expose the mandibular tumors. The tumor was removed subperiosteally in all patients, except if there was cortical perforation with soft tissue extension and in recurrent cases, where a supraperiosteal dissection and resection were performed. Resection of the coronoid process was undertaken in cases where the lesion involved

the mandibular angle thus guarding against being under the influence of the upward pull of the temporalis muscle that could lead to displacement of the proximal segment in a Superior and medial direction. Moreover, If the lesion approximated or involved the condyle, disarticulation of the temporomandibular joint was performed leaving the articular disc in place, to avoid recurrence of the lesion and subsequent invasion of the infratemporal fossa as well as to act as a cushioned surgical bed for costochondral grafting.

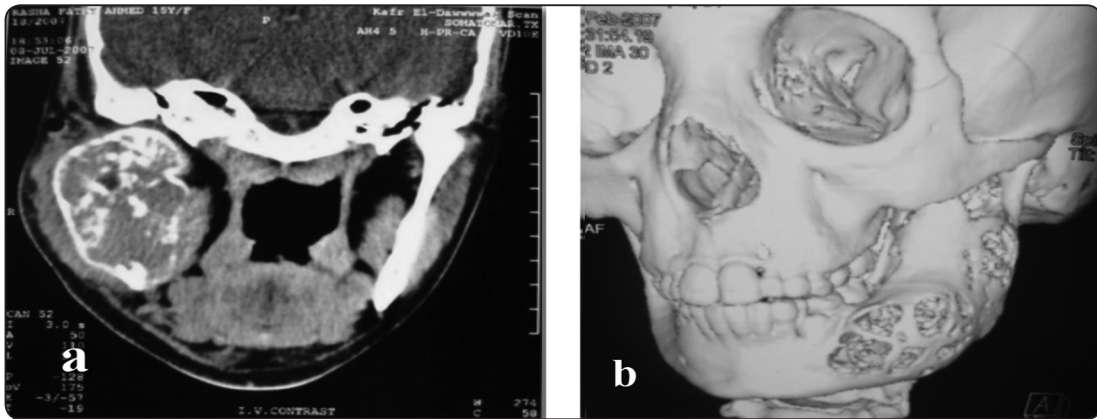


Fig. (1): a. Preoperative Coronal C.T of Desmoplastic Fibroma showing a mixed radiolucent - radiopaque lesion of the right mandibular body, angle and ramus. b. Preoperative 3D CT showing Ameloblastic Fibroma of the left body, angle and ramus.

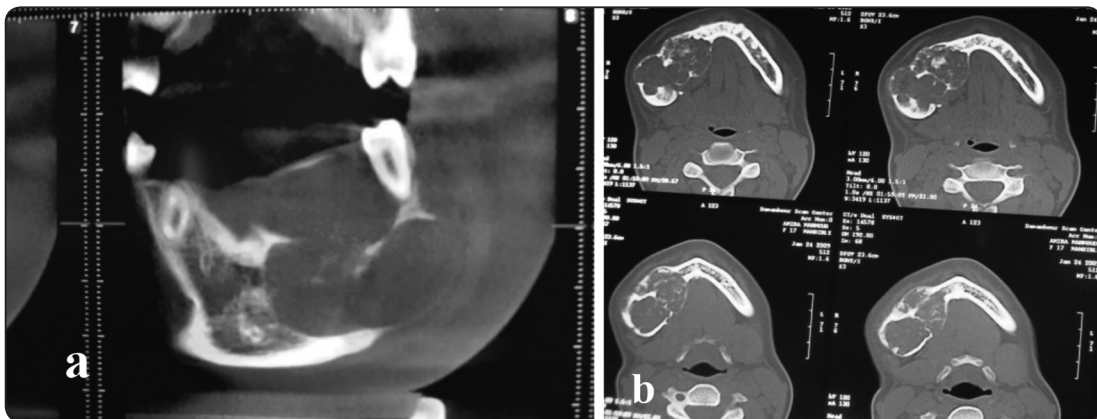


Fig. (2): a. Preoperative sagittal C.T of Ameloblastic Fibroma showing perforation of both buccal and lingual cortices and the inferior border of the mandibular angle and ramus. b. Axial C.T showing mixed RL-RO appearance of Juvenile Ossifying Fibroma of the right mandibular body, angle and ramus.

Reconstruction Plate adaptation and fixation

Preoperatively, DICOM files were converted to STL files for printing a model of the mandible with mirror image of the normal side for preoperative adaptation and contouring of the reconstruction plate thus saving the operative time.

Before resection of the lesion, the custom pre-adapted and contoured heavy 2.7mm reconstruction plate was utilized to establish the mandibular continuity. In cases of intraosseous lesions without cortical perforation and soft tissue invasion, the plate was fixed before resection. At least 3 holes were drilled in each stump whenever possible.

However, in those cases where gross cortical perforation, soft tissue invasion and facial disfigurement were encountered, Maxillo-mandibular fixation was applied first to preserve the interarch space either by complete upper and segmental lower arch bars or Ivy loops or even direct wiring applied to the remaining lower teeth, if any was still present. Here, the resection was performed first followed by fixation of the reconstruction plate to the mandibular stumps establishing continuity (Fig. 3)

Preparation of the Mandibular stumps

The sharp edges of the proximal and distal mandibular stumps, were reduced and smoothed aiming to permit water-tight and tension-free mucosal closure at these critical areas thus preventing

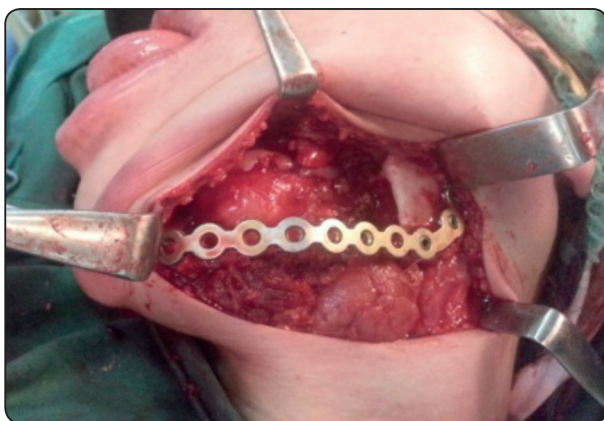


Fig. (3): Fixation of the reconstruction plate

the sharp mandibular stumps from penetrating the overlying mucosa. Mandibular stump decortication was performed by removing the outer cortices of the mandible using a dome-shaped bur thus creating a box configuration. The goal of this maneuver is to expose the spongiosa, thus favoring bony union and encouraging graft intake.

Harvesting the Rib Graft and Making the Bundle

The patient was placed in the prone decubitus position and the thorax was disinfected and draped in the usual manner to be included in the surgical field. Putting a pillow under the ipsilateral chest wall facilitates harvesting a long segment of the rib.

Two alternating ribs, usually the fourth and the sixth or the fifth and the seventh were harvested from either side of the chest wall. We prefer the right side unless a graft had previously been taken from that side. We avoided the use of two succeeding ribs to prevent the occurrence of the postoperative complication of a flail chest.

After making a minimally invasive 7 cm infra-mammary incision through the skin and underlying subcutaneous tissues, the rectus abdominis muscle was identified, running vertically through the surgical field. The muscle was bluntly dissected, divided horizontally, and retracted superiorly and inferiorly. The underlying rib was identified and bluntly dissected from the surrounding tissues until the periosteum is reached. Both ribs can be accessed via the same horizontal incision and exposed in a subperiosteal plane.

Using Doyen rib elevators, a circumferential subperiosteal dissection will expose the bare surface of the ribs with release of all of the attached soft tissues. To avoid injury to the neurovascular bundle or the pleural space, careful blunt dissection should be carried while freeing the inferior aspect of the rib. Each harvested rib should be approximately 10–12 cm in length and once stripped off the attached tissues and delivered, the lung can be readily visualized through the underlying fascia. Great care

should be taken to avoid perforating the chest wall and subsequent pneumothorax.

The required length of the rib graft can be delivered by cutting it both proximally and distally using a rib cutter for removal. A high-speed drill or an oscillating saw is generally preferred because a rib cutter can splinter the rib adjacent to the cut surface.

The overall length, shape, and sagittal contour of the ribs that were required were determined by the size and recorded dimensions of the defect to be reconstructed. Sufficient bone should be removed to provide both structural and morselized autograft.

Owing to the incomplete osseous maturation in pediatric patients, the two ribs were then easily longitudinally splitted along their length using a fine osteotome manipulated by manual pressure (Fig. 4)

and reversed so that the marrow surface was facing outwards. The split ribs are soft and malleable and can be shaped and manipulated to conform into and adapt to the contour of the mandible.

Finally, the parietal pleura should be irrigated and inspected for any air leak by hyperinflation of the lungs. Small defects in the pleura can be repaired primarily. Before closure, the area was copiously irrigated with normal saline and sutured in routine fashion with 3/0 vicryl and 5/0 nylon sutures.

In setting of the Rib Bundle Graft

With the teeth in perfect occlusion via the maxillo-mandibular fixation, one split rib was fixed to the proximal mandibular stump by wire or screw, placing it in the previously decorticated box and secured to the reconstruction plate. A second split

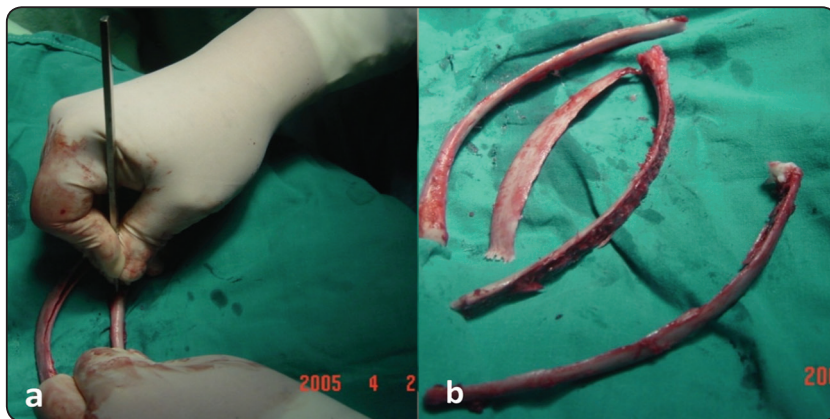


Fig. (4):

- a. Two ribs were splitted into four halves with preservation of the spongiosa.
- b. Manual Splitting of the rib into two halves by fine osteotome

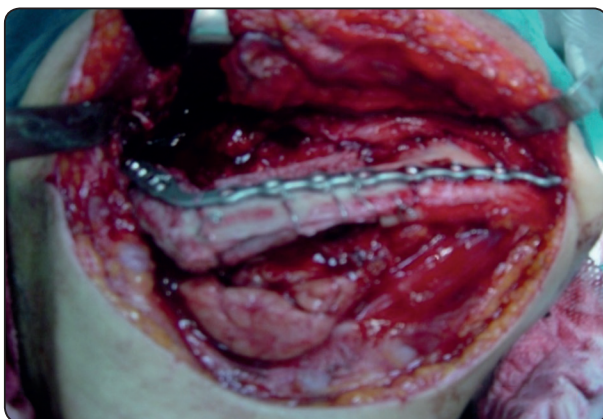

Fig. (5): Final situation after fixation of the four splits with reconstruction plate.

rib was then placed at the distal mandibular stump in a similar manner. The other two splits, were telescoped to achieve a proper mesio-distal and vertical spanning of the defect (Fig.5).

The four splits were then fixed as a bundle either by transosseous-circumferential wires or screws, and then fixed to the reconstruction plate by screws. Additional ribs or portions of the ribs, were added to obtain acceptable bucco-lingual thickness as well as adequate vertical height.

When the condyle was resected, one split costochondral graft was used to replace it. Three to five millimeters of cartilage were left attached to the medial end of the rib strut. This was carved with a scalpel to create a smooth, compressible, rounded or hemi-spherical articular surface; thus, the resulting cartilage-capped bony strut becomes the new condylar head. When the rib was installed into the joint space, the sternal cartilage component of the rib strut was aligned to function against the glenoid fossa with the retained articular disc of the resected condyle. Thus, a cartilage-on-cartilage joint was created.

The split rib bundle bone graft was then wrapped in muscles and soft tissues where the masseter, buccinator, mylohyoid, and genial muscles were suspended to the graft and plate by several 2/0 vicryl sutures. The patients' occlusion was checked periodically throughout the procedure. The oral mucosa was closed by a single layer of continuous or interrupted 3/0 black silk sutures. Another supporting layer was done on the undersurface of the mucosal one by 3/0 vicryl sutures thus providing a three-layer closure with a tight seal from the oral cavity. In addition, suspending the terminal sutures on a nearby tooth, taking the weight of the flap, provided a better healing.

Closure of the wound in three layers is very essential to create a series of barriers against salivary contamination from the oral cavity. The extraoral wound was then closed in layers using 3/0 vicryl sutures and the skin with subcuticular 4/0 Prolene sutures. Suction drainage was allowed for 2-3 days.

Adequate inter-arch space must be maintained to allow for proper insertion of Osseo-integrated dental implants or removable prosthesis. The reconstruction plates were planned to be removed 6 months postoperatively after the intake and consolidation of the bundle rib graft.

On completion of surgery, the patients were transferred, in a stable condition, to the Pediatric Intensive Care Unit for 24 h for observation. Na-

sogastric tubes (NG) were inserted and applied for all patients to allow for enteral feeding for 1 week post-operatively to guard against any salivary leak through the intraoral sutures. Antibiotics were prescribed and continued for 2 weeks post-operatively. A chest radiograph was obtained post-operatively to monitor for pneumothorax.

Significant psychological damage usually occurs in pediatric patients secondary to losing part of their body anatomy with the face being most affected. Accordingly, the need for psychosocial therapy for all patients was considered after completion of surgical intervention.

Patients to whom hemimandibulectomy involved the condylar segment and accordingly required costochondral grafting were instructed to commence passive physiotherapy mouth opening exercises starting at the Tenth postoperative day and continuing for at least 30 days. The physiotherapy was first performed with passive exercises of mouth opening and closing plus lateral excursion of the mandible, repeated three times a day in a series of 30 movements each.

After about one month of passive physiotherapy, if there was any residual mouth-opening restriction, active exercises were used with the interposition of wooden tongue depressor spatulas inserted between the central incisors one by one making the mouth open slowly, gradually increasing the number of spatulas each day. This active exercise was performed until the patient achieved an accepted near normal unassisted mouth opening of at least 35–40 mm. Active exercises were continued for 6 months until a normal range of mandibular movements was attained.

Dental Rehabilitation by insertion of endosseous implants

Meanwhile, approaching the end of the follow up period, most patients had passed 18 years of age where craniofacial growth had completed thus enabling rehabilitation by osseo-integrated implants.

In all uncomplicated patients, after 12 months of successful reconstruction and following removal of reconstruction plates by 6 months, Osseo-integrated dental implant rehabilitation was planned in the mandibular reconstructed edentulous areas after evaluation of the systemic and dental conditions of the patients.

Diagnostic casts were made and CBCTs were taken to evaluate the bone volume of the SRBBG reconstructed edentulous areas. In cases where the existing bone width and height were still sufficient to accommodate the implants, insertion of implant fixtures utilizing the two-stage surgical protocol was performed. A surgical template was fabricated to ensure proper implant position and angulation. Meanwhile, the surgically treated and augmented complicated cases received either endosseous implants or removable partial dentures again 12 months after their surgical cure.

Implant Loading

Six months after implant placement and when it was ascertained radiographically and clinically that osseointegration had taken place, second stage surgery was performed and indirect transfer analogues were placed after removing the cover screws. Impressions were made using the two-stage technique in sectional trays as mouth opening was slightly reduced due to post-surgical graft contracture.

Patients were clinically reviewed immediately postoperatively, then weekly till the second postoperative month, monthly till the second year and then every 3 months for the rest of the follow-up period for 4-7 years. Radiographic follow up of patients by O.P.Gs and C.Ts (when indicated) was performed immediately postoperatively then scheduled as every 3 months for the first 2 years, then on yearly basis throughout the remainder of the follow-up period for 4-7 years. (Fig. 6,7).

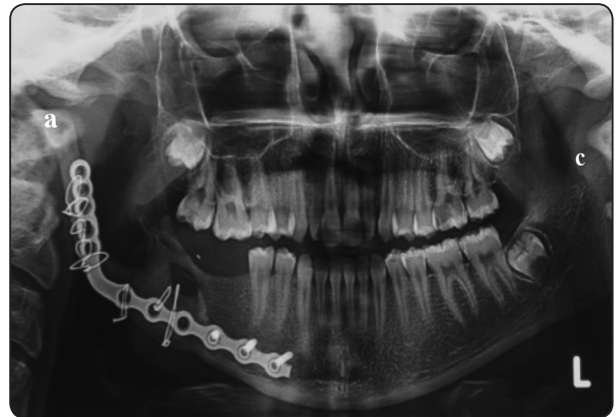

Fig. (6): Odontogenic Myxoma of the right mandibular body, angle and ramus only sparing the condyle. One year after reconstruction

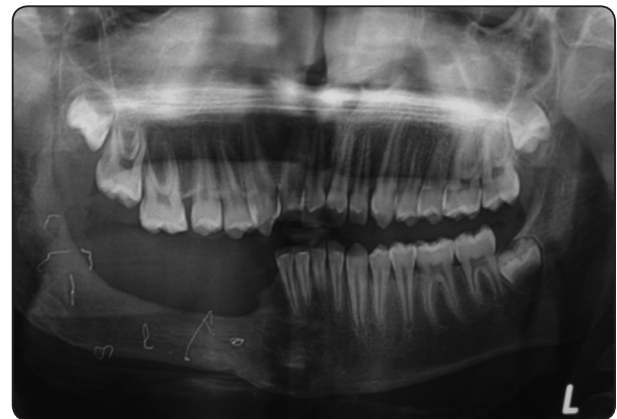


Fig. (7): Three years after reconstruction and 6 months after removal of the reconstruction plate.

Outcomes of reconstruction were assessed based on the following three parameters: mouth opening, success of dental rehabilitation in terms of patient satisfaction, and rate of occurrence of postoperative complications.

The success of reconstruction was assessed at the first, third, sixth and twelve months postoperatively by interincisal mouth opening and by the rate of occurrence of complications like infection, wound dehiscence and exposure of the graft, rejection of the graft, intra or extra-oral sinuses, plate fracture and donor site infection.

Mouth opening was assessed by measuring the maximum unassisted interincisal opening in mm using a polygauge after 1, 3, 6 and 12 months of the surgical procedure and an interincisal distance of 35 mm or more was considered adequate.

Dental rehabilitation was performed six months after removal of the reconstruction plate with osseointegrated dental implants supporting a fixed prosthesis, implant supported overdentures or removable partial dentures.

Success of dental rehabilitation was assessed in terms of patient satisfaction by verbal response scale after three months of dental rehabilitation. In a scale of 1 to 10 where the value of 5 or less was considered a failure (unsuccessful dental rehabilitation) while the value of 6 = bad, 7 = accepted, 8 = good, 9 = very good and 10 = excellent.

Criteria for success were reconstruction that did not require removal of the graft and placement of either osseointegrated dental implants supporting a fixed restoration, implant-retained overdentures or removable partial dentures. Data were analysed by Tukey's post hoc test which was used for pair wise comparison of different observations. The significance level was set at $p \leq 0.05$.

RESULTS

The study sample comprised a total of 61 pediatric mandibular tumors that were treated and followed during the period from January 2008 to December 2018. Thirty-five patients were treated at the Department of Cranio-Maxillo-Facial and Plastic Surgery, Faculty of Dentistry, Alexandria University, while twenty-six patients were treated at the Oral and Maxillofacial Surgery Department, Faculty of Dentistry, October 6 University, Egypt.

These patients comprised 37 males and 24 females, ranging in age from 2 to 16 years with a mean of 9.8 years with different benign aggressive mandibular tumors. They were followed up for a period of 4 to 7 years with a mean of 5.5 years.

Successful reconstruction was accomplished in 55 patients (90.16 %). Three patients had complete failure due to severe postoperative infection. Another three cases had partial resorption of the graft due to moderate infection to whom re-augmentation by another rib graft was performed after six months from the first operation. Two patients dropped out follow-up after 2 years while another 4 patients lost follow-up 3 years postoperatively. However, their loss did not alter statistical results as the measured parameters were recorded during the first year of follow up. No tumor recurrence or graft failure was encountered during the follow up periods for all other patients.

The Intraoperative duration ranged from three to four hours with a mean of 3 hours and 25 minutes. The total calculated surgical blood loss ranged from 250 to 400 ml. The duration of hospital stays for uncomplicated cases ranged from 4 to 6 days with a mean of 5 days, while for complicated cases (e.g., with severe infection) ranged from 8 to 15 days with a mean of 12 days.

In the post-operative period, no airway problems were encountered and patients made a gradual recovery. The potential risk of pneumothorax when harvesting the rib graft had not been encountered.

Forty nine patients had successful reconstruction with the SRBBG with adequate dental rehabilitation and facial esthetics (Fig. 8).

Criteria for success were reconstruction that did not require removal of the graft and placement of either osseointegrated dental implants supporting a fixed restoration, implant-retained overdentures or removable partial dentures, producing a total success rate of 89% (Fig. 9).

Statistical Analysis

Qualitative data were expressed as number and percentages. Microsoft Excel was used for generation of representative graphs. Quantitative data (inter-incisal opening) were presented as

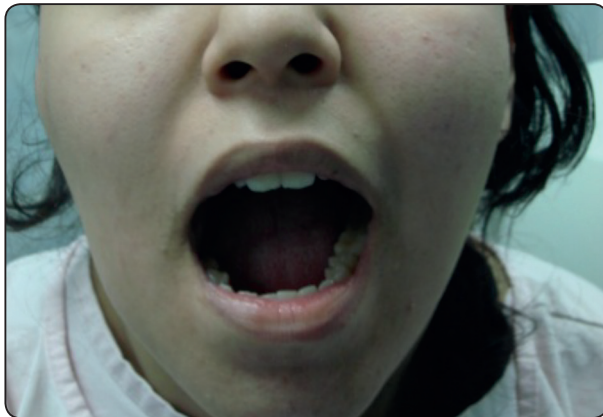

Fig. (8): five years after resection and immediate reconstruction by SRBBG.

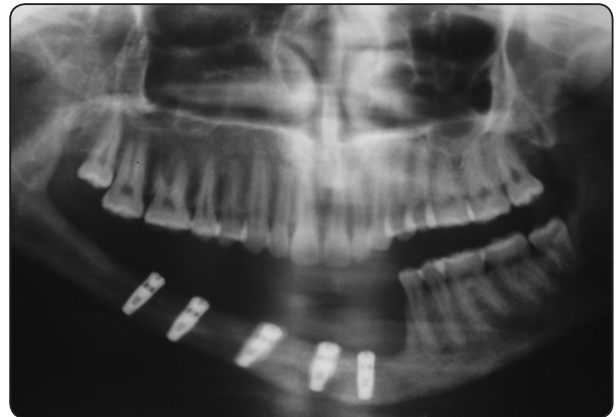


Fig. (9): 2 years post reconstruction panoramic view and 6 months after insertion of five Implant fixtures in another case.

mean and standard deviation. Repeated measures ANOVA test was used to compare values at different observation times. Tukey’s post hoc test was used for pair wise comparison of different observations. The significance level was set at $p \leq 0.05$.

Post-operative complications (Table 2)

Early onset post-operative complications (within the first week) were observed in 39.4% of the patients. These consisted of hematoma (18%), seroma (6.6%) and minor infection (14.8%)

TABLE (2): Post-operative complications

Onset post-operatively	Complication		No (%)	Total
Early (first week)	Hematoma		11 (18%)	24 (39.4%)
	Seroma		4 (6.6%)	
	Minor Infection		9 (14.8%)	
Intermediate (2-4 weeks)	Partial wound dehiscence intra-orally		8(13.1%)	39 (63.9%)
	Minor infections managed conservatively		7 (11.5%)	
	Infections needed incision & drainage		5 (8.2%)	
	Sinuses (extra- & intra-oral)		9 (14.8%)	
	Hypertrophic scars		7(11.5%)	
	Donor site infection		3 (4.9%)	
Late complications (> 4 weeks <12 months)	Exposure & Sequestration of the graft:	a. Minor (< 5%)	11(18%)	(65.6%) 40
		b. Moderate (5 to 25%)	7(11.5%)	
		c. Severe (25 to 50 %)	3(4.9%)	
		d. Total Loss of graft	3(4.9%)	
	Persistent cutaneous sinuses		3(4.9%)	
	Persistent mucosal sinus		2 (3.3%)	
	Low vertical height of the reconstructed mandible		9 (14.8%)	
	Fracture of reconstruction plate		3(4.7%)	

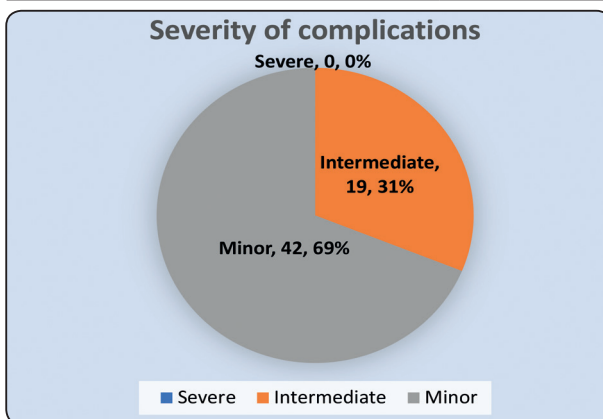
Intermediate onset post-operative complications (2-4 weeks postoperatively) were observed in 63.9% of the patients. These consisted of partial wound dehiscence intraorally (13.1%), minor infections managed conservatively (11.5%), infections needed incision and drainage (8.2%), extra-oral or intra-oral sinuses (14.8%), hypertrophic scars (11.5%) and donor site infection (4.9%).

Late onset post-operative complications (\geq 4 weeks - \leq 12 months postoperatively) were observed in 65.6% of the patients. These consisted of exposure and sequestration of graft (minor in 18% the patients, moderate in 11.5%, severe in 4.9% or total loss of graft in 4.9% of the patients). Other late complications included persistent cutaneous sinuses (4.9%), persistent mucosal sinus (3.3%), low vertical height of the reconstructed mandible (14.8%) and fracture of reconstruction plate (3.3%).

According to severity, these complications were classified as minor (68.86%) with no prolongation of hospital stay or intermediate (31.14%) requiring prolonged hospital stay. Severe life-threatening complications were almost absent (Table 3 Diagram 1)

TABLE (3) Complications According to the severity

Complication	No. of Patients
Severe (life-threatening)	nil
Intermediate (prolonged hospital stays)	19 (31.14%)
Minor (no prolongation of hospital stays)	42 (68.86%)

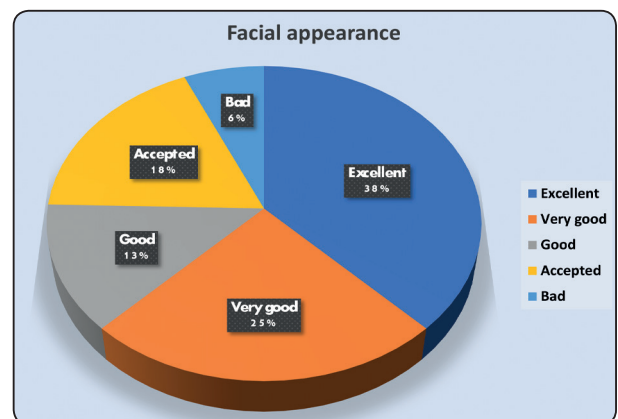


Diag. 1 Pie chart illustrating severity of post-operative complications.

Regarding facial appearance and dental rehabilitation, it was classified as excellent (37.7%), very good (24.6%), good (13.1%), accepted (18%) or bad (6.6%), (Table 4, Diagram 2, Fig. 8,9)

TABLE(4): Facial appearance and dental rehabilitation

Facial appearance	No. of Patients (%)
Excellent	23 (37.7%)
Very good	15 (24.6%)
Good	8 (13.1%)
Accepted	11 (18%)
Bad	4 (6.6%)



Diag. 2 Pie chart illustrating the evaluation of the post-operative facial appearance

Methods of dental and surgical rehabilitation

A total of 49 (80.3%) of the patients received dental rehabilitation. These consisted of partial denture (19.7%), osseointegrated dental implants (47.5%) and implant supported over denture (13.1%). A total of 12 (19.7%) of the patients received surgical rehabilitation. These consisted of Vestibuloplasty (14.8%) and augmentation by adding another rib graft (4.9%), (Table 5, Diagram 3)

The interincisal opening gradually increased by time from 24.6 \pm 6.7 at one month, to reach 43.3 \pm 8.7 after 12 months. ANOVA test revealed

TABLE (5): Methods of Dental and Surgical Rehabilitation

	Method of Rehabilitation	No. of Patients (%)	Total
Dental	Partial Denture	12 (19.7%)	49 (80.3%)
	Osseo-integrated dental implants	29 (47.5%)	
	Implant-supported overdenture	8(13.1%)	
Surgical	Vestibuloplasty	9(14.8%)	12 (19.7%)
	Augmentation by adding another rib graft	3 (4.9%)	

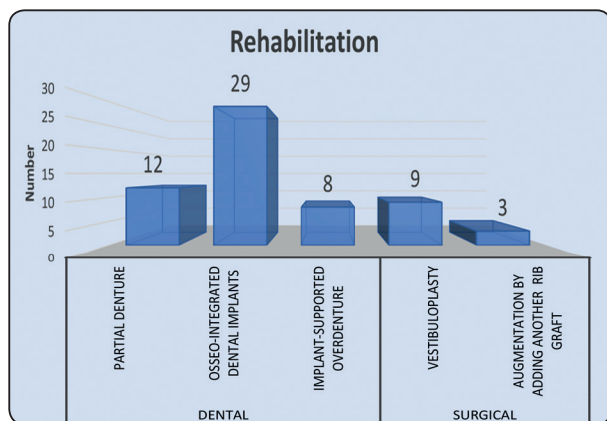
TABLE (6): Descriptive statistics and comparison of Interincisal opening (mm) at different observation times (repeated measures ANOVA)

Interincisal opening (mm)				
Time	One month	months 3	months 6	months 12
Mean±SD	24.6±6.7	38.7±7.42	41.9±8.9	43.3±8.7
F	13.8			
P	0.00*			

Significance level was set at $p \leq 0.05$.

Tukey's post hoc test: means sharing the same superscript letter are not significantly different.

that the difference was statistically significant ($p=0.00$). Tukey's post hoc test revealed no significant difference between values at 3 and 6 months. Moreover, the values at 6 and 12 months were not significantly different (Table 6)



Diag. 3 Bar chart illustrating the dental and surgical rehabilitation received by the patients.

DISCUSSION

Pathologic processes of the oral and maxillofacial region are universally classified as benign or malignant according to specific histologic criteria, including the presence or absence of necrosis, mitotic figures as well as other associated dysplastic changes [15].

However, the oral and maxillofacial region is the site of many benign although locally aggressive tumors that can produce significant anatomic destruction, deformation with resultant loss of function [1,3,6].

Locally, aggressive benign tumors are often distinguished from their malignant counterparts by their lack of skin invasion, lack of epineural infiltration and although their aggressive behaviour, they demonstrate a slow destructive growth. However, in some cases, many benign tumors of the oral and maxillofacial region can be more aggressive,

destructive, and deforming than some malignant tumors, in spite of their slower growth potential. Histopathologically, benign lesions sometimes exhibit local aggressive behaviour, and lesions with benign clinical appearance may be malignant [1-3].

Susmita *et al.* [12] in their retrospective study on 61 pediatric patients below 18 years of age reported that Aggressive Pediatric jaw tumors and tumor-like lesions included Ameloblastoma, Ameloblastic fibroma, Aneurysmal bone cysts, ossifying fibroma and central giant cell granuloma which was in accordance with aggressive tumors and lesions selected in our study. Carlson *et al.* [16] added odontogenic Myxoma, desmoplastic fibroma, eosinophilic granuloma and Langerhans cell histiocytosis to the aggressive benign tumors and tumor like lesions.

Carlson *et al.* [16] postulated that the surgical techniques for locally aggressive benign processes of the oral and maxillofacial region are dictated by the biologic behaviour of the lesion. He stated that because tumors extend beyond their clinical and radiographic margins, the surgical specimen should include quantifiably uninvolved soft and hard tissues around the tumor specimen [16, 17].

Accordingly, in our study, tumor radical surgical treatment was based on their biologic and clinical behavior rather than on their histopathologic picture. Thus, the resected segment included 1-1.5 cm of normal bone or 1 dental unit beyond the radiographic margin of the tumor.

Jaw tumors in children are relatively uncommon. The exact incidence is hard to estimate owing to the different tumor types and sites included in various studies and the differing definitions used by authors to define the pediatric age group [18]. The most common diagnosis in our series was Ameloblastoma and JOF which were also the most common tumors in similar studies [15-17, 19, 20].

Tanaka *et al.* [21] reported that pediatric tumors occur most frequently in the 6-11-years age group (43.8%), followed by the 12-15-years age group (31.4%). In a 102-patient series, they reported that

28 of 33 odontogenic tumors were in the 6-11 years age group. A number of other researchers have reported higher incidences of tumor in the 11-15 years age groups [22-24].

In the present study, we are in agreement with the literature, where maxillofacial tumors occurred most frequently at 9 - 16 years of age (73%).

In various studies on tumors, the mandible was reported to be the most frequently affected area [20, 21]. Our study was conducted therefore on aggressive mandibular tumors.

The great majority of pediatric jaw tumors in our series were odontogenic accounting for 60.7% of presented cases. However, these findings are in disagreement with those of Choung and Kaban [25] who reported one ameloblastoma and one odontoma as opposed to 47 non-odontogenic tumors. In a 46-patient series assessing benign jaw tumors, Dehner [26] found only four odontogenic tumors. In contrast, our study is in accordance with Ortega *et al.* [2] who stated that tumors of odontogenic origin predominate in a series of 362 pediatric tumors.

The importance of complete surgical excision with negative margins offers a chance for cure but presents many challenges in the pediatric population. In children with large tumors, this may mean removal of a significant portion of the mandible, with resultant functional and cosmetic complications. In our study population, most children underwent a subtotal or hemimandibulectomy for adequate control of the disease.

Specific challenges that are of utmost importance in the pediatric population include consideration of facial and mandibular growth over time, involvement of the permanent dentition, airway management and compromise, facial symmetry with facial nerve preservation, and donor site morbidity if reconstruction is required [6, 7].

The advantages of primary reconstruction include restoration of oral function and maintenance of mandibular continuity thus preventing the patient

from developing collapse of airway. Furthermore, there are improved cosmetic results that provide additional psychological advantages^[27].

The ultimate goal of mandibular reconstruction should not be considered, the restoration of mandibular continuity per se. Since the counterstone of mandibular reconstruction is permitting patients to regain previous normal functions of chewing, swallowing, speech, articulation, and oral competence. Accordingly, the reconstructive surgeon must also plan to restore an acceptable facial contour and perform any plan to restore sensation to the denervated areas^[14,28,29].

Rehabilitation by removable and fixed partial dentures following reconstruction had raised our patient's satisfaction as their function, esthetics and speech had improved markedly. Implants were inserted when facial growth had completed. All implants showed success till the end of the study. These findings are in agreement with other authors^[30,31].

However, patients who exhibited late dental rehabilitation (9 patients 14.8%) had suffered some graft resorption and subsequently inadequate vertical ridge height and so became candidates for secondary intraoral Vestibuloplasty under local anesthesia.

In general, a high primary stability was achieved for implants placed into the non-vascularized split rib bundle bone graft. Implants placed were successfully osseointegrated. Successful functional loading of implants had resulted in a high patient satisfaction (89%).

These results correlate well with those of Ashraf *et al.*^[32] in their retrospective study on 40 pediatric patients ranged in age from 2 to 15 years to whom resection of odontogenic and nonodontogenic tumors together with primary reconstruction with non-vascularised iliac crest bone grafts was performed followed by rehabilitation by successfully integrated and loaded dental implants^[32].

Ribs have often been used as free non-vascularised grafts^[4,7,10,11] and, in recent years also as pedicled and free revascularized flaps^[18,28-36]. Such grafts may be either osseous, cartilaginous, or a combination of the two as a costochondral graft (CCG).

Autogenous CCGs were conventionally utilized as a source of non-vascularized free bone grafts for the reconstruction of the mandibular and maxillary defects in adults and children with severe grades of deformity secondary to tumor ablation as well as following freeing of ankylosed joints. The graft contains a "growth center" at the costochondral junction thus promoting mandibular growth. The advantages of this graft are its biological compatibility, workability, functional adaptability, and minimal additional morbidity to the patient. The growth potential of the CCG renders it the ideal choice for children due to the ability of the rib to grow in coordination with the child's growth^[37].

In our study, 27 patients (44.2%) had resection involving the mandibular condyle which entailed joint reconstruction by costochondral grafts. The interincisal opening, therefore, was statistically significantly lower at the first postoperative month (24.6) compared to measures at the 6 and 12 months. However, it gradually increased at the third and sixth months after passive and active mouth opening exercises which had been programmed in order to achieve an accepted, near normal range of unassisted mouth opening as well as normal mandibular protrusive and lateral movements.

Mandibular reconstruction by split rib bundle bone graft had been used since, 1992^[7] for reconstructing various mandibular defects as a primary or secondary reconstructive method with very successful and predictable outcomes. Splitting of ribs exposing the cancellous bone interface helps early revascularization, lessen the extent of graft resorption, and resist or decrease the sequelae of infection. Moreover, this maneuver can help restoring the width, length and vertical height of the defect which would encourage and facilitate proper

rehabilitation by permitting the insertion of Osseo-integrated dental implants or removable prosthesis. This technique had proved to be rapid and safe, with few donor site morbidities when done by experienced hands^[7,10,11,18,37].

Kamat *et al.*^[38] in 2001 splitted a rib into 3 or 4 segments which were held and secured together using 3.5 mm bicortical screws thus converting this laminated multisegmented rib grafts into a single robust rib graft construct that was easily trimmed, manipulated and anchored to reconstruct an anterior spinal column defect after tumor ablation providing a biological strong bony construct restoring column stability.

The current study is in accordance with El Sheikh *et al.*^[7], as they had postulated that the key in this technique was not to use a natural rib segment per se but to split and reverse the ribs which helped early vascularization and graft consolidation. They reported that ribs were malleable and can be pressed and mounted into the desired shape and configuration without breaking or cracking. As quite frequently happens, if a small portion of the graft becomes exposed to the oral environment with subsequent infection, only a small portion of the rib graft will be lost while the main graft survives and will not be endangered or affected.

Regarding our postoperative infections; when mild it was managed by early antibiotics, drainage, if necessary, and proper wound care. In all cases the graft was saved and the infection was controlled with the need for removal of transosseous wires or plates and screws after graft consolidation, usually after 6 to 12 months. At that time minimal sequestrectomy was needed.

Moderate infections, however, were managed by early sequestrectomy, culture and AB sensitivity tests, prescription of specific antibiotics, proper drainage, fistulas excision and wound care resulting in saving most of the graft bulk.

On the other hand, severe postoperative infections; inspite of early surgical drainage and proper

wound care, led to near total loss of the graft in only 3 patients. These patients were treated by repeated reconstruction by rib grafting with very good outcomes ending in an overall success rate of 91.16%.

Pogrel *et al.*^[4] and Mehrotra *et al.*^[10] reported in their studies complications as unpredictable growth of the CCG, non-union, graft ankylosis or severe limitation of mouth opening together with malocclusion^[4,10]. Fortunately, these complications had not been encountered in our study.

Plate fracture occurred in 3 patients (4.7%) most probably in those cases that had deferred dental rehabilitation for 2 years or more either due to financial reasons or because they had not completed facial growth yet or in patients where mini plates were used instead of the heavy 2.4 or 2.7 reconstruction plates.

The results achieved in our study correlates with those of Patel *et al.*^[11] in 2016 who treated 14 patients with mandibular Ameloblastoma by resection and immediate reconstruction by autologous rib grafts. They reported a complication of postoperative infection at the grafted site encountered in four patients and at the donor site in one patient. However, they reported successful management of infected sites by repeated wound debridement and oral antibiotics with resultant good final functional and aesthetic outcomes for their patients^[11].

Patient's satisfaction in our study was high (37.7% excellent, and 24.5 % very good ,13.3 % good); a total of 75.5% of patients were satisfied. Only 13.1 % had accepted reconstruction, and 6.5% had bad reconstruction. These results are in accordance with the 83% success rate achieved by Mehrotra *et al.*^[10] in 2009 in a study series including 52 consequent subjects of immediate reconstruction after tumour resection using non-vascularised grafts, in whom successful rehabilitation by dental implants and overdentures had been achieved^[10].

The results achieved in the present study perfectly matches the results of the study performed by Waseem *et al.*^[33] in 2018 who reconstructed

mandibular and maxillary continuity defects by rib graft in 11 patients and CCG in 3 patients and yielded a reconstructive success rate of 86.7% and accordingly postulated that Non-vascularized rib bone grafts can be used successfully for reconstruction of maxillofacial bony defects.

Nowadays, Microvascular surgery with vascularised free flaps is considered the preferred surgical technique for reconstruction of maxillofacial bony defects as the maintained blood flow provides relative resistance to infection and resorption. However, such procedures require well-trained microvascular surgeons, long operating hours and general anaesthesia, longer hospital stay and a high cost [8,27-30].

In comparison with microvascular reconstruction, the SRBBG technique doesn't need special microvascular surgical skills and training, does not require advanced instrumentations or special facilities as pediatric intensive care units, the operative time and hospital stay are much shorter with decreased intra- and post-operative donor side morbidities [4,28]. Moreover, the SRBBG technique is much less costly than the Free flap microvascular techniques^[4].

In addition, pediatric patients can be medically brittle and thus have little physiologic reserve to achieve the medical strength required to admit for a long operation. Moreover, their body anatomy is smaller than adults making vascular anastomosis and flap inset technically challenging. Mandibular growth and development, airway management, and donor site morbidity are all potential difficulties in this type of reconstruction [4,8,9,28].

The rib graft harvest procedure is generally well-tolerated by patients. The complications of rib graft harvest are most commonly pain, chest wall deformity, clicking of the ribs, and donor site scar. Pleural perforation with resultant pneumothorax and wound infection are less frequent [4,8,28-30]. However, any of these complications had not been encountered in our case series. Postoperative pain persisted usually for 7 days, then resolved slowly. Hypertrophic

scars occurred only in 7 patients (11.5%) to whom simple plastic correction had been performed under local anesthesia. Accordingly, harvesting a rib graft proved to be a logical, feasible, reliable and risk limited surgery as it spared essential bones and presented less risk than a microvascular graft. Moreover; it can be used at different ages; children, adults, and elderly [7,9-11, 18,37].

The graft harvesting procedure is simple for a surgeon who is familiar with thoracic approaches, but can appear difficult to one who is not. The lack of experience with thoracic approaches curtails the use of this graft.

Finally, and briefly, Microvascular reconstruction is considered the gold standard method for immediate mandibular reconstruction, however, this is not always a convenient, possible and feasible option specially in the pediatric population. In persistence of such a situation, an alternative can be the use of autologous rib grafting. However, in recent years, this technique has seen significant reduction to almost non-existent for mandibular reconstruction.

This article reconceives and evaluates autologous rib grafting through a case series and defines the technique and demonstrates the advantages it provides especially when operating in rudimentary primitive conditions.

CONCLUSION

Aggressive pediatric mandibular tumors, should be treated in an aggressive manner and immediate reconstruction is advocated.

The Split Rib Bundle Bone Graft Technique is an adequate alternative for immediate mandibular reconstruction as it represents a simple, easy, less costly, and reliable method for restoring mandible continuity defects demonstrating early revascularization associated with three-dimensional reconstruction of the resected bony segment thus permitting rehabilitation with successfully osseointegrated dental implants.

Although free rib grafts have largely fallen from modern practice, they had given a reliable and trusted service over the years. They still have a small but important place in a surgeon's armamentarium. The technique should not be lost to posterity and in striding surgeons should always gaze back to retain old skills and nearly neglected techniques and should retain lesson learnt in the past.

Disclosure of interest

The authors declare that they have no competing interest.

REFERENCES

- Mercado FM. Aggressive tumors in pediatric patients. *Rev Odon Mex* 2016; 20: 125-31.
- Ortega A, Ochsenius G, Godoy L, Penafiel C, Escobar E. Odontogenic tumors in Chile: a study of 362 cases. *J Oral Pathol Med* 2002; 31:415-20.
- Paris M. Differential diagnosis of jaw tumors in infants. *Journal of Oral and Maxillofacial Surg* 2008; 66(8): 130-31.
- Pogrel AM, Podlesh S, Anthony JP. A comparison of vascularized and nonvascularized bone grafts for reconstructing mandibular continuity defects. *J Oral Maxillofac Surg* 1997; 55:1200-6.
- Braimah RO, Ibikunle AA, Abubakar U, Taiwo AO, Obo-irien M, Adejobi FA, et al. Mandibular reconstruction with autogenous non-vascularized bone graft. *Afr Health Sci* 2019; 19:2768-77.
- Benoit MM, Vargas SO, Bhattacharyya N, McGill TA, Robson CD, Ferraro N, et al. The Presentation and Management of Mandibular Tumors in the Pediatric Population. *Laryngoscope* 2013; 123:2035-42.
- El-Skeikh, MM, Zyatoun, IM, Medra AM. Split Rib Bundle Bone Graft in Mandibular Reconstruction. *J Cranio-Maxillofac Surg* 1992; 20:326-32.
- Guo L, Ferraro NF, Padwa BL, Kaban LB, Upton J. Vascularized fibular graft for pediatric mandibular reconstruction. *Plast Reconstr Surg* 2008; 121:2095-105.
- Chawla R, Ramalingam K, Sarkar A, Muddiah S. Ninety-one cases of ameloblastoma in an Indian population: a comprehensive review. *J Nat Sci Biol Med* 2013; 4:310-15.
- Mehrotra D, Kumar S, Pradhan R. Mandibular reconstruction after resection of benign tumours using non-vascularised methods in a series of patients that did not undergo radiotherapy. *Oral Surgery* 2009; 2:10-8.
- Patel V, Jenkinson A, Smith G, McGurk M. Near-total mandibular reconstruction in the absence of microvascular grafts. *Oral Surgery* 2016; 9:215-21.
- Susmita S, Sanjeev K, Siddharth P. Pediatric Jaw Tumors: Our Experience. *Journal of Oral and Maxillofac Path* 2012;16: 27-9.
- McCarthy EF. Fibro-osseous lesions of the maxillofacial bones. *Head Neck Pathol* 2013; 7:5-10.
- Goh BT, Lee S, Tideman H, Stoelinga PJW. Mandible reconstruction in adults: a review. *Int. J. Oral Maxillofac Surg* 2008; 37: 597-605.
- Caccamese JF, Yang R, Ord RA. Jaw Tumors in Infancy and Childhood, Management. In: Kountakis SE, editor. *Encyclopedia of Otolaryngology, Head and Neck Surgery*. Springer, Berlin, Heidelberg;2013, p.
- Carlson ER, August M, Ruggiero SL. Locally Aggressive Benign Processes of the Oral and Maxillofacial Region. *SROMS: VOL 12.3; 1-52*
- Perry KS, Tkaczuk AT, Caccamese JF, Ord RA, Pereira KD. Tumors of the Pediatric Maxillofacial Skeleton A 20-Year Clinical Study. *Otolaryngol Head Neck Surg* 2015;141(1):40-4.
- Simon EN, Merx MA, Shubi FM, Kalyanayama BM, Stoelinga PJ. Reconstruction of the mandible after ablative surgery for the treatment of aggressive, benign odontogenic tumours in Tanzania; a preliminary study. *Int J Oral Maxillofac Surg* 2006; 35:421-6.
- Aregbesola SB, Ugboko VI, Akinwande JA, Arole GF, Fagade OO. Orofacial tumours in suburban Nigerian children and adolescents. *Br J Oral Maxillofac Surg* 2005;43(3):226-31.
- Sato M, Tanaka N, Sato T, Amagasa T. Oral and maxillofacial tumours in children: a review. *Br J Oral Maxillofac Surg* 1997;35(2):92-5.
- Tanaka N, Murata A, Yamaguchi A, Kohama G. Clinical features and management of oral maxillofacial tumors in children. *Oral Surg Oral Med Oral Pathol* 1999; 88: 11-5.
- Arotiba GT. A study of orofacial tumors in Nigerian children. *J Oral Maxillofac Surg* 1996; 54: 34-8.

23. Günhan O, Erseven G, Ruacan S. Odontogenic tumours: a series of 409 cases. *Aust Dent J* 1990; 35: 518-22.
24. Chen YK, Lin LM, Huang HC. A retrospective study of oral and maxillofacial biopsy lesions in a pediatric population from southern Taiwan. *Pediatr Dent* 1998; 20: 404-10.
25. Choung R, Kaban L.B. Diagnosis and treatment of jaw tumours in children. *J Oral Maxillofac Surg* 1985; 43: 323-32.
26. Dehner LP. Tumors of mandibula and maxilla in children. 1. A Clinicopathologic study of 46 histologically benign lesions. *Cancer* 1973; 31: 364-84.
27. Hartman HM, Spauwen PHM, Jansen JA. Donor-site complications in vascularized bone flap surgery. *J Invest Surg* 2002; 15: 185-97.
28. Hidalgo DA, Pusic AL. Free-flap mandible reconstruction: A 10-year follow-up study. *Plast Reconstr Surg* 2002; 110: 438-49.
29. Urken ML, Buchbinder D, Weinberg H. Functional evaluation following micro-vascular oromandibular reconstruction of the oral cancer patient: a comparative study of reconstructed and non-reconstructed patients. *Laryngoscope* 1991; 101:935-50.
30. Tetsu T, Akahashi T, Inai T, Kochi M, Fukuda T, Yamaguchi K, et al. Long-term follow-up of dental implants placed in a grafted alveolar cleft: evaluation of alveolar bone height. *Oral Med Oral Pathol Oral Radiol Endod* 2008; 105:297-302.
31. Fudale P, Kokich VG, Leroux B. Determining the cessation of vertical growth of the craniofacial structures to facilitate placement of single-tooth implants. *Am J Orthod Dentofacial Orthop* 2007;131: S59-67.
32. Mahmoud AA, Farag MS. Management of pediatric maxillofacial tumors: A retrospective analysis and long-term follow-up outcomes. *Journal of American Science*, 2011;7(12):1044-52.
33. Waseem A, Muhammad AA, Afeefa E, Qalab A. Non-Vascularized Autogenous Bone Grafts for Reconstruction of Maxillofacial Osseous Defects. *Journal of the College of Physicians and Surgeons Pakistan* 2018; 28 (1): 17-21.
34. Fatma F B, Mark M, Axel R, Donald C, Barton R.B, Madhu K N. Long-standing chin-augmenting costochondral graft creating a diagnostic challenge: A case report and literature review. *Imaging Science in Dentistry* 2016; 46: 279-84.
35. Spiker AM, Humbyrd CJ, Osgood GM, Yang SC, Deune SG. Reconstruction of Ulnar Defect with Vascularized Rib Graft: A Case Report. *Microsurgery* 2017; 37: 160-164.
36. Aydinli U, Akin S, Tirelioglu O, Ozturk C, Yalcinkaya U, Sadekoglu U. A new autogenous graft choice in pelvic reconstructions: free vascularized rib (A case report) *Arch Orthop Trauma Surg* 2006; 126: 57-62.
37. Emodi O, Israel Y, Almos ME, Aizenbud D, Van Aalst JA, Rachmiel A Three-dimensional Planning and Reconstruction of the Mandible in Children with Craniofacial Microsomia Type III Using Costochondral Grafts. *Annals of Maxillofacial Surgery* 2017; 22: 65-72.
38. Kamat AS, Freeman BJ, Cain CMJ, Hall DJ. Laminated Multisegment Rib Graft in anterior column reconstruction. *Eur Spine J* 2001;11: 465-66.