

Dept. of Anatomy
Fac. Vet. Med., South Valley University.

**ANATOMICAL STUDIES ON THE UPPER CHEEK
TEETH AND THEIR RELATION WITH MAXILLARY
SINUS IN POSTNATAL DONKEYS**
(With 3 Tables & 20 Figs.)

By
SALMA A. MOHAMED
(Received at 18/6/2000)

دراسات تشريحية على الأسنان الشدقية العلوية وعلاقتها بالجيب الفكى العلوى
فى الحمير بعد الولادة

سلمى أحمد محمد

أوضحت الدراسة أن جذور الأسنان الشدقية العلوية المؤقتة والدائمة فى الحيوانات الصغيرة تكون مفتوحة ولها شكل شبه اسطوانى . يتقدم العمر يصبح الثقب القمى ضيق ولا يمكن تميزه فى الحيوانات كبيرة السن . أظهرت الدراسة أن السن الشدقي العلوي يبدأ ببرعم قصير يشغل معظمه بقناتين واسعتين . تنتهى كل قناة عند طرف البرعم بفتحه . يتقدم العمر يزداد سمك البرعم بالتالى تضيق القناتان وفتحاتهم . ثم تقفل الفتحات . تمثل القناتان الأقماع الممتمتلة . تحتوى الأسنان الشدقية المؤقتة والدائمة على قمعين . وجود وحجم القمعين يختلف فى الأعمار المختلفة . كما بينت الدراسة أن هناك علاقة بين تطور الأسنان الشدقية العليا والجيب الفكى العلوى من ناحية وموقع القناة تحت الحاجية من ناحية أخرى . يعتمد عدد المناطق الأسمتية للسطح الطباقى على عمر الحمار . وبصفة عامة أوضح البحث أن الصفات المورفولوجية للسن القبطان الثانى فى كلا الأسنان الشدقية المؤقتة والدائمة تختلف عن باقى الأسنان . أثبتت الدراسة القياسية أن السن القبطان الرابع أطول الأسنان الشدقية الدائمة بين عمر ٤ و ١٥ سنة ويليه السن القبطان الثالث . ابتداء من العام الرابع لعمر الحيوان تزداد نسبة طول الجذر الى الجسم بتقدم العمر . تمثل أجسام الأسنان الشدقية فى الحمير كبيرة السن بتيجان ظاهرة .

SUMMARY

In the young animals the roots of the deciduous and permanent upper cheek teeth are opened and semicylindrical in shape. As the animals advance in age the apical foramen becomes narrow, till it could not be distinguished in older ones. The upper cheek tooth begins as short bud which is occupied mostly by two wide canals separating by thin septum. Every canal terminates at each bud end by an opening. With advancing age the bud increases in size, the canals and their openings become narrow. Then after the openings are closed. These canals represent the future infundibula. The deciduous and permanent upper cheek teeth contain two infundibula. The presence and size of the infundibula vary in the different ages. There is a relation between the postnatal development of the upper cheek teeth and the maxillary sinus on one hand and the position of the infraorbital canal on the other hand. The number of the cement areas on the occlusal surface depends upon the age of the donkey. In general the morphological features of P2 in the deciduous and permanent cheek teeth differs than that of the other teeth. The morphometrical study indicates that P4 is the longest permanent upper cheek teeth in the period from 4 to 15 years old, it is followed by P3. Up to 4 years old the ratio between the length of the root and the corresponding body increases with advancing age. In the old donkeys the bodies of the cheek teeth are represented by exposed crowns.

Key words: Upper cheek teeth in postnatal donkeys.

INTRODUCTION

The teeth are the principal organs of mastication (Nickel, Schummer and Seiferle, 1973). Equine practitioners should be knowledgeable of dental anatomy (Lowder and Mueller, 1998). Extensive studies had been done on the anatomy of the teeth of the horse (Berg, 1973; Bone, 1979; Delahunta and Habel, 1986 as well as Milles and Grigson, 1990). Yet few informations were recorded concerning the teeth in donkey. Therefore, the aim of this investigation is to give more informations about the morphological features of the deciduous and permanent upper cheek teeth of the latter animal in the postnatal period. In addition to throw a light on the relation of these teeth with the

maxillary sinus and the infraorbital canal, also to determine different measurements on the upper cheek teeth during this developmental period.

MATERIAL and METHODS

This study was conducted on the upper cheek teeth of forty upper jaws of donkeys (*Equus asinus*) which were of both sexes and aged from 1.5 months to 15 years old. Lateromedial radiographs of the upper jaws were made. The relation of the upper cheek teeth with the maxillary sinus and the infraorbital canal was studied. Then the teeth were removed to describe the morphological features concerning with the buccal, lingual, contact and occlusal surfaces as well as the roots. The different measurements of the upper cheek teeth were obtained using Precision Digital Verner Caliper. The thickness and breadth were measured only at the middle in case of the buds

RESULTS

Morphological observations:

At 1.5 months of age the upper cheek teeth (Fig 1) are represented by three deciduous premolars (P2, P3, P4) and the bud of the first molar (M1). The premolars have large bodies and three short roots, two lateral and one medial. The rostral lateral root is the longest followed by the caudal lateral then the medial one which is the broadest. The roots are generally directed dorsally and incline somewhat rostrally, caudally and medially respectively. They are opened and semicylindrical in shape.

The buccal surface of the deciduous premolars except P2 has two longitudinal ridges (Fig.1). The rostral ridge extends to the rostral lateral root, while the caudal one extends to the caudal lateral root. The ridges are alternated by two shallow grooves. P2 has also two ridges dividing the buccal surface into three shallow grooves. The lingual surface of the premolars except P2 has a large longitudinal column which extends to the medial root. It separates two nearly equal depressions, rostral and caudal. P2 has two columns separating three depressions. The contact surfaces are smooth and flat except the mesial contact surface of P2 is represented by narrow smooth edge

The occlusal surface of the deciduous premolars is rectangular but that of the P2 is triangular with its apex directed rostrally. This surface is uneven and contains two infundibula, rostral and caudal. The enamel crests of the infundibula are white in colour. In all premolars except P2 the occlusal surface contains 4 cement areas, 2 lateral and 2 medial. The rostromedial one is the largest. P2 contains an additional rostral cement area.

The first molar is represented by a relatively long, light and straight bud (Fig. 1). It is surrounded by thin outer and inner layers of enamel. The bud is occupied mostly by two canals extending along its length. Every canal terminates at each bud end by a wide opening (Fig. 2). The two canals are separated by a longitudinal thin septum. The buccal edge of the occlusal surface is blunt and higher than the lingual edge. The buccal surface of the bud contains three longitudinal ridges extend along its whole length and separate two shallow grooves. The lingual surface contains well distinct column. The ridges and column of the previous surfaces are formed due to the folding of the outer enamel layer. The contact surfaces are smooth, the distal one has longitudinal groove.

At 7 months of age the general arrangement of the upper cheek teeth is similar to the preceding age, moreover M2 is represented by a short bud. In addition, at 9 of months (Fig. 4) M1 begins to erupt and the bud of M2 is still nonerupted. At these ages the deciduous premolars become thicker, broader and the body shorter as well as the roots longer than at 1.5 months. The occlusal surface is characterized by three grooves separated by two transverse ridges. The middle groove is the deepest one. The buccal edge of the occlusal surface is slightly higher than the lingual edge.

At 9 months M1 becomes longer, heavier and curved along its length. The septum between the two canals is thick distally but is still thin proximally. The canals and their openings at the occlusal surface are narrow (Fig. 3) but at the apical end are relatively wide. The M2 bud is short and has the same morphological features of M1 bud at 1.5 months, except that the former bud is lighter and the openings of the canals are wider.

At 12 months the buds of the permanent premolars were demonstrated overlying the corresponding deciduous ones. The M2 bud becomes longer and heavier than the preceding age. The infundibula of

P4 and the rostral infundibulum of P3 are indistinct and represented by dark spots (Fig. 5). The rostral and the rostromedial cement areas are continuous with each other in P2. The occlusal surface of M1 does not completely erupted. It contains the beginning of two lateral cement areas, which are light brown in colour and slit like. The openings of the canals which are described in the previous ages are closed. These canals represent the future infundibula.

At 15 months the upper cheek teeth (Fig. 6) are represented by small sized deciduous premolars with relatively large overlying buds of their permanent teeth. In addition to long heavy M1 and just erupted M2. The body of the deciduous premolars becomes shorter than the previous ages (Fig. 7), therefore they are represented by a short exposed crown and a relatively long roots. The roots of the deciduous premolars are diverged due to the invagination of the corresponding permanent buds between them. Moreover, the apical ends of these roots are destroyed and the apical foramens could not be distinguished. The ridges, columns and grooves on the buccal and lingual surfaces of the premolars could not be observed.

The buccal and lingual edges of the occlusal surface of the deciduous premolars have nearly the same height. The transverse grooves are shallow. The occlusal surface of P2 contains only one infundibulum which is represented by dark spot. The cement areas become large and deep in all deciduous premolars except P2 where all the cement areas except the caudomedial one are continuous with each other. The M1 is long curved tooth. Its occlusal surface has two infundibula and five cement areas. The outline of the apical end is square in shape. The just erupted M2 has the same morphological characters as M1 at 12 months of age.

At 4 years of age (Fig. 8) the upper cheek teeth are permanent, they are long curved teeth with convexity directed laterally. They have a long body and very short roots except M3 remains without roots. There are three roots, two small lateral and one large medial. The roots are opened. The buccal surface of the permanent upper cheek teeth except P2 has two longitudinal ridges. The rostral ridge is longer and lies close to the mesial contact surface, while the caudal ridge is thicker and located at the middle of the buccal surface. Behind each ridge there is a shallow groove,

the rostral groove is wider than the caudal one. P2 contains three faint ridges followed by three grooves, the middle groove is the widest.

The lingual surface (Fig. 8) of all teeth except P2 has a broad longitudinal column which lies somewhat rostrally. It extends along the whole length of the tooth and separates two depressions. The rostral depression is wider than the caudal one. The lingual surface of P2 has two columns separated three depressions. The caudal column is the larger and the middle depression is the shortest. The contact surface is flat and smooth in all cheek teeth except the mesial contact surface of P2 is represented by narrow smooth edge, and the distal contact surface of M3 is grooved.

The occlusal surface (Fig. 9) is square in shape in all upper cheek teeth except in P2 is triangular and in M3 is trapezoid in shape. The surface is irregular, its buccal edge is slightly higher than the lingual edge. Both edges are blunt. There is transverse groove on the occlusal surface which is located opposite to the column of the lingual surface. This surface contains two nearly equal infundibula, rostral and caudal. The buccal edge has two eminences which represent the continuation of the ridges of the buccal surface. All cheek teeth (Fig. 9) except P2 has 5 cement areas, 2 medial and 2 lateral to the infundibula, in addition to the most medial one which lies nearly at the middle of the lingual edge. The cement area medial to the caudal infundibulum is bifurcated caudally. P2 has an additional small rostral area (Fig. 10), the cement areas of this tooth are slit like.

At 5 years of age the upper cheek teeth (Figs 11, 12) become shorter and the roots longer than that of the previous age. The caudal lateral root is closer to the medial root. The length of the roots increases in a rostral direction. A rostral root with a wide apical foramen begins to appear in the last molar. The buccal edge of the occlusal surface is sharp and prominent. The cement areas increase in size.

At 8 years of age the upper cheek teeth and their bodies are shorter than that of the preceding age. In the premolars the rostral lateral root is the longest, while in the molars the medial root is the longest. In the last molar the medial and the caudal lateral roots are partially united. The ridges of the buccal surface become faint, in addition the caudal ridge of the last tooth is absent. The groove behind the caudal ridge becomes narrower. The lingual surface has faint column which separates two

shallow depressions in the premolars, while the caudal depression is absent in the molars.

The occlusal surface has larger and more distinct infundibula and cement areas. In P2 the two cement areas lateral to the infundibula are continuous with each other forming a large cement area separating the infundibula from the buccal edge. In the other cheek teeth the bifurcation of cement area medial to the caudal infundibulum could not be observed.

At 15 years of age the bodies of the upper cheek teeth are represented by exposed crown. The medial root is the longest and broadest root in all cheek teeth except P2 where the rostral root is the longest one. The ridges, grooves and columns of the buccal and lingual surfaces could not be demonstrated. The occlusal surface of the molars is nearly even due to the disappearance of the cement areas and infundibula which are replaced by smooth grayish coloured area. The slope between the buccal and lingual edges of the occlusal surface could not be observed. The occlusal surface of M3 is oblique rostrocaudally. The irregularity of premolars becomes faint. In P2 the caudal infundibulum is nearly absent and the rostral infundibulum (Fig. 13) is surrounded medially, rostrally and laterally by a crescentic shaped cement area.

Relation between upper cheek teeth and maxillary sinus:

At 1.5 months of age the bud of M1 fills the maxillary sinus almost entirely. At 9 months of age, the embedded part of M1 develops dorsad to occupy most of the sinus. In addition the small sized bud of M2 extends within the caudoventral part of the sinus. At 12 months of age (Fig. 14), the reserve crown of the M1 and M2 form most the medial boundary of the maxillary sinus. In all previous ages the aforementioned teeth are crossed laterally by the infraorbital canal. Moreover, the bone of the alveoli covering the embedded part of the upper cheek teeth and separating it from the sinus is somewhat thick.

When the donkey is 4 years old, the reserve crowns and the roots of the molars and the caudal portion of the last premolar embedded within the distal half of the maxillary sinus. They lie directly distal to the infraorbital canal. As the donkey ages, the body of the upper cheek teeth decreases in length, the maxillary sinus increases in size. As a result at 8 years old the molars and the last premolar project within the ventral part of the sinus and are located about 1.5 cm distal to the infraorbital canal. Moreover the sinus extends about 2.5 cm behind the last molar.

When the donkey gets older the bodies of the upper cheek teeth are represented by exposed crowns. Therefore at 15 years old the roots of the last four upper cheek teeth are located in the floor of the maxillary sinus which becomes more capacious. With the advancement of the age the alveolar bones overlying the roots of the latter teeth become thinner and easily eroded.

Morphometrical study:

The deciduous premolars at 1.5 months measure 34.12, 39.91 and 38.16 mm long respectively. With advancing age they decrease in length to reach 23.01, 26.47 and 29.87 mm at 15 months. The degree of diminish from 1.5 to 15 months of age differs in the different premolar teeth. The body of each deciduous premolar (Table 1) is longer than that of the corresponding root at 1.5 months. The difference between them decreases at 9 months, but at 15 months the root becomes longer than the body. The ratio between the body and the corresponding root varies in the different ages.

At 15 months of age (Table 1) the body of P2 is nearly one third and that of P3 and P4 are nearly half the length of that at 1.5 months. However, the root increases in length from 1.5 months of age toward 15 months. This indicates that with increasing age there is a reverse correlation between the length of the body and that of the root. All the deciduous premolars increase in thickness toward the apical end at different ages. Moreover the breadth is larger than the thickness.

The length of the permanent upper cheek teeth (Tables 2, 3 & Fig. 15 - 20) at the period from 4 to 15 years varies in the different ages. The length decreases with increasing age and reach minimum value at 15 years old. The ratio in percentage between the length of the permanent cheek teeth at 15 years and that at 4 years is ranging between 51-60%. It was observed that the P4 is the longest permanent upper cheek teeth in the age from 4 to 15 years. The latter tooth is followed by P3.

At 4 years the length of the body of all upper cheek teeth except M3 constitutes most the total length. The tooth is formed mainly of body (exposed and reserve crowns) in addition to short root. In case of M3 the length of the body represents the total length due to the absence of the root. Up to 4 years the ratio between the length of the root and the corresponding total length increases with advancing age. At the various ages the thickness of each permanent tooth at the occlusal surface except

P2 and M3 is nearly equal to the breadth. Consequently the occlusal surface of these teeth is square in outline. In case of P2 and M3 the breadth is higher than the thickness.

DISCUSSION

The present work shows generally that the deciduous and upper permanent cheek teeth in donkey have three roots, two lateral and one medial. At 1.5 months of age the rostral lateral root of the deciduous premolar is the longest, followed by caudal lateral then the medial one. At 4 years all the permanent upper cheek teeth have short roots except M3 has roots at 5 years. At 15 years the medial root is the longest and the broadest one in all cheek teeth except in P2 the rostral root is the longest. Amin and Kassem (1987) in donkey and horse, Nickel *et al.* (1973) and Clair (1975) in the latter animal mentioned the same number of roots. But the first authors added that the rostral root is the longest, the medial is the widest and the lateral one is the shortest, while the last author stated that the medial root tends to become double. In this respect the current result indicates that the medial root is partially united with the caudal lateral root at 8 years. El-Hagri (1967) reported that in equines the first and last cheek teeth have three roots, while the remainder have four or three roots. In the examined donkey the roots of the deciduous premolars are semicylindrical in shape with a wide apical foramens at 1.5 months of age. With increasing age the roots are diverged due to the invagination and pressure of the buds of the permanent premolars. Moreover, the apical foramens could not be demonstrated.

The current study reveals that each upper cheek tooth begins as short bud which is surrounded by two thin outer and inner enamel layers. The bud is occupied mostly by two wide canals extending along its length. Each canal terminates at each bud end by a wide opening. With advancing age the bud increases in length, thickness and weight, consequently the canals with their openings become narrow. After that the canals are closed proximally then distally. These canals represent the future infundibula.

Ahmed (1991) stated that the length of the upper cheek teeth is increased in caudal direction consequently the last molar is the longest tooth in horse, mule and donkey. On the contrary, the present finding

indicates that P4 is the longest permanent upper cheek teeth in all examined ages, it is followed by P3. Bunger and Hertsch (1981) mentioned that P4 and M2 in donkey are the strongest teeth in both upper and lower jaws. Corresponding to Amin and Kassem (1987) the longest tooth is P3 in donkey and P4 in horse. They added that at the age of 10-20 years, rapid elongation of the cheek teeth of donkey and horse was observed and the reserve crown appeared to compensate the excessive wear of the teeth. However, the present result shows that with increasing age the upper cheek teeth in donkey decrease in length. Occasionally, a rudimentary upper first premolar (P1) is present in horse (Nickel *et al.*, 1973), this tooth is vestige in equines (El-Hagri, 1967). Therefore the previous tooth was not described in this investigation.

The present work indicates that the presence and size of the infundibula differ in the different examined ages. At 4 years the permanent upper cheek teeth have two nearly equal infundibula which become larger at 8 years but are absent at 15 years. Nickel *et al.* (1973) reported that the upper cheek teeth in horse present two infundibula. Before these teeth are in wear, the infundibular wall are continuous with the external enamel. Kilic, Dixon and Kempson (1997) clarified that the infundibula are deep, cup-like enamel indentations that are partially filled with cement. Corresponding to Nickel *et al.* (1973); Clair (1975); Evans (1981) as well as Frandson and Whitten (1981) the infundibula are filled with cementum. However, Brown, Smith and Pillier (1997) mentioned that the molars in horse have big surfaces or tables and the enamel is folded to make funnel-like depressions in the tooth which become filled with food to look black.

The current study reveals that there is a relation between the development of the upper cheek teeth and the maxillary sinus. At 1.5 months the bud of M1 fills the sinus almost entirely. At 12 months the reserve crown of M1 and M2 form most the medial boundary of the sinus. At preceeding ages the alveolar bones overlying the apical ends of these teeth are somewhat thick. At 4 years the reserve crown of molars and the caudal portion of last premolar embeded within the distal half of the maxillary sinus. However, Kobluk, Ames and Geor (1995) stated that in young horses, younger than 6-7 years, the roots of P4 to M3 fill the sinus almost entirely. When the examined donkey is 8 years old, the molars and the last premolar project within the ventral part of the sinus.

On the contrary, P4 project within the maxillary sinus in donkey and horse at 10-20 years age as reported by Amin and Kassem (1987). But Misk and Seilem (1997) stated that the molars in donkey develop dorsally and occupy most the maxillary sinus.

When the donkey gets older the body of the cheek teeth is represented by exposed crown. Therefore at 15 years the roots of the last four cheek teeth are located in the floor of the maxillary sinus which becomes more capacious. Wiggs and Lobprise (1997) clarified that the maxillary sinusotomy in horse allows exposure to the root of the last four upper cheek teeth. With advancing age the alveolar bone overlying the roots of the teeth which lie within the maxillary sinus becomes thinner and easily eroded. Therefore, the infection can transport from the teeth to the sinus or vice versa. Mansmann, Mcallister and Pratt (1982) stated that in horse the relationship between the maxillary sinus and last four cheek teeth is clinically important in that periapical infection of these teeth may lead to maxillary sinus empyema.

The present work explains that there is a relation between the development of the upper cheek teeth and the position of the infraorbital canal. In the young investigated donkeys, younger than 15 months, the upper cheek teeth projecting in the maxillary sinus are crossed laterally by infraorbital canal. At 4 years, the teeth lie directly distal to the infraorbital canal. As the animal ages, as in 8 years old donkeys the teeth decrease in length consequently they are located ventral to the canal.

The buccal surface of the permanent cheek teeth at 4 years age contains generally two prominent longitudinal ridges separating two grooves. With increasing age the ridges and grooves become faint and could not be demonstrated in older animals. However, this surface in horse has three ridges as described by Nickel et al. (1973) and Clair (1975) or one central ridge as reported by El-Hagri (1967). The lingual surface of the examined donkeys at 4 years contains a broad column extending along the whole tooth. It separates two unequal depressions. At 8 years the column becomes faint, and the caudal depression is absent in the molars, while at 15 years the column and depressions could not be demonstrated. Concerning the anatomical features of both the buccal and lingual surfaces of the deciduous premolars, they are distinct at the younger donkeys but could not be distinguished in the older ones.

The occlusal surface of the permanent upper cheek teeth in the donkeys of 4 years old is irregular due to the presence of grooves, cement areas and infundibula. As the animals advance in age this surface becomes even due to the disappearance of the foregoing structures by wearing process. Clair (1975) stated that the enamel being very hard, wears at a slower rate than the dentin, making the occlusal surface quite rough. Also Dyce, Sack and Wensing (1987) mentioned that the enamel may be folded in a very complicated fashion, this increases the efficiency of the occlusal surface.

The present work shows that the number and size of the cement areas depend on the age of the animal. Regarding to the deciduous premolars there are 4 cement areas except P2 has an additional rostral area at 1.5 months. With advancing age the cement areas become large and deep except in P2. In the latter tooth the areas except the caudomedial one are continuous with each other inturn the number becomes two at 15 months. At 4 years of age there are 5 cement areas in all permanent upper cheek teeth except P2 has an additional rostral one. At 8 years the two cement areas lateral to the infundibula are continuous with each other in case of P2. When the donkeys get older the cement areas disappear as demonstrated at 15 years old.

LEGENDS

- Fig. 1:** Photograph of 1.5 months showing buccal surface of P2 (1), P3 (2), P4 (3) and bud of M1 (4).
- Fig. 2:** Photograph of the apical end of the M1 bud at 1.5 months showing the openings of the canals (arrow).
- Fig. 3:** Photograph of the occlusal surface of the M1 bud at 9 months showing the openings of the canals (arrow).
- Fig. 4:** Photograph of 9 months showing the buccal surface of the P2 (1), P3 (2), P4 (3), M1 (4) and bud of M2 (5).
- Fig. 5:** Photograph of 12 months showing the occlusal surface of the P2 (1), P3 (2), P4 (3) and M1 (4). Notice the cement areas (arrows) medial and lateral to the infundibula.
- Fig. 6:** Photograph of 15 months showing the deciduous premolars (1, 2, 3), the overlying buds of their permanent teeth, M1 (4) and M2 (5).

- Fig. 7:** Photograph of P2 (1) at 1.5, 9 and 15 months from right to left.
- Fig. 8:** Photographs of the lingual surface of the permanent upper cheek teeth at 4 years. From right to left P2 (1), P3 (2), P4 (3), M1 (4), M2 (5) and M3 (6).
- Fig. 9:** Photograph of the occlusal surface of P4 at 4 years, showing the infundibula (arrows) and the cement areas (1, 2, 3, 4 and 5).
- Fig. 10:** Photograph of the occlusal surface of P2 at 4 years showing the infundibula (arrow) and the cement areas (1, 2, 3, 4, 5 and 6).
- Fig. 11:** Photograph of the buccal surface of the permanent upper cheek teeth at 5 years. From right to left P2 (1), P3 (2), P4 (3), M1 (4), M2 (5) and M3 (6).
- Fig. 12:** Photograph of the buccal surface of the M1 (4) at 1.5, 9, 15 months, 4, 5, 8 and 15 years from right to left.
- Fig. 13:** Photograph of the occlusal surface of P2 at 15 years showing the rostral infundibulum (1) is surrounded medially, rostrally and laterally by crescentic shaped cement area (arrow). Notice the caudal infundibulum (2) is nearly absent.
- Fig. 14:** Lateromedial radiograph of 12 months showing the deciduous premolars (1, 2, 3) and their overlying buds, (arrows), M1 (4) and M2 (5). Notice extension of the M1 and M2 within the maxillary sinus.
- Fig. 15 - 20:** Histograms showing the relation of the total, body and root length (mm) of each permanent upper cheek tooth in different ages.

REFERENCES

- Ahmed, M.F. (1991):* Prevalent surgical affections of teeth in equine in Assiut province. Thesis, Ph.D., Fac. of Vet. Med., Assiut Univ.
- Amin, A.E. and M.M. Kassem (1987):* Topographical anatomical studies on the teeth with special reference to some surgical affections in donkey and horse. *Assiut Vet. Med. J.*, Vol. 18, No. 35: 212-218.

- Berg, R. (1973):* Angewandte und topographische Anatomie der Haustiere. Zweite Auflage. VEB Gustav Fischer Verlag; Jena.
- Bone, J.F. (1979):* Animal anatomy and physiology. Reston Publishing Co., Inc, Reston, Virginia.
- Brown, J.H.; V.P. Smith and S. Pilliner (1997):* Horse and stable Management incorporating Horse Care. 3rd edition. Blackwell Science.
- Bunger, I. und B. Hertsch (1981):* Das Gebiß des Hausesels (*Equus asinus asinus L.*) Morphologische und rontgenologische Untersuchungen. Zbl. Vet. Med. C. Anat. Histol. Embryol. 10: 61-86.
- Clair, L.E.St. (1975):* Teeth in Sissons and Grossman's. The anatomy of the domestic animals. Rev. by R. Getty. 5th ed. W.B. Saunders Company. Philadelphia, London, Toronto.
- Delahunta, A. and R.E. Habel (1986):* Applied veterinary anatomy. W.B. Saunders Company.
- Dyce, K.M.; W.O. Sack and C.J.G. Wensing (1987):* Textbook of veterinary anatomy. W.B. Saunders Company.
- El-Hagri, M.A.A. (1967):* Splanchnology of the domestic animals. 1st ed. Univ. Press, Cairo.
- Evans, J.W. (1981):* Horses: A Guide to selection, care and Enjoyment. W.H. Freeman and Company San Francisco.
- Fransson, R.D. and E.H. Whitten (1981):* Anatomy and physiology of farm animals. Lea & Febiger. Philadelphia.
- Kilic, S.; P.M. Dixon and S.A. Kempson (1997):* A light microscopic and ultrastructural examination of calcified dental tissues of horses: 1- The occlusal surface and enamel thickness. Equine Vet. J., May 29; 3, 190-197.
- Kobluk, C.N.; T.R. Ames and R.J. Geor (1995):* The horse diseases and clinical management. W.B. Saunders Company.
- Lowder, M.Q. and P.O. Mueller (1998):* Dental embryology, anatomy, development, and aging. Vet. Clin. North Am. Equine Pract. Aug. 14; 2, 227-245.
- Mansmann, R.A.; E.S. Mcallister and P.W. Pratt (1982):* Equine medicine and surgery. American veterinary publications. Drawer KK, Santa Barbara, California.

Milles, A.E.W. and Grigson, C. (1990): Colyer's: Variation and diseases of the teeth of animals. Cambridge University Press.
 Misk, N.A. and S.M Seilem (1997): Radiographic studies on the development of cheek teeth in donkeys. Equine practice. Vol. 19, No. 2. February, 27-38.
 Nickel, R.; A. Schummer and E. Seiferle (1973): The viscera of the domestic animals. Verlag paul parey, Berlin, Hamburg.
 Wiggs, R.B. and H.B. Lobprise (1997): Veterinary dentistry principles and practice. Lippincott-Raven.

Table (1): Some measurements (mm) of the deciduous upper cheek teeth of the donkey at different ages:

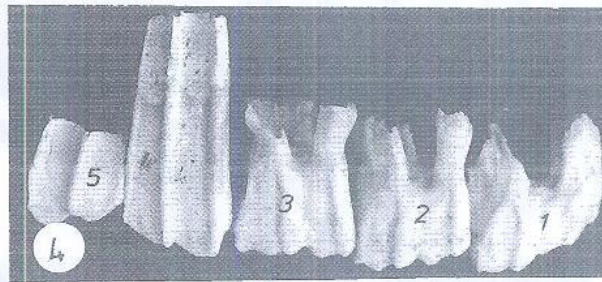
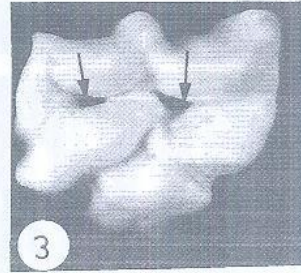
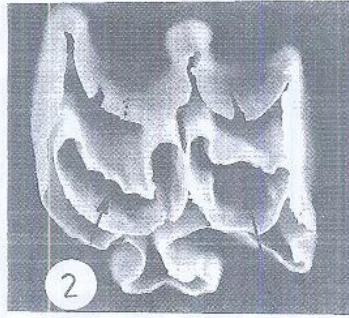
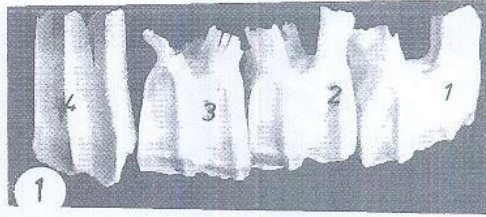
Age	1.5 months			9 months			15 months		
	P ₂	P ₃	M ₁	P ₂	P ₃	M ₁	P ₂	P ₃	M ₁
Name of tooth	P ₂	P ₃	M ₁	P ₂	P ₃	M ₁	P ₂	P ₃	M ₁
Total length:	34.12	39.91	38.16	42.15	29.01	32.25	35.44	55.79	24.13
Body length:	24.02	26.03	27.19	17.66	19.28	20.71	55.79	7.04	12.19
Root length:	10.10	13.88	10.97	11.35	12.97	14.73	15.97	14.28	15.44
Thickness at:									
Occlusal surf.	14.29	18.31	16.15	10.43	17.58	19.75	17.95	11.15	15.81
The middle	16.98	20.55	20.24	18.85	18.02	20.24	19.35	22.30	17.37
The root	19.49	23.47	23.14	14.76	20.47	23.30	24.27	19.48	19.49
Breadth at:									
Occlusal surf.	31.90	24.35	25.23	13.98	33.15	25.40	26.94	22.25	31.49
The middle	32.10	23.74	23.56	23.39	35.61	23.88	24.15	24.25	30.03
The root	32.43	23.26	25.01	19.56	33.50	23.60	24.75	20.22	30.40

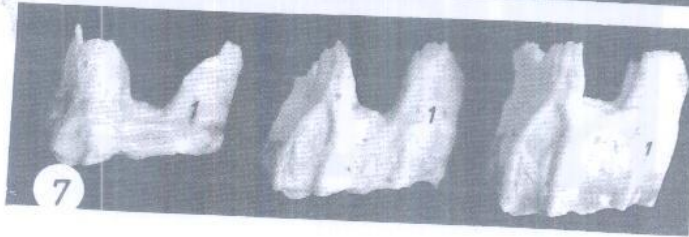
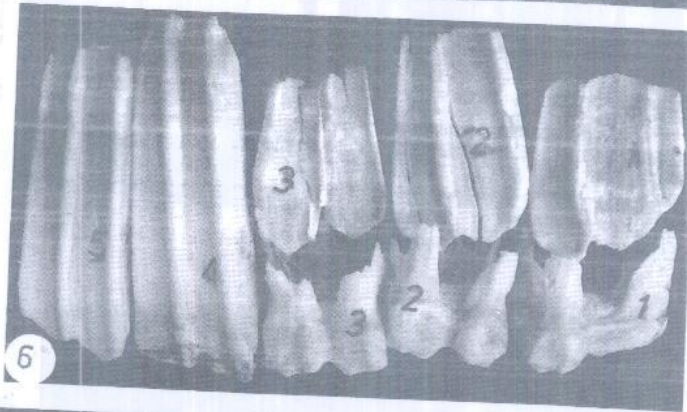
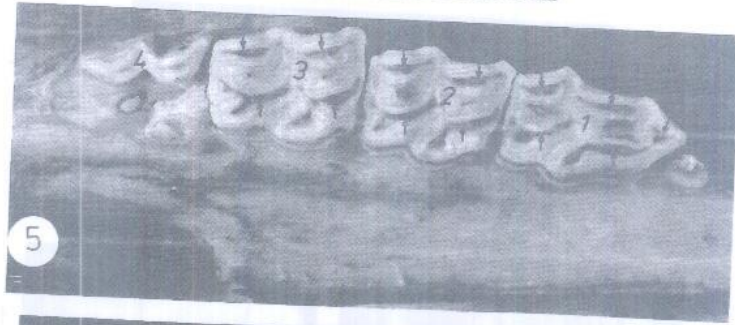Table (2): Some measurements (mm) of the permanent upper cheek teeth of the donkey at 4 and 5 years old.

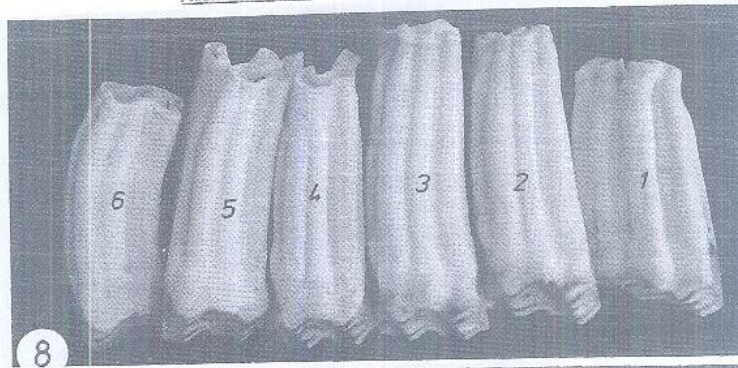
Name of tooth	Age 4 years					Age 5 years						
	P ₂	P ₃	P ₄	M ₁	M ₂	P ₁	P ₂	P ₃	P ₄	M ₁	M ₂	M ₃
Total length	56.48	66.45	69.98	65.63	65.92	60.72	50.38	55.10	57.73	49.10	50.09	47.90
Body length	51.13	61.66	65.33	56.90	59.79	60.72	37.03	43.36	46.65	38.87	41.55	42.42
Root length	5.35	4.79	4.65	8.73	6.13	-	13.35	11.74	11.08	10.23	8.54	5.48
Thickness at:												
Occlusal surf.	20.78	23.45	23.31	22.18	21.24	16.85	20.35	23.98	24.81	23.21	23.25	18.57
The middle	20.65	22.79	23.26	22.19	21.98	19.38	18.38	22.84	25.53	22.51	23.19	17.45
The root	15.01	18.82	19.17	20.77	17.62	15.05	15.75	19.89	18.17	21.99	19.92	13.29
Breadth at:												
Occlusal surf.	29.18	23.24	24.07	22.88	22.47	17.78	30.95	23.23	23.90	20.27	21.63	21.92
The middle	28.09	22.32	23.27	19.97	19.87	20.65	29.62	23.96	22.90	20.00	20.68	21.15
The root	23.44	16.21	16.20	16.45	15.98	17.09	27.33	20.78	16.88	17.23	15.99	15.65

Table (3): Some measurements (mm) of the permanent upper cheek teeth of the donkey at 8 and 15 years old.

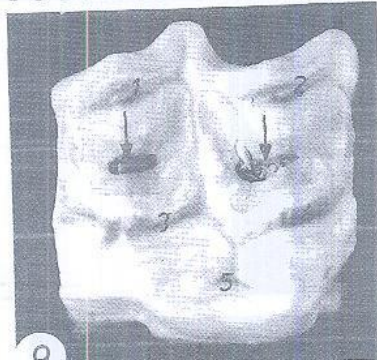
Name of tooth	Age 8 years					Age 15 years						
	P ₂	P ₃	P ₄	M ₁	M ₂	P ₁	P ₂	P ₃	P ₄	M ₁	M ₂	M ₃
Total length	45.08	48.81	52.80	40.70	45.56	43.64	37.35	38.04	39.57	33.01	34.61	36.48
Body length	28.91	33.15	35.98	26.62	33.88	29.66	20.28	21.63	21.50	18.80	19.25	17.99
Root length	16.17	15.66	16.82	14.08	11.68	13.98	17.07	16.41	18.07	14.21	15.36	18.49
Thickness at:												
Occlusal surf.	19.91	24.65	24.92	24.80	23.11	21.13	17.72	24.16	24.37	23.60	22.41	20.60
The middle	19.29	23.26	23.97	24.93	24.10	21.75	16.70	22.32	23.41	24.41	23.10	17.80
The root	15.23	19.92	20.65	23.01	21.92	16.66	11.63	20.14	20.19	22.15	19.41	15.09
Breadth at:												
Occlusal surf.	31.00	24.86	23.77	21.40	21.17	24.40	28.36	23.94	21.99	17.51	18.57	23.93
The middle	29.31	21.67	22.18	19.49	19.73	20.60	26.38	23.29	17.64	19.61	18.42	21.21
The root	26.66	21.30	12.11	17.30	17.63	17.94	24.60	18.30	16.89	19.36	14.41	12.30



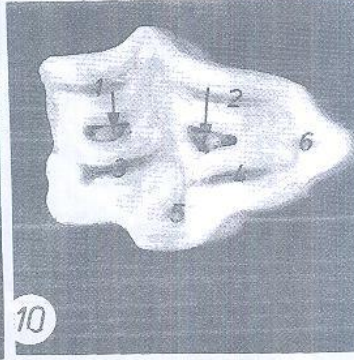




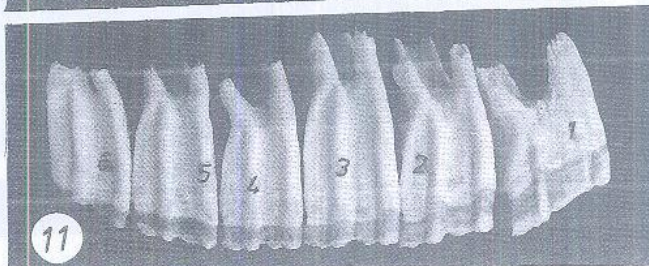
8



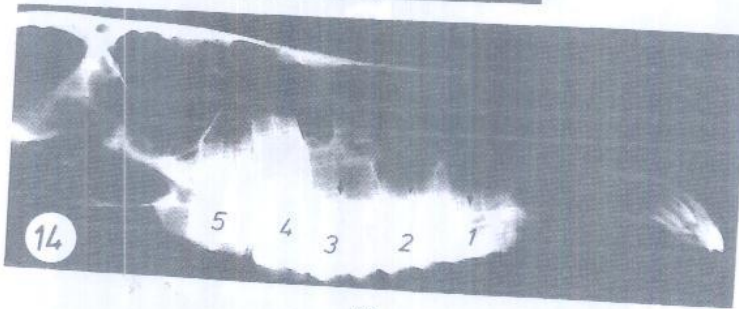
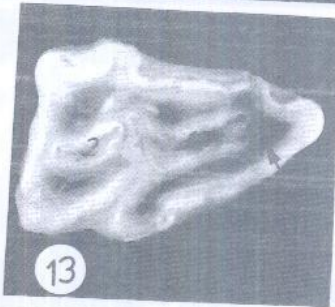
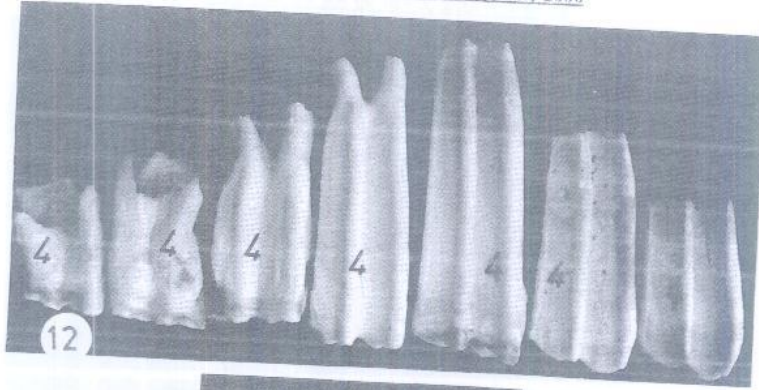
9



10



11



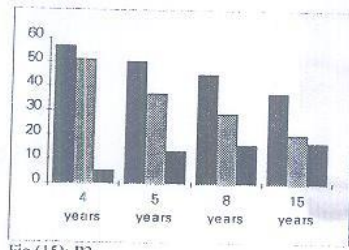


Fig. (15): P2

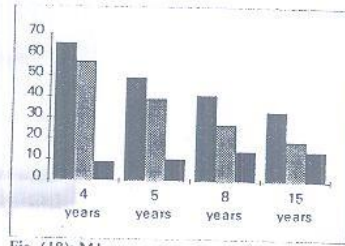


Fig. (18): M1

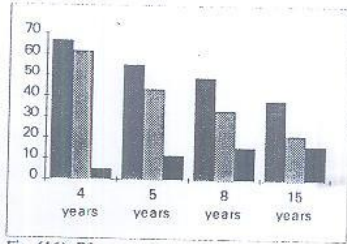


Fig. (16): P3

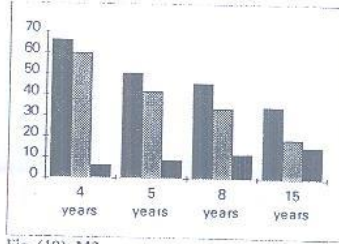


Fig. (19): M2

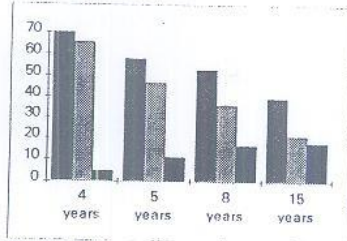


Fig. (17): P4

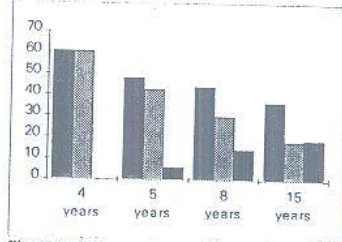


Fig. (20): M3

