

**MORPHOLOGICAL AND MORPHOMETRICAL
STUDIES ON THE LOWER CHEEK TEETH OF
THE POSTNATAL DONKEYS**
(With 3 Tables & 16 Figs.)

By

**SALMA A. MOHAMED and
MANAL ABDEL-MOHSEN***

* Dept. Forensic Med. & Toxic. Fac. Vet. Med., Assiut Univ.
(Received at 18/6/2000)

دراسات مورفولوجية وقياسية على الأسنان الشدقية السفلية
في الحمير بعد الولادة

سلمى أحمد محمد ، منال عبداللطيف عبدالمحسن

أظهرت الدراسة أن برعم الأسنان الشدقية السفلية منقطع من الناحية الأنسية الوحشية. يتكون هذا البرعم من جزئين ، كل جزء يحتوى على قناة تنتهى بقناة عند نهاية السنة . ويتقدم العمر يزداد البرعم في الحجم ، وتمتد القناة تدريجياً وبالتالي تغلق الفتحتين عند نهايتى السنة . وقد لوحظ فى الحيوانات صغيرة السن أن ميازيب وأعمدة السطح الشدقي والمائل فى الأسنان اللببية والدائمة واضحة وطويلة ويتقدم العمر تصبح قصيرة وضحلة ثم تختفى فى الحيوانات الممننة . كما أوضح البحث أن المناطق الإسمنتية للسطح الطباقى تختلف فى العدد والحجم فى الأعمار المختلفة . تبين من الدراسة أن الحافة البطنية للفك السفلى تكون مستديرة ومستقيمة عند ١,٥ شهر ويتقدم العمر تصبح سميكة ومحدبة وغير منتظمة بمحض الشئ نتيجة للامتداد البطنى للقبولاحن وفى الحمير الممننة تصبح الحافة البطنية للفك السفلى رفيقة ومستقيمة نتيجة لقصر الأسنان . ولقد تبين من البحث أن القبطاحن الرابع هو أطول الأسنان اللببية والدائمة فى الأعمار المختلفة . فى الفترة من ٤ الى ١٥ سنة تنقص الأسنان الشدقية الدائمة فى الطول يتقدم العمر . كما أوضحت الدراسة أن ميعاد ظهور الجذور وطولها واتجاهها تختلف فى الأعمار المختلفة وكذلك بين أسنان العمر الواحد . كما يمكن من المعلومات المورفولوجية والقياسية لهذه الدراسة تحديد أعمار الحمير بعد الولادة .

SUMMARY

The bud of the lower cheek tooth is flattened mediolaterally. It consists of two parts, each contains a canal terminates at each bud end by an opening. With advancing age the bud increases in size, the canal is obliterated gradually inturn the openings at the ends are closed. In the young ages the grooves and columns of the buccal and lingual surfaces in deciduous and permanent cheek teeth are distinct and long, with increasing age they become short, shallow and faint then after disappear in the old donkeys. The cement areas of the occlusal surface differ in number and size in the different ages. At 1,5 months the ventral border of the mandible is rounded and straight. As the animal advances in age the border becomes thick, convex and somewhat irregular due to the ventral extension of the premolars. In older donkeys the embeded crowns of these teeth become shorter to compensate for wear, therefore the teeth terminate away from the ventral border which becomes thin and straight. In the different examined ages P₄ is the longest tooth among all the lower deciduous and permanent cheek teeth. In the period from 4 to 15 years the permanent lower cheek teeth decrease in length with increasing age. The time of the appearance of the roots, their length and direction vary in the different ages. From the morphological and morphometrical informations of the present study the age of the postnatal donkeys can be determined.

Key words: Lower cheek teeth in donkey.

INTRODUCTION

The diseases of the equine teeth are among the common problems in the veterinary clinic. Therefore, the anatomy of the teeth received a considerable interest of many investigators (Berg, 1973; Bungler and Hertsch, 1981; Delahunta and Habel, 1986; Dyce, Sack and Wensing, 1987; Ahmed, 1991 as well as Wiggs and Lobprise, 1997). In spite of this the available literatures lack many informations about the anatomy of the lower cheek teeth in postnatal donkeys. So the aim of the present investigation is to give a detail description about the morphological features of the deciduous and permanent lower cheek teeth and their

relation with the mandible in the postnatal donkeys. Moreover, different measurements of each tooth at various ages have been determined.

MATERIAL and METHODS

The present work was carried out on the lower cheek teeth of forty lower jaws of donkeys (*Equus asinus*). The investigated animals were of both sexes and aged from 1.5 months to 15 years old. Lateromedial radiographs of hemimandibles were made. Firstly the lower cheek teeth were studied on the mandible, then they were removed from their alveoli to complete other investigations. The morphological features of the lower cheek teeth and their relation with the mandible were described. In addition, the total length of the tooth, body, root length, thickness and breadth at three different levels were measured using Precision Digital Verner Caliper. In case of the buds, the thickness and breadth were taken only at the middle of the tooth.

RESULTS

Morphological study:

At 1.5 months (Fig.1) the lower jaw contains three deciduous premolars (P₂, P₃, P₄) and the tooth bud of the first molar. The premolars are flattened mediolaterally. The body is longer than the root. Each tooth has two relatively short roots, rostral and caudal. The rostral root is directed ventrally and somewhat rostrally, but the caudal root is directed ventrally and somewhat caudally. The root has a wide apical foramen. These teeth have a slight constriction at the junction of the body with the roots. The buccal surface of the deciduous premolars has a longitudinal groove which extends along the body of the tooth and divides this surface into two columns. Moreover, P₄ has an additional faint small groove.

The lingual surface has a deep longitudinal groove lying opposite to that of the buccal surface. It divides this surface into two parts, each part contains a secondary small groove redividing it into two columns. The contact surfaces are flat and smooth except the mesial contact surface of P₂ and the distal contact surface of P₄ are thin and straight. The occlusal surfaces of P₂ and P₄ are triangular in shape with the apex directed rostrally in the former tooth but caudally in the latter one. The occlusal

surface of P₃ is rectangular. This surface is uneven in all premolars and contains 5 cement areas, 3 small medial and 2 large lateral. The lingual edge is irregular and has two small notches, while the buccal edge has a wide notch.

At 1.5 months the bud of M₁ is flattened mediolaterally and triangular in cross section with its apex directed caudally. The buccal surface (Fig. 1) has a distinct deep groove extends along the whole length of the bud. It divides this surface into two parts, the caudal part is larger and redivided by secondary small groove. Each part contains a canal which terminates at each bud end by an opening. The lingual surface has two grooves divides it into three columns. The rostral and middle columns are characterized by the presence of the previous canals which are incomplete toward this surface. The future occlusal surface has 6 eminences. The bud is surrounded by two thin enamel layers which are joined proximally but separated distally.

At 9 months of age the roots of the deciduous premolars are longer than the bodies. The grooves of the buccal and lingual surfaces become shallow and the columns become faint. The distal contact surface of the last premolar becomes broad and flat due to its contact with the erupted M1. The occlusal surfaces of the premolars slope downwards from the lingual edge toward the buccal edge. The erupted M1 is long tooth, its buccal surface has median deep groove dividing it into two equal columns. All the grooves and columns extend along the whole tooth. The mesial contact surface is broad and slightly convex, while the distal one is grooved and slightly concave. The apical end is opened and has irregular outline. The occlusal surface is white in colour and uneven. The rostral canal of the previous age is obliterated and represented by rostral longitudinal groove of the lingual surface, but the caudal canal is obliterated only proximally and is still incomplete distally. The M2 is represented by short thin bud which has the general features of the M1 bud at the previous age. In addition, the canals and their openings are wider at age of 9 months.

At 12 and 15 months of age, the deciduous premolars are shorter and the roots are longer than the preceding age. The underlying buds of the permanent premolars invaginate between the roots of the deciduous ones. Also, the grooves and columns of the buccal and lingual surfaces of the deciduous premolars could not be distinguished. The contact surfaces

become broader. The cement areas of the occlusal surface (Fig. 2) become larger and deeper than the preceding age, moreover P2 has an additional rostral area. The first molar is longer and heavier compared with the previous age. The occlusal surface is triangular in shape, and four small faint cement areas (Fig. 2) appear on it. The occlusal surface of the just erupted M2 at 15 months is thinner and narrower than the other cheek teeth of the same age, the other features similar to M₁ at the 9 months. At 12 months (Fig. 3) M2 is still bud.

At 18 months of age the reserve crowns of the deciduous premolars disappear and the bodies are represented by exposed crowns (Fig. 4, 5). The buds of the permanent premolars (Fig. 4) become longer and press on the roots of the deciduous ones, the buccal and lingual surfaces of the deciduous premolars are smooth due to the absence of the grooves and columns. The cement areas reduce in number due to their fusion, therefore each tooth contains three crescentic-shaped areas. The M2 becomes larger and its exposed crown longer compared with the previous age. The occlusal surface is thicker and broader than at 15 months. Three small faint cement areas appear. At this age M3 is represented by small bud within the mandible.

At 4 years of age all the lower cheek teeth are permanent long teeth, flattened mediolaterally. In P2, P3 and M1 (Fig. 6) two roots begin to appear. The apical ends of the lower cheek teeth are opened. The buccal surface of the lower cheek teeth has a distinct central longitudinal groove except M3 has two grooves. The groove divides this surface into two columns, consequently M3 contains three columns. The columns of each tooth are nearly equal in length except that of P2 and M3. The rostral column of P2 is shorter than the caudal one, on contrast the caudal column of M3 is the shortest of the three columns.

The lingual surface (Fig. 6) of all lower cheek tooth except P2 and M3 has two distinct longitudinal grooves extend along the whole tooth length. The rostral groove is wider and deeper than the caudal one. The rostral groove lies opposite to that of the buccal surface. The grooves divide the lingual surface into three parallel columns, the caudal column has faint groove. In case of P2 and M3 there are three grooves which separate four columns. The grooves of P2 do not extend to the occlusal surface as other teeth. The mesial contact surface of cheek teeth except P2 is convex, wide above and narrow below. In P2 this surface is

represented by smooth straight edge. The distal contact surface is smooth and concave, but it is represented by smooth concave edge in M3.

The occlusal surface is rectangular (Fig. 7) in all lower cheek teeth except P2 and M3 is triangular with the apex directed rostrally in P2 and caudally in M3. This surface is irregular, its buccal and lingual edges are nearly blunt. The lingual edges has two small notches in all lower cheek teeth except P2 and M3 which have three. The buccal edge has wide notch, but M3 has two. At this age (Fig. 7, 8) 5 cement areas, 3 medial and 2 lateral, were observed at the occlusal surface of the lower cheek teeth except M3 which has 6 cement areas, 4 medial and 2 lateral. Generally in all teeth the medial cement areas are small and rounded, while the lateral ones are large and elongated.

At 5 years of age each lower cheek tooth except the last one has two short roots, rostral and caudal. The roots are nearly equal in length and breadth, they are directed ventrally and somewhat caudally except those of P2 are vertical in direction. The exposed crown of the lingual surface is higher than that of the buccal surface. The grooves of the lingual surface of P2 are less distinct. The rostral column of the lingual surface extends toward the rostral root, while the two caudal columns are directed toward the caudal root. The lingual edge of the occlusal surface is sharp and prominent. The cement areas become larger, deeper and more distinct than the previous age.

With increasing age the lower cheek teeth become shorter and narrower than the previous ages, and the roots (Fig. 9) become relatively long on the expense of the reserve crowns. At 8 years of age the last molar has two roots. The rostral and caudal roots of each tooth are nearly equal in length. The roots of P2 and P3 are vertical in direction but with each successive caudal tooth, the ventrally directed roots take an increasingly caudal inclination, resulting in the last molar have the most angulation. The grooves and columns of the buccal and lingual surfaces become faint and short. The rostral column of the lingual surface forms the rostral root and the caudal columns form the caudal root. The distal contact surface has shallow groove. The irregularity of the occlusal surface is less than the preceding age. Two large cement areas, rostral and caudal, were demonstrated only in P2 (Fig. 8).

At 15 years of age (Fig. 10) the buccal and lingual surfaces are smooth due to the disappearance of the grooves and columns. The

occlusal surface becomes thinner and narrower than the previous age. Moreover, this surface is narrower than the crown. The notches of the lingual and buccal edges are indistinct. The apical foramen could not be distinguished. The contact surface is narrower distally than the previous age. The occlusal surface differs greatly compared with previous ages. The cement areas (Fig. 8) are represented by two large deep grayish depressions, rostral and caudal. The two depressions are nearly equal in all lower cheek teeth except M3 the caudal one is the larger.

Relation between lower cheek teeth and mandible:

At 1.5 months of age the deciduous premolars occupy most the dorsal border of the mandible. The ventral border of the mandible is rounded and straight. With the advancement of age as in 12 months (Figs. 2, 3) the deciduous premolars are pushed gradually rostrally as the first molar begin to erupt and occupy the space between the preceeding teeth and the ramus of the mandible.

At 15 months the buds of the permanent premolars underlying the deciduous ones increase in size and reach the ventral border of the mandible causing different bulges. Therefore the ventral border of the mandible becomes thick, convex and somewhat irregular.

At 4 years of age the permanent lower cheek teeth occupy most the dorsal border of the mandible. Due to the enlargement of the lower jaw, the permanent premolars are pushed more rostrally to leave space for the molars. The apical ends of the permanent premolars extend ventrally till the ventral border of the mandible producing bulges in it. It was observed that the bulges of P3 and P4 are more pronounced than that of P2. Moreover the molars do not extend to the mandible due to their caudal angulation. With increasing age the embeded crowns of the lower cheek teeth become shorter to compensate for the wear. Consequently it was noticed that the apical ends of the roots of the premolars are located at the middle of the distance between the dorsal and ventral borders of the mandible at 8 years, but terminates at proximal third of this distance at 15 years. As a result the ventral border of the mandible becomes straight and thin. At the latter age the lower permanent cheek teeth occupy smaller area from the dorsal border than the previous ages. Because at this age the total breadth of the lower cheek teeth decreases compared with other ages.

Morphometrical study:

The length of the deciduous premolars (Table 1) varies in the different ages. It is at 15 months lower than at 1.5 months, this indicates that the total length of these teeth decreases with increasing age. It is noticed that P4 has the longest length in all ages followed by P3 then P2. At 1.5 months of age the body of the deciduous premolars is longer than the root, but the ratio between them differs in the different teeth. It is 1.5 : 1, 1.9 : 1 and 3.2 : 1 in P2, P3 and P4 respectively. It is clear that the body is one and half folds the root in P2, nearly double the root in P3 but more than three folds the root at P4. At 9 months the body decreases in length, consequently the ratio between it and the root decrease to become 1.1:1, 1.1:1 and 1.6:1 in P2, P3 and P4 respectively. The body continues to decrease in length till reach its minimum value at 15 months, where the ratio between the body and the root becomes nearly 0.5 : 1 in all premolars.

It is clear that the length of the root of the deciduous premolars increases as the age advances. Therefore, there is a reverse correlation between the length of the body and that of the root in the deciduous premolars at the period from 1.5 to 15 months.

At the ages from 9 to 15 months the erupted molars are longer than the deciduous premolars (Table 1). Moreover, the former teeth increases in length as the animal advances in age, on the other hand the latter teeth decreases in length.

The length of the permanent lower cheek teeth (Fig. 11-16), differs in the various ages. These teeth (Tables 2, 3) decrease in length from 4 years toward 15 years where they reach minimum value. It was noticed that the differences in length between 4 and 5 years are generally low but they are lower in case of molars than in premolars. It is found that P4 is the longest tooth in all examined ages, it is followed by P3 at 4 years but by M2 at the other ages. On the contrary, the shortest tooth is P2 in all examined ages. The percentage of the length of the permanent cheek teeth at 15 years to that at 4 years is ranging between 54% to 62%. The highest percentage was recorded in P2 and M3, while the lowest one in P3. The body of the permanent lower cheek teeth is very long at 4 years and represents the total length in all teeth except in P2, P3 and M1 where it represents most of the tooth. It decreases in length as the animal gets older.

The breadth of all examined teeth whatever deciduous or permanent is higher than the corresponding thickness. As a result all the lower cheek teeth are flattened mediolaterally. But the ratio between the breadth and thickness differs in the various ages and also between the teeth of the same age.

In the period from 1.5 to 15 months of age the breadth of the deciduous premolars decreases distalwards. Therefore the occlusal surfaces of these teeth are broader than the apical end. In case of early erupted molar as M1 at 9 months the breadth at the occlusal surface is lower than at the middle and apical end. Then the breadth of the occlusal surface increases with advancing age.

It is found that at the period from 4 to 15 years the permanent lower cheek teeth decreases in thickness distalwards in all examined ages except at 15 years old, where the thickness at the middle of the teeth is higher than at the occlusal surface. This indicates that in older donkeys these teeth become narrower at the occlusal surfaces.

DISCUSSION

The present work shows that at 4 years of age the lower cheek teeth in donkey has no root except in P2, P3 and M1 the roots begin to appear. At 5 years all the lower cheek teeth except M3 has two relatively short roots. The roots were not demonstrated in M3 at this age. On the other hand, Amin and Kassem (1987) stated that the roots of the lower cheek teeth in donkeys and horses at age of 5 years are very small, because the most embeded part of the teeth at this age is reserve crown. In this connection, Kirkland, Baker, Manfra, Eurell and Losonky (1996) reported that at the time of eruption, the mandibular cheek teeth of horse did not have roots, or evidence of root formation. However, within 2 years after eruption, roots were present. With advancing age, each lower cheek teeth in the examined donkeys has two distinct roots, rostral and caudal, which are nearly equal in length at 8 years of age. As the age of the animal is advanced the roots become longer on the expensive of the body of the tooth. In this respect, Clair (1975) reported also that the lower cheek teeth in horse have two roots, which are short as recorded by Nickel, Schummer and Seiferle (1973). El-Hagri (1967) in equines and Misk and Seilem (1997) in donkey agreed this statement in all cheek teeth

except M3 which has one root as stated by the former author, and three roots as reported by the latter ones.

Corresponding to Krikland *et al.* (1996) the permanent lower cheek teeth of horse, at the time of eruption, consist of an exposed and a reserve crown. The present findings indicate that the body (exposed and reserve crown) of these teeth at 4 years is very long and represents the whole tooth in all cheek teeth except P2, P3 and M1. In the latter teeth it represents most of the tooth due to the appearance of the roots. With increasing age the root increases in length on the expense of the body to compensate for wear. In this concern, Brown, Smith and Pilliner (1997) mentioned that new permanent teeth have a large crown, much of which is below the level of the gum, so that in a 5 years old horse most of the jaw is filled with teeth. The tooth wears down as it is used but that is compensated for as the growth of the tooth root forces the crown upwards. Bone (1979) stated that as the animal ages the tooth sockets gradually fill from below with bone, which slowly pushes the teeth from the socket to compensate for wear. Kilic, Dixon and Kempson (1997) pointed up that the occlusal surface of the underlying equine enamel contained different wear patterns, including polished areas, local fractures, wedge-shaped pits, striations and depressions.

The present study reveals that at 1.5 months the deciduous premolars occupy most the dorsal border of the mandible. With increasing age, as at 12 months, the previous teeth are pushed gradually rostrally due to the appearance of the M1. At 4 years the permanent premolars are pushed more rostrad as the molars are located between them and the ramus of the mandible also due to the enlargement of the jaw as mentioned in horse by Clair (1975). In the older examined donkeys, 15 years old, the lower cheek teeth occupy smaller area from the dorsal border than the previous ages. Because at this age the total breadth of the lower cheek teeth at the occlusal surface decreases compared with preceding age.

At 1.5 months the ventral border of the mandible of the investigated donkeys is rounded and straight. At 15 months the buds of the underlying permanent premolars extend to this border causing different bulges, inturn the border becomes thick and somewhat irregular. These bulges were observed at 4 years due to the ventral extension of the apical ends of the permanent premolars. As the donkeys advance in age

the lower cheek teeth become shorter and the jaw larger consequently the roots terminate away from the ventral border and the bulges begin to disappear. Moreover, in older animals the ventral border of the mandible becomes thin and straight. On the other hand, Amin and kasseem (1987) stated that these bulges appear in donkeys and horses at 5 years and disappear at 10 years of age. In the donkeys ranging from 6 - 8 years, Abdalla (1990) mentioned that the distance between the roots of the cheek teeth and the ventral border of the mandible is important especially during the extirpation of the teeth, he added that this distance is about 2.4 - 5.0 cm. In young horses (under 5 years), Bone (1979) recorded that the lower border of the jaw will be rounded and convex i.e. bulge downward. In older horses (5 years and older) the lower jaw line will flatten out, sharpen along its edges, and becomes concave when the animal is old.

According to Kobluk, Ames and Geor (1995) the individual cheek teeth of horse differ in length. A similar result was obtained in the deciduous and permanent lower cheek teeth in examined donkeys. The present work indicates that up to 4 years P4 is the longest permanent lower cheek tooth in all examined ages. It is followed by P3 at 4 years, but by M2 at the other ages. The same result was observed by Abdalla (1990) in donkeys ranging from 6 to 8 years. Also Bunker and Hertsch (1981) reported that the P4 and M2 are the strongest teeth in both the upper and lower jaws. But Ahmed (1991) stated that in the lower cheek teeth P4 and M1 are the longest teeth in horse, P2 and P3 in donkey, while in mule the premolars have the same length and are longer than molars. Regarding to the deciduous premolars the recent study reveals that P4 is also the longest tooth followed by P3 then P2. It is found that the permanent lower cheek teeth decrease in length from 4 years toward 15 years where they reach minimum value. The percentage of the length of these teeth at 15 years to that at 4 years is ranging between 54% to 62%. Consequently the length of permanent cheek teeth at the former age is about half to two thirds that at the latter age.

Clair (1975) revealed that in horse the lower cheek teeth are narrower and straighter mediolaterally than those of the upper jaw, averaging 1.8 cm in width. From the present morphometrical study it is clear that the thickness of the lower cheek teeth in donkey is lower than that obtained by the previous author in horse. Moreover, at the period from 4 to 15 years the permanent lower cheek teeth decrease in thickness

distalwards in all examined ages except at 15 years. At the latter age the thickness at the middle of the teeth is higher than at the occlusal surface. This indicates that in the older donkeys the lower cheek teeth become narrower at the occlusal surface.

The present study shows that at 4 years of age the lingual and buccal edges of the permanent lower cheek teeth are nearly blunt, but at 5 years the lingual edge becomes sharp and higher than the buccal edge. The lingual edge is characterized by two small notches in all teeth except P2 and M3 have three. The buccal edge has wide notches except M3 has two notches. As the donkey advances in age the foregoing notches become indistinct. In this situation Nickel *et al.* (1973) and Mansmann, Mcallister and Pratt (1982) emphasized that the lower cheek teeth in horse slope toward the vestibule. Kobluk *et al.* (1995) clarified that in the latter animal the cheek teeth occlusal surface is mildly angled. This mild angulation of the occlusal surface plus the grinding action of the cheek teeth results in development of the sharp edges to teeth. These edges can become sharp enough to cause ulceration or laceration of the cheek mucosa and the tongue.

The buccal surface of the permanent lower cheek teeth except M3 in the examined donkeys at 4 and 5 years has distinct longitudinal groove dividing it into two columns. They are nearly equal in length except in P2 the rostral column is shorter than the caudal one. M3 has two grooves consequently three columns, the caudal one is the shortest. With increasing age the grooves and columns become faint and short at 8 years, but disappear at 15 years. Amin and Kassem (1987) in donkey and horse, El-Hagri (1967) and Clair (1975) in the latter animal described a longitudinal furrow in the buccal surface. Moreover, the latter author mentioned an additional furrow in P2 and M3. In the deciduous premolars of the investigated animal the buccal surface is characterized at 1.5 months by longitudinal groove which extends only along the body of the teeth. P4 has an additional groove. As the animal advances in age the grooves become shallow as in 9 months, then after they disappear gradually and the buccal surface becomes smooth as in 18 months. The first premolar (P1) is present in the lower jaw but does not erupt in horse (Nickel, *et al.*, 1973), or it is rarely erupt in equines (El-Hagri, 1967). Therefore, this work did not include this tooth.

The present investigation indicates that at 4 and 5 years the lingual surface of the permanent lower cheek teeth has two longitudinal grooves which divide this surface into three parallel columns. But P2 and M3 have three grooves inturn four columns. At 4 years the columns extend along the whole length of the teeth. At 8 years of age the grooves and columns become faint and short, moreover the rostral column forms the rostral root and the caudal two columns form the caudal root. At 15 years the surface becomes smooth due to the disappearance of the grooves and columns. The lingual surface is marked by several small grooves in donkey and horse (Amin and Kassem, 1987), or irregular grooves (El-Hagri, 1967), or principal groove with several shallower ones in horse (Nickel *et al.*, 1973 and Clair, 1975). Regarding to the deciduous premolars of the examined donkeys, the lingual surface has a deep longitudinal groove which divides this surface into two parts. Each part contains a secondary small groove redividing it into two columns. With advancing age the grooves and columns become faint and short, then disappear and surface becomes smooth.

According to the present study the cement areas of the occlusal surface differ in number and size in the different ages. At 4 years the lower cheek teeth have 5 cement areas, 3 medial and 2 lateral except M3 which has 6 areas, 4 medial and 2 lateral. In general the medial cement areas are small and rounded while the lateral ones are large and elongated. With increasing age the cement areas become larger, deeper and more distinct as at 5 years. At 8 years two large areas, rostral and caudal, were demonstrated in P2. In older donkeys (15 years) the cement areas are represented by two large deep grayish depressions.

LEGENDS

- Fig. 1:** Photograph of 1.5 months showing the buccal surface of P₂(1), P₃(2), P₄(3) and bud of M₁(4).
- Fig. 2:** Photograph of 12 months showing 6 cement areas on occlusal surfaces of P₂ (1), 5 areas in P₃ (2) and P₄ (3) as well as 4 faint areas in M₁ (4). Notice the cement areas are indicated by arrows.

- Fig. 3:** Lateromedial radiograph of 12 months showing the deciduous premolars (1, 2, 3) and their underlying buds (arrows), M₁(4) and the bud of M₂(5).
- Fig. 4:** Photograph showing the buccal surface of the deciduous premolars (1, 2, 3) and their underlying buds as well as M₁(4) and M₂(5) at 18 months.
- Fig. 5:** Photograph of the P₂ at 1.5 months (left), 15 months (middle) and 18 months (right).
- Fig. 6:** Photograph of the lingual surface of the permanent lower cheek teeth at 4 years. From left to right P₂ (1), P₃ (2), P₄ (3), M₁ (4), M₂ (5) and M₃ (6).
- Fig. 7:** Photograph of the occlusal surface of P₄ (right) and M₃ (left) at 4 years. Notice 5 cement areas in P₄ and 6 in M₃ (arrows).
- Fig. 8:** Photograph of the occlusal surface of P₄ at 15 years (right), P₂ at 8 years (middle) and P₂ at 4 years (left). Notice 2 cement areas (arrows) at right and middle specimens, and 5 areas at left one.
- Fig. 9:** Photograph of the buccal surface of M₁ (4) at 9, 15, 18 months and at 4, 5 and 15 years (from left to right). Notice difference in length.
- Fig. 10:** Photograph of the buccal surface of the lower cheek teeth at 15 years. From right to left P₂ (1), P₃ (2), P₄ (3), M₁ (4), M₂ (5) and M₃ (6).
- Fig. 11-16:** Histograms showing the relation of the total, body and root length (mm) of each permanent lower cheek teeth in different ages.

REFERENCES

- Abdalla, K.E.H. (1990):* The teeth of the lower jaw in donkey, buffalo and camel. *Assiut Vet. Med. J.*, Vol. 23, No. 46, July, 1-11.
- Ahmed, M.F. (1991):* Prevalent surgical affections of teeth in equine in Assiut province. Thesis, Ph.D., Fac. of Vet. Med., Assiut Univ.
- Amin, A.E. and M.M. Kassem (1987):* Topographical anatomical studies on the teeth with special reference to some surgical affections in donkey and horse. *Assiut Vet. Med. J.*, Vol. 18, No. 35: 212-218.

- Berg, R. (1973):* Angewandte und topographische Anatomie der Haustiere. Zweite Auflage. VEB Gustav Fischer Verlag; Jena.
- Bone, J.F. (1979):* Animal anatomy and physiology. Reston Publishing Co., Inc. Reston, Virginia.
- Brown, J.H.; V.P. Smith and S. Pilliner (1997):* Horse and stable Management incorporating Horse Care. 3rd edition. Blackwell Science.
- Bunger, I. und B. Hertsch (1981):* Das Gebiß des Hausesels (*Equus asinus asinus* L.) Morphologische und rontgenologische Untersuchungen. Zbl. Vet. Med. C. Anat. Histol. Embryol. 10: 61-86.
- Clair, L.E.St. (1975):* Teeth in Sissons and Grossman's. The anatomy of the domestic animals. Rev. by R. Getty. 5th ed. W.B. Saunders Company. Philadelphia, London, Toronto.
- Delahunta, A. and Habel R.E. (1986):* Applied veterinary anatomy. W.B. Saunders Company.
- Dyce, K.M.; W.O. Sack and C.J.G. Wensing (1987):* Textbook of veterinary anatomy. W.B. Saunders Company.
- El-Hagri, M.A.A. (1967):* Splanchnology of the domestic animals. 1st ed. Univ. Press, Cairo.
- Kilic, S.; P.M. Dixon and S.A. Kempson (1997):* A light microscopic and ultrastructural examination of calcified dental tissues of horses: 1- The occlusal surface and enamel thickness *Equine Vet J.*, May 29: 3, 190-197.
- Kirkland, K.d.; G.J. Baker; M.S. Manfra; J.A. Eurell and J.M. Losonsky (1996):* Effects of aging on the endodontic system, reserve crown, and roots of equine mandibular cheek teeth. *Am. J. Vet. Res.*, Jan. 57: 1, 31-38.
- Kobluk, C.N.; T.R. Ames and R.J. Geor (1995):* The horse diseases and clinical management. W.B. Saunders Company.
- Mansmann, R.A.; E.S. Mcallister and P.W. Pratt (1982):* Equine medicine and surgery. American veterinary publications. Drawer KK, Santa Barbara, California.
- Misk, N.A. and S.M. Seilem (1997):* Radiographic studies on the development of cheek teeth in donkeys. *Equine practice*. Vol. 19, No. 2. February, 27-38.

Nickel, R.; A. Schummer and E. Seiferte (1973): The viscera of the domestic animals. Verlag paul parey, Berlin, Hamburg.
 Wiggs, R.B. and H.B. Lobprise (1997): Veterinary dentistry principles and practice. Lippincott-Raven.

Table (1): Some measurements (mm) of the deciduous lower cheek teeth at different ages:

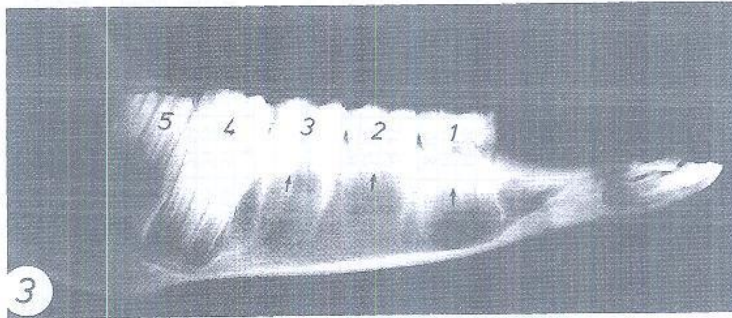
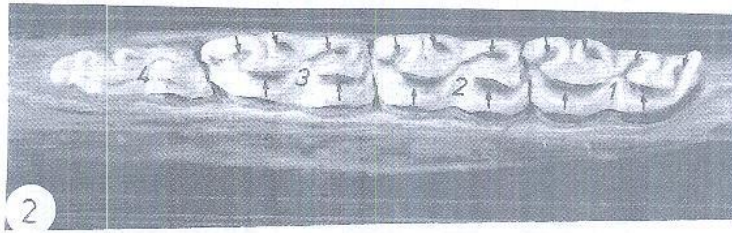
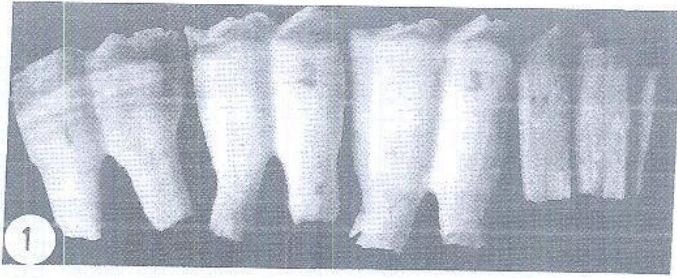
Age	1.5 months			9 months				15 months						
	P ₂	P ₃	P ₄	M ₁	P ₂	P ₃	P ₄	M ₃	P ₂	P ₃	P ₄	M ₁	M ₃	
Total length	35.46	36.50	40.52	29.48	33.14	35.40	40.01	56.59	16.63	27.08	29.01	33.56	76.78	50.94
Body length	21.34	24.01	30.76		16.99	18.88	24.51	56.59		9.34	8.70	10.76	76.78	30.94
Root length	14.12	12.49	9.76		16.15	16.52	15.50	-		17.74	20.31	22.80	-	-
Thickness at:														
Occlusal surf	10.15	9.19	8.9		10.82	12.52	11.22	8.09		12.13	13.08	12.50	9.65	6.27
The middle	11.90	11.91	10.71	8.80	9.28	12.40	11.85	10.70	7.85	11.84	12.28	12.85	12.26	11.30
The root	9.79	13.29	11.67		9.79	14.48	16.54	7.10		10.45	12.38	11.86	9.97	8.73
Breadth at:														
Occlusal surf	29.66	26.17	28.23		28.52	25.48	27.43	17.88		27.89	24.23	26.26	28.73	18.94
The middle	25.94	25.10	25.48	22.60	23.44	24.30	24.89	22.58	20.52	24.81	23.98	24.88	24.13	23.85
The root	24.80	20.46	21.46		24.70	23.70	25.38	21.81		21.31	22.45	21.06	20.18	21.64

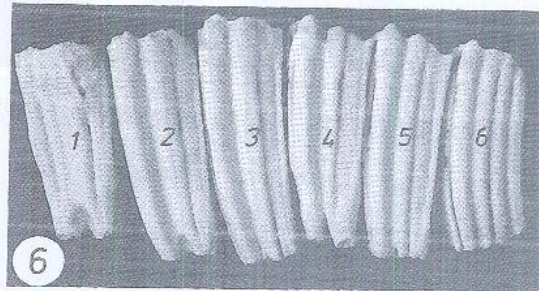
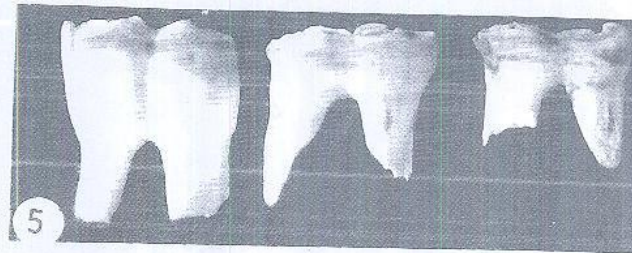

Table (2): Some measurements (mm) of the permanent lower cheek teeth at 4 and 5 years old.

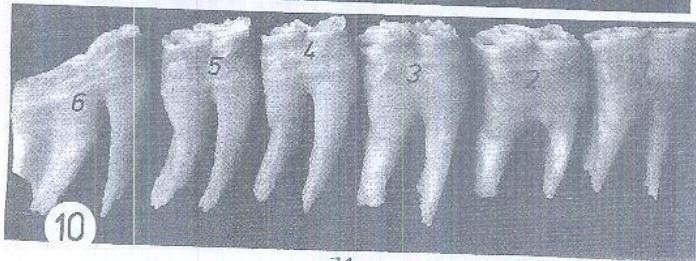
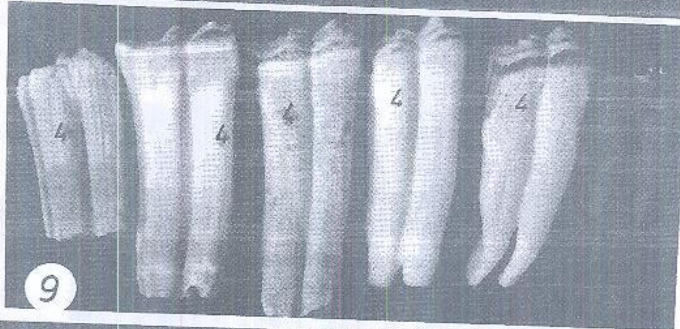
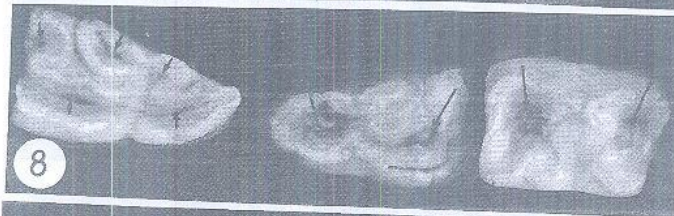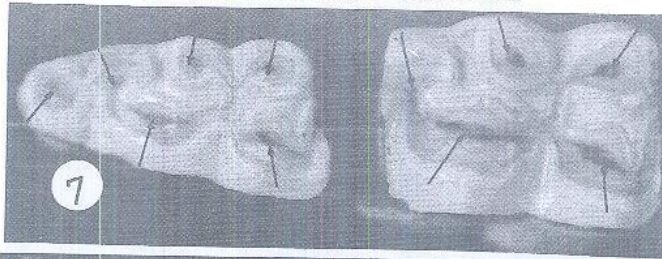
Name of tooth	Age 4 years						Age 5 years						
	P ₁	P ₂	P ₃	P ₄	M ₁	M ₂	P ₁	P ₂	P ₃	P ₄	M ₁	M ₂	M ₃
Total length	56.65	69.48	73.45	67.87	68.84	62.95	47.40	58.60	70.72	66.54	68.25	62.69	
Body length	41.94	65.57	73.45	61.14	68.84	62.95	33.89	39.88	52.46	51.08	53.71	62.69	
Root length	4.71	3.91	-	6.73	-	-	13.51	18.72	18.26	15.46	14.54	-	
Thickness at:													
Occlusal surf.	13.24	14.96	14.28	13.29	12.37	9.66	13.81	16.43	17.08	16.41	14.95	11.36	
The middle	12.89	14.39	13.19	12.40	11.75	9.30	12.80	14.33	15.20	14.73	13.34	10.48	
The root	7.08	8.30	8.76	10.11	9.80	7.05	7.14	10.42	9.62	8.37	7.60	8.01	
Breadth at:													
Occlusal surf.	25.62	24.47	23.88	20.82	23.92	21.15	25.86	23.02	22.64	22.80	21.44	25.36	
The middle	23.81	23.68	22.88	21.45	22.63	22.29	23.86	22.05	22.21	21.90	20.48	27.09	
The root	15.75	16.77	16.90	15.90	16.57	16.57	17.51	10.08	16.03	11.40	13.44	22.28	

Table (3): Some measurements (mm) of the permanent lower cheek teeth at 8 and 15 years old.

Name of tooth	Age 8 years						Age 15 years						
	P ₁	P ₂	P ₃	P ₄	M ₁	M ₂	P ₁	P ₂	P ₃	P ₄	M ₁	M ₂	M ₃
Total length	39.68	53.54	61.86	57.48	59.86	51.13	35.34	37.85	41.92	40.68	40.68	38.82	
Body length	21.93	31.59	35.20	34.50	37.62	41.87	18.93	21.48	22.22	16.10	17.35	17.45	
Root length	17.75	21.95	26.66	22.98	22.18	9.26	16.41	16.37	19.70	24.37	23.33	21.37	
Thickness at:													
Occlusal surf.	13.75	17.34	17.70	15.30	14.95	12.55	11.25	12.35	12.80	13.42	11.33	9.37	
The middle	10.97	15.14	14.89	14.28	13.81	9.00	13.37	15.93	16.33	15.85	14.61	10.26	
The root	9.43	6.97	9.32	8.02	6.24	5.62	4.45	6.28	6.93	7.04	6.36	3.82	
Breadth at:													
Occlusal surf.	22.61	23.90	23.80	21.73	21.31	27.50	20.57	21.36	20.85	19.02	19.60	26.70	
The middle	21.38	21.25	21.69	20.82	18.21	28.90	19.21	20.57	19.92	18.71	18.59	28.15	
The root	20.80	20.09	19.50	18.49	13.50	25.24	16.36	17.81	15.71	13.38	14.24	22.19	







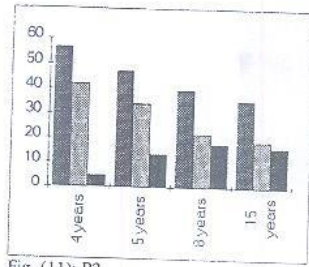


Fig. (11): P2

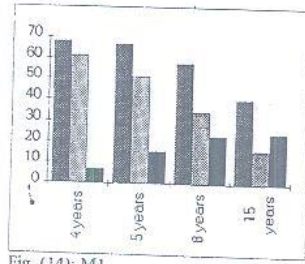


Fig. (14): M1

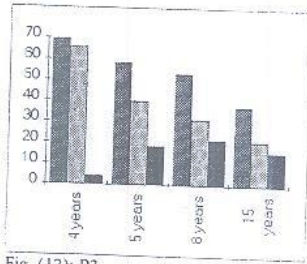


Fig. (12): P3

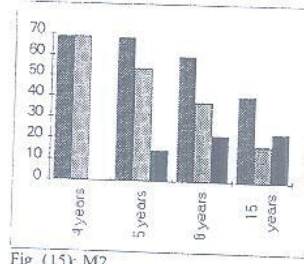


Fig. (15): M2

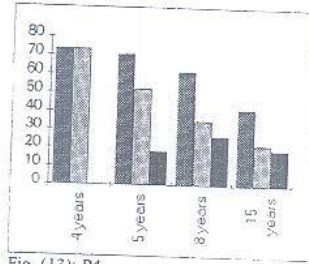


Fig. (13): P4

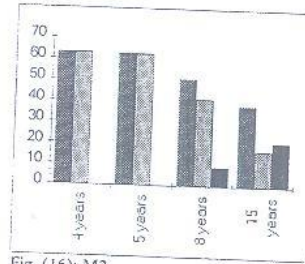


Fig. (16): M3

