

# Estimation of Sex from Hyoid Bone: A Preliminary Study with Medico-Legal Implications

Sahar M. Moustafa<sup>1</sup>

<sup>1</sup> Forensic Medicine and Clinical Toxicology Department, Faculty of Medicine, Suez Canal University, Egypt.

**Abstract** Determination of sex from analysis of human skeletal remains has been an age old problem and represents a crucial stage in any forensic study. The hyoid bone is of considerable medico-legal interest owing to its susceptibility to fracture during many forms of neck compression and is considered as a useful mean for sex estimation in forensic investigations. The aim of this study was to find out the utility of the hyoid bone in estimation of sex based on selected anthropometric parameters in a Saudi population sample. It is a prospective study on medico-legal autopsy cases in Morgue Department in Riyadh in Saudi Arabia comprised 66 Saudi cadavers (36 males and 30 females) and comprised 11 anthropometric parameters. The results showed that the values of the measured hyoid bone parameters are statistically higher in males than in females except two parameters (right and left angle of lesser cornua) and statistically higher significant difference in males than females in the measurements except four parameters (right and left maximum width of the proximal end of the greater cornua & right and left angle of lesser cornua). The maximum sexual dimorphism was recorded for the maximum body length and total hyoid length. The results revealed overall accuracy rates ranged from (63.2% in females to 93.79% in males for hyoid body length (BL) and 65.68% in females to 100% in males for total hyoid length (THL) and concluded that the hyoid bone showed sexual dimorphism.

**Keywords** sexual dimorphism, hyoid bone and Medico-legal implications

## Introduction

Identification of individual from skeletal remains by estimating age and sex is a routine procedure in forensic medicine and plays a key role in solving the medico-legal disputes. Determination of sex from analysis of skeletal remains has been an age old problem and represents a crucial stage in any forensic study, especially if it is from an isolated bone (Iscan and Steyn, 2013). The accuracy in sex determination depends on the integrity of the skeletal elements so, the possibility of collecting as much information as possible from every element available is very important. Sexual dimorphism has been quantified in numerous ways in physical anthropology based on both morphological and metric point features for most of the skeletal elements (D'Anastasio et al., 2014). Hyoid is a small bone present in the ventral aspect of neck placed between the root of tongue and the thyroid cartilage (Gig, 2003) and it is a key bone in the neck trauma (Kumar et al., 2014). Hyoid bone can be useful for identifying foul play in neck injuries in autopsy cases (Kim et al., 2006) and it can provide information about characteristics of an individual's biological profile (Jiménez-Brobeil et al., 2011). In forensic anthropology, the significance of the hyoid bone has been well recognized while the bone morphology has been used as a source of information about an individual's biological profile (Komenda and Cerny,

1990 and Kim et al., 2006) also it is known to be rather sexually dimorphic (Kindschuh et al., 2010) while it is known to bear sexually dimorphic features noticeable even from early stages of postnatal life (Scheuer and Black, 2000). To date, there have been numerous studies which have produced predictive equations for sexing human hyoids (Kindschuh et al., 2010). Previous researchers investigated the utility of the hyoid as a reliable sex indicator, but they conducted metric analyses of forensic samples indirectly through X-ray images and the accuracy of the discrimination function was variable between 69.2-88.5% (Kim et al., 2006). In a more recent study researchers attempted to obtain measurements directly from hyoid bones (Kindschuh et al., 2010). The success of sex assessment using hyoid bones is affected by the manifestation of sexually dimorphic traits within a given population (Franklin et al., 2005). However it was observed that minimal work has been done on the hyoid bone and a lesser number of studies have focused on sex determination using the characteristics of the hyoid bone in Arab countries.

## Aim of the Study

Hence the aim of this study was to find the utility of the hyoid bone in estimation of sex based on metric parameters in a Saudi population using discriminant function analysis. And best of our knowledge, this is first-ever study from Saudi Arabia on the subjects.

## Subjects and methods

**Study sample:** This study was conducted on medico-legal autopsy cases at the mortuary of the department of Forensic Medicine in Council of Forensic Medicine in Riyadh of Saudi Arabia. Ethical approval was obtained from its scientific committee. The study comprised 66 Saudi cadavers (36 males and 30 females) and all the autopsy cases were examined within 24 hours of death.

**Methods:** The hyoid bones in all the cases were carefully dissected using a V-shaped incision of the neck, extracted and removed from corpses. The inclusion criteria included intact adult hyoid bones while cases which pathologically changed, fractured and/or damaged were excluded. The hyoid bones were cleaned of soft tissues then kept in 10% formaldehyde solution for 72 hrs. plunged into alcohol solution and, once dried, kept in labeled plastic bag. Together with the actual individual's sex, age and cause of death, additional measurements such as body height and mass were taken. The selected hyoid bone measurements as described below were recorded according to their accessibility and facility on a dried bone using Neiko digital caliper graduated scale with LCD screen as illustrated in Figure 1.

### The measurements:

There are selected 11 anthropometric parameters studied according to Balseven-Odabasi et al., (2013) as illustrated in figure 2:

- 1- Length between the distal ends of the right and left greater cornua (centre point) (WCS)
- 2- Length between the distal ends of the right and left greater cornua (parietal point) (THW)
- 3- Length from the middle of the left joint space to the middle of the right joint space (across the body of the hyoid bone) (BL)
- 4- Transverse distance between bases of lesser cornua ( WCH)
- 5- Height of the body: (Width of the body of the hyoid bone at its center point (perpendicular to the surface of the bone) (BH)
- 6 & 7- Maximum width of the proximal end of the greater cornua (perpendicular to the internal surface of the bone) (right and left) (CWI)
- 8- Total hyoid length, from anterior surface of the body to the distal ends of greater horns (THL)
- 9 & 10 (+) - Angle of lesser cornua and length from the middle of the left joint space to the middle of the right joint space (across the body of the hyoid bone) (right and left)
- 11 (×) - Angle of right and left greater cornua length (long axis of greater cornua)

**Statistical analysis:** All the measurements were tabulated and statistically analyzed as mean, standard deviation and range. Paired sample t-test as well as discriminant function analysis was performed using Statistical Package for the Social Sciences (SPSS version 16, SPSS Inc., Chicago, IL, USA) to test the difference in measurements. The percentage sexual dimorphism was calculated for each measurement using this formula: percentage sexual dimorphism = mean value in males/ mean value in females X 100 and the

parameters were ranked according to percentage sexual dimorphism to establish the dimorphic order for hyoid bone measurements. ROC curve was calculated for predicting cut off point of parameters to sexual dimorphism.

### Results

In the present study, from 66 samples were collected, 36 samples (54.5%) were males while 30 samples (45.5 %) were females and the age of the autopsied cases was ranged from (21-60 years).

Table (1) revealed that, the values of all measured hyoid bone parameters are statistically higher in males than in females except two parameters [right and left angle of lesser cornua

( +)] which are statistically higher in females than in males. From the selected 11 parameters 7 parameters showed high statistical significant differences between males and females while 4 parameters showed no significant difference [Right and left maximum width of the proximal end of the greater cornua (CWI) & right and left angle of lesser cornua (+)].

Table (2) shows that the maximum sexual dimorphism was recorded for parameters no. 3& 8 [maximum body length (BL) and total hyoid length (THL)] while parameters no. 9& 10 [right and left angles of lesser cornua (+)] were least dimorphic among study population.

Table (3) shows that if the maximum body length (BL) is greater than 20.5 mm. the bone will belong to males in 93.79% of cases and if the value is less than 20.5 mm. it will be of females in 63.2% of cases. If the total hyoid length (THL) is greater than 40.17 mm. it will be of males in 100% of cases and if the value is less than 40.17 mm. it will be of females in 65.68% of cases.

**Table 1: Statistical analysis of the studied parameters of hyoid bone in males and females.**

Parameter No.	Parameter	Male		Female		Level of sig.
		Mean±SD	Range	Mean±SD	Range	
1	Length between the ends of greater cornua (center point). (WCS)	44.32±0.21	39-50	39.01±3.29	37-47	P < 0.001
2	Length between the ends of greater cornua (parietal point.) (THW)	49±0.11	41-55	42.25±4.4	39-49	P < 0.001
3	Length from the middle of the left joint space to the middle of the right joint space.(BL)	20.95 ±3.41	20 -22	18.0±3	20-21	P < 0.001
4	Transverse distance between bases of lesser cornua. (WCH)	22.31±3.14	21.5 -25	19.24±2.9	20.1-22	P < 0.001
5	Height of the body.( BH)	11.15±1.13	10 -13	10.04±1.01	9-10.2	P < 0.001
6	Right maximum width of the proximal end of the greater cornua. (CWI)	7.69±0.73	7-7.7	7.29±1.08	7.2-7.5	P > 0.05
7	Left maximum width of the proximal end of the greater cornua. (CWI)	7.57±0.84	7.2- 7.5	7.10±1.06	7.2-7.5	P > 0.05
8	Total hyoid length, from anterior surface of the body to the distal ends of greater horns (THL)	40.17±2.53	38-44	34.47±2.13	32.5-38	P < 0.001
9	Right angle of lesser cornua (+)	123.85±11.84	120-123	125.56±10.53	125-130	P > 0.05
10	Left angle of lesser cornua (+)	123.8±8.1	120-123	125.3± 4.9	125- 128	P > 0.05
11	long axis of greater cornua (×)	45.05±7.86	44- 46	43.1±10.41	40- 41	P < 0.001

Lengths measured in mm and angles in °, Sign. < 0.05, Non sign. > 0.05

**Table 2: Percentage sexual dimorphism based ranking for selected hyoid bone parameters.**

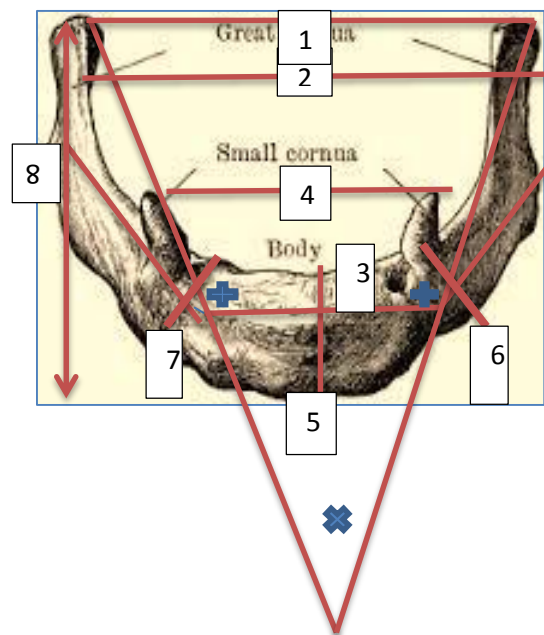
Parameter No.	Percentage Sexual Dimorphism	Rank
1	113.61	5
2	115.97	3
3	116.38	2
4	115.95	4
5	111.05	6
6	105.48	8
7	106.61	7
8	116.53	1
9	98.63	11
10	98.8	10
11	104.52	9

**Table 3: Cut off point of parameters to sexual dimorphism.**

Parameter	Mean length	Accuracy
Maximum body length (BL)	≥ 20.5	M = 93.79%
	< 20.5	F = 63.2%
Total hyoid length (THL)	≥ 40.17	M = 100%
	< 40.17	F = 65.68%



**Fig. 1: Neiko 01408A digital caliper graduated scale with LCD screen.**



**Fig. 2: Studied hyoid bone measurements (frontal view).**

## Discussion

Earlier works have shown that metric analysis of the hyoid bone is a helpful technique in sex determination of a skeleton (Reesink et al., 1999). The magnitude of sexual dimorphism is expressed to a degree which allows hyoid bone to be used as a sex predictor while assessing an individual's biological profile from skeletal remains. Previous researches estimated sex from the hyoid bone using x-ray images or digital photographs (Miller et al 1998., Komenda and C'erny, 1999 and Kim et al ., 2006) were not compared in details to the present study as these indirect method for hyoid bone measurements, do not allow for reliable comparison. The present study concluded that the measured hyoid bone parameters are statistically higher in males than in females except two parameters (right and left angle of lesser cornua) which are statistically higher in females than in males, these results are in general match reports of previous study that emphasize greater sexual dimorphism of the hyoid bone (Kindschuh et al., 2010). This was in contrast to other researches which revealed that males showed a significantly larger hyoid than females in all variables that were examined (D'Anastasio et al., 2014).

And Priya and Ranzeetha, (2015) results revealed that the male hyoids are larger than female hyoids in all 15 studied parameters and with statistically significant difference. The present results stated that right and left maximum width of the proximal end of the greater cornua & right and left angle of lesser cornua showed non-significant differences between males and females which are in agree with Mukhopadhyay (2010) results which concluded that there is no significant difference between lengths of the left and right cornu and Vohra and Kulkarni, (2017) results which revealed that all parameters was highly significant different except the width of body of hyoid which was comparatively less significant. The present results are in contrast with Kindschuh et al. (2010) and D'Anastasio et al. (2014) results which revealed that width and height of the greater cornua has statistically significance differences. The present results concluded that the maximum sexual dimorphism was recorded for maximum body length (BL) and total hyoid length (THL) which are in accordance with Miller et al. (1998) results which revealed that (BL) is the maximum sexual dimorphism and an Egyptian study which

concluded that (THL) is the maximum sexual dimorphic parameter in hyoid bone (Gad El-Hak et al., 2007) also Kindschuh et al. (2010) emphasize a greater sexual dimorphism of the maximum body height and length of the body in the transverse plane. The present results are in contrast with Agnihotri et al. (2015) results which concluded that (the perpendicular distance from midpoint of the distance between distal ends of the right and left greater cornua to midpoint of posterior aspect) is the maximum sexual dimorphic parameter. These different results indicate that some measurements are much more sexual dimorphic than others and the sexual dimorphism for hyoid bone is race specific. The present study examined the accuracy rates of discriminant functions created from the study population when applied for determination of sex from the hyoid bone, overall accuracy rates ranged from [(63.2% in females to 93.79% in males for maximum body length of the hyoid bone (BL) and 65.68% in females to 100% in males for total hyoid length (THL)] and these results are in accordance with studies which have produced predictive equations for sexing human hyoids and reported rates of accuracy ranging from 82% to 96% (Urbanová et al., 2013). In a study on Canadian white population, discriminant functions were revealed that the overall accuracy rates were between 72.1% and 92.3% with correct sex determination for white males ranged between 88.2% and 96.3%, while correct sex determination for white females ranged between 31.3% and 92.0 (Logar et al., 2016). A recent Indian study concluded that by multivariate discriminant linear functional analysis, 94% male and 85% female hyoids could be identified correctly and the total percentage of male and female hyoids is found to be 92% (Vohra and Kulkarni, 2017). The present results are in contrast with some researches on hyoid bone which reported accuracy as little as 79% for correctly classified specimens (Reesink et al., 1999). The present results concluded that the hyoid bone showed morphologically sexual dimorphism which is in accordance with Agnihotri et al. (2015) results which established the dimorphic silhouette for hyoid bone in North Indians.

#### Conclusion:

This is a humble attempt at studying the sexual dimorphism in adult hyoid bone in a population specific sample and the hyoid bone showed sexual dimorphism in the study sample. In most of the studied parameters there was a clear cut demarcation between the male and female bone values. For determining sex by using hyoid bone, single parameter may not be sufficient to predict its sex and it becomes mandatory to study all the parameters before predicting the sex of an unknown hyoid bone. This is a preliminary study, in a trial of help to design further work on hyoid bone.

#### References:

- Agnihotri G, Mahajan D and Sheth AG (2015): The Gender Based Hyoid Silhouette—A Metric Study in North Indians. *Academia Anatomica International* Vol. 1, Issue 1. 20-25.
- Balseven-Odabasi A, Yalcinozan E, Ketten A et al., (2013): Age and sex estimation by metric measurements and fusion of hyoid bone in a Turkish population. *Journal of Forensic and Legal Medicine* 20. 496-501.
- D'Anastasio R, Viciano J, Di Nicolab M et al., (2014): Estimation of sex from the hyoid body in skeletal individuals from archeological sites. *HOMO. Journal of comparative human biology* 65. 311-321.
- Franklin D, Freedman L and Milne N (2005): Sexual dimorphism and discriminant function sexing in indigenous South African crania. *HOMO*; 55:213e28.
- Gad El. Hak SA, El-Dakroory SA, El-Hawary AA et al., (2007): Sexual dimorphism of the hyoid bone, a preliminary study. *Mansoura J. Forensic Med. Clin. Toxicol.* Vol. XV, No. 1. 17-31.
- Gig WT (2003): Asphyxia. In: Payne James Jason, Anthony Busutil, Willam Smock, editors. *Forensic medicine: clinical and pathological aspect*. London: G.M.M; p. 367.
- Işcan MY and Steyn M (2013): *Textbook of The Human Skeleton in Forensic Medicine*, 3rd edition; P: 143.
- Jiménez-Brobeil SA, Al Oumaoui I, Fernández JV et al., (2011): An example of a severe neck injury with survival seen in a bronze-age burial. *Int. J. Osteoarchaeol*; 21:247-752.
- Kim DI, Lee UY, Park DK et al., (2006): Morphometrics of the hyoid bone for human sex determination from digital photographs. *J. Forensic Sci.* 51 (5), 979-984.
- Kindschuh SC, Dupras TL and Cowgill LW (2010): Determination of sex from the hyoid bone. *Am J Phys Anthropol*; 143: 279-284.
- Komenda S and Černý M (1990): Sex determination from the hyoid bone by means of discriminant analysis. *Acta Universitatis Palackianae Fac Med Olomouensis* 125, 37–51
- Kumar P, Tambe SV, Rahule AS et al., (2014): Morphology of Hyoid Bone with its Forensic Implication *J Cont. Med. A Dent* May-August, Volume 2 Issue 2. 4- 8.
- Logar CJ, Peckmann TR, Meek S et al., (2016): Determination of sex from the hyoid bone in a contemporary White population. *Journal of Forensic and Legal Medicine* 39, 34-41.
- Miller KW, Walker PL and O'Halloran RL (1998): Age and sex related variation in hyoid bone morphology. *J Forensic Sci.* 1998; 43(6):1138-43.
- Mukhopadhyay PP (2010): Morphometric features and sexual dimorphism of adult hyoid bone: A population specific study with forensic implications. *Journal of Forensic and Legal Medicine* 17, 321-324.
- Priya SK and Ranzeetha D (2015): Determination of Sex from Morphometry of Hyoid Bone. *Indian Journal of Clinical Anatomy and Physiology*; 2(3):157-161.
- Reesink EM, Van Immerseel AH, Brand R et al., (1999): Sexual dimorphism of the hyoid bone. *Int. J. Osteoarchaeol.* 9:957e60.
- Scheuer L and Black S (2000): *Developmental juvenile osteology*. London, UK: Elsevier.Ltd.
- Urbanová P, Hejna P, Zátoková L et al., (2013): The morphology of human hyoid bone in relation to sex, age and bodyproportions. *HOMO. J. Comp. Hum. Biol.* 64, 190–204.
- Vohra P and Kulkarni P (2017): Sexual dimorphism of human hyoid bone. *Int J Anat Res*, Vol 5(1):3607-10. ISSN 2321-4287

## الملخص العربي

### تقدير الجنس من العظم اللامي : دراسة مبدئية ذات دلالات طبية شرعية

سحر محمد علي مصطفى<sup>١</sup>

يعتبر تحديد الجنس من تحليل بقايا الهيكل العظمي البشري مشكلة قديمة إلى حد ما، ويمثل مرحلة حاسمة في أي دراسة طبية شرعية . و يعتبر العظم اللامي ذو أهمية طبية شرعية كبيرة بسبب قابليته للكسر خلال العديد من أشكال الضغط على الرقبة كما يعد وسيلة مفيدة لتحديد الجنس في تحقيقات الطب الشرعي. كان الهدف من هذه الدراسة هو تقدير فائدة العظم اللامي في تقدير الجنس إستنادا إلى بعض القياسات الأنثروبومترية المختارة في عينة من السكان السعوديين في دراسة إستطلاعية على حالات الصفة التشريحية الطبية في مشرحة الطب الشرعي في الرياض في المملكة العربية السعودية و قد ضمت الدراسة ٦٦ جثة سعودية (٣٦ من الذكور و ٣٠ من الإناث)، وقد خضعت الجثث لإحدى عشر قياسا أنثروبومتريا. وقد أظهرت نتائج العينة أن جميع القياسات قد سجلت قيما أعلى إحصائيا في الذكور منها لدى الإناث بإستثناء قياسين (الزاوية اليمنى واليسرى من القرن الأصغر للعظم اللامي). وقد أظهرت القياسات إختلافا إحصائيا عاليا بين الذكور والإناث بإستثناء أربعة قياسات ( أقصى عرض بين النهاية القريبة للقرن الأكبر يمينا و يسارا والزاوية اليمنى واليسرى من القرن الأصغر للعظم اللامي). كما أوضحت النتائج أن كلا من طول الجسم و الطول الكلي للعظم اللامي سجلتا أعلى درجات الإزدواجية الجنسية. كما أظهرت النتائج أن معدلات الدقة الكلية تراوحت بين (٦٣.٢٪) لدى الإناث و (٩٣.٧٩٪) لدى الذكور بالنسبة لطول جسم العظم اللامي و (٦٥.٦٨٪) للإناث إلى (١٠٠٪) للذكور في الطول الكلي للعظم اللامي و قد خلصت النتائج إلى أن العظم اللامي يتمتع بالإزدواجية الجنسية.

١ قسم الطب الشرعي و السموم الإكلينيكية، كلية الطب - جامعة قناة السويس