



COMPARISON OF USING PLATELETS RICH FIBRIN VERSUS MINERALIZED PLASMATIC MATRIX PLATELETS CONCENTRATES AFTER SURGICAL EXTRACTION OF LOWER THIRD MOLAR

Ahmed Adel Abd Elrahiem Mohammed El Kordy ^{1*}, Ahmed Ahmed Hussine Elfekey ²,
Mohammed Abd Elsalam Khalil ³

ABSTRACT

Objectives: this current study attempted the evaluation of the effect of using platelets rich fibrin and mineralized plasmatic matrix platelets concentrates after surgical extraction of lower third molar. **Subjects and Methods:** A total of 40 requiring extraction of at least one mandibular non-restorable impacted wisdom tooth. (n=40). The samples were divided into two main groups (20 each) (Group A) extraction of mandibular impacted wisdom tooth and socket was filled using platelets rich fibrin (PRF) and (Group B) extraction of mandibular impacted wisdom tooth with application of mineralized plasmatic matrix (MPM) and platelet-rich fibrin for socket preservation. Participants were evaluated at 1st, 3rd and 7th day, 6 months postoperative. Data were statistically analyzed using IBM SPSS software version 20.0. (Armonk, NY: IBM Corp). **Results:** This study showed at 7th day, MPM group showed a significant higher maximum mouth opening measurement than PRF group. At 6 months, postoperatively MPM group showed a significant higher bone density measurement than PRF group and showed a less percentage of change in density measurement than PRF group. **Conclusion:** MPM not only enhances the rate of new bone formation, but also increases the quality (density) of the newly formed bone.

KEYWORDS: Mineralized plasmatic matrix, platelet rich fibrin and third molar impaction.

INTRODUCTION

Surgical removal of impacted mandibular third molars is one of the most commonly performed dentoalveolar surgeries by oral and maxillofacial surgeons and dental surgeons around the globe. It is known to be associated with clinically significant postoperative morbidity including swelling, pain, trismus, fever, and infection. The surgical removal of the mandibular third molar involves reflection of the mucoperiosteal flap for access, removal of

overlying bone, sectioning the tooth (odontectomy), delivery of the tooth, debridement of the socket, and closure of the soft tissue flap. This leads to a significant surgical insult resulting in postoperative inflammatory response ranging from pain and swelling to acute trismus, fever, etc. In some cases, other less frequent complications, e.g., infection, nerve damage, have also been reported. In addition, the residual bony defect takes several months to a year to gradually fill with bone and to reossify ⁽¹⁾.

1. Masters Candidate, Health Insurance Organization.
2. Assistant Professor, Department of Oral and Maxillofacial Surgery, Faculty of Dental Medicine, Boys, Cairo, Al-Azhar University.
3. Professor, Department of Oral and Maxillofacial Surgery, Faculty of Dental Medicine, Boys, Cairo, Al-Azhar University.

• **Corresponding author:** ahmedelkordys4@gmail.com

The importance of growth factors in enhancing wound healing has become the focus of research in the present day. Three key elements, namely scaffolds (collagen, bone mineral, etc.), signaling molecules (growth factors), and cells (osteoblasts, fibroblasts) facilitate regeneration of particular tissues during the healing process, particularly in the reossification of bony defects and cavities⁽¹⁾.

Platelet-rich fibrin (PRF) is a second-generation platelet concentrate yielding fibrin membranes enriched in platelets and growth factors, made using anticoagulant-free blood. Platelet-rich fibrin preparation is thus very simple, requiring no anticoagulant, bovine thrombin, or any other gelling agent. The data on the biologic properties of PRF in terms of bone regeneration, however, are sparse. In searching for regenerative biomaterials that afford both biological and mechanical properties and resolve the drawbacks of titanium mesh and bone blocks exposure, mineralized plasmatic matrix (MPM) was developed. The MPM preparation features the simplicity of the PRF protocol, however, yields a liquid platelet/fibrin concentrate that can become bound to bone particles⁽²⁻⁴⁾. This study aims to evaluate the effect of using platelets rich fibrin and mineralized plasmatic matrix platelets concentrates after surgical extraction of lower third molar.

SUBJECTS AND METHODS

A total of 40 patients requiring extraction of at least one mandibular non-restorable impacted wisdom tooth, aged between 20 and 35 years, with no preexisting medical conditions and with no active pathology associated with the third molars. Heavy smokers, patients with bad oral hygiene or with any local or systemic factor that affect bone healing were excluded. Enrolled patients were selected from outpatient clinics of the Department of Oral and Maxillofacial Surgery, Faculty of Dental Medicine, Boys, Cairo, Al-Azhar University and signed written consent form, following providing them with nature of the study.

The sample size was divided into 2 groups; (Group A) extraction of mandibular impacted wisdom tooth and socket was filled using platelets rich fibrin (PRF); and (Group B) extraction of mandibular impacted wisdom tooth with application of mineralized plasmatic matrix (MPM) and platelet-rich fibrin for socket preservation.

Preoperative assessment:

Clinical evaluation: Full medical history was taken, and dental examination was done for each patient. Swelling (edema) was recorded clinically using a modification of the tape measure method.

Radiographic evaluation: Preoperative panoramic x-ray. Bone densitometry: Cone beam computed tomography (CBCT) radiograph was taken (to evaluate the density of the patient’s bone) as in Fig.1.

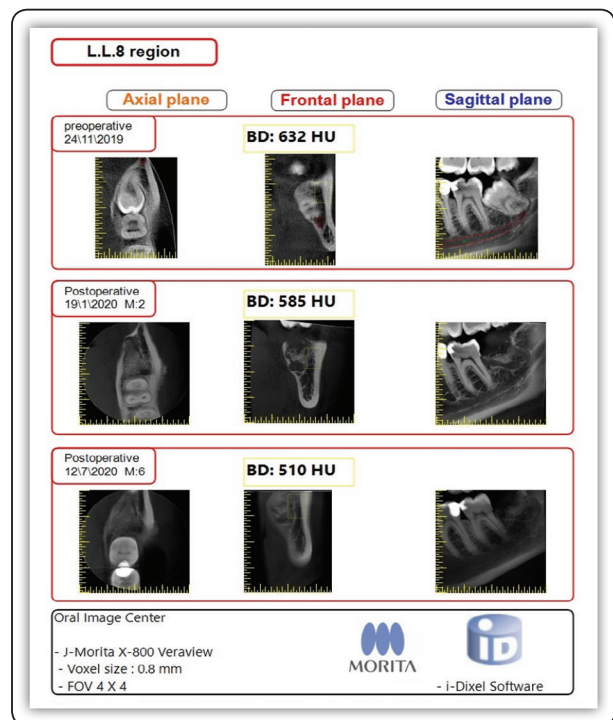


FIG (1) CBCT show bone density at different intervals with the same parameters.

Interventions:

Mandibular and buccal blocks have been administered using articaine containing 1:100,000 epinephrine. Horizontal and vertical incisions have been performed and a full-thickness mucoperiosteal flap has been raised. Tooth sectioning has been done. After tooth Extraction the socket has been thoroughly irrigated and freed from pathological tissue (e.g. granulation tissue), follicular remnants and bony spicules using a sharp curette and bone file. 28ml of blood has been collected from the patient without anticoagulant in 7ml tubes (4 tubes), 2 PRF tubes and 2 plain tubes. Then immediately centrifuged at 3000 rpm (approximately 400g according to Chokroun's calculations) for 10 min⁽³⁾.

PRF preparation:

In the PRF tubes fibrinogen is at first concentrated in the upper part of the tube, until the effect of the circulating thrombin transforms it into a fibrin network. Fibrinogen is initially concentrated in the high part of the tube, before the circulating thrombin transforms it into fibrin. A fibrin clot is then obtained in the middle of the tube, just between the red corpuscles at the bottom and acellular plasma at the top. Platelets are theoretically trapped massively in the fibrin meshes. The clot is removed from the tube and the attached red blood cells scraped off and discarded. The PRF clot is then placed on the grid in the PRF Box and covered with the compressor and lid. This produces an inexpensive autologous fibrin membrane in approximately one minute. The PRF Box was devised to produce membranes of constant thickness that remain hydrated for several hours and to recover the serum exudate expressed from the fibrin clots which is rich in the proteins vitronectin and fibronectin. The exudate collected at the bottom of the box may be used to store autologous grafts. After removing the cover of PRF box 2 membranes obtained from 2 PRF clots. With a specific tweezers the PRF was inserted in the extraction site. Edges of the mucosa were approximated to each other and

sutured using 3-0 Monocrylsutures. Healing was uneventful, and the patient was followed up for 4 months postoperatively, making sure to enforce oral hygiene and rinsing with chlorhexidine 0.12%⁽⁵⁾ as in Fig.2.

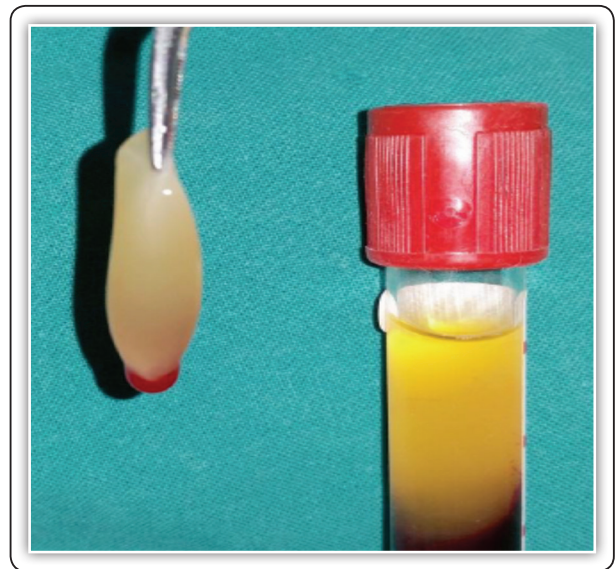


FIG (2) PRF tube.

MPM preparation:

After 10 minutes of centrifugation the 2 plain tubes present 2 layers, 1st layer is the RBC's in the bottom of the tube then in the upper portion an amount of clear yellow plasma rich in leukocytes, platelets, mesenchymal stem cells and fibrinogen. This happens due to the difference in density between all blood components. The 2nd layer is then mixed with the bone grafting material (A mix of 30% hydroxyapatite and 70% Tri calcium phosphate small granules manufactured by POLYSTOM) and a drop of patient blood from the extraction socket to provide the thrombin which will initiate the conversion of insoluble fibrinogen into soluble fibrin and all mixed together in a sterile bowl. After a couple of minutes a homogenous mixture of fibrin network with integrated bone graft particles inside and the mixture is rich of platelets, leukocytes. The MPM, which has been obtained, is placed in the extraction site⁽⁵⁾.

Post-operative assessment:

Clinical evaluation:

All patients have been given instructions on the importance of maintenance of oral hygiene and jaw physiotherapy post-operatively. Postoperatively, clindamycin 300 mg twice daily, Acetaminophen 500 mg as needed and chlorhexidine mouthwash three time daily have been administered to all patients for a week. Healing: Wound status e.g.: Dehiscence or inflammation.

Pain were assessed during the 1st, 3rd and 7th day postoperative using visual analog scales (VAS) ranging from 0cm (absence of pain) to 10cm (most severe pain) in conjunction with a graphic rating scale. After surgery, the patients have been instructed to note their postoperative discomfort and/or pain on the scale.

Maximum mouth opening were evaluated during the 1st, 3rd and 7th day postoperative by measuring the distance between the mesial incisal corners of the upper and lower right incisors during maximum mouth opening.

Edema was recorded clinically during the 1st, 3rd and 7th day postoperative using a modification of the tape measure method. The evaluation of the facial swelling was done by using a horizontal and vertical guide. For horizontal guide two points marked at the ear tragus and buccal comissura, and the distance between them was measured and recorded. The same procedure was performed for vertical guide at lateral chantus of the eye and gonion.

Radiographic evaluation:

Bone densitometry: CBCT radiograph was taken at interval 2 months and then 6 months after extraction. All the radiographic measurements were performed by one examiner using the Morita software with the same parameters (fields of view and Voxel size) as in fig.1.

Data were analyzed using IBM SPSS software package version 20.0. The Kolmogorov-Smirnov

test was used to verify the normality of distribution. Chi-square test for categorical variables. Student t-test for normally distributed quantitative variables. ANOVA with repeated measures for normally distributed quantitative variables, to compare between more than two periods and Post Hoc test (Bonferroni adjusted) for pairwise comparisons. Mann Whitney test for abnormally distributed quantitative. Significance variables of the obtained results were judged at the 5% level.

RESULTS

The results were evaluated based on clinical observation and radiographic analysis of the recorded data. Twenty patients ranged in age between 21–35 years with a mean age of 29.70 ± 4.49 years for MPM group and 22–35 years with a mean age 30.10 ± 3.60 years for PRF group. Moreover, MPM group had 10 males and 10 females, while PRF group had 11 males and 9 females, so there was statistically non-significant difference between the two groups regarding to the mean of age and gender.

Figure (3) shows MPM and PRF group had a statistically significant decrease in mean pain measurements at 3rd day and at 7th day. Figure (4) shows comparison between the two studied groups according to pain where 1st day, 3rd day and at 7th day, there was a statistically non-significant difference in mean pain between the two groups.

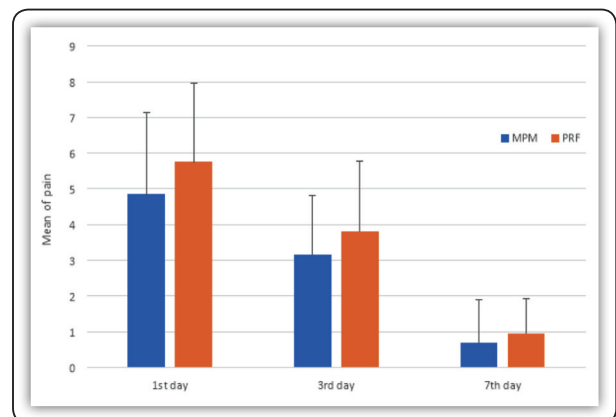


FIG (3) Comparison between the two time periods in each group according to pain

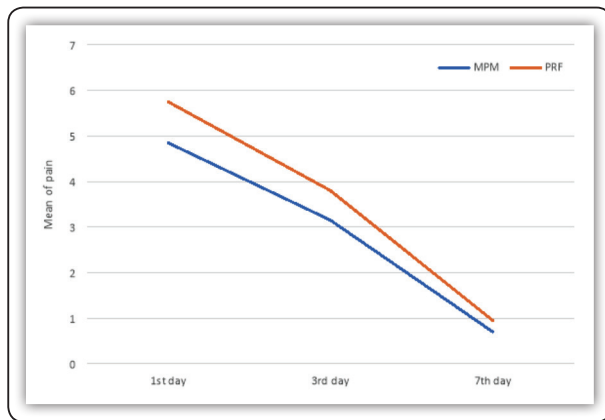


FIG (4) Comparison between the different studied groups according to pain

As regards maximum mouth opening, MPM and PRF group showed a statistically significant decrease in mean measurements at 1st day, 3rd day and increase at 7th day. At 1st day and 3rd day: there was a statistically non-significant difference in mean maximum mouth opening between the two groups while at 7th day: there was a statistically significant difference in mean maximum mouth opening between the two groups. MPM group showed a higher maximum mouth opening measurement than PRF group Table (1).

TABLE (1): Comparison between the two studied groups according to maximum mouth opening

	MPM (n = 20)	PRF (n = 20)	U	p
	Mean ± SD	Mean ± SD		
Maximum mouth opening				
1st day	37.45 ± 0.83	37.50 ± 0.89	202.50	0.947
3rd day	31.45 ± 5.24	28.70 ± 6.97	164.0	0.341
7th day	36.10 ± 2.20	33.80 ± 2.40	56.5*	<0.001*

U: Mann Whitney test

p: p value for comparing between the studied groups

*: Statistically significant at p ≤ 0.05

As regards density, PRF and MPM group showed a statistically significant decrease in mean density

measurements at 2 and 6 months table .Pre: there was a statistically non-significant difference in mean density between the two groups while at 2 months: there was a statistically non-significant change in mean density between the two groups. MPM group showed a non-significant less percentage of change in density measurement than PRF group. At 6 months: there was a statistically significant change in mean density between the two groups. MPM group showed a less percentage of change in density measurement than PRF group table (2).

TABLE (2): Comparison between the two studied groups according to density

	PRF (n = 20)	MPM (n = 20)	Test of Sig.	p
	Mean ± SD	Mean ± SD		
Density				
Pre	684.9 ± 156.9	594.6 ± 157.7	t=1.815	0.077
2 months	460.5 ± 167.8	425.0 ± 111.8	t=0.787	0.437
6 months	367.0 ± 172.1	387.6 ± 137.3	5.457*	<0.001*
% Ch. from pre to				
2 months	32.44 ± 18.19	27.88 ± 9.27	U=169.0	0.414
6 months	45.64 ± 21.62	34.90 ± 18.89	6.423*	<0.001*

t: Student t-test

U: Mann Whitney test

p: p value for comparing between the studied groups

DISCUSSION

Mandibular third molars are the most frequently impacted teeth (6,7). Their surgical removal is often accompanied by pain, swelling, trismus and general oral dysfunction during the healing phase (8). The aim of this study was to evaluate the effect of using platelets rich fibrin and mineralized plasmatic matrix platelets concentrates after surgical extraction of lower third molar.

In the present study, on the seventh post-operative day, sutures were removed, good gingival healing was found, no signs of infection or inflammation and no wound dehiscence were found in any patient. At 1st day, 3rd day and 7th day: there was a statistically non-significant difference in mean pain between the two groups.

Relief of postoperative pain is an essential criterion in the overall success of tooth extraction. In addition, most of the potential postoperative complications are in fact manifested as pain. In the present study, the degree of pain was measured using the VAS and the number of analgesic tablets taken for pain relief. This study revealed that PRF significantly reduced postoperative pain and analgesic consumption following surgical removal of impacted third molars. This, although could not be detected clinically, could reflect a better and faster healing of the extraction sockets. This is in agreement with other studies ^(9,10).

At 1st day and 3rd day: there was a statistically non-significant difference in mean maximum mouth opening between the two groups. At 7th day: there was a statistically significant difference in mean maximum mouth opening between the two groups. MPM group showed a higher maximum mouth opening measurement than PRF group.

At 6 months: there was a statistically significant difference in mean density between the two groups. MPM group showed a higher density measurement than PRF group. MPM group showed a less percentage of change in density measurement than PRF group.

There is no consensus regarding the accuracy of CBCT for density measurement. CBCT is not an adequate tool for this type of evaluation because the intensity values of CBCT are influenced by the characteristics of the system and by the scanned object ⁽¹¹⁾. The density changes in radiographic techniques are based on the darkness and brightness of images, expressed with Hounsfield Unit in CT scan

and with gray scale in CBCT. Gray scales are not the same in various devices. So far, CBCT manufacturers have not introduced a standard system for displaying gray scale. HU is a standard scheme for measuring CT values in CT scan. There was a strong linear relationship between HU and gray scale ⁽⁹⁾. There is a close linear correlation consented to determine the conversion ratio to transform the gray density values of CBCT to that of CT (HU). In the present study, the conversion ratio was approximately 0.7 (0.7 x values of CBCT = values of CT) ⁽¹²⁾.

Platelet-rich fibrin is characterized by the slow polymerization during its preparation that generates a fibrin network very similar to the natural one that enhances cell migration and proliferation. Being a reservoir of platelets, leukocytes, cytokines and immune cells, PRF is reported to allow slow release of cytokines; TGF, PDGF, VEGF, and EGF which play a critical role on angiogenesis and tissue healing and cicatrization ^(1, 2, 4). PRF also reported to enhance angiogenesis, support immunity, and to enhance the coverage of injured tissues through its positive effect on epithelial cells and fibroblasts ⁽¹⁾.

This finding is in agreement with Girish et al. ⁽¹³⁾, who conducted a study to evaluate bone regeneration in extraction sockets with autologous PRF. They observed accelerated soft tissue healing at all test sites treated with PRF compared with the control sites. The soft tissue parameters assessed qualitatively were post-operative swelling, trismus, erythema, pus formation and wound dehiscence in the first week of extraction. Also, Kumer et al. ⁽¹⁰⁾, who conducted a study to evaluate the treatment outcome after impacted third molar surgery with the use of PRF, concluded that the application of PRF lessened the severity of immediate post-operative sequelae. This is in agreement with the findings of Singh et al. ⁽¹⁴⁾, who found in their study that PRF has significantly improved soft tissue healing, bone regeneration and increase in bone density in extraction sockets.

Also, Girish et al.⁽¹³⁾ found in their study a definite improvement in the regeneration of bone after third molar surgery in cases treated with PRF as compared to the control group post-operatively. They also stated that this increase in the bone density signifies and highlights the use of PRF, certainly as a valid method in accelerating hard tissue regeneration.

The MPM is prepared by a single spin using empty tubes without neither anticoagulant nor clot activator. At the end of the centrifugation, the superior part of the tube will contain the fibrinogen, platelets, and monocytes⁽¹⁵⁾. This part stayed in liquid, which permit the mixture with the bone. This liquid will be collected and added to the bone graft, or the bone substitute before it coagulates. Once this plasma is in contact with the calcium of the bone graft, the activation will start and the transformation of the Fibrinogen into fibrin network will begin. This characteristic is very important because it allowed us to obtain a one homogenous component which contains the bone graft inside, the fibrin network, the growth factors, and cells. This is all the importance of the MPM. While Since the MPM shows a sticky and homogenous component. So, once the bone particles or the bone graft is placed on the site, it will stick to the site. Therefore, the fibrin act as fibrin glue and this way the whole mass of the MPM will not move. This will keep the spaces which are for the bone formation. In addition to the bone particles are linked together by a strong fibrin network. So, the scaffolding is secured⁽¹⁶⁾.

Since the stability and the scaffolding are secured by the MPM, this will play a very important role in the bone regeneration. In addition to that, the MPM contains some cells such as platelets which add the growth factors or the cytokines, and the monocytes that play an important role in the regulation of the natural BMP⁽¹⁶⁾.

The use of MPM in periodontology and implant therapy seems to have a great impact in the outcome of the grafting surgery. It allows the conduction

and homogenization of the grafting materials⁽¹⁷⁾. Therefore, the use of MPM in periodontology and implant therapy has a great impact in the outcome of the grafting surgery because it enhances transport of the material by securing its implementation⁽¹⁸⁾.

Lee et al.⁽¹⁹⁾, reported that the use of platelet enriched fibrin glue, a similar preparation to MPM, results in a statistically significant amount of bone gain. This result agreed with our study, where a new concept of fabricating growth factors-enriched bone graft matrix has been introduced, this offers the MPM the positional stability by stabilizing the bone particles, preserving its shape with subsequent "in situ" immobilization of the component of ridge preservation materials and this was the logical evolution of the fibrin glues function to incorporate platelets within the products⁽²⁰⁾.

However, an interesting finding was that although the study group showed to be more significant in bone density after 6 months. This means that the mean bone density is significantly higher in the MPM group. This could be attributed to the fact that the fibrin matrix in which the bone graft is suspended has osteoconductive properties. These findings agreed with Perissé⁽¹⁵⁾, revealed production of BMPs which are highly important proteins in the induction of bone production.

CONCLUSION

MPM not only enhances the rate of new bone formation, but also increases the quality (density) of the newly-formed bone. MPM can be very effective for reconstruction of bony defects. Based on the structure of the MPM, this product should be considered every time a bone grafting procedure is approached. However, more well designed and properly controlled comparative studies are needed to provide solid evidence of MPM capacity to improve wound healing, bone augmentation procedures, and soft tissue reconstruction.

REFERENCES

1. Choukroun J, Diss A, Simonpieri A, Girard MO, Schoeffler C, Dohan SL, et al. Platelet-Rich Fibrin (PRF): A second-generation platelet concentrate. Part IV: Clinical effects on tissue healing. *Oral Surg Oral Med Oral Pathol Oral Radiol Endod* 2006; 101: 56-60.
2. Dohan DM, Choukroun J, Diss A, Dohan SL, Dohan AJ, Mouhyi J, Gogly B. Platelet-rich fibrin (PRF): a second-generation platelet concentrate. Part I: technological concepts and evolution. *Oral Surg Oral Med Oral Pathol Oral Radiol Endod* 2006 Mar; 101(3): 37-44.
3. Choukroun J, Diss A, Simonpieri A, Girard MO, Schoeffler C, Dohan SL, Dohan AJ, Mouhyi J, Dohan DM. Platelet-rich fibrin (PRF): a second-generation platelet concentrate. Part V: histologic evaluations of PRF effects on bone allograft maturation in sinus lift. *Oral Surg Oral Med Oral Pathol Oral Radiol Endod* 2006 Mar; 101(3):299-303.
4. Dohan DM, Choukroun J, Diss A, Dohan SL, Dohan AJ, Mouhyi J, Gogly B. Platelet-rich fibrin (PRF): a second-generation platelet concentrate. Part II: platelet-related biologic features. *Oral Surg Oral Med Oral Pathol Oral Radiol Endod* 2006 Mar; 101(13): 45-50.
5. Ahmed Halim Ayoub, Dr Omneya R Ramadan. Comparative study socket preservation using PRF and MPM platelets concentrates. *Int J Pre Clin Dent Res* 2015; 2(1):1-4.
6. Kim J. Cone beam computed tomography findings of ectopic mandibular third molar in the mandibular condyle. *Imaging Sci Dent*. 2011; 41: 135-7.
7. Avendaño C, García P, Castellón V, Aytés B, Escoda G. Morbidity of third molar extraction in patients between 12 and 18 years of age. *Medicina Oral Patologia Oral Cir Bucal*. 2005; 10: 422-31.
8. Susarla S, Blaeser B, Magalnick D. Third molar surgery and associated complications. *Oral Maxillofac Surg Clin North Am*. 2003; 15: 177-86.
9. Marenzi Gaetano, Riccitiello Francesco, Tia Mariano, Lauro Gilberto, Sammartino Gilberto. Influence of leukocyte- and platelet-rich fibrin (L-PRF) in the healing of simple postextraction sockets: a split-mouth study. *BioMed Res Int* 2015; 2015:369273.
10. Kumar Nilima, Prasad Kavitha, Ramantujam Laitha, Ranganath Jayashree, Dexith Jayashree, Chauhan Abhishek. Evaluation of treatment outcome after impacted mandibular third molar surgery with the use of autologous platelet-rich fibrin: a randomized controlled clinical study. *J Oral Maxillofac Surg* 2015; 73 (6):1042-9.
11. Razi T, Niknami M, Alavi Ghazani F. Relationship between Hounsfield Unit in CT Scan and Gray Scale in CBCT. *J Dent Res Dent Clin Dent Prospects*. 2014; 8:107-10.
12. Cassetta M, Stefanelli L, Pacifici A, Pacifici L, Barbato E. How accurate is CBCT in measuring bone density? A comparative CBCT-CT in vitro study. *Clin Implant Dent Relat Res*. 2014; 16:471-8.
13. Girish Rao S, Bhat P, Nagesh KS, Rao GH, Mirle B, Kharbhari L. Bone Regeneration in Extraction Sockets with Autologous Platelet Rich Fibrin Gel. *J Maxillofac Oral Surg*. 2013; 12: 11-6.
14. Singh A, Kohil M, Gupta N. Platelet rich fibrin: a novel approach for osseous regeneration. *J Maxillofac Oral Surg*. 2012; 11: 430-4.
15. Perisse J, Alami HB, Vassalaky LM, Caveriviere P, Betito M, Marchou M. Aspect clinique et histologique des Matrices Plasmatisques Minéralisées (MPM). *Revue d'implantologie*. 2012:23-5.
16. Omar OM, Graneli C, Ekstrom K, Karlsson C, Johansson A, Lausmaa J, Wexell CL and Thomsen P. The stimulation of an osteogenic response by classical monocyte activation. *Biomaterials*. 2011;32: 190-204.
17. J. Perisse, "Du PRF et PRP vers les Matrices Plasmatisques Mineralisees (MPM) en implantologie," *Implantologie*. 2011; 63-69.
18. L. I. Mazzoni and J. Perisse, "Apports de la microscopie electronique à balayage pour la Matrice Plasmatisque Mineralisee," *La Lettre de la Stomatologie*. 2011; 51.
19. Lee HJ, Choi BH, Jung JH, Zhu SJ, Lee SH, Huh JY. Maxillary sinus floor augmentation using autogenous bone grafts and platelet-enriched fibrin glue with simultaneous implant placement. *Oral Surg Oral Med Oral Pathol Oral Radiol Endod*. 2007; 103:329-33.
20. DohanEhrenfest DM, Bielecki T, Jimbo R, Barbé G, Del Corso M, Inchingolo F. Do the fibrin architecture and leukocyte content influence the growth factor release of platelet concentrates? An evidence-based answer comparing a pure platelet-rich plasma (P-PRP) gel and a leukocyte-and platelet-rich fibrin (L-PRF). *Curr Pharm Biotechnol*. 2012; 13:1145-52.