College of Agriculture and Veterinary Medicine,
King Saud University, Cassim Branch
Saudi Arabia

ABNORMAL VAGINAL PROJECTIONS CAUSING INFERTILITY IN THE CAMEL (CAMELUS DROMEDARIUS)

(With One Table and 2 Figures)

By

SHEIK E.A. ABDEL RAHIM

(Received at 1/6/1996)

بروزات مهبلية مسببه للعقم فى الجمال

شيخ الدين عوض

أجريت هذه الدراسة للتعرف على بعض البروزات المهبلية التى تسبب العقم فى الابل بمنطقة القصيم بالمملكة العربية السعودية. وقد تم فحص هذه الأجزاء فى الحيوانات المصابة بالمزارع ومسلخ بريدة المركزى. كما تمت دراسة الأنسجة المكونة لتلك الأجسام مجهريا. دلت النتائج على وجود البروزات المهبلية فى النوق التى تعانى من العقم فى المزارع وتلك التى تذبح فى المسالخ بنسبة ١٢٪ و ٢٠ ٪ على التوالى. إزالة البروزات وتلقيح النوق أدت آلى حدوث الحمل، وعلى ضوء هذه النتائج أقترح أن البروزات ربما كانت تعيق حدوث عملية التلقيح ومن ثم التبويض والحمل فى النوق.

SUMMARY

In an ongoing survey on the different factors causing infertility in camels an abnormal vaginal growth was noticed in animals known to be infertile. Clinical examination revealed projections on the dorsal part of the posterior vagina. An investigation of the incidence in camel farms and the slaughter house indicated 20% and 12% of the examined females respectively. All the animals affected were in a body condition score > 3. Histological picture of the growth was much like the ordinary structure of the vagina. Removal of these projections resulted in conception, and it is postulated that, they could be interfering with insemination and/or semen deposition and ovulation.

Key words: *Camels-Infertility-Vaginal projections*

INTRODUCTION

In most of the major camel farms in the tropics there are problems of infertility of unknown origin (Abdel Rahim & Nazeir, 1990). Reduced fertility in camels results in long calving intervals, protracted post-partum anoestrus and limited breeding season (Evans and Pauys, 1979). In an on-going survey of the factors causing infertility in camels, abnormal vaginal projections were noticed on the dorsal part of the posterior vagina in camels considered infertile. However, the nature of such abnormal growth in camels, its causes and effect on the breeding female is not known. There is also no publoshed information to indicate what proportion of barren she camels fail to breed because of such physical abnormalities of the genital tract.

The present study describes for the first time the incidence and type of abnormal vaginal growth observed in camel farms and abattoirs in Gassim district of Saudi Arabia.

MATERIAL and METHOD

Camel farms in the study area were visited regularly during the breeding season (November- April) to examine animals with low fertility. Clinical examination of the animals considered by the owners to be infertile revealed the presence of projections on the dorsal part of the posterior vagina. Those projections were removed in 12 camels by using a simple surgical technique. All the females were served by mature fertile males during oestrus. Twenty one other animals considered normal after examination (without projections) were also served. The sexual state of the ovaries and uterus was examined by rectal examination. A survey of 32 camels slaughtered as infertile in the local abattoirs was also carried out to find out the presence of such abnormal vaginal growth. A small piece of the vagina including the protrusion was removed and fixed in 10% formaldehyde solution, processed, sectioned at 5 um and stained with Hematoxylin and Eosin for histopathological studies.

RESULTS

Figure I shows the abnormal vaginal projections on the dorsal part of the posterior vagina in an infertile she camel. Table I shows the reproductive performance of camels affected by abnormal vaginal projections (AVP). All the 12 camels served following removal of those projections conceived and were confirmed pregnant on rectal examination.

Incidence of the animals affected by the abnormal vaginal growth both in the farms and slaughter houses were 20% and 12% of the examined females respectively. All the animals which had abnormal vaginal growth were in a body condition score >3 (see Abdel Rahim and Nazeir, 1990) and had active ovaries as demonstrated by the presence of large follicles on both ovaries.

Figure II shows the microscopic picture of the protrusion which was much like the ordinary structure of the vagina. The mucosa comprised dense stratified squamous epithelium. Under the epithelial layer and in the lamina propria many polymorphonuclear cells and lymphocytes infiltrated the area. Few aggregations of lymphocytes formed lymphoid nodules. Much deposition of fibrous connective tissue was also noticed. The smooth muscle fibres of the muscularis mucosa partially protruded into the fold, with some blood vessels scattered in between.

No secretory cells or glands could be seen. On the other hand the vacuoles normally seen in the epithelium as a result of the loss of the collagen during the processing of the sample were not observed. The epithelium was intact and compact.

DISCUSSION

The results of the present study indicate that, the abnormal vaginal growth (called also "El Saide", by local camel owners) could be one of the factors affecting camels reproductive performance in the tropics. However, the incidence of vaginal abnormalities in domestic animals is usually low and have little effect on fertility. Obstructions and malformations of the vagina usually occur in intersexes or in association with disease as white heifer disease (Arthur, et al, 1989).

The vaginal mucosa in the camel consists of a major circular fold followed by several other less prominent but similar circular fringes which tend to obscure the os uteri externus when a vaginoscope is used, (Arthur and Al-Rahim 1982). Those vaginal folds are considered normal and are seen in fertile animals. However, the way by which the vaginal growth reported in this study could affect camels fertility is not known. The fact that removal of those abnormal projections resulted in conception indicate that, they could be interfering with insemination and/or semen deposition. Ovulation in the camel is known to occur after mating (Marie and Anouassi, 1986). As such, the effect of those projections could be mechanical interfering with insemination and or semen deposition, since the microscopic picture was much like the ordinary structure of the vagina. The fact that all the animals

affected by the abnormal vaginal growth had active ovaries, as found in the abattoir specimens, support the hypothesis that they could also be interfering with the process of ovulation.

However, the causes of the abnormal growth of the vaginal wall as noticed in the present study are unknown. The fact that all the animals affected were in good body condition (>3) suggests that the cause could be nutritional, but this needs further investigation.

The presence of various abnormalities of the genital organs in the camel has been studied locally by Dafalla et al., (1991), and abroad by Musa (1984) and El-Wishy (1989). However, the present report is the first, that indicates the presence of an abnormal vaginal growth cusing infertility in breeding camels under tropical conditions.

REFERENCES

Abdel Rahim, S.E.A. and El-Nazier, A.E. (1990): Factors affecting camel reproductive performance in the tropics. Proc. Unite de coordination pour 1 " Elevage Camelin- Workshop: Is it possible to improve the reproductive performance of the camel?

Arthur, G.H. and Al-Rahim, A.T., 1982: Aspects of Reproduction in the female camel (camelus dromedarius) in Saudi Arabia. Veterinary Medical review 1, 83-88.

Arthur, G.H., Noakes, D.E. and Pearson, H. (1989): Veterinary Reproduction and Obstetrics. Sixth edition. London, Bailliere Tindall. p. 368.

Dafalla, E.A., Al-Eknah, M.M. and Gameel, A.A. (1991): Unilateral ovarian agenesis in a camel. Reproduction in Domestic Animals, 26, 266-269.

El-Wishy, A.B. (1989): Genital abnormalities of the female dromedary, an abottoir survey. Zuchthygiene 24, 2, 84-87.

Evans, J.O. and Pauys, J.G., (1979): Camel husbandry to increase the productivity of ranchland. In: Camels IFS symposium, khartoum (Sudan) p. 244.

Marie, M. and Anouassi, A., (1986): Mating induced luteinizing hormone surge and ovulation in the female camel. Biology of Reproduction 35: 792-798.

Musa, B.E., (1984): A note on some abnormalities and anamolies in camels. Dutsche Tieraa rzdiche Wochenschuft. 91, 3, 94-96.

Table I. The reproductive performance of camels affected by vaginal abnormal projections (VAP)

Criteria	Results	Conception rate
Camels examined at farms	115	-
Camels found affected with VAP	23 (20%)	-
Camels in which the VAP was removed	12	100 %
Camels affected but no surgery performed	11	0 %
Normal camels with no surgery performed	21	100%
Camels found affected at slaughter house	12 %	

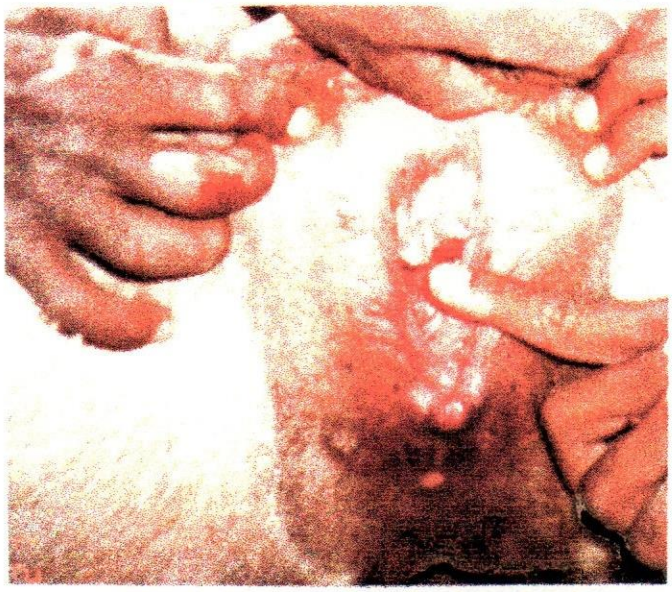

Fig. 1: Abnormal vaginal projections in an infertile camel

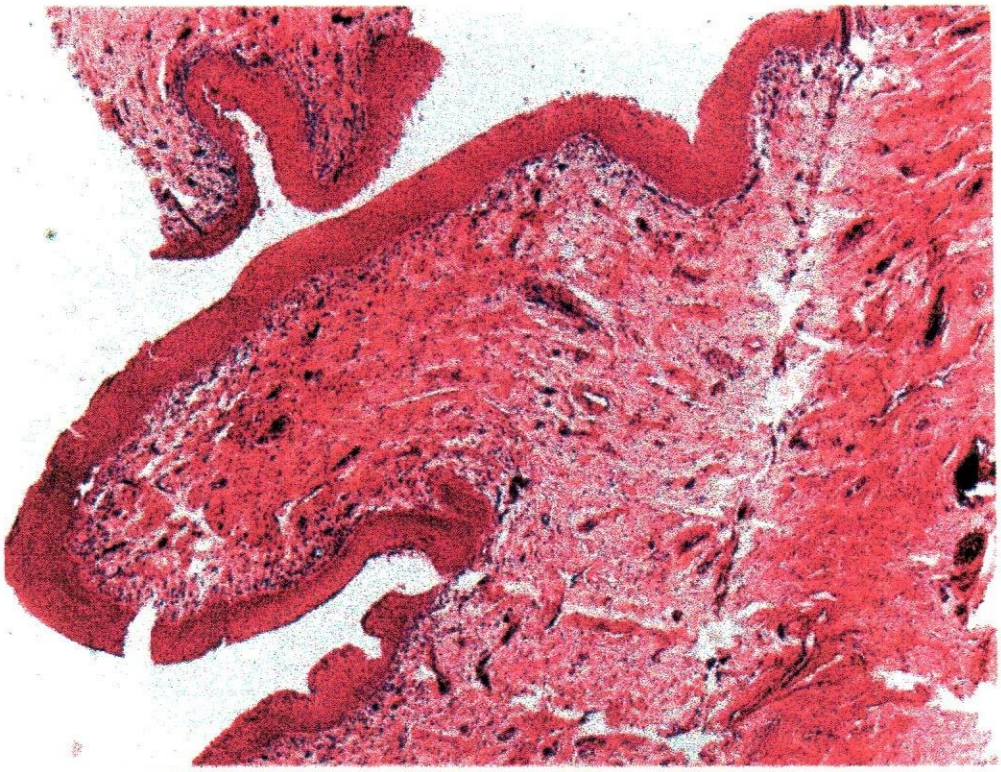

Fig. 2: Microscopic picture of the vaginal projection