

AMELIORATIVE EFFECT OF GINGER (ZINGIBER OFFICINALE ROSCOE) ON THYROID GLAND ACTIVITY IN RATS

DALIA MOUSTAFA¹, EID ABDELHAMEED² and HASSAN AHMED³

¹Physiology Department, Faculty of Veterinary Medicine, Aswan University, Aswan, 81528 Egypt

²Physiology Department, Faculty of Veterinary Medicine, Beni-Suef University, Beni-Suef, 62511 Egypt

³Physiology Department, Faculty of Veterinary Medicine, South Valley University, Qena, 83523 Egypt

Received: 20 June 2017; **Accepted:** 10 July 2017

ABSTRACT

The aim of this study is to investigate the relationship between Ginger administration and thyroid gland function. Ginger was orally administered daily to male albino rats at a dose level of either 50 or 100 mg/kg for one month. Blood samples and thyroid glands were collected after 15 and 30 days and also 10 days after stopping Ginger administration for hormonal analysis and histopathological examination. It was found that T3 elevated significantly 15 days after administration regardless of the dose. Moreover, this elevation became non-significant after 30 days. Interestingly, this change in T3 is reversible and returned to normal level after stopping Ginger administration. Regarding to T4, both doses of Ginger elevated T4 after 15 and 30 days. Likewise, T4 decreased and returned to normal level after stopping Ginger administration. Both dose level, 50 and 100 mg/kg of Ginger elevated TSH after 15 and 30 days, but this elevation after 100 mg/kg was less potent. During the recovery period, almost no change in TSH level was observed. The effect of Ginger for a long period has a deleterious effect on thyroid follicles which appear dilated and empty from colloidal materials.

Key words: Ginger, Thyroid, Thyroxin, Tri-iodothyronine, TSH

INTRODUCTION

Ginger (*Zingiber officinale* Roscoe) is a plant that has green-purple flowers and an aromatic underground stem called a rhizome (Sertie *et al.*, 1991). It is commonly used for cooking and medicinal purposes. Historically, Ginger has been used in Asian medicine for treatment of stomachaches, nausea, and diarrhea. Today, Ginger is used as a therapy for nausea caused by motion or that after surgical operation, chemotherapy, pregnancy, rheumatoid arthritis, osteoarthritis and muscle pain. The use of Ginger, specifically its medicinally active rhizome has gained popularity among most physicians in the last decades (Mascolo *et al.*, 1989). The pharmacological effects of fresh and dried rhizome of Ginger including anti-platelet, antioxidant, anti-tumor, anti-rhinoviral, anti-hepatotoxic and anti-arthritis activities back to ancient China and India (Kamatchoung *et al.*, 2002). In addition, Ginger extracts have been reported to have a potent androgenic activity in male rats (Amin

and Hamza, 2006). These androgenic activities have a useful effect on treating spermatogenesis disorder and poor sperm function (khaki *et al.*, 2009). At the same time, recent studies reported the role of Ginger in body metabolism such as improvement of lipid derangement, fructose overconsumption and liver lipogenesis (Gao *et al.*, 2012). On the other side, it has been found a new function of Ginger as anti-inflammatory in gastrointestinal tract as its protective effect against colitis by regulation of cytokine-related pathway (Hsiang *et al.*, 2013). The current study tries to find out the effect of Ginger on thyroid gland function by oral administration at dose level of 50 and 100 mg/kg body weight by monitoring of thyroid hormones and histopathological examination of thyroid gland.

MATERIALS AND METHOD

Animals:

Ninety adult male albino rats, Sprague Dawley strain, with an average weight of (160±20 g) were obtained from the private laboratory animal farm, Tanta city, Egypt. Animals were transferred to Physiology Department, Faculty of Veterinary Medicine, South Valley University, Qena. Rats were housed in clean plastic cages and maintained on a 12 h light/dark

Corresponding author: Dr. HASSAN AHMED

E-mail address: Hassan-younes@vet.svu.edu.eg

Present address: Physiology Department, Faculty of Veterinary Medicine, South Valley University. Qena, 83523 Egypt.

cycle and at temperature of 26 ± 2 °C with ad libitum access to food and water for two weeks to be acclimatized laboratory environment.

Ginger:

Ginger was bought from MEPACO-MEDIFOOD, which is an Arab company that supplies pharmaceuticals and medicinal plants (Enshas, Sharkeya, Egypt) in the form of 30 tablets each contained 400 mg of Ginger. Ginger was dissolved in NaCl 0.9%, then orally administered every day via stomach tube at two different doses 50 and 100 mg/kg body weight (Khaki *et al.*, 2009).

Experimental design:

Ninety animals were randomly distributed into three groups 30 rats in each. The first one, is a control received saline orally, whereas the second and third groups received Ginger orally at doses 50 and 100 mg/kg body weight, respectively via stomach tube daily for 30 days (Khaki *et al.*, 2012). Fifteen and thirty days after Ginger oral administration, 10 animals from each group were anesthetized by diethyl ether then blood samples were collected from retro-orbital Venus plexus. Blood samples were centrifuged at 3000 RPM for 15 min then sera were separated and kept in -20°C until hormonal analysis (T3, T4 and TSH). Rats were sacrificed and thyroid gland was collected for histopathological study. The remaining animals in each group were kept without any treatment for 10 days for recovery. After the end of the recovery period, blood samples were collected and animals were sacrificed with extraction of the thyroid gland for histopathological examination.

Histological and histopathological examination:

Thyroid glands were rapidly washed in saline solution to remove the blood. Thyroid specimens were removed rapidly from saline and fixed in 10% neutral buffered formalin, then processed up in paraffin blocks. Sections of 5 μm thick were prepared and stained with hematoxylin and eosin for histopathological studies (Drury and Wallington, 1980).

Hormonal assay:

Enzyme-linked immunosorbent assay (ELISA) used for analysis of T3, T4 and TSH using microstrip reader (Stat Fax@4700, USA) at wave length 450 nm. Following kits were used, T3 AccuLite VAST CLIA

Kits (Monobind Inc, Lake forest, USA) (Gharib *et al.*, 1971). Aviva Total Thyroxine EIA kits (Aviva Systems Biology, San Diego, USA) (Walker, 1977) and TSH AccuLite VAST CLIA Kits (Monobind Inc, Lake forest, USA) (Hopton and Harrap, 1986).

Statistical analysis:

Results were analyzed statistically by SPSS and Excel 2010 software. All data were expressed as mean \pm standard error (SE) and differences between groups were analyzed by using student's *t*-Test. Values of $P < 0.05$ were considered significant.

RESULTS

I - Tri-iodothyronine

Data in Table (I) and Fig. (1) revealed that, administration of Ginger for 15 and 30 days at a dose level of 50 and 100 mg/kg induced different effects on serum T3 level. Serum level of T3 significantly increased ($P < 0.001$) 15 days after injection of both doses (0.48 ± 0.03 and $.060 \pm 0.05$, respectively) compared with the corresponding control rats (0.24 ± 0.02). Moreover, the prolonged time of Ginger administration to 30 days revealed non-significant increase of serum T3 after 50 mg/kg (0.26 ± 0.02) while, higher dose (100 mg/kg) elevated T3 significantly ($P < 0.01$) (0.40 ± 0.04) compared with corresponding control (0.25 ± 0.02).

Table (I) showed a comparison between T3 level in the same column, after the same dose in different period of administration. Serum T3 level decreased 30 days after injection of 50 mg/kg significantly ($P < 0.001$) (0.26 ± 0.02) compared with T3 level after 15 days (0.48 ± 0.03). Likewise; it is found that after 100 mg/kg Ginger administration, T3 level significantly decreased ($P < 0.01$) after 30 days (0.40 ± 0.04) compared with 15 days (0.60 ± 0.05). After the end of Ginger administration period, surprisingly, level of T3 during recovery period in 50 and 100 mg/kg-treated groups was (0.20 ± 0.01 and 0.21 ± 0.01 , respectively) returned to level of control rats (0.26 ± 0.03). In addition, comparing T3 level with in the same column of recovery period revealed that serum T3 decreased significantly after injection of 50 ($P < 0.01$) and 100 mg/kg ($P < 0.001$) (0.20 ± 0.03 and 0.21 ± 0.01 , respectively) compared with their levels after 30 days of administration.

Table I: Serum T3 level (ng/ml) of control, 50 and 100 mg /kg BW-treated groups as well as recovery period.

Time after treatment	Control	50 mg/kg B.W	100 mg/kg B.W
After 15 days	0.24 ± 0.02	I A 0.48 ± 0.03	II A 0.60 ± 0.05
After 30 days	0.25 ± 0.02	I II 0.26 ± 0.02	II BI 0.40 ± 0.04
Recovery (10 days from stop treatment)	0.26 ± 0.03	II 0.20 ± 0.01	I 0.21 ± 0.01

A: Values significantly differ from the corresponding control at ($P < 0.001$) in the same row.

B: Values significantly differ from the corresponding control at ($P < 0.01$) in the same row.

I: Values differ significantly from each other at ($P < 0.001$) in the same column.

II: Values differ significantly from each other at ($P < 0.01$) in the same column

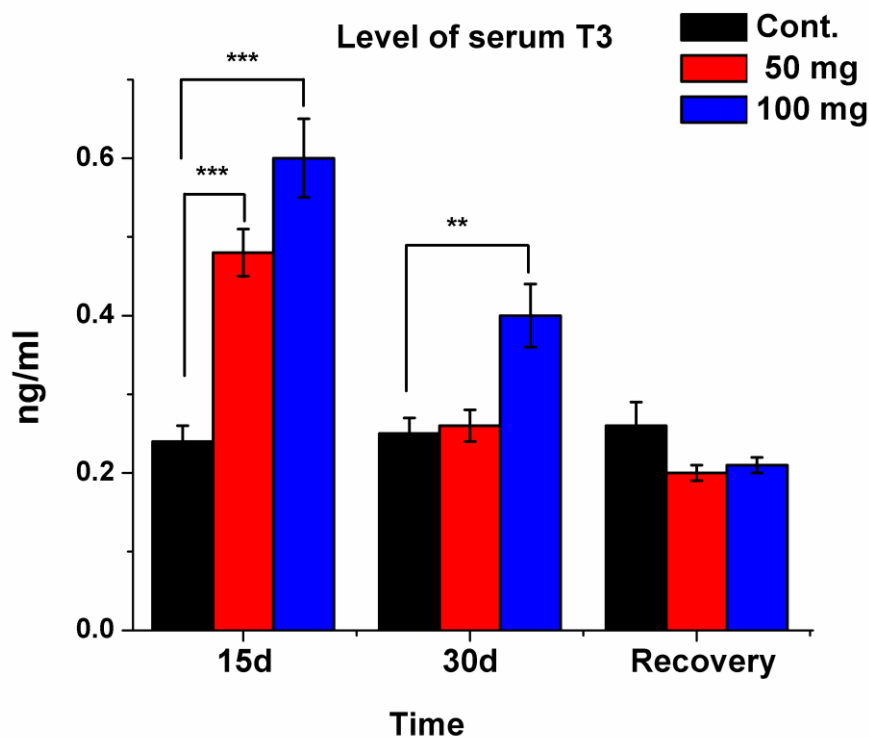


Figure (1): Serum T3 level in control rats as well as those received ginger in dose 50 and 100 mg/kg after 15 and 30 days as well as after stop Ginger treatment (Recovery). It is clear that, T3 increased after Ginger administration then return to basal level in recovery period. (***) $P < 0.001$) and (** $P < 0.01$).

II - Thyroxine

Unlike T3, serum T4 level is less affected by 50 and 100 mg/kg Ginger administration. There is non-significant increase after administration of both doses (3.60 ± 0.70 and 4.50 ± 0.90 , respectively) compared with corresponding control (2.83 ± 0.50) after 15 days of administration. The same results were obtained 30 days after administration (3.08 ± 0.60 and 2.08 ± 0.04 , respectively) compared with control (2.87 ± 0.50) (Fig. 2). Depending on the effect of same dose on T4 level in different administration period, there is non-significant decrease in T4 level

after 15 and 30 days administration (3.60 ± 0.70 and 3.08 ± 0.60 , respectively) in 50 mg/kg-treated group. However, there is a significantly decrease ($P < 0.05$) of serum T4 level 100 mg/kg-treated group after 30 days of administration (2.09 ± 0.04) compared with 15 days administration (4.50 ± 0.90) (Table II). Regarding to serum T4 level during recovery period, there was non-significant decrease in serum T4 level in treated groups (2.10 ± 0.40 and 2.13 ± 0.50) compared with their corresponding control rats (3.40 ± 0.70).

Table II: Serum T4 level ($\mu\text{g/dl}$) in control, 50 and 100 mg/kg B.W-treated groups and recovery period.

Time after treatment	Control	50 mg/kg B.W	100 mg/kg B.W
After 15 days	2.83 ± 0.5	3.6 ± 0.7	I 4.5 ± 0.9
After 30 days	2.87 ± 0.5	3.08 ± 0.6	I 2.08 ± 0.04
Recovery (10 days from stop treatment)	3.4 ± 0.7	2.1 ± 0.4	2.13 ± 0.5

I: Values differ significantly from each other at ($P < 0.05$) in the same column.

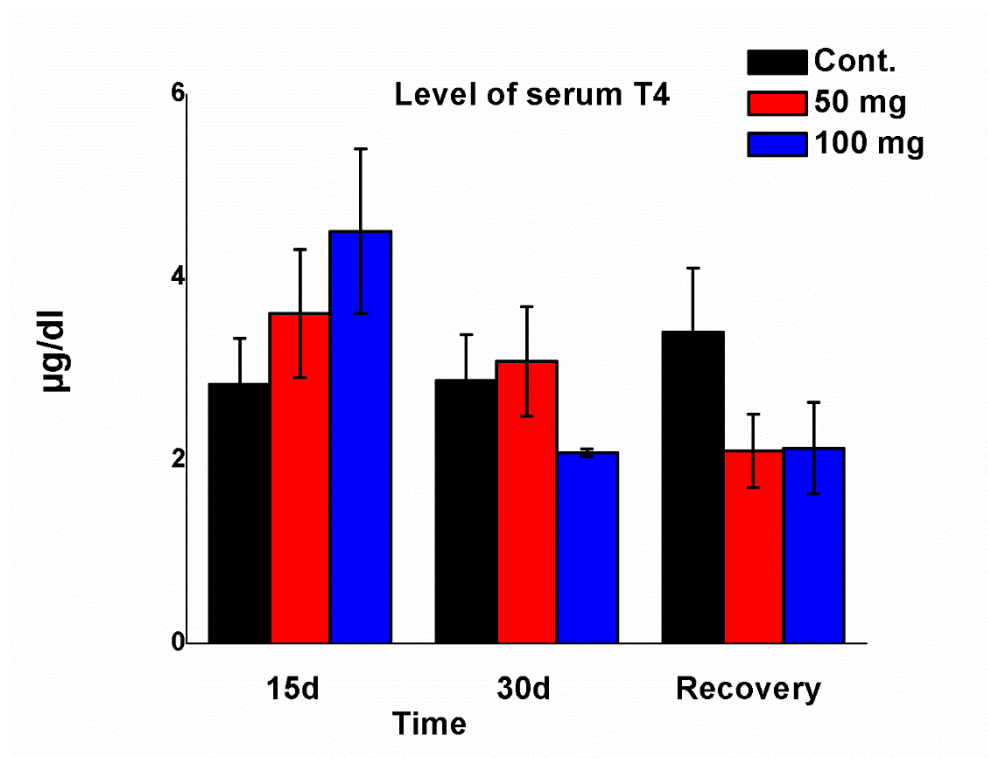


Figure (2): Serum level of T4 after 15 and 30 days of Ginger administration and in recovery period in control rats and those received Ginger 50 and 100 mg/kg. It shows elevation of T4 after 15 days and decreased after 30 days (with high dose) from Ginger administration then return to normal level.

III - Thyroid stimulating hormone

Ginger administration in 50 and 100 mg/kg for 15 and 30 days had variable effect on TSH level. Administration of 50 mg/kg showed non-significant increase of TSH level after 15 (8.20 ± 1.00) compared with control (7.10 ± 0.09) and 30 days (9.36 ± 1.20) compared with corresponding control (6.53 ± 0.80), respectively. Moreover, the same

results were obtained when the rats administered 100 mg/kg for 15 (7.40 ± 0.03) and 30 days (7.93 ± 0.90) (Fig. 3) & (Table III) compared with control group. During the recovery period, there was a non-significant increase in serum TSH level in treated groups (50 and 100 mg/kg) (9.40 ± 1.40 and 7.27 ± 1.10) compared with control rats (6.83 ± 0.90).

Table III: Serum level of TSH ($\mu\text{IU/ml}$) in control male rats, 50 and 100 mg/kg B.W-treated groups and recovery period.

Time after treatment	Control	50 mg/kg B. W	100 mg/kg B. W
After 15 days	7.1 ± 0.09	8.2 ± 1.00	7.4 ± 0.03
After 30 days	6.53 ± 0.8	9.36 ± 1.2	7.93 ± 0.9
Recovery (10 days from stop treatment)	6.83 ± 0.9	9.4 ± 1.4	7.27 ± 1.1

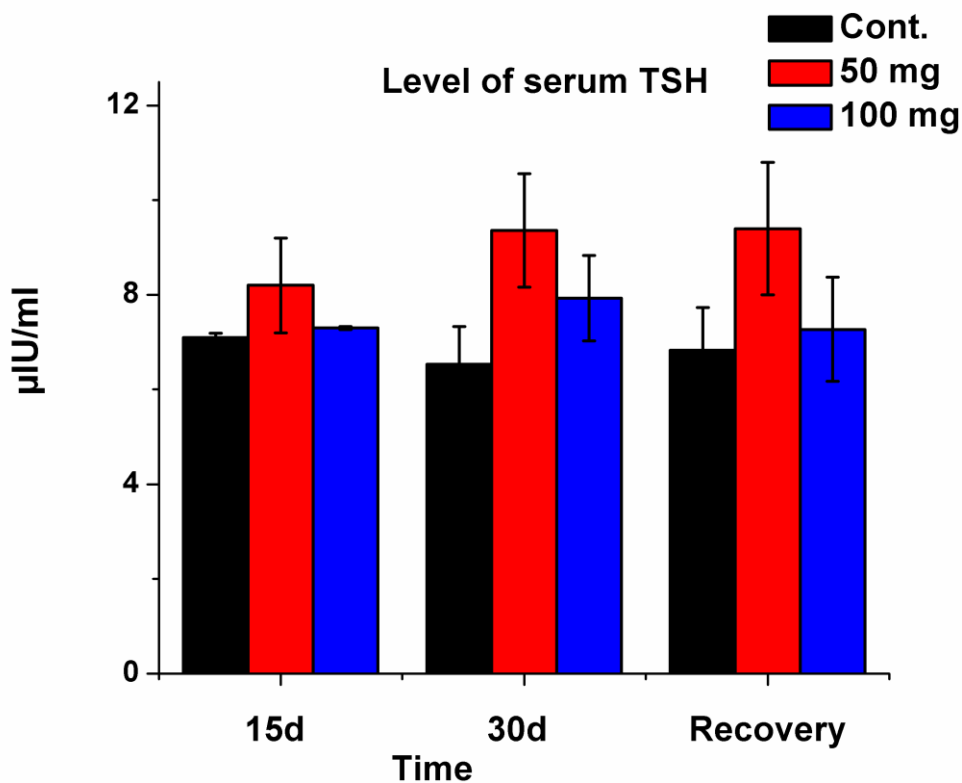


Figure (3): Serum level of TSH after Ginger administration in different periods (15 and 30 days) as well as recovery time. There is small elevation of TSH after Ginger administration especially after prolonged administration.

IV-Histological and histopathological examination

Thyroid gland of control animals (Fig. 4A) composed of thyroid follicles of varying sizes lined by cuboidal cells containing colloidal materials in different amounts. Normal histological structure of thyroid gland was disturbed after Ginger administration depending on the dose and period of administration. After 15 days of 50 mg/kg Ginger administration, some thyroid follicles are dilated (Fig. 4B) with colloidal materials. However, other follicles appeared empty and smaller with pale colloidal materials. Thyroid gland is highly affected by higher Ginger dose (100 mg/kg). After 15 days of administration, some thyroid glands appeared with normal colloid structure (Fig. 4C) while, others were empty and contain desquamated cells in their lumen without colloidal materials in addition to inter-follicular hemorrhage.

On the other side, Ginger administration for 30 days revealed normal histological structure of thyroid gland (Fig. 5A). While, in 50 mg/kg-treated group there was less changes represented by smaller follicle with pale colloidal materials compared with the control (Fig. 5B). Interestingly, thyroid gland of 100 mg/kg-treated rats showed drastic effect (Fig. 5C); these changes represented by empty follicles and detached epithelial cells. During the recovery period, thyroid follicles showed some histopathological improvement in treated groups. Thyroid follicles recovered after 50 mg/kg administration to normal structure however, others still empty without colloidal materials with detached epithelial cells (Fig. 6A). On the other side, some thyroid follicles after 100 mg/kg administration appeared as normal ones with cuboidal cells while, some follicles still affected (Fig. 6B).

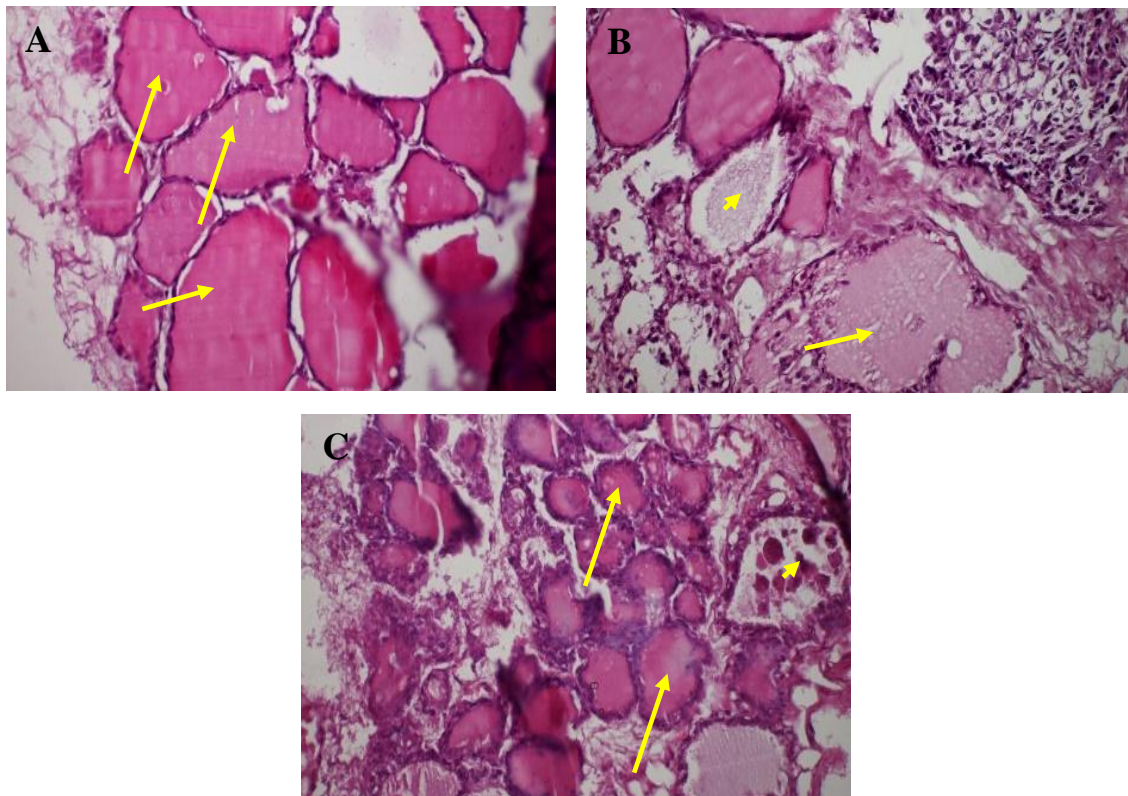


Figure (4): Microscopic photography revealed histological and histopathological structure of thyroid gland in normal (A) and ginger-treated rats (B and C) for 15 days. (A) Normal thyroid follicles (Arrows) in different sizes filled with colloidal materials (X400). (B) Adverse effect of 50 mg/kg represented by impaired dilated follicles (Arrows) while, others (Arrow head) are smaller, empty or contain pale colloidal materials. (C) Ginger at dose 100 mg/kg leading to smaller follicles (Arrows) while, others are empty with desquamated cells (Arrow head) (Stain: H&E, Magnification: X200).

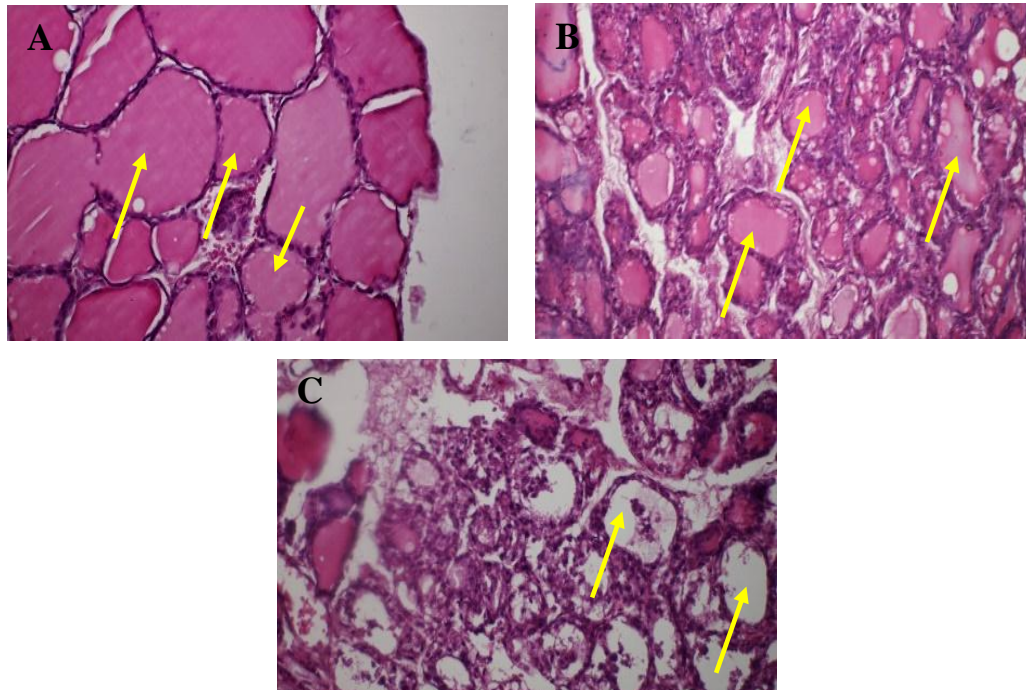


Figure (5): Histological and histopathological findings of thyroid gland in normal (A) and ginger-treated rats (B and C) for 30 days. (A) Similar to the previous control rats, there are normal thyroid follicles (Arrows) (X400). (B): At 50 mg/kg Ginger dose, there is limited effect on thyroid follicles represented by smaller in size (Arrows) (X200). (C) High Ginger dose, 100 mg/kg has drastic changes in thyroid follicles which appeared empty (Arrows) with detached epithelial cells (Stain: H&E, Magnification: X400)

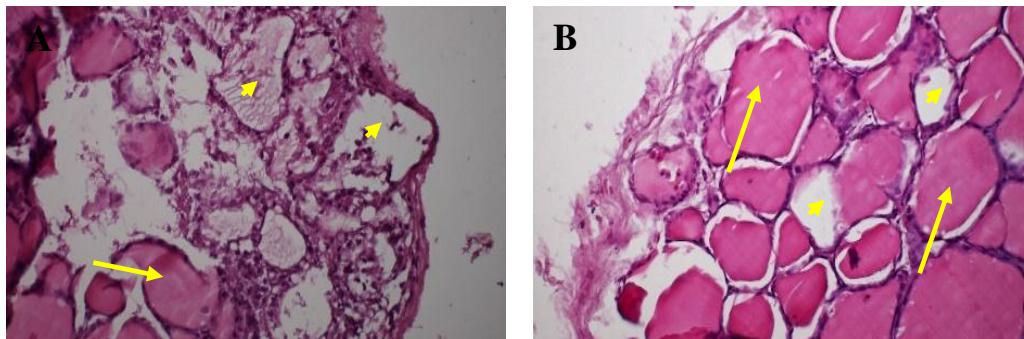


Figure (6): Recovery of some affected thyroid follicles after stop of Ginger administration 50 mg/kg (A) and 100 mg/kg (B). (A) Showed some follicles recovered (Arrows) and filled with colloidal materials however, others still empty (Arrow head) (X400). (B) There is a partial recovery of adversely affected follicles, some recovered (Arrow) while, others appeared empty with desquamated cells (Stain: H&E, Magnification: X400).

DISCUSSION

The present aimed to find out the effect of the Ginger on thyroid gland after oral administration. The results represent the lost ring in scientific research of Ginger medical uses. All the previous studies shed the light on various medical effect of Ginger such as on cardiovascular function (Ohizumi *et al.*, 1996), anti-hypertensive effect (Ghayur and Gilani, 2005), on gastrointestinal tract and digestion (Platel and Srinivasan, 1996 and 2000) as it enhances GIT hormones activity. Moreover, these studies extended to include improvement effect of Ginger on testicular

function (Khaki *et al.*, 2009 and 2012), anti-oxidant effect (Nassiri *et al.*, 2009 and Khaki *et al.*, 2012), hepatic (Zakhari, 2006) and renal (Sakr *et al.*, 2011) protective and anti-inflammatory effect (Srivastava and Mustafa, 1989 and 1992). The present study clarified that Ginger affected thyroid activity centrally through TSH or locally through thyroid tissue depending on the dose and period of administration. Level of TSH, T3 and T4 elevated after 15 days of Ginger oral administration (50 mg/kg) and this elevation may be due to increase blood supply and nutrients to thyroid follicles. Depending on the previous studies, Ginger increase

cardiac output subsequently, blood supply to the body in addition, it enhances intracellular metabolism (Shoji *et al.*, 1982). Moreover, histopathological examination revealed dilatation of some thyroid follicles in the same group indicating distention of these follicles with thyroglobulins subsequently with thyroid hormones.

Level of T3 and T4 in continuous elevation after higher dose of Ginger (100 mg/kg) as well as thyroid follicles filled with thyroglobulins therefore, this elevation during short period administration (15 days) is dose independent. On the other hand, levels of TSH, T3 and T4 during long period administration (30 days) is dose dependent and 50 mg/kg elevates levels of TSH, T3 and T4. Interestingly, higher dose (100 mg/kg) within the same period decreases level of TSH and T4 but not T3 that still high. This decrease may be due to inhibitory effect of higher dose of Ginger in prolonged time. As recorded before, high dose of Ginger for long time cause subacute thyroiditis and inhibitory effect on metabolic rate and adenylate energy status (Riewe *et al.*, 2008). Therefore, ending with damage of thyroid follicle membrane and inhibit thyroid hormone synthesis (Sanavi and Afshar, 2010). In addition, histopathological examination confirmed the presence of thyroiditis by detached epithelial lining in some follicles, which appear empty from thyroglobulins.

The most surprising finding is the elevation of T3 with higher Ginger dose for long time, which may be due to different metabolic effect of Ginger on biosynthesis of T3 and T4 during binding of Di-iodotyrosin molecules with each other or with Mono-iodotyrosin to form T4 and T3, respectively. This change in metabolic effect may enhance T3 and suppress T4 biosynthesis, but this needs to be confirmed by further and advanced study at molecular biological and cellular level. After recovery period, the hormonal changes are reversible and levels of T3 and T4 returned around the normal level in both low and high doses after 15 and 30 days of Ginger administration. At the same time, the histological structure of thyroid follicles revealed that most of affected follicles recovered to normal structure with thyroglobulins in their lumina. Although, some follicles still deteriorated and their lumen still empty with detached epithelial lining, they may be recovered completely if recovery period is longer with normal level of thyroid hormones. Although levels of T3 and T4 returned during recovery period to the normal level, TSH still high after low Ginger administration (50 mg/kg) while, it reduced after high ginger dose (100 mg/kg). This may be due to feedback mechanism and decreasing level of T3 and T4 from high to basal level.

In conclusion, oral administration of Ginger has stimulatory effect on thyroid hormones after 15 days

of administration regardless its dose. On the other hand, prolonged Ginger administration (30 days), T3 elevated with high Ginger dose (100 mg/kg) however, T4 decreased with the same dose. These changes are TSH independent but they depend on local effect of Ginger on thyroid follicles. This change of hormonal level is reversible due to hormones returned to basal level after stop of Ginger administration.

REFERENCES

- Amin, A. and Hamza, A.A. (2006): Effects of Rosell and Ginger on cisplatin- induced reproductive toxicity in rats. *Asian J. Androl.*, 8(5): 607-612.
- Drury, R.A. and Wallington, E.A. (1980): Carleton's histopathological technique (pp. 234-239, 4th ed.). Oxford University Press, Oxford, New York, Toronto.
- Gao, H.; Guan, T.; Li, C.; Zuo, G.; Yamahara, J.; Wang, J. and Li, Y. (2012): Treatment with Ginger Ameliorates Fructose-Induced Fatty Liver and Hypertriglyceridemia in Rats: Modulation of the Hepatic Carbohydrate Response Element-Binding Protein-Mediated Pathway. *Evid Based Complement Alternat Med.*, 570948.
- Gharib, H.; Ryan, R.J.; Mayberry, W.E. and Hockett, T. (1971): Radioimmunoassay for Triiodothyronine (T3): Affinity and Specificity of Antibody for T3. *J Clinical Endocrinol.*, 33, 509-516.
- Ghayur, M.N. and Gilani, A.H. (2005): Ginger lowers blood pressure through blockade of voltage dependent calcium channels. *J. Cardiovasc. Pharmacol.*, 45: 74-80.
- Hopton, M.R. and Harrap, J.J. (1986): Immunoradiometric assay of thyrotropin as a first line thyroid function test in the routine laboratory. *Clinical Chemistry*, 32:691-693.
- Hsiang, C.Y.; Lo, H.Y.; Huang, H.C.; Li, C.C.; Wu, S.L. and Ho, T.Y. (2013): Ginger extract and zingerone ameliorated trinitrobenzene sulphonic acid-induced colitis in mice via modulation of nuclear factor- κ B activity and interleukin-1 β signalling pathway. *Food Chem.*, 136(1):170-177.
- Kamtchouing, P.; Mbongue-Fandio, G.Y.; Dimo, T. and Jatsa, H.B. (2002): Evaluation of androgenic activity of Zingiber officinale extract in male rats. *Asian J. Androl.*, 4: 299-301
- Khaki, A.; Farnam, A.; Badie, A.D. and Nikniaz, H. (2012): Treatment Effects of Onion (*Allium cepa*) and Ginger (*Zingiber officinale*) on Sexual Behavior of Rat after Inducing an Antiepileptic Drug (lamotrigine). *Balkan Med J.*, 29: 236-242.
- Khaki, A.; Fathiazad, F.; Nouri, M.; Khaki, A.A.; ozanci, C.C.; Ghafari-Novin, M. and Hamadeh, M. (2009): The Effects of Ginger

- on Spermatogenesis and Sperm parameters of Rat. Iranian J. Reprod. MED. 7 (1): 7-12.
- Mascolo, N.; Jain, R.; Tain, S.C. and Capasso, F.J. (1989): Ethnopharmacologic investigation of Ginger (Zingiber officinale). J. Ethano Pharmacol., 27 (1-2): 129-140.
- Nassiri, M.; Khaki, A.; Ahmadi-Ashtiani, H.R.; Rezazadeh, S.h.; Rastgarm, H. and Gharachurlu, S.h. (2009): Effects of Ginger on Spermatogenesis in Streptozotocin-induced Diabetic Rat. Journal of Medicinal Plants, 8 (31): 118-124.
- Ohizumi, Y.; Sasaki, S.; Shibusawa, K.; Ishikawa, K. and Ikemoto, F. (1996): Stimulation of sarcoplasmic reticulum Ca^{2+} ATPase by gingerol analogues. Biol. Pharm. Bull., 19: 1377-1379.
- Platel, K. and Srinivasan, K. (1996): Influence of dietary spices or their active principles on digestive enzymes of small intestinal mucosa in rats. International Journal of Food Sciences & Nutrition, 47: 55-59.
- Platel, K. and Srinivasan, K. (2000): Influence of dietary spices and their active principles on pancreatic digestive enzymes in albino rats. Nahrung, 44: 42-46.
- Riewe, D.; Grosman, L.; Zauber, H.; Wucke, C.; Fernie, A.R. and Geigenberger, P. (2008): Metabolic and developmental adaptations of growing potato tubers in response to specific manipulations of the adenylate energy status. Plant Physiol., 146:1579-1598.
- Sakr, A.S.; Lamfon, A.H. and Essawy, E.A. (2011): Ginger (Zingiber officinale) extract ameliorates metalaxyl fungicide induced nephrotoxicity in albino mice. African Journal of Pharmacy and Pharmacology, 5(2):104-112.
- Sanavi, S. and Afshar, R. (2010): Subacute thyroiditis following Ginger (Zingiber officinale) consumption. International Journal of Ayurveda Research, 1(1):47-48.
- Sertie, J.A.; Basile, A.C. and Panizza, S. (1991): Pharmacological assay of Cordia verbenacea. III: oral and topical anti-inflammatory activity and gastrotoxicity of a crude leaf extract, J. Ethnopharmacol., 31: 239-247.
- Shoji, N.; Iwasa, A.; Jakemoto, T.; Ishida, Y. and Ohizuma, Y. (1982): Cardiotoxic principle of Ginger (Zingiber officinale Roscoe). J. Pharm Sci., 7: 1174-1175.
- Srivastava, K.C. and Mustafa, T. (1989): Ginger (Zingiber officinale) and rheumatic disorders. Med Hypotheses, 29 (1):25-28.
- Srivastava, K.C. and Mustafa, T. (1992): Ginger (Zingiber officinale) in rheumatism and musculoskeletal disorders. Med Hypotheses, 39 (4):342-348.
- Walker, W.H.C. (1977): Introduction: An Approach to Immunoassay. Clin. Chem., 23(2): 384-387.
- Zakhari, S. (2006): Overview: how is alcohol metabolized by the body? Alcohol Res Health., 29(4):245-254.

التأثير التحسني للزنجبيل علي نشاط الغدة الدرقية في الفئران

داليا مصطفى ، عيد عبد الحميد ، حسن أحمد

Email: Hassan-younes@vet.svu.edu.eg

Assiut University web-site: www.aun.edu.eg

يعتبر الزنجبيل من أهم الأعشاب التي تم اكتشافها قديما وعادة كان يستخدم في الطهي وإكتساب طعم طيب للطعام. انتشر الزنجبيل انتشارا واسعا في الدول الآسيوية مثل الهند والصين ويرجع انتشاره في هذه المناطق إلي اكتشاف استخدامات طبية للزنجبيل وعلاج الكثير من الأمراض مثل أمراض المعدة، الغثيان والإسهال. كما امتد الأثر الطبي للزنجبيل ليشمل تخفيف الآلام الناتجة عن التهاب المفاصل والعمود الفقري والام العضلات. في العقود الأخيرة تم اكتشاف المزيد من الأثار الطبية للزنجبيل مثل القدرة علي منع تجلط الدم ومضاد للأوكسدة ومضاد للاورام وأمراض الكبد والكلية وعلاج تصلب الشرايين وذلك بالتخلص من الدهون المتركمة في الجسم كما أثبتت الأبحاث الحديثة أنه منشط للحيوانات المنوية. من هذا المنطلق تأتي نظرية هذه الدراسة حيث تمت محاولة اكتشاف دور الزنجبيل علي الغدة الدرقية والهرمونات التي تفرزها مثل التيروتوكسين (T4) وثالث يود التيرونين (T3) وكذلك علي الهرمون المحفز للغدة الدرقية (TSH) والذي يفرز من الغدة النخامية. في هذه الدراسة تم استخدام عدد تسعون ذكر من الفئران البيضاء البالغة وتم تقسيمها إلي ثلاث مجموعات الأولي هي المجموعة الضابطة وتم تجريعها بمحلول ملح عن طريق الفم والمجموعة الثانية تم تجريعها ٥٠ مجم زنجبيل/كجم من وزن الجسم أما المجموعة الثالثة تم تجريعها ١٠٠ مجم زنجبيل/كجم من وزن الجسم يوميا لمدة شهر هو مدة إجراء هذه الدراسة. بعد انتهاء ١٥ يوما من تجريع الثلاث مجموعات يتم تجميع عينات الدم من ١٠ فئران من كل مجموعة ثم تذبح هذه الفئران بهدف استخلاص الغدة الدرقية وبعد انتهاء ٣٠ يوما من التجريع تكرر نفس الخطوات في اخذ العينات من نفس عدد الفئران. بعد انتهاء ٣٠ يوما (مدة التجريع) يتبقى ١٠ فئران في كل مجموعة تترك بدون تجريع لمدة ١٠ أيام (فترة التعافي) ثم يؤخذ منها عينات الدم والغدة الدرقية بنفس الطريقة. جميع عينات الدم التي تم أخذها يتم وضعها في جهاز الطرد المركزي عند ٣٠٠٠ لفة في الدقيقة لمدة ١٥ دقيقة ثم يفصل مصل الدم ويحفظ في درجة حرارة ٢٠ درجة مئوية تحت الصفر لحين استخدامها في تحليل الهرمونات المطلوبة وبالنسبة لعينات الغدة الدرقية فتحفظ في فورمالين ١٠% لحين استخدامها. بعد الإنتهاء من تحليل العينات وجدنا زيادة في هرمونات التيروتوكسين وثالث يود التيرونين والهرمون المحفز للغدة الدرقية في المجموعتين الثانية والثالثة بعد ١٥ و ٣٠ يوما من التجريع ومقارنة بالمجموعة الضابطة. بالنسبة لمجموعة الفئران في فترة التعافي فلم يلاحظ تغيير في مستوى الهرمونات مقارنة بالمجموعة الضابطة. مما سبق نضح جليا الدور الفعال للزنجبيل في تنشيط الغدة الدرقية عن طريق الهرمون المحفز للغدة الدرقية مما ينتج عنه زيادة في مستوى هرمونات التيروتوكسين وثالث يود التيرونين وهذا التأثير يتلاشي إذا توقف تجريع الزنجبيل.