

Treatment of Genu Valgum Deformity in Adolescent by Closed Wedge Femoral Osteotomy

Mohammed Saeid Adrees*, Khaled Mohamad Hassan, Reda Hussein Al-kady, Ehab Mohamed Shehata

Department of Orthopedic Surgery, Faculty of Medicine, Zagazig University, Egypt.

*Corresponding author: Mohammed Saeid Adrees, Mobile: (+20) 01020867907,

Email: mohammedsaed.edris.1988@gmail.com

ABSTRACT

Background: Various types of corrective osteotomies of the distal femur have been described in the literature for genu valgum deformity such as lateral opening wedge, medial closing wedge, dome osteotomy, wedgeless spike osteotomy, and wedgeless “V” osteotomy.

Objectives: We aimed in this study to evaluate the effectiveness of medial closing wedge osteotomy in correction of deformity.

Patients and Methods: This study was done on 32 knees (18 patients) with age ranged from 10 to 18 years with mean average of 15.61 ± 1.28 years. After recording history and physical examination, appropriate radiographs were taken. We did varus distal femoral osteotomy by standard medial subvastus approach then followed the patients clinically and radiographically.

Results: Mean operation time was 139.72 ± 42.4 minutes, with minimum 90 minutes and maximum 170 minutes. The mean time to union of osteotomy was 8.9 weeks (ranged from 7 to 11 weeks). The mean preoperative tibiofemoral angle (TFA) was 16.5° (range: 12° – 19°) that improved after surgery to a mean postoperative value of 2.57° (range: 1.3° – 4.7°), which was statistically significant ($P < 0.001$).

Conclusion: Distal femoral varus osteotomy can be a reliable procedure for the treatment of valgus knee deformity. In this procedure, with more tibiofemoral angle correction, more congruence angle correction can be achieved. Therefore, along with genu valgum correction, the patella should be stabilized simultaneously.

Key words: Genu valgum, Pathological, Femur, Osteotomy.

INTRODUCTION

Genu valgum involves medial angulation of the knee and outward deviation of the longitudinal axis of both the tibia and femur. Persistent genu valgum in adolescents induces abnormal gait and functional disturbances (including difficulty in running, knee discomfort, patellar malalignment, lateral patellar instability, and ligamentous instability) ⁽¹⁾.

Angular knee alignment changes according to the age of the child. It is genu varum with internal tibial torsion at birth and then aligns to straight legs by the eighteenth month to the twenty-fourth months. Further drifts into valgus with about 12 degrees around five years. This genu valgum spontaneously correct by age of seven years to that of normal adult values of around 8 degrees ⁽²⁾.

After seven years old, correction of excessive physiologic genu valgum may be indicated ⁽³⁾.

Nutritional rickets is the leading cause of these deformities in developing countries. The deformity may originate from the distal femur, proximal tibia, or the knee joint ⁽⁴⁾. Genu valgum usually originates from the distal femur that may be confirmed by various angle measurements on standing radiographs of both lower limbs including hips, knees, and ankles ⁽⁵⁾.

The advantages of medial closing wedge are: Direct bony contact leads to inherent stability and reliable bony healing compared to the need for bone grafting of an opening-wedge technique. There is less hardware irritation because of the plate not being

directly under the iliotibial band ⁽⁶⁾. Corrective osteotomy for excessive genu valgum is appropriate when the patient presents near or after skeletal maturity ⁽⁷⁾. Young patients with valgus alignment and lateral compartment disease including isolated lateral compartment arthritis, lateral meniscal deficiency, and/or focal chondral or osteochondral lateral compartment defects are excellent candidates for a distal femoral osteotomy ⁽⁸⁾.

The aim of the present study was to evaluate the effectiveness of medial closing wedge osteotomy in correction of deformity.

SUBJECTS AND METHODS

This prospective clinical study was conducted on 18 adolescents aged between 10 and 18 years presenting with a genu valgum deformity. They were admitted to Orthopedic Department Zagazig University Hospitals during the period from April 2020 to April 2021.

Ethical approval:

Written informed consent was obtained from all participants and the study was approved by the Research Ethical Committee, Faculty of Medicine, Zagazig University. The work has been carried out in accordance with The Code of Ethics of the World Medical Association (Declaration of Helsinki) for studies involving humans.



This article is an open access article distributed under the terms and conditions of the Creative Commons Attribution (CC BY-SA) license (<http://creativecommons.org/licenses/by/4.0/>)

Inclusion criteria: At skeletal maturity. Patients with genu valgum deformity having a tibiofemoral angle more than 15 degree. Pathological genu valgum. Non-traumatic etiology. Desire to participate in activities with heavy functional loading.

Exclusion criteria: Before skeletal maturity. Instability of the knee. End stage OA. Bi and Tri-compartmental OA. Flexion deformity. Osteonecrosis. Hematological or rheumatological diseases. Presence of infection.

The patients having genu valgum deformity who were selected after qualifying inclusion criteria were clinically assessed and underwent radiological and biochemical investigations. Patients having a TFA ranged 12-15°, intermalleolar distance (IMD) of more than 10 cm, origin of the deformity in the distal femur, were considered for inclusion in the study. Patients who had instability of the knee. End-stage osteoarthritis. Bi and Tri-compartmental osteoarthritis. Flexion deformity. Osteonecrosis. Hematological or rheumatological diseases were excluded from the study.

The origin of the deformity was clinically assessed by the knee flexion test. Measurement of the IMD was done while in standing position with the knee extended and the medial surface of both the knees touching each other and patella facing forward. Measurement of the radiological TFA was done as the angle formed between the anatomical axis of the femur and tibia. The lateral distal-femoral angle (LDFA) was measured as the lateral angle between the mechanical axis of the femur and the articular surface of the distal femur (Figure.1). Evaluation was done on the basis of pre and postoperative radiological (TFA and LDFA) parameters.

Functional assessment was done using The Hospital for Special Surgery Knee-rating Score (HSS). The standing anteroposterior (AP) radiograph was taken including both hips, both knees with patella facing forward and both ankles to measure the angles to quantify the deformity.

Preoperative assessment:

The patients were managed according to age, severity of deformity and cause of deformity. The patient should be assessed clinically, laboratory and radiologically.

Clinically: Examine limb length, deformity (unilateral or bilateral), origin of deformity (Tibial or femoral or both and another associated deformity as external tibial torsion).

Laboratory: Serum calcium, phosphate, alkaline phosphatase. All laboratory investigations were done at Zagazig University Hospitals.

Radiological: Long film x-ray showing from both hips to ankles, showing angles and mechanical axis deviation.

Operative procedure: The operation is performed under anaesthesia (general/ spinal) with the patient supine on a radiolucent operating table under tourniquet control. The knee is flexed to 60° during the surgery to avoid pressure in the popliteal area by keeping a large bolster under it. During draping care is taken to expose the ankle so that the center of the ankle could be determined easily.

A medial longitudinal skin incision of approximately 8–10 cm long was made extending from the level of the medial joint line to 5 cm above the adductor tubercle (Figure.1). The deep fascia was incised in line with the incision. The vastus medialis was identified and elevated anteriorly. The epiphyseal vessels traversing transversely were identified just proximal to the adductor tubercle. The periosteum was incised and elevated anteriorly and posteriorly to expose the femoral metaphysis and to protect the popliteal vessels. The adductor tubercle was identified.

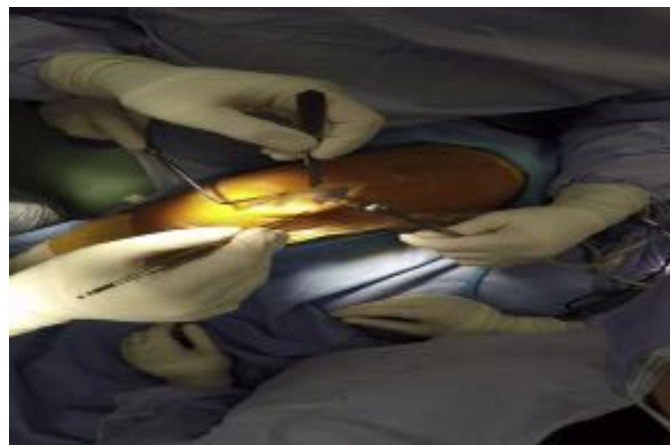


Figure (1): A medial longitudinal skin incision was made extending from the level of the medial joint line to above the adductor tubercle.

A transverse medial incision through the periosteum is extended along the anterior and posterior femur using electrocautery. A malleable retractor is placed anteriorly to protect the quadriceps and posteriorly to protect the neurovascular structures. The osteotomy is outlined by placing 2 K-wires from medial to lateral corresponding with the planned osteotomy angle.

The wedge osteotomy is created using an oscillating saw between the 2 K-wires preserving approximately 5 mm of lateral femoral cortex. The bone cut must be parallel to the K-wire and the articular joint line. Copious irrigation is used to avoid thermal injury from the saw. The wedge of bone is then removed. The 2 K-wires are then removed (Figure 2). Closing the wedge must be performed gradually by gentle compression of the lower leg laterally.

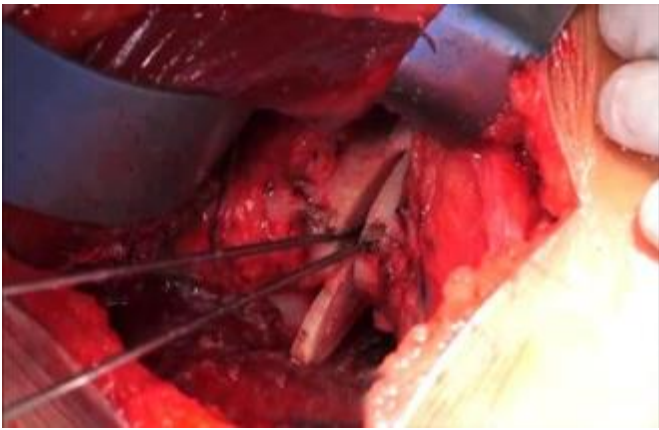


Figure (2): 2 K- wires to plan osteotomy angle, and Removal the wedge of bone.

The osteotomy may temporarily stabilized by crossed K-wires. Leg alignment was checked radiologically after closing with a rigid alignment bar positioned between hip and ankle center. Once confirmed, the osteotomy was then stabilized by internal fixation. We used in this study distal femoral plate and proximal tibial plate (T-plate).

Plate position was then verified with AP and lateral fluoroscopy. vacuum drain was inserted and closure of the vastus medialis was fastened back to medial septum with interrupted sutures. The subcutaneous tissue and skin were closed in routine fashion, and compression dressing was applied. High cast above knee was applied in all patients (Figure 3).

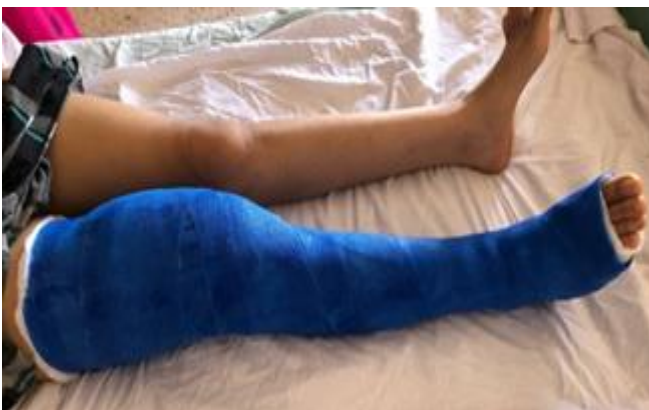

Figure (3): High above knee cast.

Postoperative treatment:

The drain was removed at 24-48 hours after surgery and the amount of blood collected in the drain was less than 50 cc. All patients received intravenous 500 mg of third generation cephalosporin for 48 hours post operatively followed by oral antibiotic capsules for 5 days. Analgesic (Intramuscular 75 mg of diclofenac sodium) in first 48 hours then mild analgesic belonging to NSAIDs were given as required for 5 days postoperatively.

Immediate postoperative radiographs including the knee (AP and lateral views) were taken. The patients were kept non-weight bearing for 3 weeks to be followed by partial weight bearing with 2 crutches

as tolerated. Removal of the cast after 3 weeks and, active assisted exercises were started. The patient was allowed full weight bearing and more demanding activities as his or her muscle strength and symptoms allow. Patients were reviewed at 3 weekly intervals. Standing radiographs both AP and lateral views were taken at 4 weekly intervals. Follow up period was 6 months.

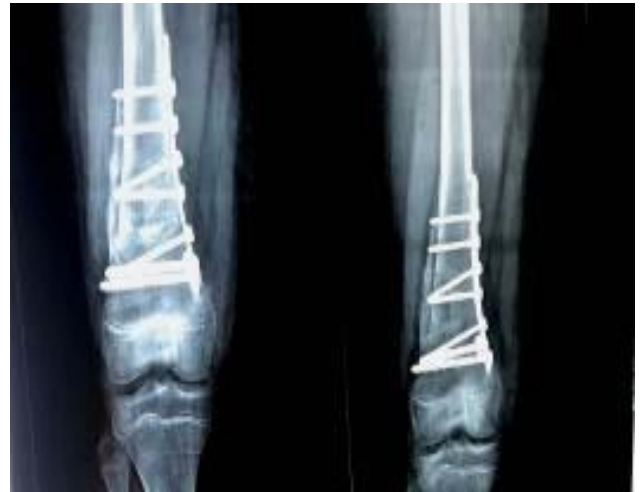

Figure (4): Standing radiographs AP views were taken at 6 months show callus formation and completely healing at site of osteotomy cut.

Statistical analysis

The collected data were coded, processed and analyzed using the SPSS (Statistical Package for Social Sciences) version 22 for Windows® (IBM SPSS Inc, Chicago, IL, USA).

Data were tested for normal distribution using the Shapiro Walk test. Qualitative data were represented as frequencies and relative percentages. Chi square test (χ^2) to calculate difference between two or more groups of qualitative variables. Quantitative data were expressed as mean \pm SD (Standard deviation). Independent samples t-test was used to compare between two independent groups of normally distributed variables (parametric data). P value \leq 0.05 was considered significant.

RESULTS

Table (1): Age distribution of the studied group

Variable	The studied group(18)	
Age (years):		
Mean \pm SD	15.61 \pm 1.28	
Range	(14-18)	
Median	15.5	
Variable	NO(18)	%
Age grouping:		
\leq 15.5 years	8	44.4%
>15.5 years	10	55.6%

The mean age of the patients was 15.16 years (range: 14–18 years). There were 11 males and 7 females. 14 patients' bilateral lesions and 4 patients had

unilateral lesions so the total number of limbs affected was 32 limbs (Table 1).

Table (2): Comparing pre- & post-operative change on tibiofemoral angle among study group

Variable	Pre-operative mean \pm SD	Post-operative mean \pm SD	p-value
Tibiofemoral angle	16.5° \pm 1.9	5.6° \pm 1.3	< 0.001*

The mean preoperative tibiofemoral angle was 16.5° (range, 12°–19°) that improved after surgery to a mean postoperative value of 5.6° (range, 1.3°–4.7°) which was statistically significant (P < 0.001) (Table 2).

Table (3): Intermalleolar distance before and after correction

Variable	Pre-operative mean \pm SD (Range)	Post-operative mean \pm SD (Range)	p-value
Intermalleolar distance (IMD) (cm)	14.77 \pm 1.95 (12-17)	5.11 \pm 1.2 (4-7)	0.001**

The mean preoperative IMD was 14.77 cm (range: 12–17 cm) that improved to a mean postoperative value of 5.11 cm (range: 4–7 cm) and that was statistically significant (P < 0.001) (Table 3).

Table (4): The change on pre- & post-operative of mL DFA among studies group

	Pre-operative mean \pm SD Range	Post-operative mean \pm SD Range	p-value
mL DFA (°)	77 \pm 3.5 73°–83°	88.4 \pm 1.3 87°–91°	< 0.001*

The mean preoperative LDFA was 77.3° (range, 73°–83°) that improved significantly after corrective osteotomy to a mean postoperative value of 88.1° (range, 87°–91°) with P < 0.001) (Table 4).

Table (5): Pre- and post-operative change on HSS scores among the studied group

	Pre-operative mean \pm SD	Post-operative mean \pm SD
HSS score	61.78 \pm 6.041	84.15 \pm 6.9

The mean preoperative HSS score was 61 that improved significantly to a mean postoperative value

of 84.15 (P < 0.001) and that falls in the good and excellent outcome category (Table 5).

DISCUSSION

Coronal plane deformities such as genu valgum are a frequent cause of outpatient clinic visit in the orthopedic department, especially among adolescent females and young adults. Malalignment in coronal plane increases the risk of development and progression of osteoarthritis⁽⁹⁾.

The altered biomechanics and lateral shifting of mechanical axis in genu valgum deformity may lead to anterior knee pain, patellofemoral instability, abnormal gait, and difficulty in running. Severe genu valgum deformity needs surgical intervention to restore biomechanics and improve cosmesis, gait, and function⁽¹⁰⁾. A large number of corrective distal femoral osteotomies have been described for genu valgum deformity because the most common site of deformity is distal femur. Femoral osteotomies work well for realignment of the limb with a valgus deformity. The degree of correction may vary depending on the progression of disease at the time of treatment⁽¹¹⁾.

A total of 18 patients that were included in the study underwent surgical correction of genu valgum deformity with medial closed wedge femoral osteotomy and were followed up for 6 months. The mean age of the patients was 15.16 years (range, 14–18 years). There were 11 males and 7 females. 14 patients had bilateral lesions and 4 patients had unilateral lesions so the total number of limbs affected was 32 limbs.

Our study showed that the mean tibiofemoral angle was 19.8° (range: 16° to 29°) before surgery, that improved to a mean postoperative value of 5.3° (range: 0° to 10°). This agrees with the results of **Gupta et al.**⁽¹²⁾ where the study included 30 adolescent or young adults presenting with a genu valgum deformity. The mean tibiofemoral angle was 22.2° (range: 16° to 29°), that improved to a mean postoperative value of 5.1° (range: 0° to 10°). Moreover, **Jaiman et al.**⁽¹³⁾ reported that the mean age of the patients was 17.4 years (range: 13–23 years). The mean preoperative clinical TFA was 23.4° (range: 18°–28°) that improved after surgery to a mean postoperative value of 5.8° (range: 4°–7°). These two studies are similar to our results.

The current study showed that the mean preoperative intermalleolar distance was 14.7cm (range: 12-19 cm) that decreased significantly to 5.11cm (range: 2–6 cm). With little differences in the results compared to study of **Jaiman et al.**⁽¹³⁾ that reported the preoperative IMD was 13.5 cm (range: 13–21cm) that improved to a mean postoperative value of 2.3 cm (range: 1–5 cm). **Ranjan et al.**⁽¹⁴⁾ recorded that the mean preoperative IMD was 17.3 cm (range: 12–24 cm), which was improved significantly after treatment to average value of 3.9 cm (range: 2–7 cm). Both of these studies have similar results of the current study.

Regarding clinical results, this was assessed in the current study by the hospital for special surgery (HSS) scoring system. The HSS score for these patients improved from a mean of 62 points preoperatively. This score increased to a mean of 84 points postoperatively more than have of the studied groups 20 limbs (65.16%) had excellent clinical results, 9 limbs (28.08%) had good clinical results and 3 limbs (9.36%) had fair clinical results. This is in agreement with the study of **Stähelinm et al.** ⁽¹⁵⁾ who found that 21 knees were improved in average HSS score from 65 points preoperatively to 84 points. Results were rated as excellent in 11 knees, good in 8 knees, and fair in 2 knees. We disagree with the study of **Buda** ⁽¹⁶⁾ who retrospectively reviewed 32 valgus knees (mean age: 41.4 ± 11.2 years) which recorded improvement in HSS score with mean post-operative range of about 84-88.

From the results obtained in this study and from the review of literature we found that, closed wedge osteotomy when done for proper indication with thorough preoperative planning could offer a satisfactory and a more successful results than other methods mentioned for operative correction of genu valgum deformity.

CONCLUSION

Distal femoral varus osteotomy can be a reliable procedure for the treatment of valgus knee deformity. In this procedure, with more tibiofemoral angle correction, more congruence angle correction can be achieved. Therefore, along with genu valgum correction, the patella should be stabilized simultaneously.

REFERENCES

1. **Castaneda P, Urquhart B, Sullivan E et al. (2008):** Hemiepiphyodesis for the correction of angular deformity about the knee. *J Pediatric Orthopaedic*, 28: 188-91.
2. **Jowett C, Barry M (2016):** Lower Limb Alignment and Leg Length Discrepancy. In *Paediatric Orthopaedics in Clinical Practice*. Springer, London. Pp: 189-203. <https://link.springer.com/book/10.1007/978-1-4471-6769-3>
3. **Ekwedigwe H, Enweani U, Madu K et al. (2020):** Clinical measurement of angular profile of the knee and correlation with intermalleolar distance in children in Enugu metropolis. *Nigerian Journal of Clinical Practice*, 23: 1-7.
4. **Dhar S, Butt M, Mir M et al. (2009):** A reciprocating ledge technique in closing wedge osteotomy for genu valgum in adolescents. *Journal of Orthopaedic Surgery*, 17 (3): 313-6.
5. **Gautam V, Maini L, Gupta R et al. (2013):** Flexion test in the coronal plane deformities of the knee. *J Clin Orthop Trauma*, 4: 115-118.
6. **Cameron J, McCauley J, Kermanshahi A et al. (2015):** Lateral opening-wedge distal femoral osteotomy: Pain relief, functional improvement, and survivorship at 5 years. *Clin Orthop Relat Res.*, 473 (6): 2009-2015.
7. **Stevens P, MacWilliams B, Mohr R (2004):** Gait analysis of stapling for genu valgum. *Journal of Pediatric Orthopaedics*, 24: 70-74.
8. **Scott C, Nutton R, Biant L (2013):** Lateral compartment osteoarthritis of the knee: Biomechanics and surgical management of end-stage disease. *The Bone & Joint Journal*, 95 (4): 436-444.
9. **Dean R, Beck E, Waterman B (2021):** Knee malignancy: Is there a role for correction in primary ACLR. <https://www.sciencedirect.com/science/article/abs/pii/S1060187221000393>
10. **Ambrožič B, Slokar U, Brulc U et al. (2021):** Anatomic Knee Joint Realignment. In *Clinical Anatomy of the Knee*. Springer, Cham. Pp: 207-247. <https://link.springer.com/book/10.1007/978-3-030-57578-6>
11. **Micicoi G, Grasso F, Kley K et al. (2021):** Osteotomy around the knee is planned toward an anatomical bone correction in less than half of patients. *Orthopaedics & Traumatology: Surgery & Research*, 107 (4): 102897.
12. **Gupta V, Kamran G, Singh D et al. (2014):** Wedgeless 'V' shaped distal femoral osteotomy with internal fixation for genu valgum in adolescents and young adults. *Acta Orthop Belg.*, 80 (2): 234-240.
13. **Jaiman A, Prakash J, Chopra R et al. (2020):** Supracondylar chevron osteotomy for correction of genu valgum deformity in constrained resources. *Medical Journal of Babylon*, 17 (3): 247-252.
14. **Ranjan R, Sud A, Kanojia R et al. (2019):** Results of Supracondylar "V" Osteotomy for the Correction of Genu Valgum Deformity. *Indian Journal of Orthopaedics*, 53: 366-373.
15. **Stähelin T, Hardegger F, Ward J (2000):** Supracondylar osteotomy of the femur with use of compression: Osteosynthesis with a malleable implant. *J Bone Joint Surg Am.*, 82 (5): 712-722.
16. **Buda R, Castagnini F, Gorgolini G et al. (2017):** Distal femoral medial closing wedge osteotomy for degenerative valgus knee: mid-term results in active patients. *Acta Orthop Belg.*, 83 (1): 140-5.