

## Axillary Lymph Node Dissection versus Axillary Radiation in Patients with Positive Sentinel Lymph Node Biopsy in Early Breast Cancer

HEBA THARWAT ABD EL AZIZ, M.D.; EL-SAYED M. ABD-ELWAHAB, M.D. and HANY A. EL HADY, M.D.

The Department of Surgery, College of Medicine for Girls, Al-Azhar University, Egypt

### Abstract

**Background:** Patients with cancer detected in a sentinel lymph node biopsy have undergone axillary lymph node dissection (ALND), which is an effective but invasive surgical procedure associated with adverse side effects, such as lymphedema and difficulty moving the arm. Axillary radiation delivers outcomes that are similar to axillary lymph node dissection and with fewer side effects.

**Aim of Study:** To define which patient may benefit from axillary dissection and who may benefit from axillary radiation without the hazards of axillary dissection in Patients with positive sentinel lymph node biopsy in early breast cancer patients.

**Patients and Methods:** The 150 female patients with successful lymphatic mapping for early breast cancer T1 and T2, who were clinically node-negative, were randomly assigned prior to SLNB to receive either ALND (n=75) or axillary radiotherapy (n=75). The first 75 patients who were positive for SLNB were eligible for ALND (standard level I and II clearance) and the second consecutive positive 75 patients of the study were eligible for axillary radiotherapy.

**Results:** Lymphedema rates were (2.6%) in the axillary dissection group and no arm edema in the axillary radiotherapy group. Long thoracic nerve injury rates were (2%) in the axillary dissection group and no nerve injury in the axillary radiation group, although no other nerve or vascular injuries were reported within two groups. Five year axillary recurrence rates (0.7% ALND vs 0.2% axillary radiotherapy). Most patients received adjuvant chemotherapy (68.6%) and/or endocrine therapy (31.4%) 47.

**Conclusion:** Axillary radiation in patients with sentinel lymph node biopsy positive in early breast cancer may be considered as a standard therapy instead of axillary lymph node dissection.

**Key Words:** Early breast cancer – Sentinel lymph node biopsy – Axillary clearance – Axillary radiotherapy.

### Introduction

**AXILLARY** lymph node (ALN) status is a key prognostic factor in patients with breast cancer. ALN staging and loco-regional control can be performed by (ALND), but this procedure is associated with the potential for serious complications, such as lymphedema and nerve damage [1].

In previous years, the number of positive lymph nodes was an important criterion to indicate systemic therapy [2]. However, recently, biological markers and tumor biology have been rapidly gaining importance [3].

The sentinel lymph node biopsy is a diagnostic test that is used to determine the status of regional lymph nodes. The sentinel node is the first lymph node to receive drainage from a tumor [4]. Sentinel lymph node biopsy (SLNB) represents an opportunity to reduce axillary morbidity while obtaining lymph node staging. Several trials have proven the safety of omitting axillary dissection (AD) in the case of negative SLNB [5].

Sentinel node biopsy (SNB), a procedure with fewer potential complications, has been proposed as an alternative. The accuracy of SNB has been confirmed in several clinical studies and SNB has become the standard surgical procedure for axillary staging [6]. De-escalation from ALND to SLNB significantly decreased the risk of arm lymphedema and improved the patients' quality of life [7].

Axillary lymph node dissection is associated with harmful and often persistent side effects, particularly lymphoedema and restriction in shoulder mobility. Axillary lymph node dissection has long been regarded as standard if treatment of the axilla is indicated for patients with a positive sentinel node [8].

For a long time, the usage of regional lymph node irradiation in early breast cancer was very restrictive. Most international guidelines advise radiotherapy of the lymphatics only in the case of more than 3 positive lymph nodes. The commonly recommended treatment volume merely encompassed the supraclavicular fossa. This cautious approach was mainly based on insufficient data regarding the benefit of additional lymph node irradiation in terms of survival and the supposed risk of side effects such as lymphedema and plexopathy. Therefore, complete omission of AD in the case of positive SLNB has been the next progressive step to reduce treatment-related side effects. However, the surgical approach led to an almost 2-fold increase in lymphedema compared with radiotherapy [5].

Some discussion could occur in case of positive sentinel lymph node and no axillary lymph node dissection about the usefulness of chest wall and/or lymph nodes irradiation [9]. Therefore, complete omission of AD in the case of positive SLNB has been the next progressive step to reduce treatment-related side effects [10].

Before the introduction of sentinel node biopsy, axillary radiotherapy was described as an alternative for axillary lymph node dissection in clinically nodenegative patients. Satisfactory local control was reported with axillary radiotherapy, with fewer side effects compared with axillary lymph node dissection [11]. Arm lymphedema and shoulder impairment can appear also after adjuvant breast radiotherapy, but less frequently than after ALND [12]. We aimed to compare ALND and axillary Radiotherapy in positive SLNB regarding recurrence, lymphedema, and nerve injury.

### Patients and Methods

This prospective clinical study enrolled 150 female patients with successful lymphatic mapping for early breast cancer T1 and T2, who were clinically nodenegative and who received either breast conservative surgery or total mastectomy.

The patients were consecutively admitted from March 2012 to March 2015, in two major university-affiliated hospitals, College of Medicine, Al-Azhar University, Cairo, Egypt. The patients aged 30-70 years (mean 46.5 years).

Patients signed an informed consent and the study was approved by The Local Ethical Committee of College. Our patients were randomly assigned prior to SLNB to receive either ALND (n=75) or

axillary radiotherapy (n=75). The first 75 patients who were positive for SLNB were eligible for ALND (standard level I and II clearance) and the second consecutive positive 75 patients of the study were eligible for axillary radiotherapy. Negative SLNB cases were excluded.

The study excluded patients with inflammatory breast cancer, bilateral breast cancer, neoadjuvant systemic therapy, medical history of previous malignancy, and previous axillary surgery or radiotherapy, and failed mapping (non-identified SLN). Multifocal disease was not an exclusion criterion, axillary treatment for patients with a tumor-positive sentinel node had to start within 8 weeks after the sentinel node biopsy and breast surgery (conservative surgery or total mastectomy). Consequently, systemic treatment, if indicated, was administered after completing the axillary treatment.

Axillary dissection of anatomical levels I and II, through a curvilinear incision in the axillary hair line 4-5cm below the most superior aspect of the axilla, the incision extends from anteriorly the lateral border of the pectoralis major muscle and posteriorly to the anterior border of the latissimusdorsi muscle. Axillary radiotherapy consisted of 50Gy divided doses to all axillary nodes, levels I, II and III and supraclavicular lymph nodes. The booster dose of 10Gy was administered to tumor-bed (inconservative breast surgery).

### *Surgical technique of SLNB:*

Under general anesthesia 3-5mL of blue dye (Guerbet patent blue V sodium 2.5%, Laboratoire Guerbet, France-imported by Egy-Drug, Cairo) was injected around the tumor (peri-tumor), intratumoral approach and sub-dermal injection was done in some cases, Fig. (1A). After 5 to 7 minutes, an axillary incision was done and a blue lymphatic tract were identified. These tracts were dissected until a blue-stained lymph node (sentinel node) was identified, Fig. (1B). The sentinel node was excised and sent for histo-pathological examination. Local treatment of the breast consisted of breast conserving surgery including whole breast radiotherapy or mastectomy with chest wall irradiation.

Patients were followed-up according to (history, physical examination, and ultrasonography) every year for 5 years.

Data analysis was carried out using SPSS Version-23 software for percent distribution and significance using Chi-Square Tests. Statistical significance was set at  $p < 0.05$ .

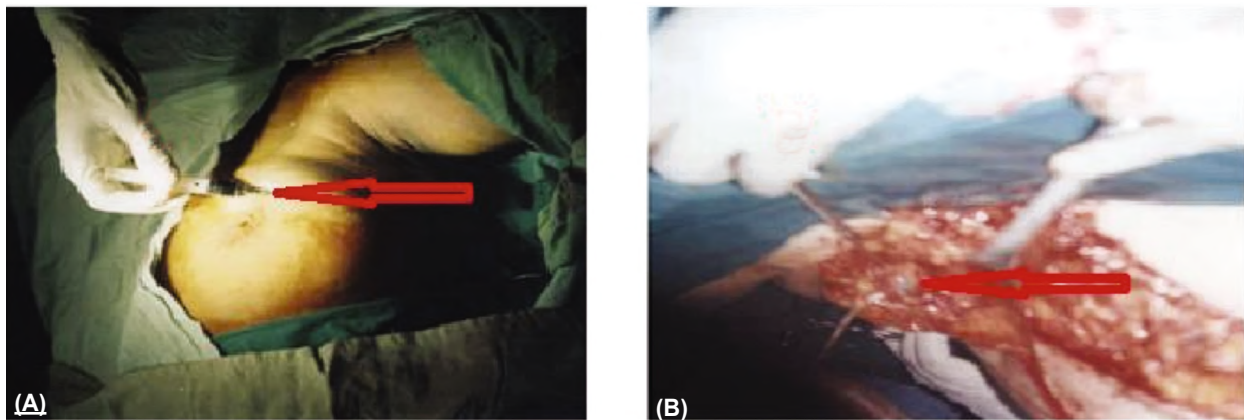


Fig. (1): (A) Injection of blue dye intratumorly (arrow) (B) Identified blue SLN (arrow).

**Results**

Between March 2012 to March 2015, 150 patients were enrolled at a single center, 75 patients were randomly assigned to receive axillary lymph node dissection level I and II, and 75 to receive axillary radiotherapy. All of them were successful SLN mapping and sentinel lymph nodes positive, the patients with failure of mapping and sentinel lymph nodes negative were excluded from our study. We apply the blue dye method only for all patients.

The majority (63.4%), 95 patients of the 150 patients with positive SLNB underwent total mastectomy and (36.6%) 55 patients underwent breast-conserving surgery. In both groups (76.6%) 115 patients of the sentinel node metastases were macrometastases (deposits of more than 2.0mm in size), (14.6%) 22 patients micro metastases (less than 0.2mm and/or more than 200 cells, but none >2.0mm) and (8.6%) 13 patients isolated tumor cells. Post treatment lymphedema rates were (2.6%) 4 patients in the axillary dissection group and no arm edema in the axillary radiotherapy group. Long thoracic nerve injury rates were (2%) 3 patients in the axillary dissection group and no nerve injury in the axillary radiation group, although no other nerve or vascular injuries were reported in both groups. Five-year axillary recurrence rates (0.7%, one patient ALND vs. 2%, 3 patients' axillary radiotherapy).

Most patients received adjuvant chemotherapy (68.6%), while 103 patients and/or endocrine therapy (31.4%) 47 patients.

Axillary radiotherapy in positive SLNB is an effective treatment with fewer complications than axillary lymph node dissection.

Table (1): Characteristics of the patients.

Patients characteristic	Axillary lymph node dissection (n=75)	Axillary radiotherapy (n=75)	Total (n=150)
<i>Menopausal status:</i>			
Premenopausal	41 (54.6%)	36 (48%)	77
Postmenopausal	34 (45.3%)	39 (52%)	73
<i>Preoperative ultrasound axilla:</i>			
Done	75 (100%)	75 (100%)	150
Not done	0 (0%)	0 (0%)	0
<i>Tumor side:</i>			
Right	40 (53.4%)	55 (73.3%)	95
Left	35 (46.6%)	20 (26.7%)	55
<i>Clinical tumor size:</i>			
T1	20 (26.7%)	31 (41.4%)	51
T2	55 (73.3%)	44 (58.6%)	99
<i>Tumor type:</i>			
Infiltrating ductal	74 (98.6%)	73 (97.4%)	147
Infiltrating lobular	1 (1.4%)	2 (2.6%)	3
<i>Clinical N classification:</i>			
N0	75 (100%)	75 (100%)	150
N1	0 (0%)	0 (0%)	0
<i>Multifocal disease:</i>			
Yes	2 (2.6%)	1 (1.4%)	3
No	73(97.4%)	74 (98.6%)	147
<i>Type of breast surgery:</i>			
Mastectomy	48 (64%)	47 (62.6%)	95
Breast-conserving surgery	27 (36%)	28 (37.4%)	55
<i>Adjuvant radiotherapy:</i>			
Breast	27 (36%)	28 (37.4%)	55
Chest wall	48 (64%)	47 (62.6%)	95
<i>Systemic treatment:</i>			
Chemotherapy	47 (62.6%)	56 (74.6%)	103
Hormonal therapy	28 (37.4%)	19 (25.4%)	47
<i>Result of mapping:</i>			
Successful	75 (100%)	75 (100%)	150
Failed	0 (0%)	0 (0%)	0
Number of positive node	75 (100%)	75 (100%)	150
<i>Size of the largest sentinel node metastasis:</i>			
Macro-metastasis	60 (80%)	55 (73.4%)	115
Micro-metastasis	10 (13.4%)	12 (16%)	22
Isolated tumor cells	5 (6.6%)	8 (10.6%)	13

Table (2): Complications.

Item	Axillary lymph node dissection (n=75)	Axillary radiotherapy (n=75)	Total complications (n=150)
Arm lymphedema	4 (2.6%)	0 (0%)	4
Axillary recurrence	1 (0.7%)	3 (2%)	4
<i>Nerve injury:</i>			
Long thoracic	3 (2%)	0 (0%)	3
Other nerves	0 (0%)	0 (0%)	0

## Discussion

Axillary recurrence is an uncommon event in patients without lymph node involvement (N0) or with limited involvement in the axilla (N1); its incidence ranges between 0% and 3.6% [13]. The increasing number of patients diagnosed with early breast cancer and their excellent prognosis have resulted in less invasive treatments to decrease late sequelae. The evidence for omission of axillary dissection without impairment of local control and overall survival (OS) is still weak [14]. Patients with N2-N3 lymph node involvement, however, required radical lymphadenectomy and radiation therapy of the axilla to achieve adequate loco-regional control [15].

The authors of a systematic review and meta-analysis concluded that SLNB only is an adequate treatment for patients with up to micro-metastases. For those patients with macro-metastases in the SLNB, omission of AD is a feasible option provided that the patients receive adequate adjuvant treatment including adjuvant radiotherapy to the breast [16].

The clinical value of sentinel lymph node biopsy has been validated in numerous randomized studies, including patients with early clinically node negative breast cancer. Completion of axillary lymph node dissection is unnecessary in case of a negative sentinel lymph node biopsy, without any difference in terms of regional control or disease-free and overall survival [17]. The aim of prophylactic nodal irradiation is to eradicate micro/macro metastases, to reduce regional recurrence and distant metastases and to improve survival. Regional nodal Irradiation improved slightly distant metastase free survival and overall survival in randomized trials [18].

Of the 4806 patients entered, 1425 patients had a tumor-positive SNB: 744 in the ALND-arm and 681 in the ART-arm, 60% with a macro-metastasis. Both treatment arms achieved a median 10-year follow-up and were comparable regarding age, tumor size, grade, tumor type, and adjuvant systemic treatment [19].

In all previous studies evaluating sentinel lymph node biopsy, irradiation was limited to the axilla or, in some cases extended to infra/supraclavicular areas. Because the trials used, in most of the patients, tangential fields including a large part of the axilla, this area must be considered as a target volume in case of micro-or macro-metastases. The usefulness of high tangential fields is a matter of discussion. It has been estimated that the level I, II and III of the axilla were covered on 66%, 44%, and 31 %, respectively, with standard tangential field, and 86%, 71% and 73% with high tangential fields [20].

In another study, high tangential fields provide also a better coverage of level I and II axillary lymph nodes [21]. In our study all axillary nodes levels I, II and III and supraclavicular lymph nodes were covered in 100% of patients.

Lymphoedema in the ipsilateral arm was noted significantly more often after axillary lymph node dissection than after axillary radiotherapy at 1 year, 3 years, and 5 years [22]. An axillary dissection was significantly predicted for upper extremity lymphedema (25.0% vs 9.4%; hazard ratio, 3.20; 95% confidence interval, 1.168.86; PZ.021), but irradiation of the regional nodes was not predictive (hazard ratio, 1.44; 95% confidence interval, 0.46-4.54; PZ.532). Among the 108 patients who underwent ALND, the total number of lymph nodes dissected did not predict for lymphedema (PZ.600)

[23].

Indeed, the axillary recurrence rates were 0.43% after axillary lymph node dissection and 1.19% after radiotherapy, without any differences in disease-free survival or overall survival risk of arm lymphedema was significantly higher in the axillary lymph node dissection arm (23 vs. 1 % at 5 years) [9]. Axillary recurrence occurred in four of 744 patients in the axillary lymph node dissection group and seven of 681 in the axillary radiotherapy group over the entire follow-up period [22].

The 5-year axillary recurrence rate was 0.43% after ALND and 1.19% after axillary radiotherapy (ART); the difference was not statistically significant. Lymphoedema was noted significantly more often after ALND than after ART at 1 year, 3 years, and 5 years. There were no significant differences in shoulder function or quality of life [10]. The rate of axillary recurrence was identical in both arms (axillary lymph node dissection: 2%; radiotherapy: 1.9%) as disease-free survival and overall survival [24]. Death due to breast cancer occurred in 53 (7%) patients in the axillary lymph node dissection

group and 54 (8%) in the axillary radiotherapy group [22].

In the current study, the five-year axillary recurrence rates (0.7%, one patient ALND vs. 2%, 3 patients' axillary radiotherapy). Lymphedema rates were (2.6%) 4 patients in axillary dissection group and no arm edema in the axillary radiotherapy group. Long thoracic nerve injury rates were (2% vs 0%) in axillary dissection and axillary radiotherapy respectively.

#### Conclusion:

Both axillary lymph node dissection and axillary radiation provide excellent and comparable locoregional control in patients with a positive sentinel node. Axillary radiation is a safe, less toxic, well-tolerated procedure associated with fewer complications and can be considered as a standard procedure.

#### Data availability:

Data is available on request. Please contact the corresponding author (El-Sayed Mahmoud Abd-Elwahab, MD).

#### Conflicts of interest:

The authors declare that there is no conflict of interest regarding the publication of this paper.

#### Disclosure:

No funders have any role in the design of the study; in the collection, analyses, or interpretation of data; in the writing of the manuscript; or in the decision to publish the results.

### References

- HAN A., MOON H.G., KIM J., et al.: Reliability of sentinel lymph node biopsy after neoadjuvant chemotherapy in breast cancer patients. *J. Breast Cancer*, 16: 378e385, 2013.
- CARTER C.L., ALLEN C. and HENDERSON D.E.: Relation of tumour size, lymph node status and survival in 24,740 breast cancer cases. *Cancer*, 73: 505-508, 1989.
- CALDOS C. and APARICIO S.A.: The molecular outlook. *Nature*, 415: 484-485, 2002.
- ISMAIL J., MANFRED K. and JEAN Y.P.: Surgery for Breast Carcinoma, Sentinel Lymph Node Biopsy. *Atlas of breast surgery*, Chapter 6: 61-84, 2006.
- PETER N. and SILLA H.K.: Lymph Node Radiotherapy Instead of Extended Axillary Surgery: The New Standard? *Breast Care*, 13: 173-175, 2018.
- KIM T., GIULIANO A.E. and LYMAN G.H.: Lymphatic mapping and sentinel lymph node biopsy in early-stage breast carcinoma: A metaanalysis. *Cancer*, 106: 4e16, 2006.
- LAND S.R., KOPEC J.A., JULIAN T.B., BROWN A.M., ANDERSON S.J., KRAG D.N., et al.: Patient-reported outcomes in sentinel node-negative adjuvant breast cancer patients receiving sentinel-node biopsy or axillary dissection: National surgical adjuvant breast and bowel project phase III protocol B-32. *J. Clin. Oncol.*, 28: 3929-36, 2010.
- DEUTSCH M., LAND S., BEGOVIC M. and SHARIF S.: The incidence of arm edema in women with breast cancer randomized on the National Surgical Adjuvant Breast and Bowel Project study B-04 to radical mastectomy versus total mastectomy and radiotherapy versus total mastectomy alone. *Int. J. Radiat. Oncol. Biol. Phys.*, 70: 1020-24, 2008.
- HENNEQUIN C., GUILLERM S. and QUERO L.: The sentinel lymph node of breast cancer and the radiation oncologist. *Cancer/Radiotherapy*, 22: 473-477, 2018.
- DONKER M., VAN TIENHOVEN G., STRAVER M.E., et al.: Radiotherapy or surgery of the axilla after a positive sentinel node in breast cancer (EORTC 10981-22023 AMAROS): A randomized multicentre, open-label, phase 3 non-inferiority trial. *Lancet Oncol.*, 15: 1303-1310, 2014.
- HOEBERS F.J., BORGER J.H., HART A.A., PETERSE J.L., TH E.J. and LEBESQUE J.V.: Primary axillary radiotherapy as axillary treatment in breast-conserving therapy for patients with breast carcinoma and clinically negative axillary lymph nodes. *Cancer*, 88: 1633-42, 2000.
- LEE T.S., KILBREATH S.L., REFSHAUGE K.M., HERBERT R.D. and BEITH J.M.: Prognosis of the upper limb following surgery and radiation for breast cancer. *Breast Cancer Res. Treat*, 110: 19-37, 2008.
- GIULIANO A., McCALL L., BETISCH P., WITH WORTH P., BLUMENCRANZ P., LEITCH M., ET AL.: Locoregional recurrence after sentinel lymph node dissection with or without axillary dissection in patients with sentinel lymph node metastases. *Ann. Surg.*, 252: 426-33, 2010.
- GIULIANO A.E., BALLMAN K.V., McCALL L., et al.: Effect of axillary dissection vs no axillary dissection on 10-year overall survival among women with invasive breast cancer and sentinel node metastasis: The ACOSOG Z0011 (Alliance) randomized clinical trial. *JAMA*, 318: 918-926, 2017.
- GALIMBERTI V., COLE B.F., ZURRIDA S., VIALE G., LUINI A., VERONESI P., et al.: IBCSG 23-01 randomised controlled trial comparing axillary dissection versus no axillary dissection in patients with sentinel node micrometastases. *Lancet Oncol.*, 14: 297-305, 2013.
- RAM R., SINGH J. and McCAIG E.: Sentinel node biopsy alone versus completion axillary node dissection in node positive breast cancer: Systematic review and metaanalysis. *Int. J. Breast Cancer*, 513-78, 2014.
- LAND S.R., KOPEC J.A., JULIAN T.B., BROWN A.M., ANDERSON S.J., KRAG D.N., et al.: Patient-reported outcomes in sentinel node-negative adjuvant breast cancer patients receiving sentinel-node biopsy or axillary dissection: National surgical adjuvant breast and bowel project phase III protocol B-32. *J. Clin. Oncol.*, 28: 3929-36, 2010.

- 18- WHELAN T.J., OLIVOTTO I.A., PARULEKAR W.R., ACKERMAN I., CHUA B.H., NABID A., et al.: Regional nodal irradiation in early-stage breast cancer. *N. Engl. J. Med.*, 373: 307-16, 2015.
- 19- RUTGERS E.J., DONKER M., PONCET C., STRAVER M.E., MEIJNEN P., VAN DE VELDE C.J., et al.: Radiotherapy or surgery of the axilla after a positive sentinel node in breast cancer patients: 10 year follow-up results of the EORTC AMAROS trial (EORTC 10981/22023) [abstract]. In: Proceedings of the 2018 San Antonio Breast Cancer Symposium; 2018 Dec 4-8; San Antonio, TX. Philadelphia (PA): AACR; *Cancer Res.*, 79 (4 Suppl): Abstract nr GS4-01, 2019.
- 20- REZNIK J., CICHETTI M.G., DEGASPE B., FITZGERALD T.J.: Analysis of axillary coverage during tangential radiation therapy to the breast. *Int. J. Radiat. Oncol. Biol. Phys.*, 61: 163-8, 2005.
- 21- BELKACÉMI Y., ALLAB-PAN Q., BIGORIE V., KHODARI W., BEAUSSART P., TOTOBENAZARA J.L., et al.: The standard tangential fields used for breast irradiation do not allow optimal coverage and dose distribution in axillary levels I-II and the sentinel node area. *Ann. Oncol.*, 24: 2023-8, 2013.
- 22- HELEN A.W., JEAN H.G.K., LORENZO O., WILLEM H.B., HUUB C.J., GRARD A.P.N., et al.: Radiotherapy or surgery of the axilla after a positive sentinel node in breast cancer (EORTC 10981-22023 AMAROS): A randomized, multicenter, open-label, phase 3 non-inferiority trial. *Lancet Oncol.*, 15: 1303-10., 2014
- 23- DIANE C.L., NICK A.I., COLIN E.C., ATILLA S., M.P.H. and SUSHIL B.: Regional Recurrence Rates With or Without Complete Axillary Dissection for Breast Cancer Patients with Node-Positive Disease on Sentinel Lymph Node Biopsy after Neoadjuvant Chemotherapy. *Advances in Radiation Oncology*, 1-8, 2019.
- 24- SAVOLT A., PELEY G., POLGAR C., UDVARHELYI N., RUBOVSKY G., KOVACS E., et al.: Eightyear follow-up result of the OTOASOR trial: The optimal treatment of the axilla-surgery or radiotherapy after positive sentinel lymph node biopsy in earlystage breast cancer: A randomized, single center, phase III, non-inferiority trial. *Eur. J. Surg. Oncol.*, 43: 672-9, 2017.

## استئصال الغدد الليمفاوية تحت الإبط مقابل العلاج الإشعاعي لمرضى الحالات المبكرة لأورام الثدي عند إيجابية عينة الغدة الحارسة

البحث عن الغدة الليمفاوية الحارسة في مرضى سرطان الثدي أثبتت دورها الفعال في تجنب الإستئصال الكلي للغدد الليمفاوية تحت الإبط بما يترتب عليه من مضاعفات مثل صعوبة حركة الذراع مع حدوث تورم لمفاوى بالذراع. في هذه الدراسة نبحث عن إمكانية إستخدام الإشعاع الموجه تحت الإبط بديلاً عن إستئصال الغدد ونتائج كل طريقة.

اشتملت الدراسة على ١٥٠ سيدة من الذين يعانون من سرطان الثدي في المرحلة الأولى أو الثانية والذين كانوا لا يوجد عندهم بالفحوص وإكلينيكيًا تضخم بالغدد الليمفاوية تحت الإبط. تم تقسيم المرضى إلى مجموعتين اشتملت كل مجموعة على ٧٥ سيدة على أن يتم العلاج في المجموعة الأولى بعد فحص الغدة الحارسة وثبوت إيجابية العينة بإستئصال الغدد الليمفاوية تحت الإبط والمجموعة الثانية بالعلاج الإشعاعي الموجه تحت الإبط. تم إستبعاد امضى الذين ثبت سلبية الغدة الحارسة عندهم.

كانت نتائج البحث أنه على المدى القصير أن نسبة إصابة العصب الصدرى الطويل كانت ٢٪ في مجموعة الجراحة بينما كانت ٠٪ في مجموعة الإشعاع. كذلك كانت نسبة حدوث تورم الذراع ٢.٦٪ في مجموعة الجراحة بينما كانت ٠٪ في مجموعة الإشعاع. على المدى الطويل كانت نسبة الإرتجاع للثانويات ٠.٧٪ في مجموعة الجراحة بينما كانت ٠.٢٪ في مجموعة الإشعاع. لذلك إستنتجنا أن إستخدام الإشعاع الموجه تحت الإبط بديلاً عن إستئصال الغدد بعد فحص الغدة الحارسة وثبوت إيجابية العينة يمكن أن يكون العلاج الأمثل.