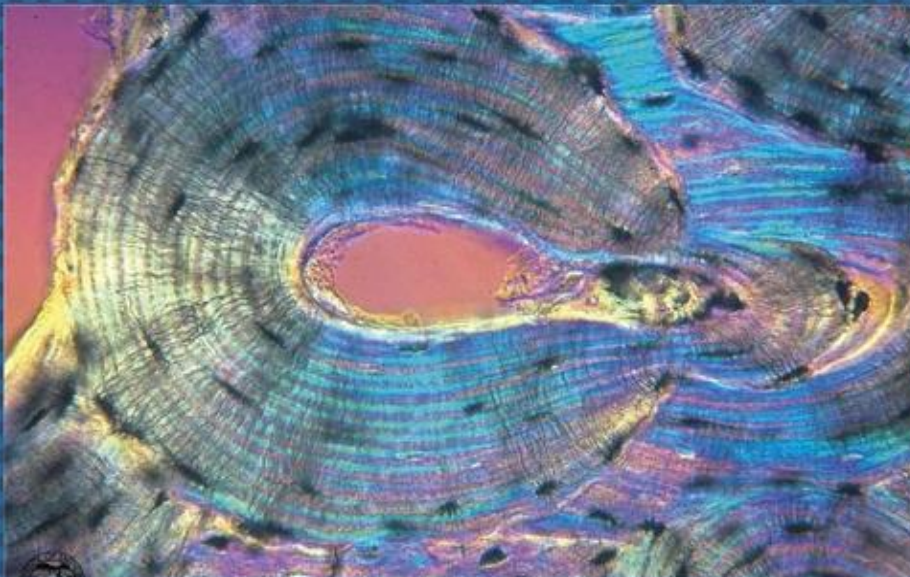




EGYPTIAN ACADEMIC JOURNAL OF
BIOLOGICAL SCIENCES
HISTOLOGY & HISTOCHEMISTRY

D



ISSN
2090-0775

WWW.EAJBS.EG.NET

Vol. 13 No. 2 (2021)



Carisoprodol-Induced Histological and Immunohistochemical Changes in Spleen of Pregnant Rats

Asmaa A. Abo Elqasem

Lecturer of Immunology, Zoology and Entomology Department, Faculty of Science,
Al-Azhar University (Girls branch), Cairo, Egypt

E.Mail : asmaamohamed.sci.g@azhar.edu.eg

ARTICLE INFO

Article History

Received:17/6/2021

Accepted:24/7/2021

Keywords:

Carisoprodol,
histological
studies,
immunohistochemical
studies,
pregnant rats,
spleen.

ABSTRACT

Background: Carisoprodol (Somadril®) is a centrally acting skeletal muscle relaxant that is commonly used to treat serious musculoskeletal disorders. Carisoprodol's mechanism of action is unknown and it is often attributed to its active metabolite, meprobamate.

Objective: This study aimed to detect histopathological and immunohistochemical changes in the tissues of the splenic pregnant rats treated orally with Carisoprodol (Soma). **Method:** Thirty pregnant female albino rats were randomly categorized into three groups. The first group was a negative control and administered oral doses of distilled water. The other two groups were administered oral doses of carisoprodol in the distilled water equivalent to 10.8 mg and 21.6 mg/100g body weight/day respectively for 15 days from the 6th day to the 20th day of gestation.

Results: Histological and immunohistochemical studies have been performed on the tissue of the spleen to detect histopathological and immunohistochemical changes. Compared to untreated (negative control) and pregnant rats treated with carisoprodol, the treated rats showed numerous histopathological and immunochemical changes.

Conclusion: Treatment of pregnant rats with carisoprodol has induced many atrophic changes in the tissue of the spleen in pregnant rats, so the use of this drug during pregnancy should be under strict protection.

INTRODUCTION

Muscle relaxants, also known as myorelaxants, are a class of chemical compounds that relax the skeletal muscle and are used to minimize the need for anaesthesia and make intubation easier (Vardanyan and Hruby, 2006).

Skeletal muscle relaxants can work in both the central and peripheral nervous systems. Carisoprodol (Soma), chlorphenesin carbamate (Maolate), and chlorzoxazone are centrally acting skeletal muscle relaxants (Parafon Forte). Dantrolene, atracurium besylate (Tracrium), and decamethonium bromide (Syncurine, C-10) are peripheral-acting relaxants (Plumlee, 2004). Carisoprodol (N-isopropyl-2-methyl-2-propyl-1,3-propanediol dicarbamate) is a muscle-skeletal relaxant that was licenced as an unregulated drug in the United States (US) in 1959 for the treatment of acute and painful musculoskeletal disorders (Patil *et al.*, 2020).

It has been on the market for more than 40 years and is widely used with over 10 million prescriptions filled per year (Rall, 1985). Because of their role in the US opioid crisis, high-risk combinations of controlled drugs, such as those containing opioid analgesics, are being scrutinised more closely. The triple-drug category - opioids, benzodiazepines, and skeletal muscle relaxants, especially carisoprodol - should not be prescribed, according to prescribing guidelines (Wang *et al.*, 2019). Soma, Carisoma, Sodol, Somadril, and Vanadom are trade names for carisoprodol, which comes in 250 and 350 mg generic formulations (Simon *et al.*, 2010). Due to the risk of dependency and abuse, the recommended adult dose is 250 to 350 mg three to four times daily for just two to three weeks (Zacny *et al.*, 2011). It is metabolised by the cytochrome P450 oxidase isozyme CYP2C19 in the liver and excreted by the kidneys, with a half-life of approximately 8 hours (Bramness *et al.*, 2007). Dizziness, drowsiness, nausea, and psychomotor weakness are all side effects of carisoprodol (Raffel *et al.*, 1969). Drug addiction, drug dependency, drug overdose, extreme withdrawal, progressive obtundation, coma, neuromuscular rigidity, myoclonus, and seizures can occur at high doses or with long-term use (National Institutes of Health 2017). Reeves and Carter (1999) discovered that carisoprodol causes recurrent withdrawal symptoms and toxic effects, which are consistent with previous case reports and series. Carisoprodol, on the other hand, is a pregnancy category C drug; animal tests show that it affects foetal growth and postpartum survival.

Carisoprodol's mechanism of action is unknown, although it is often attributed to that of its active metabolite, meprobamate (Carbonaro *et al.*, 2020). Carisoprodol is

metabolised to meprobamate (Olsen *et al.*, 1995), which has been shown to have an addiction risk comparable to benzodiazepines, which are widely abused drugs (Rho *et al.*, 1997). Meprobamate is known to produce phenomena that lead to physical and psychological dependence (Jackson *et al.*, 2014).

Carisoprodol, on the other hand, is now known to control and specifically gate -aminobutyric acid types A receptors (GABA A Rs), the inhibitory neurotransmitter receptors found in mammalian brains. This may be attributable to carisoprodol's potential to improve the sedative effects of central nervous system (CNS) depressants, raising the risk of violence (Kumar and Dillon, 2015; Gonzalez *et al.*, 2009). Carisoprodol was classified as Schedule IV in the United States due to its increased risk of adverse effects. Carisoprodol was listed as schedule A in Norway and was taken off the market, although it can still be used by patients who have been specially approved. Carisoprodol comes in the form of somadril in Egypt, which contains 200 mg carisoprodol, 160 mg paracetamol, and 32 mg caffeine. Mina Pharm has a prescription medication for pharmaceutical regulations as a result of Minister of Health and Population Decision No.172 of 2011 (Abouel-Magd, 2018). The analgesic and antipyretic effects of paracetamol (acetaminophen) are commonly used over-the-counter (Bernal *et al.*, 2010). Hepatic dysfunction was exacerbated by paracetamol, which could lead to liver transplantation (Reuben *et al.*, 2010). Caffeine is the most commonly consumed CNS stimulant, and it is absorbed quickly and almost entirely (up to 90%) by the stomach, with peak plasma concentrations occurring in 20 to 40 minutes. As a result, toxic levels can be reached easily and last for a long time after caffeine's 3- to 10-hour half-life has passed (Holstege *et al.*,

1993). Drugs may induce spleen enlargement through a direct effect on spleen cells or as a side effect of disorders in other organs or systems, such as the liver or the haematoimmunological system. Some medications cause serious haemolysis and splenomegaly (Petroianu, 2007). There have been no studies available regarding changes in the splenic tissue after administration of carisoprodol to pregnant. Therefore, the aim of this study was to investigate the effect of carisoprodol on splenic tissues with two different doses.

MATERIALS AND METHODS

Drug:

The carisoprodol drug was obtained in the form of tablets of a combination of some products containing carisoprodol 200mg, paracetamol 160mg and caffeine 32mg. The drug was purchased from Mina Pharm for Pharmaceuticals and Chemical Industries, Cairo, Egypt.

Animals:

Adult male and female albino rats were used in the current work, with an average weight of 150- 180g and put in cages alone for two weeks under a standard laboratory environment of light and temperature. They were taken from the animal house of El-Nasr Pharmaceutical Chemicals Company. All rats were kept under standard breeding conditions of dry food diet supply, temperature, tap water and light cycle.

Gestation Course:

The estrous phase was performed according to Taylor (1986). Daily, the vaginal signs were calm to check the estrus phase. The female rats were caged with one male overnight. The presence of sperm and a vaginal plug meant that reproduction was established and this was reversed on the zero-day of pregnancy.

Study Design:

Thirty rats were randomly categorized into three groups (10 pregnant female rats in each). The first

was administered oral doses of distilled water and was served as negative control (NC). The other two groups (S1 and S2) were administered oral doses of carisoprodol in the distilled water equivalent to 10.8 mg and 21.6 mg/100g body weight/day respectively for 15 days from day 6 to day 20 of gestation. The equivalent dose for rats was adjusted according to the method Paget and Barnes (1964) formula on the basis of the human dose. All groups were sacrificed after 4 hours from the last drug administration.

Histological and Immunohistochemical Studies:

All rats were sacrificed and small pieces of spleen were picked out, rinsed in formalin (10%) and Bouin's solution for histological and immunohistochemical purposes. Sections of the spleen were prepared and stained with hematoxylin and eosin stain according to the method reported by Bancroft and Gamble (2008). Another set of slides were processed for detection of Caspase 3, CD₁₆₃ and CD₆₈ as immune markers according to Tan *et al.* (1986).

RESULTS

Histopathological Changes in Splenic Tissue:

The spleen is a large lymphoid organ that performs two main functions: immune reaction to blood-borne foreign antigens and filtration of the blood of particulate substances/debris. Each of these two functions is performed by specific compartments known as the "white pulp" and the "red Pulp" respectively. The white pulp is essentially a collection of both B and T-lymphocytes, whereas the red pulp is the intervening splenic tissue that consists of sinuses and cords (Fig. 1A). Histologically, treatment of pregnant rats with carisoprodol at current doses S1 and S2 caused many pathological changes in splenic tissues, as opposed to negative control rats. Splenic tissue of group S1 showed numerous changes

include thickened central arteries with narrow lumens, congested blood sinuses in the red pulps and congested veins. There was a proliferation of lymphocytes in some white pulps. Atrophic white pulp and thickened central arteries were observed (Figs. 1

B1&2). S2 group showed connected white pulps with increased proliferation of lymphocytes. Central arteries were congested and with a narrow lumen. There were congested blood sinuses in the red pulps (Figs. 1 C1&2).

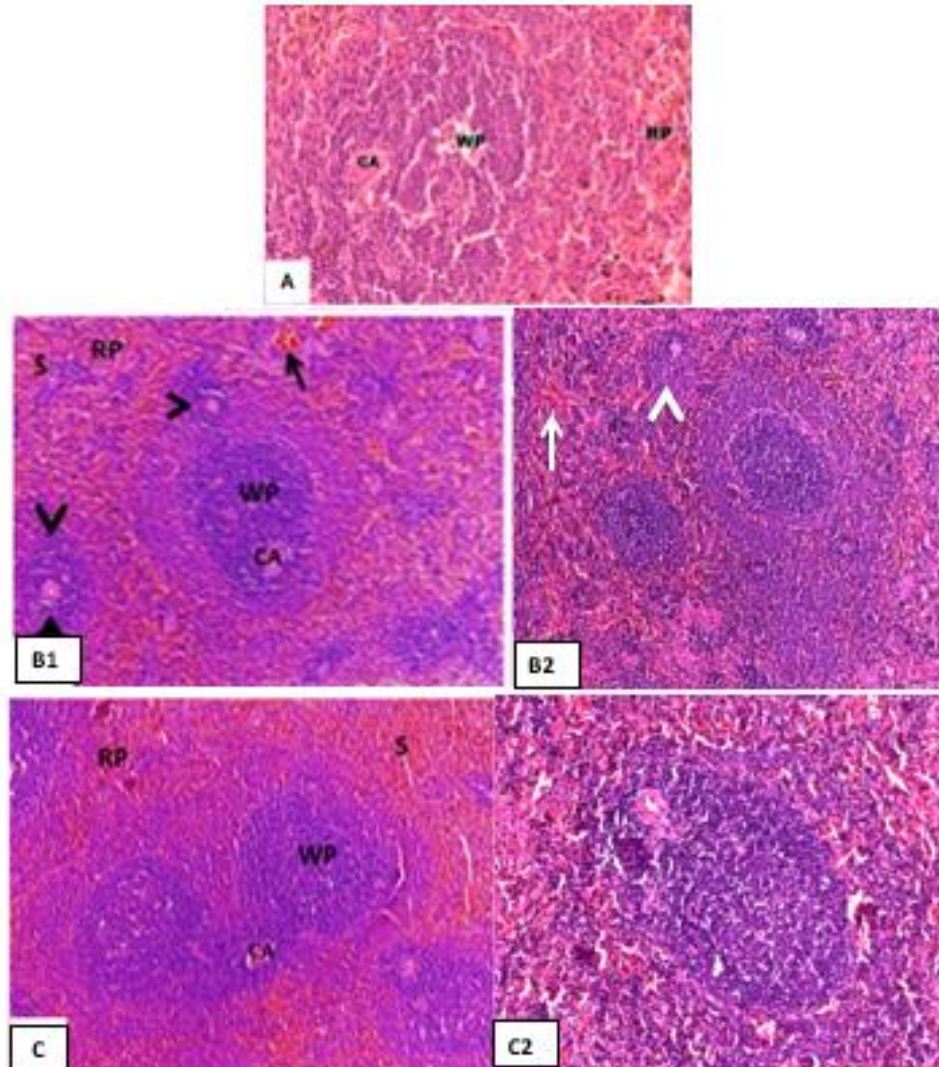


Fig. 1: Photomicrograph of sections in splenic tissue of a pregnant rat (A): negative control group showing intact and distinct spleen follicles with clear white pulps (WP) with central arteries (CA) inside them and normal red pulps (RP) (H&E X200). (B1&2): S1 group showing highly increased proliferation of lymphocytes in some white pulps (WP), others were atrophic (arrow heads) and thickened central arteries (CA) with narrow lumens. Congested pools of blood sinuses (S) in the red pulps (RP) and congested vein (arrow) were noticed (H&E X100). (C1&2): S2 group showing connected white pulps (WP) with increased proliferation of lymphocytes. Central arteries were congested and with narrow lumen. Congested pools of blood sinuses (S) in the red pulps (RP) were shown (H&E X100).

Immunohistochemical Changes:

Immune reactions evaluated in splenic tissues of all pregnant rats and caspase 3 was immunopositive in all treated groups with a varying positivity level (Fig. 2). Caspase 3 in splenic tissues of negative control rats showed a negative (-) caspase 3 stain (Fig. 2A). There was a moderate positive (+3) for caspase 3 in both S1 (Fig. 2B) and S2 groups (Fig. 2C). CD163 was positive in all treated pregnant rat splenic tissues when compared to negative control rats (Fig.

3). CD163 immunohistochemical staining of splenic tissues of negative control rats showed negative (-) CD163 stain (Fig. 3A) while was Mild positive for CD163 in both S1 (Fig. 3B) and S2 groups (Figure 3C). CD68 staining was positive in all treated pregnant rat splenic tissues when compared to negative control rats (Fig. 4). Negative control rats showed negative (-) CD68 stain (Figure 4A) but the splenic tissues of S1 was mild CD68 positivity in S1 (Figure 4B) and S2 groups (Fig. 4C).

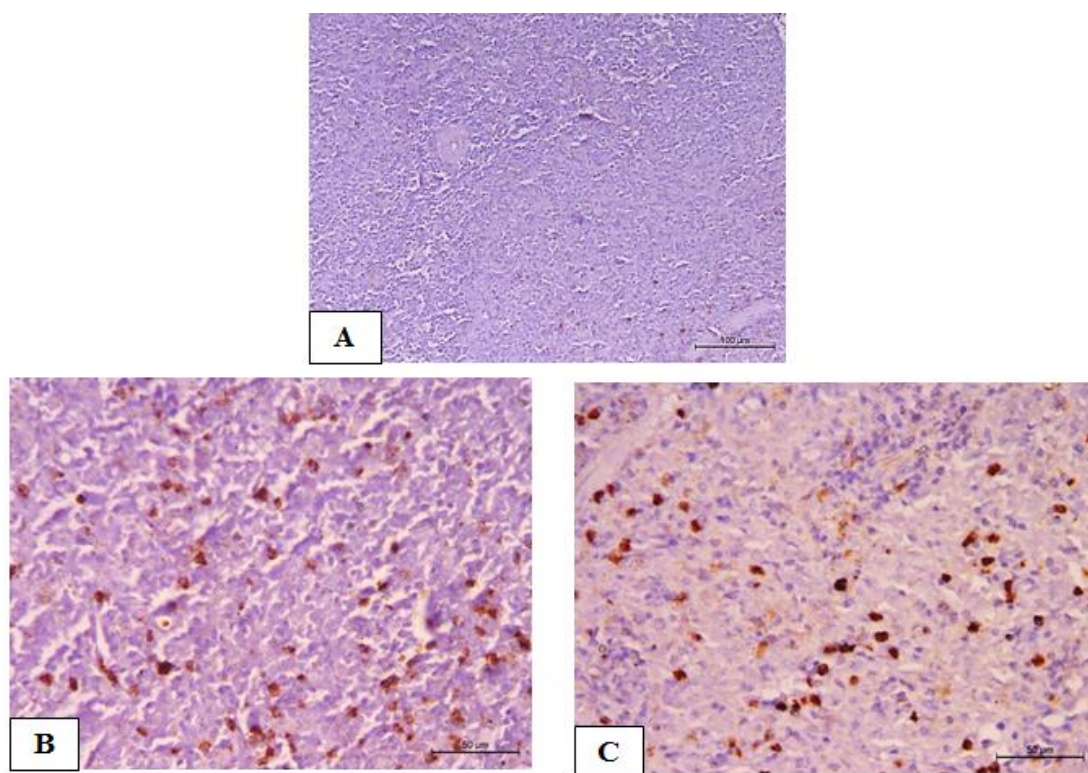


Fig. 2: Caspase 3 immunohistochemical staining of apoptosis: immunohistochemical staining of Caspase 3 in splenic tissues of (A) negative control rats showed negative (-) caspase 3 stain. (B) Moderate positive (+3) for caspase 3 as in S1 group. (C) Moderate positive (+3) for caspase 3 as in S2 group.

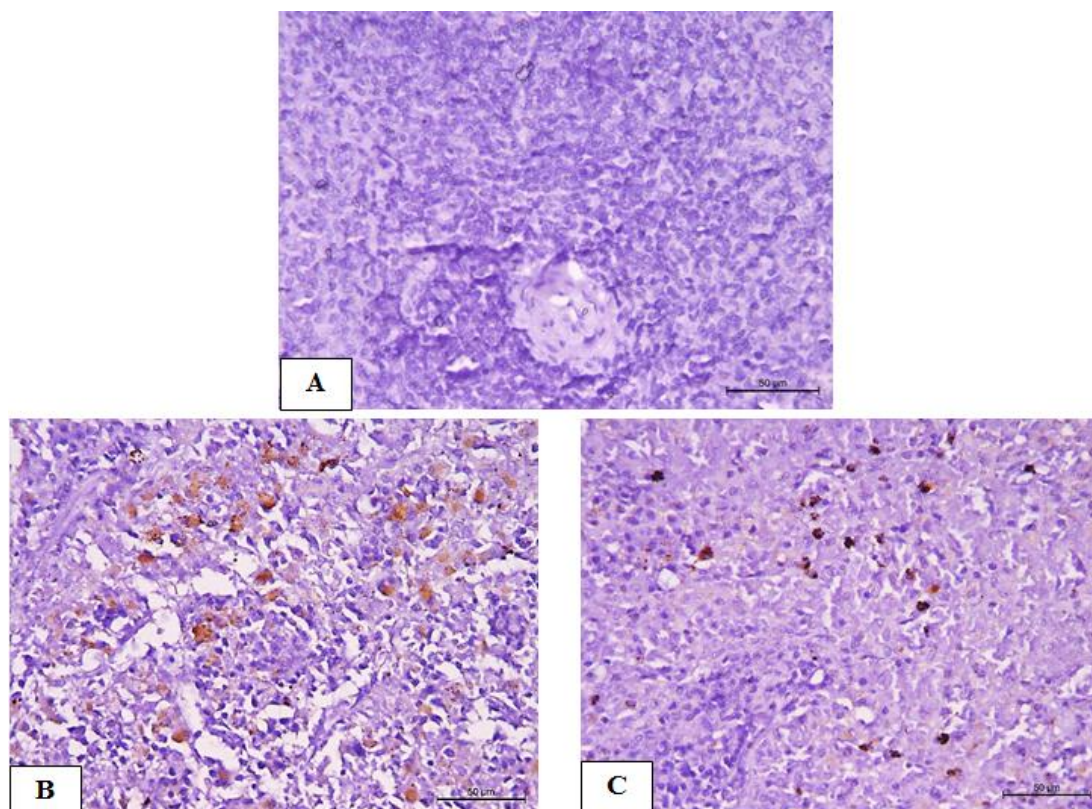


Fig. 3: CD163 immunohistochemical staining of splenic tissues of (A) negative control rats showed negative (–) CD163 stain, (B) Mild positive for CD163 as in S1 group and (C) Mild positive for CD163 as in S2 group.

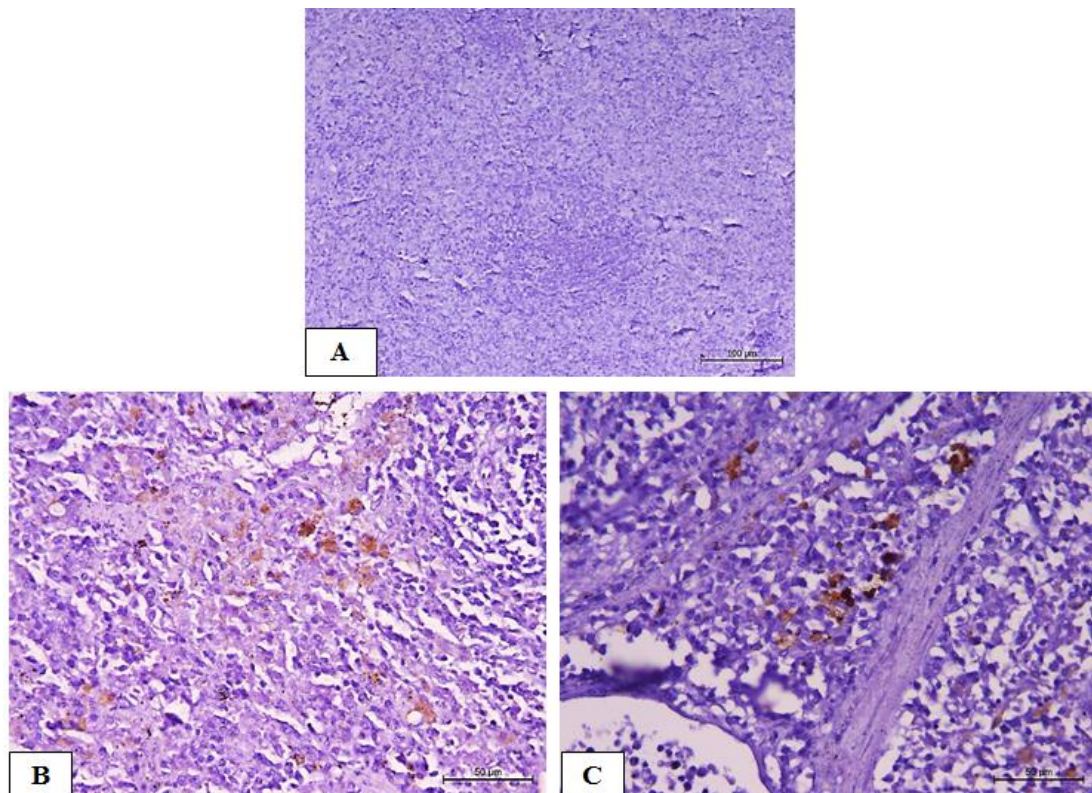


Fig. 4: Immunostaining of CD68 in splenic tissues of (A) negative control rats showed negative (–) CD68 stain. (B) Mild CD68 positivity in S1 group. (C) Mild CD68 positivity in S2 group.

DISCUSSION

Meprobamate, a Schedule II opioid linked to abuse, dependency, and central nervous system side effects, is formed when carisoprodol is processed. A high dose of carisoprodol can cause respiratory distress, hypotension, seizures, and death. Serotonin syndrome can be caused by carisoprodol toxicity (Spence *et al.*, 2013). Patients who take carisoprodol for a long time or who take it with other drugs that are affected may be at a higher risk of carisoprodol side effects (Abdelhafez and Abd Rabou, 2020).

In the present study, carisoprodol treatment in pregnant rats with the current doses S1 and S2 induced several pathological changes in splenic tissues compared to negative control rats. These changes include an increase in the number of connected white pulp with increased proliferation of lymphocytes and a highly thickened wall of central arteries with a narrow lumen. Emam (2020) also mentioned these changes in his report, stating that carisoprodol treatment in pregnant rats induced many dystrophic changes in lung tissue that worsened in a dose-dependent manner. Extensive lung tissue injury, multiple necrotic areas, and narrow alveolar cysts with thick alveolar septa are among the pathological changes. There was also alveolar hemorrhage, severe damage to the bronchi, very thick walls of blood vessels, most of which were congested with dissolved blood cells and cytological infiltration in lung tissue. Abd Rabou (2019) discovered that giving carisoprodol to pregnant rats caused dystrophic changes in the mother and foetal esophageal tissue as compared to the control group, implying that its use during pregnancy should be strictly controlled. The current findings were consistent with Abouel-Majd (2018) findings, which showed that carisoprodol-treated mother and foetal liver tissues were

seriously affected. These findings were in line with those of Ali *et al.* (2017), who found testicular vacuole, degeneration, and diminution in spermatozoa within the lumen, as well as loss of normal structure of the seminiferous tubules in Somadril-treated rats. These findings matched those of Awadalla and Salah-Eldin (2016), who found that tramadol, like other opioids, caused severe pathological changes in rat lung tissue and resulted in lower antioxidant plasma levels, suggesting a failure of the antioxidant protection mechanism. Lung depression, moderate sinus tachycardia, annexations, and ataxia were among the toxic effects of carisoprodol in a dog case study (Lane and Mazzaferro, 2005). Carisoprodol can cause congenital malformations in the first trimester of pregnancy (Robertson and Marinetti, 2003). Gomaa (2018) research has also shown that diclofenac, ibuprofen, and paracetamol have negative effects on immune-related organs (bone marrow, thymus, spleen, and lymph nodes). Both tapentadol and tramadol (CNS depressants) were found to cause significant cellular damage, inflammatory cellular infiltrations, and cell death in the pulmonary tissues, according to Faria *et al.* (2017), but tapentadol caused more damage. These findings were consistent with those of Liu *et al.* (2006), who found that infiltration of inflammatory cells into the liver in cases of direct drug-induced hepatotoxicity depletes neutrophils from the periphery, implying that the innate immune system (e.g., neutrophils and macrophages) plays a role in drug hepatotoxicity defence. Furthermore, paracetamol is metabolised into a toxic reactive metabolite that damages hepatocytes and releases risk signals, triggering an innate immune response that results in inflammation and collateral tissue damage to the liver, potentially lowering the number of

leukocytes in the blood (Rainsford and Velo, 2012). Treatments with paracetamol resulted in a substantial reduction in the relative weight of the spleen, according to Gomaa (2017). Changes in the organ-body weight ratio may indicate cell constriction or inflammation, with the latter occurring as a result of a loss of fluid from the organ associated with damage; however, an improvement in the organ-body weight ratio may indicate inflammation (Moore *et al.*, 1999). Furthermore, several medications are thought to have immunotoxic effects in humans and animals, resulting in immune system disturbances manifested by changes in the weight of immune-related organs (spleen and thymus) (Descotes, 1986). According to Bessone (2010) and Kishida *et al.* (2012), nonsteroidal anti-inflammatory drugs (NSAIDs) such as paracetamol cause liver injury due to their acidic moiety or reactive metabolites that bind to host proteins and cause cellular injury. Moreover, paracetamol is metabolized into a toxic reactive metabolite that binds to glutathione and depletes it in the hepatocytes resulting in impaired mitochondrial function causing hepatocyte damage and necrosis. This damage causes cellular leakage and loss of functional integrity of the cell membrane in the liver, resulting in the release of high levels of serum markers into the blood, particularly AST and ALT that which account for 90% of the total enzyme and are a better predictor of liver injury (Watkins and Seef, 2006; Ansari and Asif, 2012). McIntyre *et al.* (2012) demonstrated that carisoprodol was concentrated in the liver with the organism dying before being distributed to the rest of the body. Besides this, because of its central nervous system depressant activity, the active metabolite, meprobamate, can contribute significantly to the overall toxic effects of carisoprodol in many cases. Concerning splenic sections, the experimental groups of Abbasi *et al.*

(2018) search not only demonstrate shrinkage as well as a cellular distortion of white pulp at each time point compared to the control sections. Furthermore, in the white pulp, a decrease in lymphocyte population, follicle activation, and cellular disruption were observed. These changes may be attributed to toxic metabolites of the dose of paracetamol.

The current study produced a quantity of Caspases-3 in the splenic tissue of treated rats indicating apoptosis compared to negative control rats. These results were identical with Emam (2020) who indicated that when comparing treated pregnant rats to the control group, the amount of caspase-3 indicated by the dense brown stain increased. These findings were consistent with those of other studies of CNS depressants or analgesic drugs as Gloor *et al.* (2019), who found that acetaminophen causes apoptosis, necrosis, and mitochondrial harm. Jaeschke (2015) agreed that overdosing on paracetamol, which is considered a safe medication at therapeutic doses, can result in serious liver damage, acute liver failure, and cell death. Moreno *et al.* (2016) examined the main pathways for apoptosis following ethanol (CNS depressants) exposure and concluded that ethanol exposure has a substantial impact on the degree of apoptosis in the CNS. They revealed widespread pro-apoptotic responses, suggesting that while apoptosis increased cellular attempts to compensate and resolve exposure also increased. Gomaa (2018) concluded that consuming diclofenac, ibuprofen, or paracetamol can cause immunological and biochemical changes, as well as an increase in toxicity depending on the dosage. Oxidative stress and subsequent overproduction of reactive oxygen species (ROS), which have been proposed as the most significant mechanism of toxicity, may be the cause of such extreme histopathological changes with carisoprodol therapy (Rajapakse *et al.*, 2007). Ostrovsky *et*

al. (2009) demonstrated that oxidative stress and ROS cause cellular damage, including apoptosis and DNA fragmentation. NSAIDs (such as paracetamol) can impair thymocyte development and induce bone marrow suppression by reducing the production of cells that provide immunity (leukocytes). It can also have various immunomodulatory effects on activated macrophages, granulocytes, and extrathymic T cells, which may become cytotoxic effectors against self-tissues or self-cells when they are overactivated. The aetiology of the tissue impairment caused by NSAIDs may be linked to these activated leukocytes (Cho, 2007; Aronson, 2009).

In the current study, CD163 was positive in all treated rats when compared to negative control rats. Splenic immune cells, especially macrophages, play a key role in a variety of pathological processes, and mesencephalic astrocyte-derived neurotrophic factor (MANF) has been shown to have anti-inflammatory and immunoregulatory properties in inflammation (Hou *et al.*, 2019). The upregulation of CD163, a macrophage-specific protein, is one of the main changes in the macrophage switch into alternative active phenotypes in inflammation. As a result, tissues that lead to inflammation have increased CD163 expression in macrophages. CD163 indirectly contributes to the anti-inflammatory response by scavenging oxidative and proinflammatory haemoglobin (Hb), which leads to activation of heme-oxygenase-1 and the development of anti-inflammatory heme metabolites. CD163 is a potential biomarker of inflammation and a therapeutic target, in addition to its biological function in inflammation (Etzerodt and Moestrup, 2013). Bacterial sepsis/infection is an acute inflammatory disease (Møller *et al.*, 2006), while rheumatoid arthritis is a chronic inflammatory disease (Greisen *et al.*, 2011).

Our study found that immunohistochemical staining of splenic sections for the detection of CD68 was positive in all treated rats compared to negative control rats. CD68 expression can be significantly upregulated in rat resident peritoneal macrophages in response to inflammatory stimuli (Rabinowitz and Gordon, 1991). CD68 is a typical histochemical/cytochemical marker of inflammation in the presence of monocytes/macrophages (Ferenbach and Hughes, 2008). Cells of the macrophage lineage, such as tissue histiocytes, multinucleated giant cells, kupffer cells, and osteoclasts, have also been identified using CD68 (Brooks *et al.*, 2009). CD68 immunostaining can be seen in a number of cell types, including fibroblasts and inflammatory cells (Chen *et al.*, 2017). Increased CD68 staining was characterised by activated kupffer cells in a previous study (Lee *et al.*, 2016), and appeared to be co-stimulated by increased secretion of the cytokine macrophage colony-stimulating factor (M-CSF). Mossanen *et al.* (2016) determined that acetaminophen (paracetamol) toxicity is a leading cause of acute liver failure (ALF) in humans, resulting in hepatocyte necrosis and innate immune system activation. Overdosage of depleted glutathione (GSH) with acetaminophen (paracetamol) resulted in liver damage and thus increased hepatotoxicity and CD68 expressions (Fadda *et al.*, 2017).

Conclusion

Despite the fact that carisoprodol is believed to be the most powerful pain reliever, our findings showed that taking it during pregnancy induced numerous histopathological and immunohistochemical changes in the spleen tissues of pregnant rats. As a result, the toxicity of carisoprodol must be noted, and extreme care should be used when using it in therapies.

Acknowledgements

Authors thank the zoology lab scientific and technical staff for caring

for animals and making specimens available for processing.

Conflict of interest

The authors declare that there is no Conflict of interest. The authors alone are responsible for the content and writing of this article.

Ethical Approval

All applicable international, national, and institutional guidelines for the care and use of animals were followed. We respected the welfare of animals, and excluded situations when animals were in pain.

REFERENCES

- Abbasi, M. H.; David, K.; Idnan, M.; Ahmed, Z. and Qureshi, A. M. (2018) Effect of Time-Lapse Administration of Panadol (Paracetamol) on Spleen and Kidney Functions of Adult Albino Mice. *RADS Journal of Biological Research and Applied Sciences*, 9(2):88-93.
- Abd Rabou, M. A. (2019) Histological and histochemical alterations induced in rats fetal esophageal tissue intoxicated maternally with carisoprodol. *The Egyptian Journal of Hospital Medicine*, 75(2):2254-2260.
- Abdelhafez, H. M. and Abd Rabou, M. A. (2020) Carisoprodol (Somadril) induced histological and histochemical changes in renal cortex of pregnant rats and their fetuses. *Egyptian Journal of Histology*, 43(3):835-848.
- Abouel-Magd, M. H. (2018) Maternal and fetal toxicity of carisoprodol. *The Egyptian Journal of Hospital Medicine*, 71(1):2322-2350.
- Ali, K. A.; Salih, L. S. and Abdulkareem, S. M. (2017) Histo-Physiological Study of some Parts of Organs Treated with Somadril Drug. *Journal of Raparin University*, 4(11):33.
- Ansari, J. A. and Asif, R. (2012) Hepatoprotective effect of *Tabernaemontana divaricate* against acetaminophen-induced liver toxicity". *Medical Chemistry and Drug Discovery*, 3(2):146-151.
- Aronson, J. K. (2009) Side Effects of Drugs Annual 31: A Worldwide Yearly Survey of New Data and Trends in Adverse Drug Reactions. Elsevier Science Publishing Company 1–84.
- Awadalla, E. A. and Salah-Eldin, A. E. (2016) Molecular and histological changes in cerebral cortex and lung tissues under the effect of tramadol treatment. *Biomedicine and Pharmacotherapy*, 82:269-280.
- Bancroft, J. D. and Gamble, M. (2008) Theory and practice of histology techniques. Churchill Livingstone Elsevier, London 83-134.
- Bernal, W.; Auzinger, G.; Dhawan, A. and Wendon, J. (2010) Acute liver failure. *The Lancet*, 376(9736):190-201.
- Bessone, F. (2010) Non-steroidal anti-inflammatory drugs: What is the actual risk of liver damage? *World Journal of Gastroenterology: WJG*. 16(45): 5651-5661.
- Bramness, J. G.; Furu, K. Engeland, A. and Skurtveit, S. (2007) Carisoprodol use and abuse in Norway. A pharmacoepidemiological study. *British Journal of Clinical Pharmacology*, 64(2): 210-218.
- Brooks, E.; Simmons-Arnold, L.; Naud, S.; Evans, M. F. and Elhosseiny, A. (2009) Multinucleated giant cells' incidence, immune markers, and significance: a study of 172 cases of papillary thyroid carcinoma. *Head and Neck Pathology*, 3(2):95-99.
- Carbonaro, T. M.; Nguyen, V.; Forster, M. J.; Gatch, M. B. and Prokai, L. (2020) Carisoprodol pharmacokinetics and distribution in the nucleus accumbens correlates with

Immunohistochemical and histological alterations in the spleen of pregnant rats³¹
induced by carisoprodol

- behavioral effects in rats independent from its metabolism to meprobamate. *Neuropharmacology*, 174: 108152.
- Chen, X. J.; Han, L. F.; Wu, X. G.; Wei, W. F.; Wu, L. F.; Yi, H. Y. and Wang, W. (2017) Clinical significance of CD163+ and CD68+ tumor-associated macrophages in high-risk HPV-related cervical cancer. *Journal of Cancer*, 8(18):3868-3875.
- Cho, J. Y. (2007) Immunomodulatory effect of nonsteroidal anti-inflammatory drugs (NSAIDs) at the clinically available doses. *Archives of Pharmacal Research*, 30(1):64-74.
- Descotes, J. (1986) Pseudo-allergic drug reactions. *Clinical Research Practices and Drug Regulatory Affairs*, 4(1):75-84.
- Emam, N. M. M. (2020) Maternal and Fetal Toxicity of Carisoprodol Drug (Somadril Compound) on Pulmonary Tissues of Albino Rats. *Journal of Biology and Life Science*, 11(1):72-97.
- Etzerodt, A. and Moestrup, S. K. (2013) CD163 and inflammation: biological, diagnostic, and therapeutic aspects. *Antioxidants and Redox Signaling*, 18(17): 2352-2363.
- Fadda, L. M.; Al-Rasheed, N. M.; Hasan, I. H.; Ali, H. M.; Al-Rasheed, N. M.; Al-Fayez, M. and Khalaf, R. (2017) Bax and CD68 expression in response to liver injury induced by acetaminophen: The hepatoprotective role of thymoquinone and curcumin. *Pakistan Journal of Zoology*, 49(1):85-93.
- Faria, J.; Barbosa, J.; Leal, S.; Afonso, L. P.; Lobo, J.; Moreira, R. and Dinis-Oliveira, R. J. (2017) Effective analgesic doses of tramadol or tapentadol induce brain, lung and heart toxicity in Wistar rats. *Toxicology*, 385:38-47.
- Ferenbach, D. and Hughes, J. (2008) Macrophages and dendritic cells: what is the difference? *Kidney International*, 74(1):5-7.
- Gloor, Y.; Schwartz, D. F. and Samer, C. (2019) Old problem, new solutions: biomarker discovery for acetaminophen liver toxicity. *Expert Opinion on Drug Metabolism and Toxicology*, 15(8):659-669.
- Gomaa, S. (2018) Adverse effects induced by diclofenac, ibuprofen, and paracetamol toxicity on immunological and biochemical parameters in Swiss albino mice. *The Journal of Basic and Applied Zoology*, 79(1):1-9.
- Gomaa, S. (2017) Immunomodulatory and hematological effects induced by diclofenac, ibuprofen or paracetamol toxicity in Swiss albino mice. *European Journal of Biological Research*, 7(4):348-359.
- Gonzalez, L. A.; Gatch, M. B.; Taylor, C. M.; Bell-Horner, C. L.; Forster, M. J. and Dillon, G. H. (2009) Carisoprodol-mediated modulation of GABAA receptors: in vitro and in vivo studies. *Journal of Pharmacology and Experimental Therapeutics*, 329(2):827-837.
- Greisen, S. R.; Moller, H. J.; Stengaard-Pedersen, K.; Hetland, M. L.; Hørslev-Petersen, K.; Jørgensen, A. and Deleuran, B. (2011) Soluble macrophage-derived CD163 is a marker of disease activity and progression in early rheumatoid arthritis. *Clinical and experimental rheumatology*, 29(4):689-692.
- Holstege, A.; Kurz, M.; Weinbeck, M. and Gerok, W. (1993) Excretion of caffeine and its primary

- degradation products into bile. *Journal of Hepatology*, 17(1):67-73.
- Hou, C.; Wang, D.; Li, X.; He, Y.; Wei, C.; Jiang, R. and Shen, Y. (2019) MANF regulates splenic macrophage differentiation in mice. *Immunology Letters*, 212: 37-45.
- Jackson, II K. C.; Argoff, C. E. and Dubin, A. (2014) Skeletal muscle relaxants. In *Practical Management of Pain* 569-574.
- Jaeschke, H. (2015) Acetaminophen: dose-dependent drug hepatotoxicity and acute liver failure in patients. *Digestive Diseases*, 33(4):464-471.
- Kishida, T.; Onozato, T.; Kanazawa, T.; Tanaka, S. and Kuroda, J. (2012) Increase in covalent binding of 5-hydroxydiclofenac to hepatic tissues in rats co-treated with lipopolysaccharide and diclofenac: involvement in the onset of diclofenac-induced idiosyncratic hepatotoxicity. *The Journal of Toxicological Sciences*, 37(6):1143-1156.
- Kumar, M. and Dillon, G. H. (2015) Carisoprodol: update on abuse potential and mechanism of action. *Molecular and Cellular Pharmacology*, 7(1):1-10.
- Lane, S. G. and Mazzaferro, E. (2005) SOMA (carisoprodol) toxicity in a dog. *Journal of Veterinary Emergency and Critical Care*, 15(1):48-51.
- Lee, E. H.; Oh, J. H.; Selvaraj, S.; Park, S. M.; Choi, M. S.; Spanel, R. and Borlak, J. (2016) Immunogenomics reveal molecular circuits of diclofenac induced liver injury in mice. *Oncotarget*, 7(12):14983.
- Liu, Z. X.; Han, D.; Gunawan, B. and Kaplowitz, N. (2006) Neutrophil depletion protects against murine acetaminophen hepatotoxicity. *Hepatology*, 43(6):1220-1230.
- McIntyre, I. M.; Sherrard, J. and Lucas, J. (2012) Postmortem carisoprodol and meprobamate concentrations in blood and liver: lack of significant redistribution. *Journal of Analytical Toxicology*, 36(3): 177-181.
- Møller, H. J.; Moestrup, S. K.; Weis, N.; Wejse, C.; Nielsen, H.; Pedersen, S. S. and Kronborg, G. (2006) Macrophage serum markers in pneumococcal bacteremia: prediction of survival by soluble CD163. *Critical Care Medicine*, 34(10): 2561-2566.
- Moore, K.; Dalley, A. and Agur, A. M. R. (1999) Clinically orientated anatomy. 4th edn. Lippincott Williams and Williams, Philadelphia 263-271.
- Moreno, M. C.; Ignacio, C.; Burke, P. and Middleton, F. A. (2016) Alcohol intake and apoptosis: a review and examination of molecular mechanisms in the central nervous system. *Molecular Aspects of Alcohol and Nutrition* 45-61.
- Mossanen, J. C.; Krenkel, O.; Ergen, C.; Govaere, O.; Liepelt, A.; Puengel, T. and Tacke, F. (2016) Chemokine (C-C motif) receptor 2-positive monocytes aggravate the early phase of acetaminophen-induced acute liver injury. *Hepatology*, 64(5): 1667-1682.
- National Institutes of Health. (2017) Livertox: clinical and research information on drug-induced liver injury. Available from: Nih. gov <https://livertox.nih.gov>.
- Olsen, H.; Koppang, E.; Alvan, G. and Mørland, J. (1994) Carisoprodol elimination in humans. *Therapeutic Drug Monitoring*, 16(4):337-340.
- Ostrovsky, S.; Kazimirsky, G.; Gedanken, A. and Brodie, C. (2009) Selective cytotoxic effect

Immunohistochemical and histological alterations in the spleen of pregnant rats³³
induced by carisoprodol

- of ZnO nanoparticles on glioma cells. *Nano Research*, 2(11): 882-890.
- Paget, G. E. and Barnes, J. M. (1964) Interspecies dosage conversion scheme in evaluation of results and quantitative application in different species. Evaluation of drug activities: *Pharmacometrics*, 1:160-162.
- Patil, A. A.; Shirsat, M. K. and Salunkhe, V. R. (2020) A Review-Carisoprodol as Skeletal Muscle Relaxant. *International Journal of Scientific Research in Science and Technology*, 7(1): 40-44.
- Petroianu, A. (2007) Drug-induced splenic enlargement. *Expert Opinion on Drug Safety*, 6(2):199-206.
- Plumlee, K. (2004) Clinical Veterinary Toxicology-E-Book. Elsevier Health Sciences 282-336.
- Rabinowitz, S. S. and Gordon, S. (1991) Macrosialin, a macrophage-restricted membrane sialoprotein differentially glycosylated in response to inflammatory stimuli. *The Journal of Experimental Medicine*, 174(4): 827-836.
- Raffel, S. C.; Swink, R. and Lampton, T. D. (1969) The influence of chlorphenesin carbamate and carisoprodol on psychological test scores. *Current Therapeutic Research, Clinical and Experimental*, 11(9):553-560.
- Rainsford, K. D. and Velo, G. P. (2012) Side-effects of anti-inflammatory drugs: part two studies in major organ systems (Vol. 2). Springer Science and Business Media.
- Rajapakse, N.; Kim, M. M.; Mendis, E. and Kim, S. K. (2007) Inhibition of free radical-mediated oxidation of cellular biomolecules by carboxylated chitoooligosaccharides. *Bioorganic and Medicinal Chemistry*, 15(2):997-1003.
- Rall, T. W. (1985) Drugs effective in the therapy of the epilepsies. *The Pharmacological Basis of Therapeutics* 446-472.
- Reeves, R. R.; Carter, O. S. and Pinkofsky, H. B. (1999) Use of carisoprodol by substance abusers to modify the effects of illicit drugs. *Southern Medical Journal*, 92(4):441.
- Reuben, A.; Koch, D. G. and Lee, W. M. (2010) Drug-induced acute liver failure: results of a US multicenter, prospective study. *Hepatology*, 52(6):2065-2076.
- Rho, J. M.; Donevan, S. D. and Rogawski, M. A. (1997) Barbiturate-like actions of the propanediol dicarbamates felbamate and meprobamate. *Journal of Pharmacology and Experimental Therapeutics*, 280(3):1383-1391.
- Robertson, M. D. and Marinetti, L. J. (2003) Carisoprodol-effects on human performance and behavior. *Forensic Science Review*, 15(1):3-9.
- Simon, S.; D'Andrea, C.; Wheeler, W. J. and Sacks, H. (2010) Bioavailability of oral carisoprodol 250 and 350 mg and metabolism to meprobamate: A single-dose crossover study. *Current Therapeutic Research*, 71(1):50-59.
- Spence, M. M.; Shin, P. J.; Lee, E. A. and Gibbs, N. E. (2013) Risk of injury associated with skeletal muscle relaxant use in older adults. *Annals of Pharmacotherapy*, 47(7-8):993-998.
- Tan, C. K.; Castillo, C.; So, A. G. and Downey, K. M. (1986) An auxiliary protein for DNA polymerase-delta from fetal calf thymus. *Journal of Biological Chemistry*, 261(26):12310-12316.

- Taylor, P. (1986) Handling: the reproductive cycle and mating. *Practical Teratology*, Academic Press, London 3-9.
- Vardanyan, R. and Hruby, V. (2006) Synthesis of essential drugs. *Muscle Relaxants*, Elsevier 209-218.
- Wang, Y.; Delcher, C.; Li, Y.; Goldberger, B. A. and Reisfield, G. M. (2019) Overlapping prescriptions of opioids, benzodiazepines, and carisoprodol: "Holy Trinity" prescribing in the state of Florida. *Drug and Alcohol Dependence*, 205:107693.
- Watkins, P. B. and Seeff, L. B. (2006) Drug-induced liver injury: summary of a single topic clinical research conference. *Hepatology*, 43(3):618-631.
- Zacny, J. P.; Paice, J. A. and Coalson, D. W. (2011) Characterizing the subjective and psychomotor effects of carisoprodol in healthy volunteers. *Pharmacology Biochemistry and Behavior*, 100(1):138-143.