

Effectiveness of Angioplasty in Treatment of Diabetic Foot Patients with Infragenicular Single Stenosis or Occlusion: A Prospective Study

Ali Mahmoud Mohamed Galal*, Mohamed Ahmed Mohamed Ismail

Vascular Surgery Department, Faculty of Medicine, Aswan University, Egypt

*Corresponding author: Ali M. M. Galal, Mobile: (+20)1001816078, E-Mail: a_mando76@yahoo.com

ABSTRACT

Background: Diabetes is linked to both microvascular and macrovascular complications, such as retinopathy, nephropathy, and neuropathy (microvascular) and ischemic heart disease, peripheral vascular disease, and cerebrovascular disease (macrovascular), resulting in organ and tissue damage in approximately one third to one half of people with diabetes.

Objectives: The aim of the current work was to examine the effectiveness and safety of infragenicular angioplasty in diabetic patients with critical limb ischemia (CLI) due to single stenosis or occlusion.

Patients and Methods: The current study was a prospective cohort investigation that recruited diabetic patient with infragenicular CLI with or without supragenicular lesion at Vascular Surgery Department, Aswan University Hospital. The primary endpoint in our study was the primary patency at the end of sixth month of follow-up.

Results: This study included 20 patients with age ranged between 42 years and 82 years; the majority of patients were males (75%). Eighteen patients (90%) had immediate success; after six months, 14 patients (70%) remained patent. By the end of the sixth month post-revascularization, 15 patients (75%) had limb salvage, while four out of the remaining patients had rest pain relief (80%). Healing of minor ulcers occurred in 80% of the patients, and healing of tissue after debridement or minor amputation occurred in 60% of the patients.

Conclusion: It could be concluded that infragenicular angioplasty exhibited efficacy in the management of CLI due to single stenosis or occlusion in diabetic patients, with acceptable patency rate and safety profile.

Keywords: Diabetes, Diabetic Foot, Limb Ischemia, Infragenicular Angioplasty,

INTRODUCTION

The epidemic of diabetes mellitus (DM) has increased dramatically over the past decades and become on the apex of chronic diseases across different parts of the world. According to recent literature, DM affects nearly 9% of the global population, with highest prevalence in the Eastern Mediterranean Region. The number of affected people is expected to rise to 642 million patients worldwide by the end of 2040 ^(1,2). Moreover, DM is a major cause of mortality and exerts substantial burden on healthcare expenditure amongst different parts of the world ⁽³⁾.

Patients with DM are prone to increased risks of wide range of complications, which mainly develop secondarily to micro and macro-vascular affection ⁽⁴⁾. It was reported that diabetic patients had two-to-four folds increase in the risk of peripheral arterial disease (PAD), compared to healthy population ⁽⁵⁾.

Various risk factors are incorporated in the development of PAD in diabetic patients, which lead to impaired metabolic status and chronic vascular inflammation; in return, diabetic patients exhibit rapid progression of atherosclerosis and ischemic symptoms ⁽⁶⁾. The co-existence of PAD in diabetic patient is a well-established risk factor for cardiovascular morbidity and mortality ⁽⁷⁾.

Critical limb ischemia (CLI) is the end-stage form of PAD that significantly increase the risk of amputation and overall mortality in diabetic patients ⁽⁸⁾. The progression to CLI was noted to occur at faster rate in diabetic than non-diabetic patients ⁽⁹⁾. Moreover, in diabetic patients, CLI is usually associated with foot

ulcers and more extensive tissue damage as consequence of peripheral neuropathy ⁽⁴⁾. CLI can lead to leg amputation in up to 40% of the affected patients and an over-all mortality in up to 25%, which reflect the adverse effect exerted by CLI on diabetic patients ⁽¹⁰⁾. The leg amputation itself is a risky procedure in this type of population -who are usually old and have several comorbidities- with reported postoperative mortality of 10% and unfavorable long-term survival ⁽¹¹⁾. Thus, reducing the rate of leg amputation represents the cornerstone in the management of CLI patients. In the setting of lower limb ischemia, surgical bypass is the modality of choice owing to anatomical factors and favorable clinical outcomes ⁽¹²⁾.

A growing body of evidence highlighted promising results of infragenicular angioplasty in diabetic patients with CLI; it was shown that infragenicular angioplasty achieved high patency rates and limb salvage in diabetic patients, which were comparable to non-diabetic patients ⁽¹³⁾. Nonetheless, limited data are available about the safety and efficacy of infragenicular angioplasty in limited resources areas like Egypt.

Accordingly, our study was aimed to examine the effectiveness and safety of infragenicular angioplasty in diabetic patients with critical limb ischemia (CLI) due to single stenosis or occlusion.

PATIENTS AND METHODS

This prospective cohort study included a total of 20 diabetic patients with infragenicular CLI due to single



This article is an open access article distributed under the terms and conditions of the Creative Commons Attribution (CC BY-SA) license (<http://creativecommons.org/licenses/by/4.0/>)

stenosis or occlusion with or without supragenicular lesion, recruited at Department of Vascular Surgery, Aswan University Hospital. This study was conducted between January 2019 to June 2020.

The diagnosis of diabetic foot was based on clinical presentation and supporting imaging modalities ⁽¹⁴⁾. While the CLI was defined as Rutherford category of equal or more than four ⁽¹⁵⁾.

Inclusion criteria:

Diabetic patients having diabetic foot, older than 18 years and had confirmed diagnosis of CLI. Besides, patients were included if they had TransAtlantic Inter-Society Consensus (TASC) classification type A, defined as ≤ 5 cm single lesion of the target tibial artery with occlusion or stenosis similar or worse in severity in the other tibial arteries ⁽¹⁶⁾.

Exclusion criteria:

Patients were excluded if they had extensive lower limb infections, full-thickness gangrene, primary vascular etiology, and/or mental or cognitive impairment. Besides, we excluded patients who were not eligible for two revascularization strategies.

Ethical consent:

An approval of the study was obtained from Aswan University academic and ethical committee. Every patient signed an informed written consent for acceptance of the operation.

This work has been carried out in accordance with The Code of Ethics of the World Medical Association (Declaration of Helsinki) for studies involving humans.

The following data were obtained for every eligible patient:

- Demographic characteristics.
- Risk factors for CLI and diabetic foot.
- History of previous PAD procedures or leg amputation.
- Findings of the physical examination.
- Routine laboratory findings.
- Imaging findings, including duplex ultrasound, computerized tomography angiography (CTA), magnetic resonance angiography (MRA), and digital subtraction angiography (DUS).

Patients were instructed to take clopidogrel five days preoperatively. Alternatively, a periprocedure loading dose of 300 mg was administrated. The angioplasty technique was performed according to the institute's protocol and all procedures were performed under local anesthesia.

The access through the artery was guided by pre-operative imaging and done by either antegrade or cross-over techniques of common femoral artery puncture. Then, a F sheath was inserted, and a dye-guided

angiography was performed to identify the lesion. To cross the stenosis, guidewires were introduced, and a drilling motion of the guidewire was performed, followed by insertion of coaxial catheter balloon. Then, a 2-3.5 mm balloons were inserted and inflated. After balloon deflation, a 100ug of nitroglycerin was injected intra-arterially. Then, an angiogram was performed.

A success technique was defined as less than 30% residual stenosis of the target tibial artery and restoration of pulse. Patients were managed postoperatively according to the institute's protocol and maintained on cilostazol 100mg twice/day, acetylsalicylic acid 150mg/day, and /or clopidogrel 75mg/day after hospital discharge. All patients were followed-up for six months after the procedure.

The primary endpoint in our study was the primary patency rate at the end of sixth month of follow-up, the patency was determined by palpation of the pulse and Duplex ultrasound. The secondary endpoints included the rate of clinical success, limb salvage, rest pain restoration, and postoperative complications.

Statistical analysis

The statistical analyses were employed using SPSS software (Statistical Package for the Social Science; SPSS Inc., Chicago, IL, USA) version 22 for Microsoft Windows. The mean \pm standard deviation (\pm SD) or median with interquartile range (IQR) were used to describe numerical variables according to the normality of the data.

Frequencies with percentages were applied to present categorical variables. The association between quantitative variables was examined using unpaired Student's t-test for normally distributed data or Mann-Whitney Rank Sum test for non-normally distributed data. The Chi-square test was implemented to identify the level of significance for categorical variables. The level of significance was set at a probability critical value (p-value) lower than 0.05.

RESULTS

This study included 20 patients with age ranged between 42 years and 82 years. The majority of patients were males (75%).

Patients were followed up over 6 months and were allocated into two groups: Group A (occluded patients) and Group B (patent patients).

In this study, 15 patients (67.5%) were smokers, 12 patients (72.5%) were hypertensive, 19 patients (47.5%) were ischemic heart disease, 14 patients (60%) had hyperlipidemia, 5 patients (12.5%) had previous stroke, and 11 patients (27.5%) had previous peripheral angioplasty.

Regarding the presenting symptoms, nine patients (22.5%) had rest pain (Rutherford 4), 20 patients (50%) had minor tissue loss (Rutherford 5, and 11 patients (27.5%) had major tissue loss (Rutherford 6). No cases with IC included in our study (**Table 1**).

Table (1): Baseline data in both groups

	Patients (n=20)	
	No.	%
Sex		
Male	16	80.0
Female	4	20.0
Age (years)		
Min. – Max.	46.0 – 72.0	
Mean ± SD.	60.10 ± 6.53	
Median	60.0	
Smoking	13	65
DM	15	75
HTN	14	70
IHD	7	35
HLIP	11	55
Stroke	1	5
Previous angioplasty	6	30
Rutherford		
4	5	25.0
5	10	50.0
6	5	25.0
Min. – Max.	4.0 – 6.0	
Mean ± SD.	5.0 ± 0.73	
Median	5.0	

Eighteen patients (90%) had immediate success, while 15 patients (75%) remained patent after one month. After three and six months, 14 patients (70%) remained patent (**Figure 1**).

With regard to limb salvage by the end of six months, 15 patients (75%) had limb salvage (14 patients with patent arteries) in form of rest pain relief in 4/5 patients (80%), healing of minor ulcers in 8/10 patients (80%), and healing of tissue after debridement or minor amputation 3/5 patients (60%).

There were six patients with non-salvaged limb; three with below knee amputation due to failed revascularization and spreading infection in spite of revascularization, one with sever graft infection, one patient with sever life threatening hemorrhage with infection at site if distal anastomosis, and patient had below knee amputation (**Figure 2**).

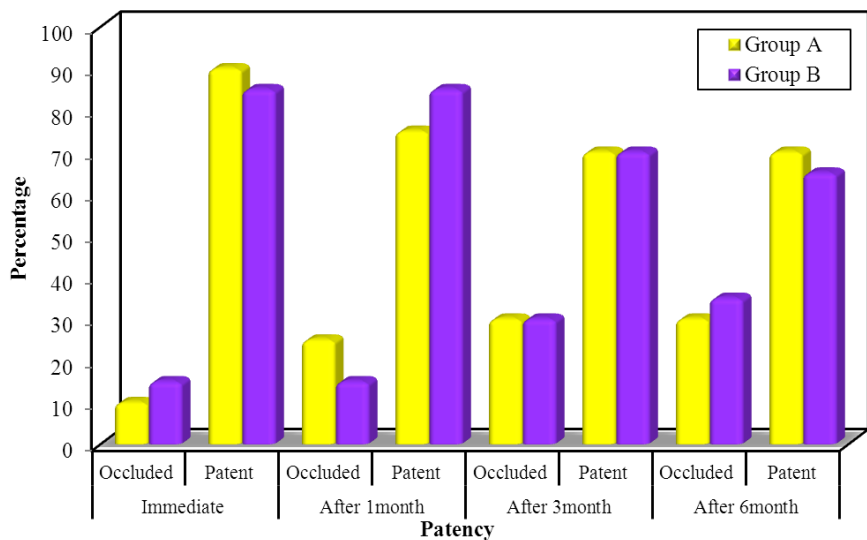


Fig. (1): Comparison between the two studied groups according to patency.

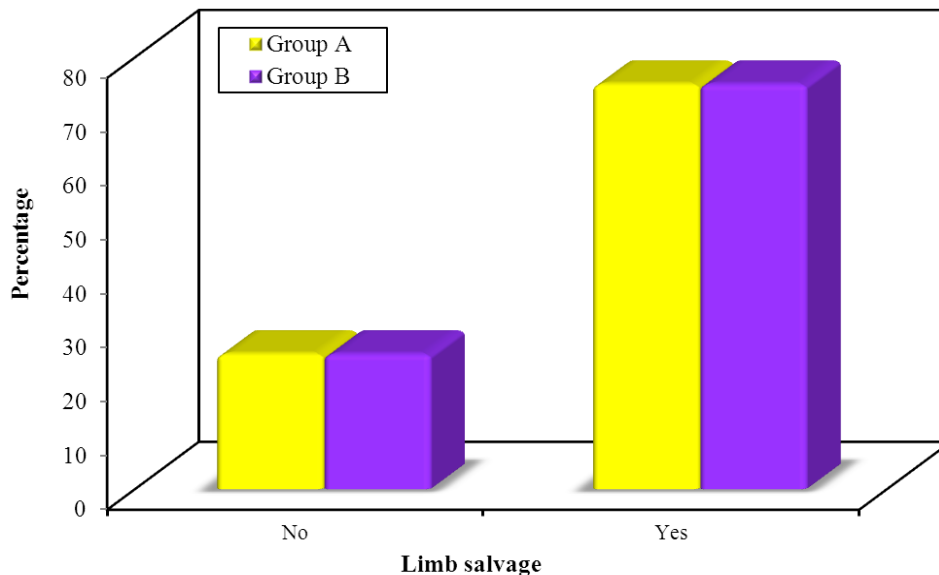


Fig 2: Comparison between the two studied groups according to limb salvage.

As regarding amputations, five patients (25%) underwent major amputation. Thirteen patients (65%) underwent complications. Out of them, five patients (25%) with major complications; three patients with immediate graft thrombosis and underwent below knee amputation after failed graft thrombectomy, one patient with sever graft infection and underwent above knee amputation, and one patient with life threatening hemorrhage and infection underwent below knee amputation. Regarding minor complications, eight patients (40%) with minor complications; three patients (15%) with wound infection treated conservatively with antibiotics and topical antibacterial ointments. one patient with knee contracture scar which treated by physiotherapy. four patients (20%) with post revascularization lower limb edema managed conservatively with limb elevation and below knees elastic stocking with grade II compression applying pressure 20 mmHg and subsided two months post-operatively (Table 2).

Table (2): Amputations and complications in both groups.

Variables		Patients (n= 20)	
		No.	%
Amputation	No	15	75
	Yes	5	25
Complications	Major	5	25
	Acute thrombosis	3	15
	Sever hemorrhage	1	5
	Sever graft infection	1	5
	Huge hematoma& pseudo-aneurysm	0	0
	Minor	8	40
	Edema	4	20
	Infection	3	15
	Hematoma	0	0
Contracture scar at knee	1	5	

DISCUSSION

Recently, a growing body of evidence highlighted promising results of infragenicular angioplasty in diabetic patients with CLI. It was shown that infragenicular angioplasty achieved high patency rates and limb salvage in diabetic patients, which were comparable to non-diabetic patients (13). Nonetheless, limited data are available about the safety and efficacy of infragenicular angioplasty in limited resources areas like Egypt. Accordingly, our study aims to examine the effectiveness and safety of infragenicular angioplasty in diabetic patients with CLI due to single stenosis or occlusion. We demonstrated that most of our patients (90%) had immediate success, with a patency rate of 70% at the end of sixth month of follow-up. Concerning limb salvage, 15 patients (75%) had limb salvage (14 patients with patent arteries).

There were six patients with non-salvaged limb; three with below knee amputation due to failed revascularization and spreading infection in spite of revascularization, one with sever graft infection, one patient with sever life threatening hemorrhage with infection at site if distal anastomosis, and patient had below knee amputation. Our findings run in a parallel with a pooled analysis of more than 6700 patients with infrapopliteal lesions, who underwent angioplasty. The authors reported that the primary patency rate was 91.1%. (17). **Faglia et al.** (18), report, the primary patency rate was 93.6%. **Gamal et al.** (13), recruited 62 patients with diabetic foot ulcer and demonstrated that the primary patency rate was 88.7%. Another report on 101 diabetic patients with CLI showed a lower patency rate (1ry = 67%; 2ndry = 83%); however, the limb salvage rate was comparable to our results (84%) (19). Other reports showed primary patency rates of 75% (limb salvage rate – 91%) (20,21), However, it should be noted that the current literature is not universally homogeneous with other reports showing very low patency rate at 13% (22). Moreover, our salvage rate was

lower than some reports and clinical studies^(23,24). Such discrepancies can be explained by different population (diabetic versus non-diabetic patients)⁽²⁵⁾.

Previous CLI research has mainly focused on patency and limb salvage rates, neglecting cost-effectiveness, clinical improvement, and functional status⁽²⁶⁾. The results of **Romiti et al.'s**⁽²⁷⁾ meta-analysis on 30 infrapopliteal angioplasty studies showed the futility of these endpoints and their ability to misinform patient outcomes. They observed a significant difference between secondary patency and limb salvage, showing that patency was not a requirement for avoiding amputation. As regarding amputations, five patients (25%) underwent major amputation in the present study. Thirteen patients (65%) underwent complications. Out of them, five patients (25%) with major complications. Regarding minor complications, eight patients (40%) with minor complications. Our mortality rate was zero with no fatality case.

We acknowledge that this prospective study has some limitations. All patients were recruited from one center only; therefore, these results may not be generalized to all patients. In addition, the small sample size and the lack of long-term follow-up are other limitations.

CONCLUSION

It could be concluded that infragenicular angioplasty exhibited efficacy in the management of CLI due to single stenosis or occlusion in diabetic patients, with acceptable patency rate and safety profile. Nonetheless, the current published literature shows conflicting results and further studies with multinational collaboration is required to assess the outcomes of infragenicular angioplasty.

REFERENCES

1. **Roglic G (2016):** WHO Global report on diabetes: A summary. *Int J Noncommunicable Dis.*, 1(1):3-6.
2. **Al-Lawati J (2017):** Diabetes mellitus: A local and global public health emergency. *Oman Medical Journal*, 32: 177-9.
3. **Lozano R, Naghavi M, Foreman K et al. (2012):** Global and regional mortality from 235 causes of death for 20 age groups in 1990 and 2010: A systematic analysis for the Global Burden of Disease Study 2010. *Lancet*, 380(9859):2095-128.
4. **Spren M, Gremmels H, Teraa M et al. (2016):** Diabetes is associated with decreased limb survival in patients with critical limb ischemia: Pooled data from two randomized controlled trials. *Diabetes Care*, 39(11):2058-64.
5. **Murabito J, D'Agostino R, Silbershatz H et al. (1997):** Intermittent claudication: A risk profile from the Framingham Heart Study. *Circulation*, 96(1):44-9.
6. **Blaslov K, Zibar K, Bulum T et al. (2013):** Relationship of vascular complications and exenatide therapy failure in type 2 diabetic patients. *Acta Clin Croat.*, 52(3):328-36.
7. **Kamalesh M, Shen J (2009):** Diabetes and peripheral arterial disease in men: Trends in prevalence, mortality, and effect of concomitant coronary disease. *Clin Cardiol.*, 32(8):442-6.
8. **Teraa M, Conte M, Moll F et al. (2016):** Critical limb ischemia: Current trends and future directions. *J Am Heart Assoc.*, 5(2): 002938.
9. **Jude E, Eleftheriadou I, Tentolouris N (2010):** Peripheral arterial disease in diabetes - A review. *Diabetic Medicine*, 27: 4-14.
10. **Voloshyn O, Nykonenko A (2019):** Long-term Quality of Life Results in Patients with Peripheral Arterial Disease after Endovascular Treatment. *Eur J Vasc Endovasc Surg.*, 58(6):477-8.
11. **Nehler M, Coll J, Hiatt W et al. (2003):** Functional outcome in a contemporary series of major lower extremity amputations. *J Vasc Surg.*, 38(1):7-14.
12. **Treiman G, Treiman R, Ichikawa L et al. (1995):** Should percutaneous transluminal angioplasty be recommended for treatment of infrageniculate popliteal artery or tibioperoneal trunk stenosis? *J Vasc Surg.*, 22(4):457-65.
13. **Gamal W, Mohammed Askary Z, Ibrahim M (2017):** Comparison of Clinical outcomes of Infragenicular Angioplasty between diabetic and non-diabetic patients with Peripheral Arterial Occlusive Disease. *Angiol Open Access*, 5(3): 88-93.
14. **Lipsky B, Berendt A, Deery H et al. (2006):** Diagnosis and treatment of diabetic foot infections. *Plastic and Reconstructive Surgery*, 117(7):212-238.
15. **Rutherford R, Baker J, Ernst C et al. (1997):** Recommended standards for reports dealing with lower extremity ischemia: Revised version. *Journal of Vascular Surgery*, 26: 517-38.
16. **Norgren L, Hiatt W, Dormandy J et al. (2007):** Inter-Society Consensus for the Management of Peripheral Arterial Disease (TASC II). *Journal of Vascular Surgery*, 45: 5-67.
17. **Mustapha J, Finton S, Diaz-Sandoval L et al. (2016):** Percutaneous Transluminal Angioplasty in Patients With Infrapopliteal Arterial Disease: Systematic Review and Meta-Analysis. *Circ Cardiovasc Interv.*, 9(5):3468-73.
18. **Faglia E, Mantero M, Caminiti M et al. (2002):** Extensive use of peripheral angioplasty, particularly infrapopliteal, in the treatment of ischaemic diabetic foot ulcers: Clinical results of a multicentric study of 221 consecutive diabetic subjects. *J Intern Med.*, 252(3):225-32.
19. **Tartaglia E, Lejay A, Georg Y et al. (2016):** Results of isolated infrapopliteal percutaneous transluminal angioplasty for critical limb ischemia in high-risk diabetic patients. *Vascular*, 24(5):515-22.
20. **Park S, Kim J, Yun I et al. (2013):** Clinical outcomes of endovascular treatments for critical limb ischemia with chronic total occlusive lesions limited to below-the-knee arteries. *Acta Radiol.*, 54(7):785-9.
21. **Ferraresi R, Centola M, Ferlini M et al. (2009):** Long-term Outcomes after Angioplasty of Isolated, Below-the-knee Arteries in Diabetic Patients with Critical Limb Ischaemia. *Eur J Vasc Endovasc Surg.*, 37(3):336-42.
22. **Sadaghianloo N, Jean-Baptiste E, Declémy S et al. (2013):** Percutaneous angioplasty of long tibial occlusions in critical limb ischemia. *Ann Vasc Surg.*, 27(7):894-903.
23. **Adam D, Beard J, Cleveland T et al. (2005):** Bypass versus angioplasty in severe ischaemia of the leg (BASIL): multicentre, randomised controlled trial. *Lancet (London, England)*, 366(9501):1925-34.
24. **Iida O, Nakamura M, Yamauchi Y et al. (2013):** Endovascular treatment for infrainguinal vessels in patients with critical limb ischemia: OLIVE registry, a prospective, multicenter study in Japan with 12-month follow-up. *Circ Cardiovasc Interv.*, 6(1):68-76.
25. **Ni W, Leong S, Irani F et al. (2020):** "Angioplasty-First" Approach for Limb Salvage in Asian Patients with Critical Limb Ischemia: Outcomes from 3,303 Angioplasties on 2,402 Limbs in a Single Tertiary Hospital. *J Vasc Interv Radiol.*, 31(12):1969-1977.
26. **Sultan S, Tawfik W, Hynes N (2013):** Cool excimer laser-assisted angioplasty (CELA) and tibial balloon angioplasty (TBA) in management of infragenicular arterial occlusion in critical lower limb ischemia (CLI). *Vasc Endovascular Surg.*, 47(3):179-91.
27. **Romiti M, Albers M, Brochado-Neto F et al. (2008):** Meta-analysis of infrapopliteal angioplasty for chronic critical limb ischemia. *J Vasc Surg.*, 47(5):975-981.