

## Outcome of Unilateral Intraocular Retinoblastoma

Mohammad Ahmad Wahdan<sup>1</sup>, Abd Allah El Hussainy Shaleel<sup>1</sup>,

Hossam El Dein Ahmed El Zomor<sup>2</sup>, Hossam El Din Hassan El Sayed El Baz<sup>1\*</sup>

Ophthalmology Department, Faculty of Medicine, Al Azhar University, Pediatric Oncology National Cancer Institute

\*Corresponding author: Hossam El Din Hassan El Sayed El Baz, E-mail: hossam\_eldin4444@yahoo.com

### ABSTRACT

**Background:** retinoblastoma is the most common primary, malignant intraocular tumor of childhood, the aim of the study is to evaluate the outcome of management of 50 consecutive cases of unilateral retinoblastoma.

**Aims of the Work:** to evaluate the outcome of management of unilateral retinoblastoma and to assess the risk of recurrence.

**Patients and Methods:** prospective study of 50 consecutive cases with unilateral intraocular retinoblastoma. The management of cases was performed in the National eye center (Rod El Farag). Fundus examination was done under general anesthesia with RetCam 3. Management of cases according to the staging was group A: Focal treatment, TTT or cryotherapy, group B & C: chemotherapy with focal treatment, group D: If the patient has good visual potential (according to macular affection) Chemotherapy with focal treatment, if the patient has poor visual potential Enucleation, group E Enucleation.

**Results:** as regard cases that managed with chemotherapy, there was 23 cases, 13 out of them treated with chemotherapy and transpupillary thermotherapy and showed complete regression, 10 cases showed initial regression with further new tumor recurrence after finishing chemotherapy, 5 cases was well managed by focal therapy, and another 5 cases failed to be controlled by focal therapy and Intra vitreal melphalan and ended by enucleation. As regard cases that was managed by enucleation, there was 32 cases, 27 out of them managed by primary enucleation, and 5 cases managed by secondary enucleation after failure of chemotherapy and focal therapy, 17 cases out of the enucleated eyes revealed presence of high risk pathological features, none of the cases developed local or metastatic tumors in the follow up period.

**Conclusion:** retinal seeding, vitreous seeding are major predictive factors for tumor recurrence,

**Keywords:** Unilateral Intraocular Retinoblastoma, leukocoria

### INTRODUCTION

Retinoblastoma is the most common primary, malignant intraocular tumor of childhood with an incidence of 1:17000 to 1:34000 new births in USA<sup>(1)</sup>. Some unilaterally diagnosed cases go on to develop tumors in the fellow eye and become bilateral<sup>(2)</sup>. Children with unilateral retinoblastoma are usually diagnosed at a later age than bilateral retinoblastoma<sup>(3)</sup>. Unilateral retinoblastoma most commonly presents with advanced intraocular disease<sup>(4)</sup> and is treated with enucleation. Survival rates of over 90% are now widely reported for unilaterally affected patients treated with simple enucleation<sup>(5)</sup>.

It has been recognized that some cases of unilateral retinoblastoma can be managed without primary enucleation. The diagnosis may be made at an earlier age and stage in children with a family history of retinoblastoma, when small retinoblastomas affect the macula of one eye, causing strabismus, or when the eye is examined for other reasons in the first few months of life. Modalities used for primary therapy include external beam radiotherapy, localized radioactive

applicators, cryotherapy, photocoagulation, and, more recently, systemic chemotherapy<sup>(6)</sup>.

Although such 'conservative' approaches to managing unilateral retinoblastoma have enabled physicians to salvage eyes and vision without sacrificing survival, it has been emphasized that the decision to manage unilateral retinoblastoma without enucleation requires careful analysis of the risks and benefits of such an approach<sup>(6)</sup>.

### AIM OF THE WORK

To evaluate the outcome of management of unilateral retinoblastoma, to assess the risk of recurrence, extra ocular extension and to assess the prevalence of high risk pathological features in the enucleated eyes.

### PATIENTS AND METHODS

#### Patient Selection

Prospective study of 50 consecutive cases with unilateral intraocular retinoblastoma was recruited. The management of cases was performed

In the National eye center (Rod El Farag), the cases was collected in one year & the follow up period was for another year.

Evaluation of cases was done through full detailed history with special attention to prematurity, previous admission in neonatal care unit, contact with dogs, consanguinity. Fundus examination under general anesthesia with RetCam 3, with drawing of the fundus

Staging of the disease was made according to the International (ABC) Classification System for Intraocular Staging

**Group A:**

- Small tumor(s) located only in the retina
- No tumor is larger than 3 millimeters (mm)
- No tumor is closer than 2 disc diameters (DD) from the fovea (the central “pit” of the retina) or 1 DD from the optic nerve
- No vitreous seeding, subretinal seeding or retinal detachment

**Group B:**

- Tumor(s) located in any location in the retina
- No vitreous seeding
- No retinal detachment more than 5 mm from tumor base

**Group C:**

- Fine localized (located in 1 spot) vitreous seeding
- Subretinal fluid without seeding involving up to one quarter of the retina
- Localized subretinal seeding less than 2 disc diameter from the tumor

**Group D:**

- Massive vitreous/sub-retinal seeding
- Retinal detachment: more than Group C and up to total retinal detachment

**Group E:**

Presence of 1 or more:

- Tumor in CB/anterior segment
- Neovascular glaucoma.
- Vitreous hemorrhage.
- Phthisical/prephthisical (deteriorating) eye
- Hyphema

**Management**

According to the staging Management was

**Group A:** Focal treatment, Laser or Cryotherapy

**Group B & C:** Chemotherapy with focal treatment

**Group D:** If the patient has good visual potential (according to macular affection)→ Chemotherapy with focal treatment and if the patient has poor visual potentials→ Enucleation.

**Group E:** Enucleation.

For patients that were managed by enucleation, follow up for the other eye to assess the occurrence of any tumor by photographing the fundus with the fundus camera.

For cases that had conservative management, his/her visits are scheduled after each two cycles during the period of chemotherapy, then as required, focal therapy is started as soon as there no subretinal fluid (usually after the first two cycles) at each visit the residual tumor burden is reassessed, photographed & drawn, the response is documented, and focal therapy are given according to the response.

The enucleated eyes were sent for histopathology, to assess the degree of differentiation and to assess the invasion of the anterior chamber, choroid, sclera and optic nerve, presence of high risk pathological features such as massive choroidal invasion, post laminar optic nerve invasion and scleral invasion, indicate that the patient should receive adjuvant chemotherapy using vincristine, etoposide, and carboplatin to prevent metastasis.

In this study we used the VEC protocol (Vincristine, etoposide, carboplatin) for 6 cycles, each cycle consists of, day one the patient receives the three drugs, day two he receives only etoposide and carboplatin then the patient rests for 26 days, before each cycle the pediatric oncologist assesses his general condition, CBC, kidney and liver function tests are checked. Audiometry was used to monitor drug toxicity.

The dose of vincristine is 0.05mg/kg if the patient is younger than 36 months and 1.5 mg/m<sup>2</sup> if he is older than 36 months with maximum dose 2 mg; vincristine is administered through IV push over two minutes. The dose of etoposide is 6 mg/kg if the patient is younger than 36 months and 180 mg/m<sup>2</sup> if he is older than 36 months; etoposide is administered through IV infusion over 60 minutes with monitoring of blood pressure.

The dose of Carboplatin is 14 mg/kg if the patient is younger than 36 months and 420 mg/m<sup>2</sup> if he is older than 36 months; Carboplatin is administered through IV infusion over 60 minutes.

Thermotherapy is used as the sole method of treatment for small tumors, or in conjunction with other treatment methods for larger tumors or if treatment is not entirely successful in eliminating retinoblastoma. The heat often seems to increase the effectiveness of chemotherapy.

Treatment was performed using infrared diode laser 810 nm. Continuous exposure with

large spot size 1200 nm. Treatment power setting varied from 300 to 1000 mW. According to tumor elevation, starting first with low power, covering the whole surface of the tumor, then increasing the laser power to ensure heating of the tumor.

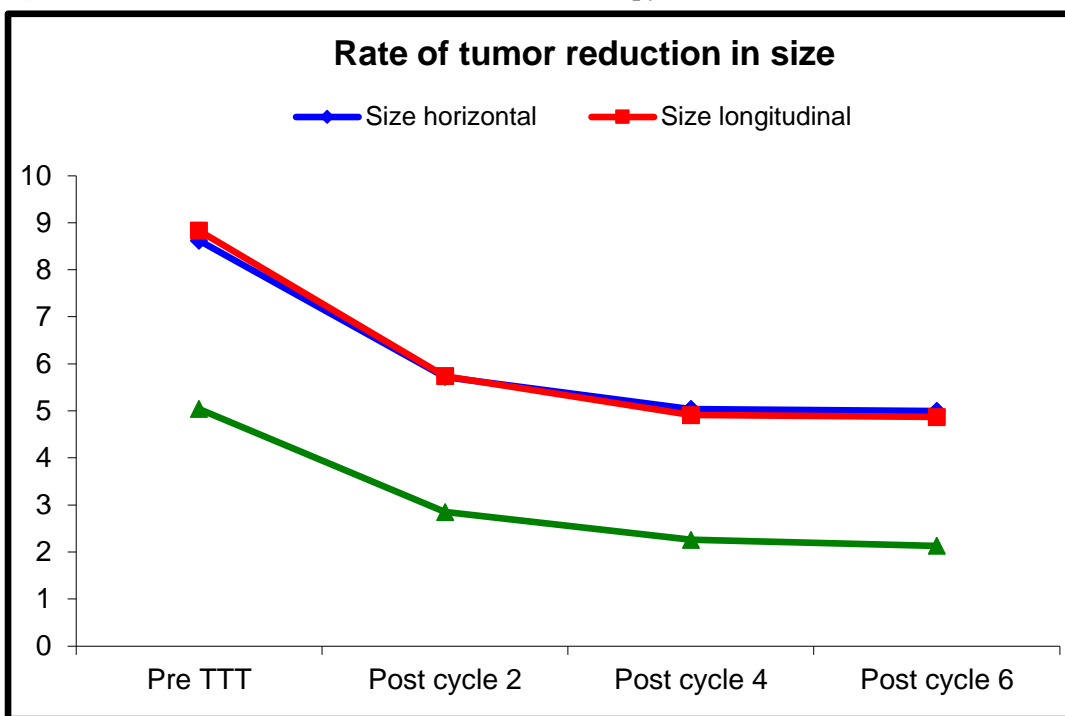
Patient approval before each procedure with counseling about benefits and risks of each procedure

**RESULTS**

**Table (1):** Rate of Reduction of tumor size after chemotherapy

		Pre-TTT	Post 2	Post 4	Post 6	Paired t-test		
						P1	P2	P3
Size horizontal	Mean ± SD	8.62± 2.15	5.72 ± 1.34	5.04 ± 1.46	5.00 ± 1.51	0.001	0.002	0.665
	Range	5 – 13	3 – 8	2 – 8	2 – 8			
Rate of reduction (%)			49.38%	11.9%	0.79%			
Size longitudinal	Mean ± SD	8.83 ± 2.30	5.74 ± 1.68	4.91 ± 1.76	4.87 ± 1.89	0.001	0.001	0.714
	Range	5 – 13	3 – 8	2 – 8	1 – 8			
Rate of reduction (%)			49.29%	14.5%	0.81%			
Size vertical	Mean ± SD	5.04 ± 1.49	2.85 ± 1.08	2.26 ± 1.19	2.13 ± 1.26	0.001	0.001	0.266
	Range	3 – 8	1 – 6	0.5 – 6	0.5 – 6			
Rate of reduction (%)			66.71%	20.7%	5.75%			

**Figure (1):** Rate of Tumor reduction after chemotherapy



The maximum reduction in size occurred after the second cycle , while very little reduction occurred after the 6th cycle

**Table (2):** Assessment of recurrence

## Outcome of Unilateral Intraocular Retinoblastoma

		No (%) / Mean±SD
Recurrence	Negative	13 (56.5%) cases
	Positive	10 (43.5%) cases
Interval between end of chemo. & recurrence	Mean ± SD	2.11 ± 1.62 months
	Range	0 – 4 months
Number of recurrence	Mean ± SD	3.11 ± 1.62
	Range	2 – 4
Primary treatment of recurrence	Transpupillary Thermotherapy & Cryotherapy	10 (100.0%)
	Intra vitreal melphalan	0 (0.0%)
	Enucleation	0 (0.0%)
Response to treatment	Regressed	5 (50.0%)
	Vitreous seeds	2 (20.0%)
	Diffuse recurrence	3 (30.0%)
Additive treatment	Transpupillary Thermotherapy & Cryotherapy	2 (60.0%)
	Intra vitreal melphalan	2 (40.0%)
	Enucleation	0 (0.0%)
Fresponse to the additive treatment	Regressed	0 (0.0%)
	Vitreous seeds	2 (40.0%)
	New recurrence	3 (60.0%)

Recurrence occurred in 10 cases out of 23 cases managed by chemotherapy , transpupillary thermotherapy and cryotherapy was effective in 5 cases , while failed in another 5 cases

**Table (3):** Comparison between recurrent and non-recurrent tumors in the initial assessment

Pre		Non Recurrence	Recurrence	Test value	P-value	Sig.
		No. = 13	No. = 10			
Size horizontal	Mean ± SD	8.08 ± 1.75	9.50 ± 2.22	-1.718•	0.100	NS
	Range	5 – 10	6 – 13			
Size longitudinal	Mean ± SD	8.38 ± 1.56	9.40 ± 2.55	-1.183•	0.250	NS
	Range	5 – 10	4 – 13			
Size vertical	Mean ± SD	4.69 ± 1.49	5.50 ± 1.58	-1.254•	0.224	NS
	Range	3 – 8	3 – 8			
Retinal seeding	Negative	6 (46.2%)	0 (00.0%)	7.611*	0.022	S
	Localized	4 (30.8%)	2 (20.0%)			
	Deffuse	3 (23.1%)	8 (80.0%)			
Vitreous seeding	Negative	13 (100.0%)	8 (80.0%)	0.038*	0.046	S
	Localized	(0.0%)	2 (20.0%)			
	Diffuse	0 (0.0%)	0 (0.0%)			

•: Independent t-test; \*: Chi-square test      NS: Non significant; S: Significant; HS: Highly significant  
Retinal and vitreous seeding is significant predictive factors for tumor recurrence other than tumor size

**Table (4):** Showing distribution of high-risk pathological features

		No.	%
Grade	Well differentiated	0	0.0%

	Moderate	11	34.4%
	Poor	21	65.6%
Optic disc invasion	No invasion	12	37.5%
	prelaminar invasion	13	40.6%
	Post laminar invasion	7	21.9%
Choroidal invasion	No invasion	12	37.5%
	Focal invasion	12	37.5%
	Massive invasion	8	25.0%
Scleral invasion	No invasion	31	96.9%
	Focal invasion	0	0.0%
	Massive invasion	1	3.1%
Post enucleation chemotherapy	Negative	15	46.9%
	Positive	17	53.1%

Among the 32 cases that managed by enucleation , high risk pathological features was present in 17 cases which required adjuvant chemotherapy

## DISCUSSION

The main results of this study revealed that as regard presenting symptoms, 39 (78%) patients their parents complained from leukocoria while 7 (14%) parents complained from squint and 4 (8%) parents complained from other symptoms such as red eye or enlarged globe. this agreed with what Shanmugam et al. reported that the most common presenting symptom was leukocoria (72%), followed by squint (12.5%)<sup>(7)</sup>.

As regard cases that managed with chemotherapy, there was 23 cases, 13 out of them treated with chemotherapy and transpupillary thermotherapy and showed complete regression without any recurrence during the follow up period, 10 cases showed initial regression with further new tumor recurrence after finishing chemotherapy whether on the tumor edge or in the periphery of the retina, 5 cases was well managed by focal therapy, and another 5 cases failed to be controlled by focal therapy and Intra vitreal melphalan and ended by enucleation.

After the second cycle chemotherapy reduction in the horizontal diameter was about 49.38% from the primary tumor size, with further reduction 11.9% after the 4th cycle and 0.8% after the 6th cycle, 49.3% reduction in the longitudinal diameter after the second cycle, with further 14.5% after the 4th cycle and 0.8% after the 6th cycle, Vertical diameter revealed 66.7% reduction after the second cycle with further reduction 20.7% after the 4th cycle with 5.75% after the 6th cycle and this is comparable to what Abramson et al reported

in his study (2005) on 36 tumor, 37.1% mean decrease in area after the first cycle. Mean decrease in area was 17.8% after the second cycle. The mean cumulative decrease in area after two treatments was 55.1%. Mean decrease in area was 5.4% after the third cycle. Cumulative decrease in area after three cycles was 58.1%<sup>(8)</sup>.

The recurrent cases showed larger tumor diameters in the initial assessment, the mean horizontal diameter was  $9.50 \pm 2.22$  in comparison to  $8.08 \pm 1.75$  in the cases that showed no recurrence, the mean longitudinal diameter was  $9.40 \pm 2.55$  in comparison to  $8.38 \pm 1.56$  in the cases that showed no recurrence, the mean vertical diameter was  $5.50 \pm 1.58$  in comparison to  $4.69 \pm 1.49$  in the cases that showed no recurrence, diffuse subretinal seeding was present in 8 cases and 2 cases had localized subretinal seeding in the initial assessment, the only 2 cases that had localized vitreous seeding in the initial assessment, showed diffuse retinal seeding after finishing chemotherapy, revealing that presence of subretinal seeding or vitreous seeding is very predictive for recurrence, this agreed to what Gunduz et al. reported that older patient age, greater tumor thickness, presence of vitreous seeds and subretinal seeds after chemoreduction were factors associated with the need for enucleation<sup>(9)</sup>, also agreed to what Shields et al. reported that presence of diffuse vitreous or subretinal seeds is very predictive of tumor failure<sup>(10)</sup>.

As regard cases that was managed by enucleation, there was 32 cases, 27 out of them managed by primary enucleation, and 5 cases managed by secondary enucleation after failure of chemotherapy and focal therapy, 17 cases out of the enucleated eyes revealed presence of high risk pathological features and eventually needed post enucleation chemotherapy, As regard the follow up of the enucleated eyes, none of them developed local or metastatic tumors in the follow up period, this agreed to what Wang et al. reported that no local or metastatic tumors appeared after the adjuvant chemotherapy<sup>(11)</sup>.

### CONCLUSION

Delay in diagnosis much affects the outcome of management. The maximum reduction in size occurs after the first two cycle of chemotherapy. Retinal seeding, vitreous seeding are major predictive factors for tumor recurrence. There was no correlation between the presence of high risk features and stage of the disease, also there is was no correlation between the degree of tumor differentiation and stage of the disease. Along the follow up period, no case out of the 50 cases in the study, whether managed by chemotherapy or by enucleation, developed extraocular extension or distant metastasis.

### REFERENCES

1. **Abramson DH (1988):** The diagnosis of retinoblastoma. *Acad Med.*, 64: 283-317.
2. **Abramson DH, Notterman RB, Ellsworth RM, Kitchin FD (1983):** Retinoblastoma treated in infants in the first six months of life. *Arch Ophthalmol.*, 101: 1362-6.
3. **Abramson DH, Ellsworth RM, Grumbach N, Kitchin FD (1985):** Retinoblastoma: survival, age at detection, and comparison 1914-1958, 1958-1983. *J Pediatr Ophthalmol Strabismus*, 22: 246-50.
4. **Abramson DH (1982):** Retinoblastoma: diagnosis and management. *Cancer Clin.*, 32: 130-40.
5. **Abramson DH, Ellsworth RM, Grumbach N, Buckhout LS, Haik BG (1986):** Retinoblastoma: correlation between age at diagnosis and survival. *J Pediatric Ophthalmology*, 23:174-7.
6. **Lennox EL, Draper GJ, Sanders BM (1997):** Retinoblastoma: A Study of the Natural History and Prognosis of 268 Br M J., 3(5986):731-4.
7. **Shanmugam MP, Biswas J, Lingam Gopal MS (2005):** The clinical spectrum and treatment outcome of retinoblastoma in Indian children. *Journal of Pediatric Ophthalmology and Strabismus*, 42(2):75.
8. **Abramson DH, Lawrence SD, Beaverson KL, Lee TC, Rollins IS, Dunkel IJ (2005):** Systemic carboplatin for retinoblastoma: change in tumour size over time, *British Journal of Ophthalmology*, 89(12): 1616-1619.
9. **Gunduz K, Gunalp I, Yalcindag N, Unal E, Tacyildiz N, Erden E, Geyik PO (2004):** Causes of chemoreduction failure in retinoblastoma and analysis of associated factors leading to eventual treatment with external beam radiotherapy and enucleation. *Ophthalmology*, 111:1917–1924.
10. **Shields CL, Shelil A, Cater J, Meadows AT, Shields JA (2003):** Development of new retinoblastomas after 6 cycles of chemoreduction for retinoblastoma in 162 eyes of 106 consecutive patients. *Archives of Ophthalmology*, 121 (11): 1571-1576.
11. **Wang Y, Huang D, Shi J, Ma J, Zhao J, Li B, Xu X, Hu H, Zhou Y and Sun Y (2014):** Clinical treatment and prognostic observation for different pathological infiltrations in 537 patients with unilateral retinoblastoma. *Chinese Medical Journal*, 127(20):3581-6.