



Evaluation of Injectable Platelet Rich Fibrin (I-PRF) with Bone Graft around Immediate Dental Implant in Esthetic Zone

Riham M. Reda^{1*}, Abeer S. Gawish², Mai S. Attia³, Mohamed M. Ghoneim⁴

Codex : 15/21.07

azhardentj@azhar.edu.eg

http://adjg.journals.ekb.eg

DOI: 10.21608/adjg.2021.76269.1388

Oral Medicine & Surgical Sciences
(Oral Medicine, Oral & Maxillofacial
Surgery, Oral Pathology, Oral Biology)

ABSTRACT

Purpose: Injectable Platelet Rich Fibrin (I-PRF) is an efficient method in periodontal wound healing and regenerating bone; thus, the purpose of the current research was to assess radiographic and clinical of I-PRF around the immediate dental implant in the esthetic zone with xenograft. **Material and methods:** Twelve patients with unrestorable tooth/teeth in the esthetic zone were selected. Patients were selected randomly and split into two groups; Group I (test group; n = 6) patients that received immediate implant placement using I-PRF and xenograft and Group II (control group; n = 6) patients that established immediate implant placement with xenograft only. Clinically, the pain was evaluated for each patient by using the visual analog scale (VAS). Assessment of healing progress was conducted by modified gingival index (MGI) and modified plaque index (MPI) at 1st, 3rd, and 6th months after implant placement. Radiography, the assessment of osteointegration, can be conducted by bone density at 1st and 6th month after implant placement. **Results:** Regarding the change in both MPI and MGI, there was statistically a significant difference. The study group showed a higher Change than the control group. At 1, 3 and 7 days, there was a statistically non-significant difference in mean VAS in the two groups P=0.18. Regarding Change in Bone Density, the study group showed a higher Change than the control group with a statistically significant difference (P=0.002). **Conclusion:** The use of I-PRF with immediate dental implant placement offers a new promising safe, compatible, and effective method for managing the healing process around immediate dental implants.

KEYWORDS

*Injectable Platelet-rich fibrin,
I-PRF, Dental implant,
Bone healing, Xenograft*

- Paper extracted from Master thesis titled “Evaluation of Injectable Platelet Rich Fibrin (I-PRF) with or without Bone graft around Immediate Dental Implant in Esthetic Zone”
- 1. Dentist, Health Care Quality Supervisor at Baheya Hospital for Early Detection and Treatment of Breast Cancer, Egypt.
- 2. Professor of Oral Medicine, Periodontology, Oral Diagnosis and Radiology, Faculty of Dental Medicine for Girls, Al-Azhar University, Cairo, Egypt and Sinai University, Arish, Egypt
- 3. Associate Professor of Oral Medicine, Periodontology, Oral Diagnosis and Radiology, Faculty of Dental Medicine for Girls, Al-Azhar University, Cairo, Egypt.
- 4. Lecturer of Oral and Maxillofacial Surgery, Faculty of Oral and Dental Medicine, Sinai University, Egypt

* Corresponding author email: rihamredamoussa@gmail.com

INTRODUCTION

The main base of implant success is Osseointegration, the biological method in which bone integrates strongly to the surface of a particular material, e.g. some ceramics and titanium, without soft tissue interference. Implant and bone integration can retain physical loads for decades without failure.⁽¹⁾

Osseointegration is equivalent to primary bone healing with the same sequence in which an inflammatory process with mediator cascade promotes circulatory alteration after surgical trauma, thereby regeneration development and wound replaced by bone tissue⁽²⁾.

No difference had been reported in implant survival rate occurred between one- and two-stage surgeries⁽³⁾. The decision between single-stage or two-stage surgery is now based on how well the soft and hard tissues surrounding the dental implants can be reconstructed.

To minimize alveolar bone loss following extraction, Crest preservation can reduce buccal wall reabsorption and increase alveolar bone formation; hence, the use of an immediate implant can help reduce alveolar bone loss. The significance of maintaining bone structure is directly related to the aesthetic outcome and healthy forms surrounding the implant.⁽⁴⁻⁶⁾

Different surgical procedures performed using other barrier membranes and augmentation techniques such as preservation of alveolar ridge, sinus floor elevation, and guided bone regeneration to recover the lost bone structures. Although of good results of these techniques, there is a need to enhance and promote wound healing and bone regeneration around the dental implant⁽⁷⁾.

For long-term performance, the implant's macro architecture necessitates unique dimensional properties⁽⁸⁾. Bone required for implant placement has adequate bone biological characteristic and volume. The choice of an effective surgical procedure and graft material is part of the treatment planning for

bone graft placement. Resorption of the graft material and failure to incorporate may occur due to poor planning or execution. Fibrous tissue, rather than usable bone, can be used to replace the missing tissue. Implants may be inserted simultaneously during the grafting process or after a phase of primary healing⁽⁹⁾.

In the late 1990s, platelet concentration has its popular name Platelet Rich Plasma (PRP)^(10, 11); PRP is composed of 95% platelet, which produces several growth factors for starting wound-healing, in addition to secreting factors which enhance cell proliferation, adhesion, and migration of several cell types^(10,12). Simultaneously, another formulation of a second platelet concentration is formulated, namely, Platelet Rich Growth Factor (PRGF)^(12, 13).

Besides, various factors were thought to restrict PRP and PRGF application. PRP and PRGF preparation require the extra advantage of anticoagulant (GCL₂, Bovine Thrombin), and it should be centrifugated twice in separated stages to enhance platelet counts without including leukocytes (almost one h), and the PRP-liquid form is challenging to handle, reducing its possible application because it should be used in conjunction with other biomaterials, the clinical efficacy of PRP in regenerating bone is restricted in posing a minimal production of growth factor profile^(14,15).

Due to these limitations, Platelet Rich Fibrin (PRF), the second generation of platelet concentration fabricated from 100% autologous source, has emerged⁽¹⁶⁾. Dissimilar to PRP, which needs the accumulation of anticoagulants like Bovine Thrombin, PRF is obtained by centrifugation without an anticoagulant.

Besides, PRF is a highly compatible matrix since fibrin forms during the final stages of the coagulation cascade. It is combined with cytokines secreted by platelets, particularly in a damaged site where fibrin also serves as a reservoir for tissue growth

factors⁽¹⁷⁾. Such factors enhance the differentiation and proliferation of chondrocytes, osteoblast, endothelial cells, and several fibroblasts⁽¹⁸⁾.

According to the preparation methods, the PRF can be classified into three categories (1) Standard-PRF: which involve a sterile plastic tube (9 ml, 2700 rpm/12 min.) glass-coated; (2) Advanced-PRF: include sterile vacuum tube (10 ml 1500 rpm/14 min.) with plain glass-based. (3) Injectable-PRF: unique tube (10 ml, 700 rpm/3 min.).

One of the most developed of the PRF method is the I-PRF, the standard PRF is made of gel that is injection inconvenient⁽¹⁹⁾. The I-PRF procedure requires centrifugation for a short period to generate liquid platelet concentration, principally involving liquid thrombin and fibrinogen before forming fibrin⁽²⁰⁾.

Since plastic tubes with a hydrophobic surface are used, the coagulation does not begin efficiently. As a result, with a short centrifugation period of 3 minutes, all of the blood portions reach the tube's top under centrifugation power. I-PRF is obtained by aspirating the light-yellow colored layer, which is a mixture of plasma and platelets.⁽²¹⁾

Now I-PRF is applied with bone-graft to retain graft particles strongly encapsulated in fibrin matrix; with the coagulation, I-PRF produces a gel consistency holding bone-graft together; furthermore, the growth factor released is helpful for the graft. Any osteoconductive graft may potentially be converted to osteopromotive, allowing for quicker and improved bone development. The PRF block is another form of graft prepared with I-PRF; I-PRF is mixed with a mixture of bone graft and shredded PRF clot⁽¹⁹⁾.

Few studies had been conducted to assess the situation, the efficacy of (I-PRF) around the dental implant; thus, the present study will be carried out to evaluate clinically and radiographically I-PRF around the immediate dental implant in the esthetic zone.

MATERIAL AND METHODS

Patients' selection:

The current research was a randomized controlled clinical trial, including twelve patients with unrestorable tooth/teeth in the esthetic zone. They were selected from the outpatient clinic of Oral Medicine, Periodontology, Oral Diagnosis and Radiology Department, Faculty of Dental Medicine for Girls, Al-Azhar University. Before any procedure, all participants were informed about the nature, benefits, and/or risks of being involved in the present study and each participant signed an informed consent document. All patients had undergone an adequate pre-surgical preparation consisting of detailed case history and radiographic examination. Approval number **REC-ME-19-05** from the Research Ethical Committee of Faculty of Dental Medicine for Girls, Al-Azhar University was received.

All patients were chosen to agree to the under-mentioned inclusion criteria. Based on the current modified Cornell Medical Index, all of the patients selected were not showing any systemic problems that could impair bone healing or implant placement. Each patient required the extraction of at least one non-restorable tooth located in the esthetic Zone that restored implant needed, non-smoker's patients, good Oral Hygiene. Patients' age ranging from 20 to 50; all patients should not have any known contraindication to oral surgery, no active infection at the extraction site, patients not on chemotherapy or radiotherapy, patients with no bone disease.

Sample size:

Sample size 12 patients according to the research⁽²¹⁾. The sample size was estimated using G*power version 3.1.9.6. Accordingly, a sample size of 12 patients is sufficient to detect an effect size of 0.40, partial eta squared of 0.14, and power of 0.8 (80%). Based on the calculated sample size each group was represented by 6 patients.

Study design and randomization methods:

The present study was a randomized control trial design. A randomized control clinical study was done in the 12 sites of the study. A computerized generated table was used to provide random and equal distribution for the sites involved in the two groups. The patients were shared out equally into two groups. In Group I (test group; n= 6), patients were under-went immediate implant placement using I-PRF and Xenograft. Group II (control group; n = 6) involved patients who underwent immediate implant placement using Xenograft only.

Materials:

1. Neo Biotech implant system (Neo Biotech Co, Seoul, Korea) was used in this study. Implants were made from commercially pure titanium with length ranging from (6.5 – 13 mm) and a diameter ranging from (3.5-5.5 mm), which has sandblasting with large grit and acid etching surface that make rough surface by blasting on machined implant surface with hydroxyapatite particle smaller than 50µm and dual acid etching. Also, it has a wide cutting edge at the apex, which improves fixation and increases operator comfort when placing the implant.
2. Xenograft bone graft (Medtronic -USA).
3. I-PRF plastic tube.

Surgical procedures:

Two phases of the surgical procedure were carried out for each patient. The first one involved atraumatic extraction under local anesthesia and alveolar ridge preservation and placement of an immediate implant, while the second surgical procedure routinely involves Abutment placement. The second procedure was performed 6 months after the first one.

Implant and Grafting Surgical procedures:

Full-thickness flap, Atraumatic extraction, alveolar ridge preservation, post-surgical medication, instructions, and follow-up visits. A sterile field was

prepared. The patients were anesthetized using infiltration technique and/ or nerve block according to a selected site by Articaine 4%, Spain. A full-thickness flap was performed by crestal incision employing no.15c surgical blade mounted on no.3 Bard Parker handle; incision was guided both anterior and posterior around the neck of adjacent teeth if exist. The flap was slightly mirrored with a molt no. 9 periosteal elevator until the periosteal membrane was dissected horizontally at a flap depth to ensure a tension-free closure. The flap allowed to reveal the buccal aspect of the bone so that no bony defects could arise and that the membranes could cover it. A slight reflection of the flap was performed lingually to ensure the complete reflection of soft tissue. A traumatic extraction using straight periotoms and forceps for preserving the surrounding bone. After the Atraumatic extraction, the implant placement procedure was made: The surgical sequence was followed the protocol described by the implant company surgical kit, with reduced low speed (1200 rpm) under copious irrigation with normal saline. The drilling procedure starts with a pilot drill first to full implant length. After drilling the pilot hole, a paralleling pin was used to check parallelism with adjacent teeth. The drilling process continuous with successional drills until reaches to drill diameter less than the implant diameter by 1 mm.

Implants were located at the alveolar crest level using an insertion torque of 35 Ncm, Drilling. The implant is placed in the prepared socket manually first; then, the process will be continued with a ratchet wrench until the implant is fully seated in with the bone level. After a proper osteotomy site preparation, the implant was removed from its sterile vial, then held using its fixture adapter (Titanium dental Implant), installed manually until it reached the proper depth. The implants were positioned in the osteotomy site with crestal bone level. The covering screw is placed in the external hex connector and replaced later by implant abutment after 6 months. The mucoperiosteal flaps were adapted to cover the implant to heal and were sutured with 3-0 polypropylene sutures. Suture removal was done 7-10 days post-operatively.

I-PRF preparation was as following⁽²²⁾:

10 mL of autologous blood was collected from the median cubital vein (forearm) by needle gauge no. 20 connected with a 10-ml sterile syringe without anticoagulant. The entire blood was moved to a 10-mL plastic tube, directly centrifuged for 3 minutes at 700 revolutions/min at room temperature. A liquid form I-PRF was then achieved on Top of the tube just and the red corpuscles at the bottom Figure 1 (A). Subsequently, the I-PRF liquid form was collected from the tube by a sterile Plastic Syringe without add any anticoagulant Figure 2 (B).

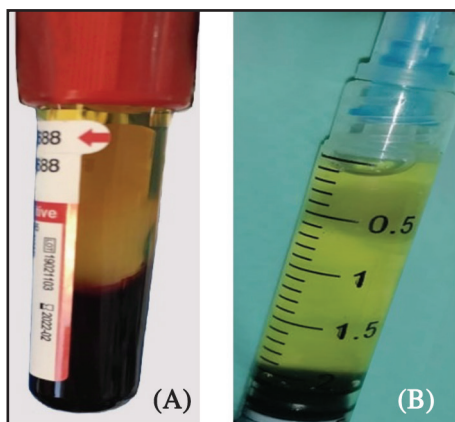


Figure (1) (A) showed the I-PRF in the tube after center fusion.
Figure (1) (B) I-PRF after being collected in a plastic syringe to be ready to use

Bone Graft Placement:

In the **Control Group**, Xenograft was put in a bone dish, and few drops of sterile saline mixed with the bone graft in the bone dish using a condenser to form a sticky bone graft. Then the mix of bone graft applied around the immediate implant.

In the **Study Group**, xenograft was put in the bone dish, and few drops of I-PRF mixed with the bone graft in a bone dish using a condenser to form a sticky bone graft. Then the mix of bone graft is applied to the Space around the immediate implant. A figure of eight sutures is then made to close the flap in the graft and implant with resorbable suture material (Vicryl 3-0) A periodontal pack was

applied over the flap. A suture was removed 7-10 days post-operatively

Post-surgical medications and instructions:

The patient was instructed to avoid eating or drinking for one hour after surgery. Soft and cold food was recommended for one day the post-operative one day. 2- Patients were advised to use cold fomentation on the day of operation to reduce edema formation. Patients were instructed to use chlorhexidine mouth wash three times daily for two weeks starting the 24 hours after the surgery to reduce the risk of infection. Antibiotic, anti-inflammatory, and anti-edematous medications were prescribed for all patients. Post-operative antibiotics following regenerative procedure (bone graft with or without I-PRF) from three to ten days after procedure were recommended by several researchers⁽²⁴⁾. Antibiotic [amoxicillin- Clavulanic acid orally:1gmevery 12 hours for 7 days + metronidazole500 mg orally tabs every 12 for 7 days] Anti-inflammatory [Diclofen potassium 50 mg tab every 8 hours] Anti-edematous [chymotrypsin-trypsin,1 tablet 3times daily for 5 days].

Follow up visits:

The patients returned for follow-up and removal of suture7- 10 days later; patient follow-up visits were planned to be in 3 and 6 months after the procedure.

Clinical evaluation

Clinical reading was obtained after 1, 3, and 6 months after implant placement.

Clinical parameters include⁽²⁵⁾:

- **Modified Plaque index (MPI):**

It was used to assess plaque accumulation around the gingival margin and measured in four locations mesiobuccal, distobuccal, mesiolingual distolingual around the implant site. The degree of plaque accumulation was evaluated according to the

following criteria (0 - no plaque; 1 - plaque only with a probe; 2 - Plaque visible to the naked eye; and 3 - abundant plaque). Reading was being obtained after 1, 3, and 6 months after implant placement by using a periodontal probe.

The average of (MPI) scores for each implant was calculated by dividing the four collecting values.

- **Modified Gingival index (MGI):**

The gingival conditions were scoring by using a periodontal probe according to the following criteria (0-no bleeding; 1- isolated bleeding spots; 2-confluent blood; 3-profuse bleeding). And it's measured in four locations mesiobuccal, distobuccal, mesiolingual distolingual around the implant site; reading was being obtained after 1, 3, and 6 months after implant placement

The average of (MPI) scores for each implant was calculated by dividing the four collecting values.

- **Pain assessment:**

Was evaluated at 1 day, 3 days, 7 days post-operatively using a Visual analog scale (VAS).

Radiographic assessment:

Cone Beam analysis:

- CBCT was taken for each patient by using the Planameca machine. The tube voltage was 90 kV, the tube current was 12Ma according to the field of view of pulse exposure.
- For the Implant treatment plane, CBCT data was a valuable resource for information that enhance the treatment plan as linear measurement, bone quality, 3D assessment of ridge topography, and vital structure approximation like maxillary sinus and inferior alveolar nerve.
- The CBCT was taken at the baseline and 6 months after implant placement for evaluation.

Bone Density:

Bone density value (as grey value) was determined using software that automatically illustrated the difference in the gray value in numbers by moving the pointer from one region to another. The bone density was taken at a fixed point on the software at baseline and after 6 months of implant placement. The bone density was taken into two planes, coronal and sagittal. For each one-two, lines were drawn parallel to the entire length of the implant, and each line was divided into three areas (coronal, middle, apical) thirds:

- » These three lines were recorded at a fixed point away parallelly from the implant to be away from titanium artifact at the bone-implant interface.
- » The bone density value around the implant was measured Automatically by CBCT software which was recorded in Hounsfield Unit.

Prosthetic phase:

After 6 months post-operatively, the crestal incision was made and the abutment was tightened, a condensation silicone impression was utilized to take the impression, and final Ceramic metal crowns were cemented to all patients.

Statistical analysis:

Data were handled and analyzed using IBM-SPSS software package version 26.0 for Mac OS (Armonk, NY: IBM Corp.). Data were checked for normality using Shapiro-Wilk to evaluate whether data are parametric or nonparametric, qualitative data (nonparametric) were described using number and percent, significance was assessed at 0.05 level. To compare two groups of nonparametric data, the Chi-square test and/or Fisher exact test only when the expected count in any cell was found less than 5. To compare between two different groups of parametric data, an Independent t-test was applied; however, for nonparametric data, the Mann-Whitney test was applied. Repeated measure ANOVA was performed to check the effect of different treatment groups and time of investigation in addition to the interaction

between time and groups at 0.05 level. One-way ANOVA was followed by Duncan's Multiple Range Tests (DMRTs).

RESULTS

Table (1) demonstrate the demographic data. 6 patients ranged in age between 29.00-50.00 years with a mean age of 45.16 ± 8.10 years for the Control group and 6 patients ranged in age between 29.0- 50.00 years with a mean age 40.16 ± 8.08 years for the Study group. There was a statistically non-significant difference between the two groups regarding the mean of age. The Control group had 3 males and 3 females, while the Study group had 4 males and 2 females. There was a statistically non-significant difference between gender distributions in the two groups.

Table (2) summarises the comparison between the different periods in each group according to the modified plaque index in each studied group. Both groups showed a statistically significant decrease in mean Modified plaque index measurements at 1, 3, 6 months. At 1, 3 and 6 months, there was a statistically non-significant difference in mean Modified plaque index in the two groups. The Control group show -0.25 ± 0.59 Changing in MPI; however, this difference was statistically insignificant ($P=0.48$). The study group show -1.0 ± 0.47 Changing in MPI; however, this variation was significant ($p=0.008$) statistically. Regarding Change in MPI, there was statistically a significant difference. the study group showed a higher Change than the control group $P=0.04$

Table (1): Comparison between the two studied groups according to demographic data:

Variable	Control (n = 6)	Study (n = 6)	Significance
Sex			
Male	3 (50.0)	4 (66.7)	Chi= 0.34 Sign. >0.05 ns
Female	3 (50.0)	2 (33.3)	
Age (years)			
Min. – Max.	29.00 -50.00	29.00 -50.00	Mann-Whitney U = 0.29 Sign. >0.05 ns
Mean \pm SD.	45.16 ± 8.10	40.16 ± 8.08	
Median	49.0	41.0	

*, **, *** significant at $p < 0.05$, < 0.01 , < 0.001 ; ns, non-significant at $p > 0.05$

Table (2): Modified Plaque Index (MPI) in both control and study groups at different periods.

Groups	Time (months)	Modified plaque index				p-value	Change in MPI
		Min.	Max.	Mean \pm SD	Median		
Control (n = 6)	1	0.50	1.75	0.87 ± 0.51	0.62	0.048*	-0.25 ± 0.59
	3	0.50	1.0	0.91 ± 0.20	1.0		
	6	0.0	1.0	0.62 ± 0.44	0.75		
Study (n = 6)	1	1.0	2.0	1.37 ± 0.44	1.25	0.008*	-1.0 ± 0.47
	3	0.50	1.0	0.87 ± 0.21	1.0		
	6	0.0	1.5	0.37 ± 0.58	0.12		
p-value between the 2 groups		Non-significant $p > 0.05$ at 1,3, and 6 months				0.04	

*, **, *** significant at $p < 0.05$, < 0.01 , < 0.001 ; ns, non-significant at $p > 0.05$

Table (3) summarises the comparison between the different periods in each group according to the modified gingival index in each studied group. Both groups showed a statistically significant decrease in mean Modified gingival index measurements at 1, 3, 6 months, Regarding the 6 months readings of MGI, the Study Group showed a lower MGI mean 0.33 ± 0.49 than control Group, which showed 0.66 ± 0.40 . At 1,3, and 6 months, there was a statistically non-significant difference in mean Modified gingival index in the two groups. Regarding Change in MGI, there was statistically a significant difference $p =$

0.04. The study group showed a higher Change than the control group.

Table (4) summarises the comparison between the different periods in each group according to VAS in each studied group. Both groups showed a statistically significant decrease in mean VAS measurements at 1, 3, 7 days. At 1,3, and 7 days, there was a statistically non-significant difference in mean VAS in the two groups. Regarding Change in VAS, there was a statistically non-significant difference ($p > 0.05$).

Table (3): Modified Gingival Index (MGI) in both control and study groups at different periods. Means followed by different letters are significantly different at 0.05 level.

Group	Time (months)	Min.	Max.	Mean ± SD	Median	p-value	Change in MGI Mean ± SD
Control (n = 6)	1	0.75	1.5	1.0 ± 0.32 ^{AB}	0.88	>0.05 ns	-0.33 ± 0.46
	3	0.75	1.0	0.88 ± 0.14 ^{AB}	0.88		
	6	0.0	1.0	0.67 ± 0.41 ^{AB}	0.75		
Study (n = 6)	1	1.0	1.75	1.25 ± 0.31 ^A	1.1	0.008*	-0.91 ± 0.37
	3	0.50	1.0	0.83 ± 0.20 ^{AB}	0.87		
	6	0.0	1.25	0.33 ± 0.49 ^B	0.12		
Repeated Measures ANOVA							
Source of variation		F-ratio		p-value			
Groups (control, Study)		112.8		<0.001***			
Time points (1, 3, 6)		6.78		0.006**			

*, **, *** significant at $p < 0.05$, < 0.01 , < 0.001 ; ns, non-significant at $p > 0.05$

Table (4): Comparison between the different periods in each group according to VAS in each studied group, means followed by different letters are significantly different.

Groups	Time (day)	VAS				p-value	Change in VAS Mean ± SD
		Min.	Max.	Mean ± SD	Median		
Control (n = 6)	1	3.0	4.0	3.5 ± 0.54 ^A	3.5	0.002**	-2.66 ± 0.51
	3	1.0	3.0	2.1 ± 0.75 ^B	2.0		
	7	0.0	1.0	0.83 ± 0.40 ^C	1.0		
Study (n = 6)	1	3.0	5.0	3.83 ± 0.75 ^A	4.0	0.002**	-3.33 ± 0.81
	3	1.0	3.0	2.16 ± 0.75 ^B	2.0		
	7	0.0	1.0	0.50 ± 0.54 ^C	0.5		
<i>p</i> -value between 2 groups				Non-significant at $p > 0.05$; at 1, 3, and 6 day			

*, **, *** significant at $p < 0.05$, < 0.01 , < 0.001 ; ns, non-significant at $p > 0.05$

Table (5) and Figure (1) illustrated the changes in bone density in two groups throughout the study. Control group and study group readings were 689.66 ± 93.04 and 740.5 ± 78.58 ; respectively, at the baseline; this statistically was with a non-significant difference ($p > 0.05$). The control group showed an increase in its bone density from 689.66 ± 93.04 to 764.5 ± 77.66 at the end of the study (after 180 days); this increase was statistically with a highly significant difference ($P=0.03$). The study group showed an increase from 740.5 ± 78.58 to 894.66 ± 84.49 at

the end of the study (after 180 days); this increase was with a highly significant difference statistically ($p= 0.03$).

The Control group showed an increase in its density of 74.83 ± 19.31 throughout the study while the Study group increased 154.16 ± 42.44 and the changes in the percentage of bone density between both readings before and after implant insertion were statistically with a highly significant difference (p -value= 0.002).

Table (5): Comparison between the different periods in each group according to Bone Density in each studied group. means followed by different letters are significantly different.

Groups	Time	Bone Density				p-value	Change (Mean ± SD)
		Min.	Max.	Mean ± SD	Median		
Control (n = 6)	baseline	512	790	689.7 ± 93.04	705.5	0.03 *	74.83 ± 19.31
	6 months	610	830	764.5 ± 77.66	786.0		
Study (n = 6)	baseline	610	813	740.5 ± 78.58	770.0	0.03 *	154.16 ± 42.44
	6 months	790	1021	894.7 ± 84.49	876.0		

ANOVA repeated measures		
Source of variation	F-ratio	p-value
Groups	3.65	0.085 ns
Time	144.683	<0.001***
Time * groups	17.364	0.002**

*, **, *** significant at $p < 0.05$, < 0.01 , < 0.001 ; ns, non-significant at $p > 0.05$

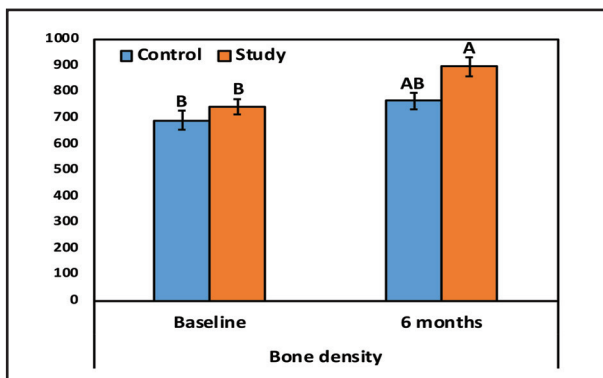


Figure (2): Comparison between the different periods in each group according to Bone Density in each studied group. Bars with different letters are significantly different according to DMRTs.

The significant difference in the increase of the bone density between the Control Group and Study influence the success of implant in the long period and the measure of bone density through CBCT support the significant different of bone density between control group and study group.




Figure (3) (A) CBCT demonstrates the bone density around the dental implant pre-operatively of the control group (A1) and study group (B1) and After 6 months of implant insertion in the Control group (A2) and study group(B2).

DISCUSSION

One of dentistry’s most complex challenges is immediate implant placement in the aesthetic region. Immediate dental implant placement has the benefit of minimizing recovery time and having a comparable success rate to delayed implants; however, it allows for immediate provisionalization, allowing for excellent cosmetic outcomes and enhancing the patients’ quality of life.⁽²⁵⁾

This innovative advancement in the field of PRF, such as I-PRF, has opened a new way for the usefulness in the applications of platelet concentrates. It influences osteoblastic behaviour with a tremendous release of growth factors alone or in combination with bone graft. The significant advantage and features of I-PRF are: the ability to regenerate tissue vascularisation and thus a successful dental implant; high potential for tissue regeneration; I-PRF is capable of accelerating the formation of bone and gingival tissues; ability to accelerate the formation of bone and gingival tissues; and the ability to accelerate the formation of bone and gingival tissues.⁽²⁴⁾

There was a study confirms that the use of

Xenograft is considered as one of the readily available bone grafts with reasonable cost, the predictable clinical outcome with Biocompatibility. Bovine xenografts play a significant role and have been proven for craniomaxillofacial applications.⁽²⁶⁾

The sex of the patient (Male or Female) did not affect the results of the study.

Research showed that the antimicrobial effect of I- PRF that support the results of this study that showed the modified gingival index and the modified plaque index results show significant difference between the control and study group as this has been discussed by many authors that the I-PRF has an antibacterial effect the improve the tissue healing.^(27,28)

A study held in, showed, showed a decrease in the pain score assessed by using VAS along the different observational times within each study group. Both groups showed a statistically significant reduction in mean VAS measurements at 1, 3, 7 days. At 1,3 and 7 days, there was a statistically non-significant difference in mean VAS in the two groups. Regarding Change in VAS, there was a statistically non-significant difference $P=0.18$.⁽²⁹⁾

The bone density showed a significant difference between the control group and the study group, according to the study held in, discussed the significant effect of I-PRF with grafted bone and increased the cell migration of osteoblast this means more bone formation and more dense bone.⁽³⁰⁾

CONCLUSION

The use of Injectable Platelet Rich Fibrin around the immediate dental implants may be able to increase and improve healing around dental implants by the anti-inflammatory and antibacterial properties and increase the success rate of dental implants by increase the bone density.

RECOMMENDATION

Further studies on the use of injectable platelet Rich fibrin with an immediate dental implant with a longer period of follow-up the cases and larger sample size are needed.

ACKNOWLEDGMENTS

The staff members of Oral Medicine and periodontology had great assistance during the progress of the study.

Declaration Of Interests:

No financial conflicts of interest are to be declared. The study was self-funded by the principal investigator.

REFERENCES

- Misch, CE. Contemporary implant dentistry St. Louis Missouri, Mosby Elsevier. Implant Dentistry: 1999; 8 (1)- 90
- Schell H, Duda GN, Peters A, Tsitsilonis S, Johnson KA, Schmidt-Bleek K. The haematoma and its role in bone healing. *J Exp Orthopaed.* (2017) 4:5. 10.1186/s40634-017-0079-3
- Gheisari R., Eatemadi H., Alavian A. Comparison of the Marginal Bone Loss in One-stage versus Two-stage Implant Surgery. *J Dent Shiraz Univ Med Sci.*, 2017; 18(4): 272-276.
- Gluckman H, Salama M, Du Toit J. Partial extraction therapies (PET) part 2: procedures and technical aspects. *Int J Periodontics Restorative Dent.* 2017;37(3):377-385..
- Canellas JVDS, Medeiros PJD, Figueredo CMDS, Fischer RG, Ritto FG Platelet-rich fibrin in oral surgical procedures: a systematic review and meta-analysis. *Int J Oral Maxillofac Surg.* ; 2019;48, (3): 395-414.
- Gluckman H, Salama M, Du Toit J. Partial extraction therapies (PET) part 1: maintaining alveolar ridge contour at pontic and immediate implant sites. *Int J Periodontics Restorative Dent.* 2016;36(5):681-687.
- Saleem, M., Pisani, F., Zahid, F.M., Adjunctive platelet-rich plasma (PRP) in intrabony regenerative treatment: a systematic review and RCT's meta-analysis. *Stem Cells Int.* 2020; 65(2): 131-142.
- Hsieh, M-T., Begley, M.R., Valdevit, L., Architected implant designs for long bones: Advantages of minimal surface-based topologies, *Materials & Design* 2021;207 109838
- Jo SH, Kim YK, Choi YH. Histological Evaluation of the Healing Process of Various Bone Graft Materials after Engraftment into the Human Body. *Materials (Basel).* 2018 2;11(5):714.
- Kothari K. Role of platelet-rich plasma: The current trend and evidence. *Indian J Pain* 2017;31:1-6.
- Patel GK, Gaekwad SS, Gujjari SK, Kumar V. Platelet-rich fibrin in regeneration of intrabony defects: a randomized controlled trial. *J Periodontol.* 2017;88:1192-1199..
- Anitua E, Prado R, Troya M, Zalduendo M, de la Fuente M, Pino A, et al. Implementation of a more physiological plasma rich in growth factor (PRGF) protocol: Anticoagulant removal and reduction inactivator concentration. *Platelets* 2016;27:459-66.
- Lucarelli E, Beretta R, Dozza B, Tazzari PL, O'Connell SM, Ricci F, et al. A recently developed bifacial platelet-rich fibrin matrix. *Eur Cell Mater* 2010;20:13-23.
- Kobayashi E, Fluckiger L, Fujioka-Kobayashi M, Sawada K, Sculean A, Schaller B, et al. Comparative release of growth factors from PRP, PRF, and advanced-PRF. *Clin Oral Investig.* 2016;20: 2353-60.
- Khouly I., Pardiñas López S., Aliaga I., Froum S.J. Long-Term Implant Survival After 100 Maxillary Sinus Augmentations Using Plasma Rich in Growth Factors. *Implant Dent.* 2017;26:199-208..
- Patel GK, Gaekwad SS, Gujjari SK, Kumar V. Platelet-rich fibrin in regeneration of intrabony defects: a randomized controlled trial. *J Periodontol.* 2017;88:1192-119.

17. Miron RJ, Bishara M, Choukroun J. Basic of platelet-fibrin therapy. *Dentistry Today*. 2017;36: 74-6.
18. Del Fabbro, M., Bucchi, C., Lolato, A., Corbella, S., Testori, T., Taschieri, S., Healing of postextraction sockets preserved with autologous platelet concentrates. a systematic review and meta-analysis. *J. Oral Maxillofac. Surg.* 2017;75 (8), 1601–1615..
19. Shah R, Triveni MG, Thomas R. An update on protocols and biologic action of platelet-rich fibrin in dentistry. *Eur J Prosthodont Restor Dent*. 2017; 25:64-72.
20. Franz J S, Alexandra S, Rein G. The use of platelet fibrin to enhance the outcomes of implant therapy: A systemic review. *Clin Oral Impl Res*. 2018; 29:6-19.
21. Richard JM, Masako F., Maria H. Injectable Platelet Rich Fibrin (I-PRF): Opportunities in regenerative dentistry. *Clin Oral Invest* 2017;21:1-9.
22. Miron RJ, Fujioka-Kobayashi M, Hernandez M, Kandalam U, Zhang Y, Ghanaati S, Choukroun J. Injectable platelet-rich fibrin (I-PRF): opportunities in regenerative dentistry?. *Clin Oral Investig* 2017;21:2619-27.
23. Chenchov IL, Ivanova VV, Neychev DZ, Cholakova RB. Application of Platelet-Rich Fibrin and Injectable Platelet-Rich Fibrin in Combination of Bone Substitute Material for Alveolar Ridge Augmentation - a Case Report. *Folia Med (Plovdiv)*. 2017 Sep 1;59(3):362-366.
24. Diksha R. Agrawal, Priyanka G. Jaiswal. Injectable Platelet Rich Fibrin (i-PRF): A Gem in Dentistry *IJCRR* 2020;12:25-30
25. Salvi GE and Lang NP. Diagnostic parameters for monitoring peri-implant conditions. *Int J Oral Maxillofac Implants* 2004;19:116–27
26. Tadea LM, Héctor Z, Karla R, Daniel M (2020) Immediate Implant Placement in the Aesthetic Zone: A Multidisciplinary Management - Case Report. *Int J Oral Dent Health* 6:111.
27. Haugen HJ, Lyngstadaas SP, Rossi F, Perale G. Bone grafts: which is the ideal biomaterial? *J Clin Periodontol*. 2019;46 Suppl 21:92-102. doi: 10.1111/jcpe.13058. PMID: 30623986..
28. Kour P, Pudukalkatti PS, Vas AM, Das S, Padmanabhan S. Comparative evaluation of antimicrobial efficacy of platelet-rich plasma, platelet-rich fibrin, and injectable platelet-rich fibrin on the standard strains of *Porphyromonas gingivalis* and *Aggregatibacter actinomycetemcomitans*. *Contemp Clin Dent* 2018;9(Suppl 2):S325.
29. Fotani S, Shiggaon LB, Waghmare A, Kulkarni G, Agrawal A, Tekwani R. Effect of injectable platelet-rich fibrin (i-PRF) on thin gingival biotype: A clinical trial. *J. appl. dent. med. sci.* 2019;5:10-16.
30. Sirintawat N, Sawang K, Chaiyasamut T, Wongsirichat N. Pain measurement in oral and maxillofacial surgery. *J Dent Anesth Pain Med*. 2017; 17(4): 253–263.
31. Wang X, Zhang Y, Choukroun J, Ghanaati S, Miron RJ. Effects of injectable platelet-rich fibrin on osteoblast behavior and bone tissue formation in comparison to platelet-rich plasma. *Platelets* 2018;29:48-55