

THE EFFECT OF VARIED FORCE VECTOR ON TYPE OF TOOTH MOVEMENT OF MAXILLARY ANTERIOR TEETH DURING EN MASSE RETRACTION; RANDOMIZED CLINICAL TRIAL

Tarek N. Yousry*, Mohamed Mowafy**, Sherief H. Abdel-Haffiez*

Keywords: *En-masse retraction, mini-implants, force vector.*

Introduction: *En-masse retraction of upper anterior teeth is a common method for sliding mechanics tooth movement. Predictable tooth movement requires that the force vector passes through the center of resistance of upper maxillary teeth.*

Materials and methods: *This randomized clinical trial was carried on female patients in need of extraction of at least of two maxillary first premolars. The sample was separated into three groups; Group I: study group with Anterior retraction hook (ARH) of 9 mm, group II: study group with ARH of 6 mm, group III: study group with ARH of 3mm. Cone beam computed tomography were taken at two-time intervals for the whole sample; T1: Before the onset of en-masse retraction and T2: At the end of en-masse retraction.*

Results: *Significant reduction in the inclination of anterior teeth as measured to the palatal plane had been recorded in three groups. Significant retraction of crowns and roots of anterior teeth had been recorded in all groups. Significantly lower amount of root movement had been recorded in group 2 and 3 compared to group 1. All groups showed statistically significant intrusive movement with significantly less intrusion movement in group 2 and group 3 relative to group 1.*

Conclusions: *Bodily movement is possible during en-masse retraction if the force vector passes through the center of resistance of anterior teeth. Increasing length of ARH decrease amount of uncontrolled tipping during en-masse retraction with more intrusive effect on the anterior teeth.*

Introduction

Orthodontics includes the usage and control of forces applied to teeth and bone. Teeth extraction is often used as a treatment strategy to resolve severe crowding, correct protruded anterior incisors, achieve optimum molar relationships, and improve facial esthetics.⁽¹⁾

Maxillary anchorage control is more challenging compared to the mandible as mandibular molars do not move forward as easy as the maxillary molars due to their anatomic morphology and position. In the maxillary arch, mesial movement of the first molar or what is regarded as 'Anchorage loss' occurs more easily. This is especially critical in the management of class II division 1 malocclusion. The correction of anchorage loss usually requires complex mechanics and prolonged treatment duration.

During 'En-masse retraction' the incisors with the canines are retracted as a single unit. Bennett and McLaughlin⁽²⁾ who developed the MBT system relied mainly on this method of space closure.

In a finite element analysis⁽³⁾ aiming to identify the best retraction setup such as length of the power arm and its position on the archwire, a 3D finite element model was designed to mimic en masse retraction in sliding mechanics.

Upper central incisor labio-palatal tipping was assessed against different power arm heights, located mesial or distal to the canine. When the

*Lecturer, Orthodontic Department, Faculty of Dentistry, Alexandria University.

**Assistant Professor, Orthodontic Department, Faculty of Dentistry, Alexandria University.

point of force application was mesial to the canine and at the same level of the arch wire, lingual tipping of the incisor occurred together with downward deformation of the anterior part of the archwire. Increasing the force level to 5.5 mm gingival to the archwire resulted in bodily movement and less archwire deformation. But above 5.5 mm lingual root tipping occurred together with upward deformation of the archwire.

On the other hand when the point of force application was distal to the canine, lingual crown tipping was observed even with the force level as high as 11.2 mm. so it was recommended to use an arm height of 4-5 mm to achieve controlled lingual crown tipping of the upper central incisor.

Another finite element analysis study ⁽⁴⁾ was performed to examine effective en-masse retraction with TADS. They treated bimaxillary protrusion cases, using TADS placed in different positions and at different heights, with variable power arm heights, compensating curves, and midline traction. They didn't find much difference upon studied variables as they had minimal effect on tipping of the incisors. The 0.016X 0.022 inch stainless steel archwire allowed more tipping than the 0.019 X 0.025 inch archwire.

Hedayati et al ⁽⁵⁾ found that 9 mm long anterior retraction hooks led to bodily movement and decreased rotational tendency of the anterior teeth irrespective of the TAD position.

Upon using 2mm length ARH Zhang et al ⁽⁶⁾ found lingual crown tipping of the lateral incisor, while when using 4mm only the maxillary central and canine teeth showed lingual crown tipping while the lateral incisors moved bodily with intrusion.

In a recent systematic review to evaluate studies dealing with the efficiency of en-masse retraction on TADS regarding the retraction hook position and height. The results of the

included studies were mixed. It was concluded that the force vector has to pass through the center of resistance. ⁽⁷⁾

In another study by Pedersen et al ⁽⁸⁾ the CR of anterior teeth was found to lie on a line 3 mm behind the distal surface of the canines.

In addition Melsen et al ⁽⁹⁾ estimated that the CR of the anterior teeth is halfway between the center of resistance of the incisors and the center of resistance of the canines.

Nevertheless, all previous studies to evaluate the effect of varying retraction hook height were finite element studies. Orthodontic tooth movement is a biological process accomplished by alveolar bone (re)modeling, triggered by changes in the stress distribution in the Periodontal ligament(PL). In finite element models assignment of non-linear mechanical properties for the PL, show that it's loading cannot be simply described in terms of compression and tension. ⁽¹⁰⁾

The null hypothesis of this study was that varying the height of anterior retraction hook will have no effect on the vertical position of the maxillary anterior teeth during mini-implant supported en- masse retraction.

MATERIALS AND METHODS

Sample collection

The following criteria were strictly followed in patient selection:

Inclusion criteria

1. Female patients with age range between 16 to 22 years.
2. Need of extraction of at least upper first premolars as a part of the orthodontic treatment plan with overjet greater than 6 mm.
3. Need for maximum or absolute maxillary posterior anchorage.
4. Symmetrical maxillary arch with minimal maxillary midline deviation (2mm or less)
5. Good oral hygiene and gingival condition with no loss of epithelial attachment.

6. Completely erupted permanent dentition excluding the third molars.

Exclusion criteria

1. Bad oral hygiene with signs of gingival inflammation.
2. Radiographic evidence of bone loss.
3. Radiographic evidence of root resorption in the maxillary anterior region.
4. History of previous orthodontic or orthopedic treatment.
5. Medically compromised patients with any systemic disease affecting the rate of tooth movement or bone metabolism.
6. Pregnant or lactating females to exclude hormonal influence on rate of tooth movement or bone metabolism.
7. Patients receiving pharmacological agents that affect the rate of orthodontic tooth movement such as corticosteroids and analgesics.

8. History of trauma or root canal treatment of maxillary anterior teeth.

Patients with fair oral hygiene were scheduled for thorough gingival and periodontal treatment with oral hygiene instructions for at least 4 weeks and re-examined to evaluate gingival and periodontal condition before taking the decision of enrollment onto the sample.

Periodontal condition was examined clinically by measuring probing depth and evaluating bleeding on probing according to the bleeding sulcus index.⁽¹¹⁾

Sample size calculation was made using Power and Sample Size Calculation computer software (Epi-Info 7 software, Atlanta, GA, USA). At $\alpha=0.05$ and a power of 0.95, giving six patients per group.

Eighteen patients were chosen to be enrolled in the study. (Figure1). They all met the selection criteria.

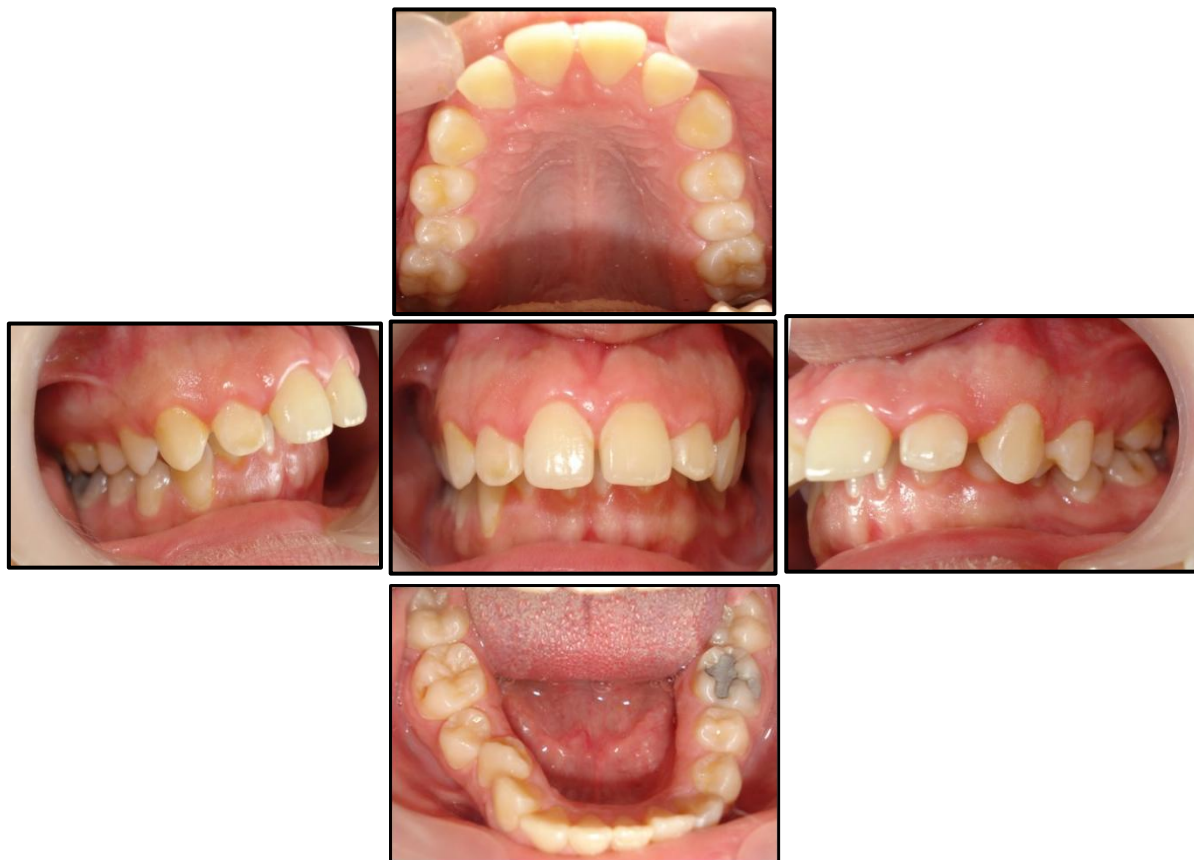

Figure 1: Example of one of the cases enrolled in the study.

Study design

This study was designed as a randomized clinical trial. The sample was randomly allocated into three equal groups. Randomization ensures that the variables will not systematically affect the results of the study. The randomization was performed using the random sequence generator (www.random.org) to generate three columns of random sequence. The blind allocation was performed by closed envelopes to allocate the sample subjects into their respective group.

Group I: Study group with Anterior retraction hook (ARH) of 9 mm.

Group II: Study group with ARH of 6 mm.

Group III: Study group with ARH of 3 mm.

The patients were fitted with straight wire braces 0.022 X 0.028 inch with Roth prescriptions (Mini diamond series, Ormco Corporation, USA). All patients underwent extraction of upper first premolars according to their treatment plan. Some patients required extraction of mandibular premolars to level curve of Spee or to relieve crowding.

Initial alignment and leveling was performed with the wire sequence 0.014, 0.016 inch nickel titanium wires followed by 0.018 inch stainless steel wires, followed by 0.016 X 0.022 inch nickel titanium wires and 0.016 X 0.022 inch stainless steel wires. The regular appointment interval was every 4-5 weeks. Emergency visits were scheduled in case of broken bracket or loose bands. The first phase of leveling and alignment ranged between 5 to 6 months.

After initial leveling and alignment, 0.017X0.025 inch stainless steel wires were

fitted for at least 4 weeks to ensure passivity of the arch wire.

Mini-implants placement

Peri-apical X-rays were taken before scheduling the patient for mini-implant placement appointment. Available space was checked between the first molar and second premolar. If no adequate space was available gabbling bend was performed in the 0.016X0.022 inch St. St wire to diverge the roots to create enough space and the wire was refitted for another 4 to 5 weeks and another set of peri-apical X-rays were taken until adequate space had been created between the first permanent molar and second permanent premolar.

The site of the implant was chosen to be between the second premolar and first molar at the level of muco-gingival junction. To standardize the position of mini-implants in all cases to compensate for any effect of its variation in position on the forces and moments during en-masse retraction, the mini-implant was set to be placed at 7 mm apically measured from the archwire. This distance was considered to be suitable in terms of adequacy of space between the roots and corresponding to the thickness of the attached gingiva. The site was lightly anaesthetized with infiltration anesthesia. The area was disinfected with betadine swab. Pinpoint bleeding point was prepared by sharp instrument (periodontal probe). Self -drilling mini-implants with length 10 mm and diameter 1.6 mm standard type (Perfect Anchor) were used. Hand driver was used to place the mini-implants. (Figure 2)

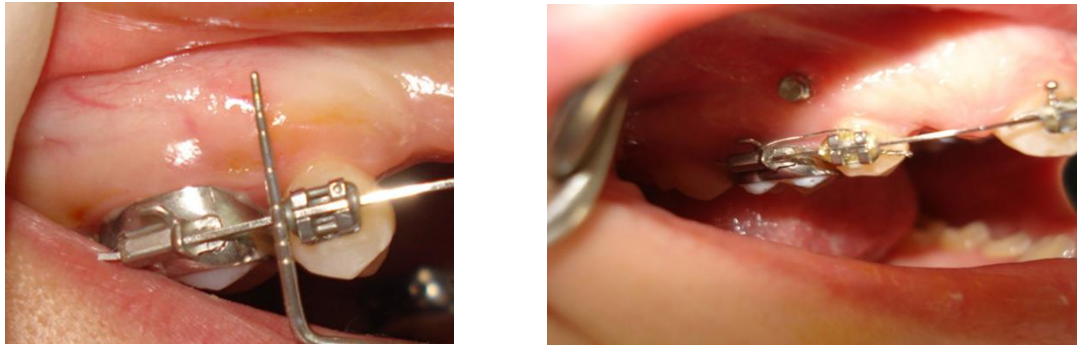

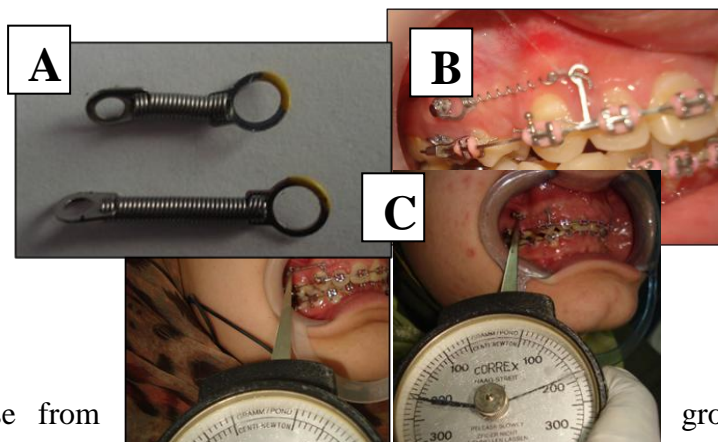
Figure 2: Site of mini-implant measured and placed.

For all groups, crimpable hooks with their assigned length (Figure 3) were used distal to the maxillary lateral incisor. The maxillary six anterior teeth were ligated with 0.011-inch St. St. Liagture wire prior to en masse retraction. Retraction force was be achieved by NiTi closed coil springs (Figure 3) stretched between the crimpable hooks and directly connected to the TAD placed between the upper second premolar and first molar. Different lengths of readymade NiTi coil springs (8mm and 13 mm) with different force

grades (light, medium, and heavy) with eyelet 1.5 – 2.5 were tried till the desired force was achieved. Force was adjusted with a Correx tension gauge. (Figure 4) The gauge was adjusted to produce 200 gm of force per side. The NiTi closed coil spring was activated every 28 days by re-activating the spring tension. Following the required amount of en masse retraction had been achieved, finishing and detailing by 0.017 X 0.025 inch St. St, wires was performed.



Figure 3: Different lengths of AFH used in the study.



Only one case from

group 2 failed to finish the

Figure 4: A; Ready made NiTi coil springs used, B; Intraoral setting of the en-masse retraction, C; Amount of force measured by Correx tension gauge.

study due to travelling for education. Cone beam computed tomography (Soredex Scanora 3D, medium FOV 75 X 100 with voxel size 0.2 mm) were taken at two-time intervals for the whole sample:

- T1: Before the onset of en-masse retraction.
- T2: After the completion of en-masse retraction.

The anterior nasal spine (ANS) and the posterior nasal spine (PNS) were marked on the midsagittal slice, the palatal plane was rotated until it became parallel to the axial plane. Also the axial slice corresponding to the palatal plane was identified and the image rotated, until the line joining the ANS and PNS was parallel to the sagittal plane. (Figure 5)

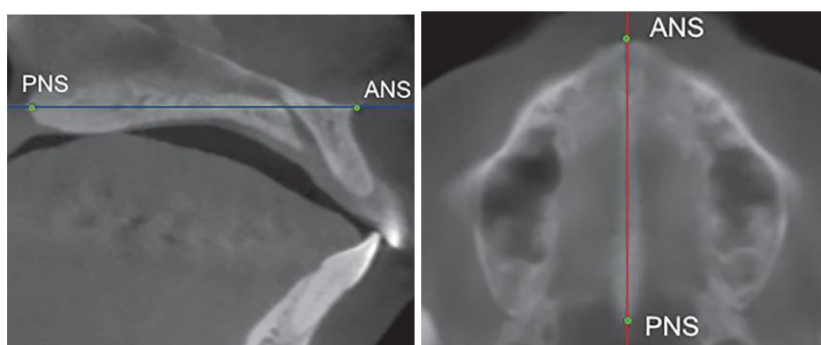


Figure 5: Orientation of palatal plane with the axial plane prior to measurements.

The measurements were recorded in the axial plane following orientation after selecting the appropriate tooth. (Figure 6)

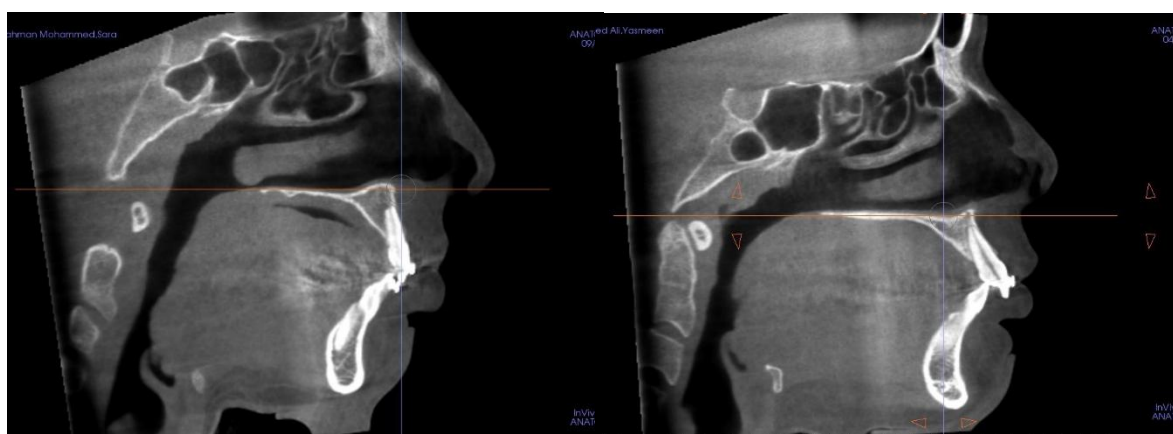


Figure 6: Example of CBCT axial slice ready for measurements.

Reference lines:

Upper central incisor long axis (R and L)
Line connecting incisal edge and root apex of the upper central incisor.

Upper lateral incisor long axis (R and L)
Line connecting incisal edge and root apex of the upper lateral incisor.

Upper canine long axis (R and L) Line connecting cusp tip and root apex of the upper canine.

Palatal plane (PP) Plane defined by two landmarks: ANS and PNS points and perpendicular on the midsagittal plane.

S vertical plane (S Ver) Plane: through Sella and perpendicular to the Frankfort horizontal plane and midsagittal planes.

Frankfurt horizontal plane (FHP) Plane defined by 3 landmarks: right orbitale, right porion and left porion.

Measurements:

Coronal retraction CR: Linear perpendicular distance from incisal edge or cusp tip to S-vertical plane, measured for the upper central and lateral incisors, and canine (right and left).

Root retraction RR Linear perpendicular distance from root apex to S-vertical plane, measured for the upper central and lateral incisors, and canine (right and left).

Vertical movement V Linear perpendicular distance from incisal edge or cusp tip to palatal plane, measured for the upper central and lateral incisors, and canine (right and left).

Labio-lingual inclination inc For the central and lateral incisors:

The angle formed between the long axis of the incisor and the palatal plane.

Measurement Error

The measurements reproducibility was assessed by analyzing the differences between two measurements taken one week apart. The whole reconstruction and orientation of CBCT was repeated for the double measurement. Amount of permissible error was set at 1 degree for the angular measurements and 0.5 mm for linear ones. If the second measurement was within the permissible error the average was taken.

Results

The mean starting chronological age was 19.23 years. (17.25-21.83)

Regarding duration of en-masse retraction in the three groups, table 1 shows the average duration for all groups with no significant difference between them.

Table 1: Mean duration for en masse retraction between three groups.

Measurement	Group 1	Group 2	Group 3	P value
Duration of retraction in months(mean +/- SD)	11.23 +/- 2.72	11.93 +/- 2.15	12.2 +/- 2.32	1&2 =0.632 2&3=0.83 1&3=0.52

Normality was checked for all variables using descriptive statistics, plots (histogram and boxplots), and normality tests. All variables showed normal distribution, so mean and standard deviation (SD) were calculated, and parametric analysis was adopted. Comparisons between the three study groups were done using one-way ANOVA followed by multiple pairwise comparisons using Bonferroni adjusted significance levels for statistically significant differences. Comparisons between

T1 and T2 within each group were done using paired t-test. Significance was set at p value <0.05. Data were analyzed using IBM SPSS for Windows (Version 23.0)

Table 2 shows the difference in the labiolingual inclination between the three groups at T1 and T2 for maxillary central and lateral incisors and canine. Significant reduction in the inclination as measured to the palatal plane had been recorded in three groups.

Table 2: Labio-lingual inclination (angle formed between the long axis of the tooth and palatal plane) in the three study groups

		Group 1 (n=5)	Group 2 (n=5)	Group 3 (n=5)	One-way ANOVA P value
		Mean \pm SD			
T1	Central	118.35 \pm 0.94	119.44 \pm 0.56	118.28 \pm 0.74	0.05
	Lateral	118.55 \pm 0.92	119.42 \pm 0.36	118.28 \pm 0.88	0.08
	Canine	117.88 \pm 0.92 a	119.22 \pm 0.33 b	118.32 \pm 0.80 a,b	0.03*
	Average of 3 teeth	118.26 \pm 0.91	119.36 \pm 0.41	118.29 \pm 0.80	0.054
T2	Central	114.30 \pm 1.25 a	112.90 \pm 0.63 a,b	111.70 \pm 0.83 b	0.001*
	Lateral	114.38 \pm 1.25 a	113.56 \pm 0.83 a	111.17 \pm 0.66 b	<0.001*
	Canine	114.85 \pm 1.04	114.94 \pm 0.36	113.73 \pm 0.86	0.05
	Average of 3 teeth	114.51 \pm 1.15 a	113.80 \pm 0.43 a	112.20 \pm 0.47 b	<0.001*
Mean difference (T2-T1)	Central	-4.05 \pm 0.69 a	-6.54 \pm 0.63 b	-6.58 \pm 1.22 b	<0.001*
	Lateral	-4.17 \pm 0.88 a	-5.86 \pm 0.57 b	-7.12 \pm 1.23 b	<0.001*
	Canine	-3.03 \pm 1.03 a	-4.28 \pm 0.44 a,b	-4.58 \pm 0.80 b	0.01*
	Average of 3 teeth	-3.75 \pm 0.82 a	-5.56 \pm 0.24 b	-6.09 \pm 0.94 b	<0.001*
Paired t-test P value (T2 vs. T1)	Central	<0.001*	<0.001*	<0.001*	
	Lateral	<0.001*	<0.001*	<0.001*	
	Canine	0.001*	<0.001*	<0.001*	
	Average of 3 teeth	<0.001*	<0.001*	<0.001*	

*statistically significant at p value <0.05

a,b different letters denote statistically significant differences between groups using Bonferroni adjusted significant levels.

Table 3 shows the comparison between the three groups regarding the amount of coronal retraction measured in mm. Significant

difference had been recorded between the three groups with more coronal retraction recorded in group 3 compared to group 1 and group 2.

Table 3: Coronal retraction (mm) in the three study groups.

		Group 1	Group 2	Group 3	One-way ANOVA
		Mean \pm SD			P value
T1	Central	78.47 \pm 1.86	79.82 \pm 0.95	78.85 \pm 0.84	0.26
	Lateral	77.58 \pm 2.51	79.66 \pm 0.73	78.33 \pm 0.75	0.14
	Canine	77.68 \pm 2.37	79.66 \pm 0.73	77.40 \pm 0.61	0.06
	Average of 3 teeth	77.91 \pm 2.20	79.71 \pm 0.75	78.19 \pm 0.66	0.12
T2	Central	73.97 \pm 1.95 a	73.00 \pm 0.81 a,b	71.40 \pm 0.69 b	0.01*
	Lateral	73.10 \pm 2.54	73.34 \pm 0.68	71.63 \pm 0.55	0.18
	Canine	72.20 \pm 2.53 a,b	73.96 \pm 0.50 a	70.98 \pm 0.67 b	0.03*
	Average of 3 teeth	73.09 \pm 2.26	73.43 \pm 0.53	71.34 \pm 0.46	0.053
Mean difference (T2-T1)	Central	-4.50 \pm 0.39 a	-6.82 \pm 0.69 b	-7.45 \pm 0.34 b	<0.001*
	Lateral	-4.48 \pm 0.27 a	-6.32 \pm 0.50 b	-6.80 \pm 0.50 b	<0.001*
	Canine	-5.48 \pm 0.35 a	-5.70 \pm 0.47 a,b	-6.42 \pm 0.65 b	0.02*
	Average of 3 teeth	-4.82 \pm 0.13 a	-6.28 \pm 0.27 b	-6.68 \pm 0.37 b	<0.001*
Paired t-test P value (T2 vs. T1)	Central	<0.001*	<0.001*	<0.001*	
	Lateral	<0.001*	<0.001*	<0.001*	
	canine	<0.001*	<0.001*	<0.001*	
	Average of 3 teeth	<0.001*	<0.001*	<0.001*	

*statistically significant at p value <0.05
a,b different letters denote statistically significant differences between groups using Bonferroni adjusted significant levels.
Table 4 shows the comparison between three groups in the maxillary anterior teeth regarding

the amount of root retraction. Significant retraction of root had been recorded in all teeth in all groups. Significantly lower amount of root movement had been recorded in group 2 and 3 compared to group 1.

Table 4: Root retraction (mm) in the three study groups

		Group 1	Group 2	Group 3	One-way ANOVA P value
		Mean ± SD			
T1	Central	77.32 ± 1.78	79.16 ± 0.81	77.58 ± 1.12	0.08
	Lateral	77.17 ± 2.59	79.18 ± 0.81	76.85 ± 0.69	0.08
	Canine	76.58 ± 2.21	78.60 ± 0.96	77.02 ± 0.51	0.09
	Average of 3 teeth	77.02 ± 2.15	78.98 ± 0.81	77.15 ± 0.69	0.07
T2	Central	73.85 ± 1.51 a	76.66 ± 0.40 b	75.02 ± 0.96 a,b	0.003*
	Lateral	73.40 ± 1.86 a	76.50 ± 0.68 b	74.83 ± 0.54 a,b	0.003*
	Canine	73.15 ± 1.22 a	75.68 ± 0.83 b	75.13 ± 0.65 b	0.001*
	Average of 3 teeth	73.47 ± 1.43 a	76.28 ± 0.51 b	74.99 ± 0.66 a,b	0.001*
Mean difference (T2-T1)	Central	-3.47 ± 0.50 a	-2.50 ± 1.05 b	-2.57 ± 0.25 b	0.04*
	Lateral	-3.77 ± 1.15 a	-2.68 ± 0.49 a,b	-2.02 ± 0.78 b	0.01*
	Canine	-3.43 ± 1.14 a	-2.92 ± 0.20 a,b	-1.88 ± 0.36 b	0.008*
	Average of 3 teeth	-3.55 ± 0.80 a	-2.70 ± 0.46 a,b	-2.15 ± 0.38 b	0.003*
Paired t-test P value (T2 vs. T1)	Central	<0.001*	0.006*	<0.001*	
	Lateral	<0.001*	<0.001*	0.001*	
	Canine	0.001*	<0.001*	<0.001*	
	Average of 3 teeth	<0.001*	<0.001*	<0.001*	

*statistically significant at p value <0.05

a,b different letters denote statistically significant differences between groups using Bonferroni adjusted significant levels

Table 5 shows the amount of vertical change in the maxillary anterior teeth in three groups. All groups showed significant intrusive movement

with significantly less intrusion movement in group 2 and group 3 compared to group 1. Group1 showed more intrusive movement with an average of 2.52 mm intrusion. Both group 2 and 3 showed intrusive movement of maxillary anterior teeth with an average of 1.14 and 1.36 mm respectively.

Table 5: Vertical movement (mm) in the three study groups

		Group 1	Group 2	Group 3	One-way ANOVA P value
		Mean ± SD			
T1	Central	32.45 ± 0.87	32.28 ± 0.93	33.15 ± 0.90	0.25
	Lateral	31.90 ± 0.76 a	33.48 ± 0.38 b	33.27 ± 1.04 b	0.009*
	Canine	32.88 ± 0.84	32.68 ± 0.68	33.55 ± 0.90	0.21
	Average of 3 teeth	32.41 ± 0.72	32.81 ± 0.30	33.32 ± 0.76	0.08
T2	Central	30.15 ± 1.08 a	30.94 ± 1.50 a	34.25 ± 1.00 b	<0.001*
	Lateral	29.23 ± 0.82 a	32.26 ± 0.60 b	34.60 ± 1.08 c	<0.001*
	Canine	30.28 ± 0.98 a	31.82 ± 0.65 b	35.20 ± 0.82 c	<0.001*
	Average of 3 teeth	29.89 ± 0.75 a	31.67 ± 0.52 b	34.68 ± 0.76 c	<0.001*

Mean difference (T2-T1)	Central	-2.30 ± 0.46 a	-1.34 ± 0.58 b	1.10 ± 0.39 c	<0.001*
	Lateral	-2.67 ± 0.16 a	-1.22 ± 0.28 b	1.33 ± 0.42 c	<0.001*
	Canine	-2.60 ± 0.24 a	-0.86 ± 0.05 b	1.65 ± 0.57 c	<0.001*
	Average of 3 teeth	-2.52 ± 0.13 a	-1.14 ± 0.27 b	1.36 ± 0.39 c	<0.001*
Paired t-test P value (T2 vs. T1)	Central	<0.001*	0.007*	0.001*	
	Lateral	<0.001*	0.001*	0.001*	
	canine	<0.001*	<0.001*	0.001*	
	Average of 3 teeth	<0.001*	0.001*	<0.001*	

*statistically significant at p value <0.05

a,b,c different letters denote statistically significant differences between groups using Bonferroni adjusted significant levels

Discussion

En masse retraction can be undertaken using either continuous or segmented arch mechanics. It was reported that conventional methods of en masse retraction using sliding mechanics result in extrusion of maxillary incisors and clockwise rotation of the occlusal plane. Thus, these techniques are not indicated in cases with vertical maxillary excess or gummy smile.⁽⁹⁾

Melsen et al.⁽⁹⁾ assumed that the center of resistance (CR) of maxillary anterior teeth lied 13.5 mm posteriorly and 9 mm superiorly to the center of the arch wire. Thus, true translational movement of teeth will occur if the force vector passes through CR. Others^(12,13) assumed that the center of resistance of maxillary anterior teeth to be 13.5 mm apical and 14 mm posterior to the incisal edge of central incisors.

From a biomechanical perspective, the type of tooth movement depends on the relationship between the line of force application and the location of the center of resistance of the tooth.⁽¹⁴⁾ In sliding mechanics, the height of the power arm affects the type of anterior tooth movement, so different types of tooth movements can be designed by attaching various lengths of power arms onto an archwire.⁽¹⁵⁾

Thus, alteration of the position of the TAD or the height of the retraction hook can affect type of the tooth movement. Changing the height of mini-implant is usually not feasible as we are confined within the limitation of the available

soft tissue which is limited in the posterior region. Therefore, altering the length of ARH is the more convenient and more readily applicable to change the direction of force. On the other hand, Chetan et al⁽¹⁶⁾ found that changing the TAD position vertically had very little effect on the type of tooth movement. Similarly, Bohara et al⁽¹⁷⁾ found that irrespective of the TAD position if the force passes away from the center of resistance (CR) tipping will occur.

In this study, the position of the mini-implant was standardized at 7mm measured from the archwire level. The sample was confined for females to limit sex differences that might affect the results. The selection of the age range between 16 and 22 years relied on the assumption that by the onset of menstruation, the majority of the growth is complete. Also, selection of 16 years as a minimum age limit was to ensure complete root closure of canines. In this study, the experimental site was restricted to the upper arch because of the difference in elastic property and apparent density between the mandible and the maxilla that affect the type of orthodontic tooth movement.^(18,19)

Three lengths of retraction hook (3, 6, 9 mm) crimped on main archwire distal to lateral incisors were used in this study.

The results of this study suggest that uncontrolled tipping with 3, and 6 mm of the power arm occurred with more significant uncontrolled tipping with ARH of 3 mm. This can be explained by the fact that the force

passed inferior to the center of resistance of the anterior teeth. Obviously, the clockwise moment on the anterior teeth decreases with longer power arms. These findings are in agreement with those of the finite element study done by Kojima et al. ⁽²⁰⁾ as they found that tipping of anterior teeth decreased with longer power arms.

Similar results were reached by Hedayati et al ⁽⁵⁾ who found that longer power arms resulted in less tipping and 9 mm arms led to bodily movement. During en masse retraction with 9 mm arms, bodily movement occurred due to the total force passing close to the center of resistance of the anterior teeth. ⁽²¹⁾

The current study showed intrusive movement of maxillary anterior teeth during en masse retraction in all three groups with significantly more intrusive movement with ARH of 9 mm. This can be attributed to the length of retraction hook and the relation of the line of action to the mini-implant causing anticlockwise rotation of the anterior dentition. On the other hand, less intrusion reported in other groups due to shorter length of retraction hook compared to mini-implant position. These results doesn't coincide with finite element study of Hedayati⁽⁵⁾ who reported Slight extrusion happened when applying force to the 9-mm power arm.

Similar results were reached by Cetan et al ⁽²²⁾ who reported in their 3D finite element study that intrusive force of anterior teeth increases with apical displacement of the mini-implant. Intrusive forces were explained by Upadhyay and Nanda ⁽²³⁾ by the fact that during the retraction phase, the vertical component of the total force constantly increases as the angle between the applied force and the occlusal plane increases.

This vertical component of force can increase the binding or friction of the archwire to the braces and tubes, hindering sliding and causing the transmission of the vertical force to the whole arch wire. Subsequently, these patients showed intrusion of the entire arch.

As a result, orthodontic patients with discrepancies in the sagittal and vertical planes that necessitates the removal of 1st premolars, need careful planning of TADS location and

arm heights to fulfill the patient's needs, as regards esthetic, and function, it is those needs that enable us to develop a patient oriented treatment plan.

Conclusions

- 1. According to the available literature, bodily movement can be achieved during en masse retraction when the force vector passes through CR.**
- 2. Increasing length of ARH decrease amount of uncontrolled tipping during en masse retraction with more intrusive effect on the anterior teeth.**
- 3. Proper setting of the height of ARH together with height of the mini-implant to achieve coincided force vector through CR results in more predictable tooth movement during en masse retraction.**

References

- Baumrind S, Korn EL, Boyd RL, Maxwell R. The decision to extract: part II. Analysis of clinicians' stated reasons for extraction. *Am J Orthod Dentofac Orthop* 1996; 109:393-402.
- Bennett JC, McLaughlin RP. Controlled space closure with a pre-adjusted appliance system. *J Clin Orthod* 1990; 24:251-60.
- Tominaga JY, Tanaka M, Koga Y, Gonzales C, Kobayashi M, Yoshida N. Optimal Loading Conditions for Controlled Movement of Anterior Teeth in Sliding Mechanics. *Angle Orthod.* 2009; 79:1102-1107.
- Sung S, Jang GW, Chun YS, Moon YS. Effective en-masse retraction design with orthodontic mini-implant anchorage: A finite element analysis. *Am J Orthod Dentofac Orthop* 2010; 137:648-57.
- Hedayati Z, Shomali M. Maxillary anterior en masse retraction using different antero-posterior position of mini screw: A 3D finite element study. *Prog Orthod.* 2016;17(1):31. doi:10.1186/s40510-016-0143-z.

6. Zhang DQ, Su JH, Xu LY, Zhong PP. 3D finite element study of en masse retraction of maxillary anterior teeth in two typical force directions. *Chin J Dental Res.* 2008;11:101-107.
7. Ashish Agrawal, P Subash. The Effect of Varied Positioning of Miniscrew, Anterior Retraction Hook, and Resultant Force Vector on Efficient En- Masse Retraction Using Finite Element Method: A Systematic Review. *Journal of Indian Orthodontic Society* 55(1) 11–21, 2021.
8. Pedersen E, Isidor F, Gjessing P, Andersen K. Location of centers of resistance for maxillary anterior teeth measured on human autopsy material. *Eur J Orthod* 1991; 13:452-8.
9. Melsen B, Fotis V, Burstone CJ. Vertical force considerations in differential space closure. *J Clin Orthod* 1990; 24:678-83.
10. Paolo M Cattaneo, Michel Dalstra, Birte Melsen. The Finite Element Method: A Tool to Study Orthodontic Tooth Movement June 2005 *Journal of Dental Research* 84(5):428-33.
11. Muhlemann HR, Son S. Gingival Bleeding: A leading symptom in initial gingivitis. *Helvetica odontologica acta* 1971; 15:107-113.
12. Park H-S, Kwon O-W, Sung J-H. Microscrew implant anchorage sliding mechanics. *World J Orthod.* 2005;6(3):265–74.
13. Jeong G-M, Sung S-J, Lee K-J, Chun Y-S, Mo S-S. Finite-element investigation of the center of resistance of the maxillary dentition. *Korean J Orthod.* 2009;39(2):83–94.
14. Smith RJ, Burstone CJ. Mechanics of tooth movement. *Am J Orthod.* 1984;85:294–307., Vanden Bulcke MM, Burstone CJ, Sachdeva RC, Dermaut LR. Location of the centers of resistance for anterior teeth using the laser reflection technique. *Am J Orthod Dentofacial Orthop.* 1987;91:375–384.)
15. Jayade VP, Annigeri S, Jayade C, Thawani P. Biomechanics of torque from twisted archwires. *Angle Orthod.* 2007;77:214-20.
16. Shankar C, Keluskar K, Vasisht V, Revankar S. En-masse retraction of the maxillary anterior teeth by applying force from four different levels—A finite element study. *J Clin Diagn Res.* 2014;8:ZC26-ZC30. doi:10.7860/JCDR/2014/8408.4831.
17. Bohara P, Kumar M, Sharma H, Jayprakash PK, Misra V, Savana K. Stress distribution and displacement of maxillary anterior teeth during En-masse intrusion and retraction: A FEM study. *J Indian Orthod Soc.* 2017;51:152. doi:10.4103/jios.jios_199_16
18. Seong WJ, Kim UK, Swift JQ, Heo YC, Hodges JS, Ko CC. Elastic properties and apparent density of human edentulous maxilla and mandible. *Int J Oral Maxillofac Surg* 2009; 38:1088-93.
19. Bridges T, King G, Mohammed A. The effect of age on tooth movement and mineral density in the alveolar tissues of the rat. *Am J Orthod Dentofac Orthop* 1988; 93:245-50.
20. Kojima Y, Kawamura J, Fukui H. Finite element analysis of the effect of force directions on tooth movement in extraction space closure with miniscrew sliding mechanics. *Am J Orthod Dentofacial Orthoped.* 2012;142(4):501–8.
21. Lee K-J, Park Y-C, Hwang C-J, Kim Y-J, Choi T-H, Yoo H-M, et al. Displacement pattern of the maxillary arch depending on miniscrew position in sliding mechanics. *Am J Orthod Dentofacial Orthoped.* 2011; 140(2):224–32.
22. Chetan.S, Kanhoba M Keluskar, Vikram N Vasisht, Siddharth Revankar. En-masse Retraction of the Maxillary Anterior Teeth by Applying Force from Four Different Levels –A Finite Element Study. *Journal of Clinical and Diagnostic Research* • September 2014 DOI:10.7860/JCDR/2014/8408.4831 .
23. Madhur Upadhyay, Sumit Yadav, and Ravindra Nanda. Vertical-dimension control during en-masse retraction with mini-implant anchorage. *Am J Orthod Dentofacial Orthop* 2010;138:96-108.