



Treatment Effect of Oregano Essential Oil in Broiler Chickens Experimentally Infected with Avian Pathogenic *Escherichia coli* O27 with Emphasis on Hemogram, Serum Biochemistry, and Histopathology of Vital Organs



Waleed Abu El Hammed^{a*}, Hamdy Soufy^a, A. EL-Shemy^a, Soad M. Nasr^a and Mohamed I. Dessouky^b

^a Department of Parasitology and Animal Diseases, National Research Centre, 33 Bohouth Street, Dokki, Giza, 12622, Egypt.

^b Department of Clinical Pathology, Faculty of Veterinary Medicine, Cairo University, Giza, 12211, Egypt.

Abstract

This study aimed to evaluate the efficacy of oregano oil 20% for the treatment of broiler chickens experimentally infected with avian pathogenic *Escherichia coli* O27 (APECO27) -local isolate. Hemogram, biochemical constituents, and histopathology of the internal organs were assessed. Two hundred chicks -19-days-old- were randomly assigned to four equal groups; G1 (normal control), G2 (Infected), G3 (oregano treated), and G4 (antibiotic treated). At the 19th, 20th, and 21st day of age, G2, G3, and G4 were intratracheally infected with 0.2ml of APECO27 (1×10^7 CFU/chick). On the 22nd, 23rd, and 24th day of age, G3 & G4 were treated with oregano 20% (2ml/5liters) and difloxacin (10mg/kg b.wt.) in drinking water, respectively. On the 3rd, 6th, 10th, and 21st day post-infection, blood and tissue samples were collected for laboratory investigations of the hemogram, serum biochemistry, and histopathology of the internal organs. Infected non-treated G2 chicks showed dullness, ruffled feathers, gasping and loss of appetite, while infected-treated G3 & G4 birds showed mild symptoms. The mortality rate was 30%, 8% and 4% in G2, G4 and G3, respectively. Chicks of G2 & G4 developed macrocytic hypochromic anemia, leukocytosis, heterophilia, and lymphopenia. Values of ALT, AST, creatinine, and uric acid were increased while protein profile was decreased. After oregano treatment, alterations were returned to normal levels. Histopathologically, chicks of G2 & G4 showed alterations in the internal organs. Finally, APECO27 caused alterations in hematology and serum biochemistry, and histopathology of the internal organs. Oregano could be used as antibiotic for the treatment of APECO27.

Keywords: Avian pathogenic *E. coli* O27; oregano oil 20%; hemogram; serum biochemistry; pathology, chickens.

1. Introduction

Avian colibacillosis caused by avian pathogenic *Escherichia coli* (APEC), is one of the most significant and widespread infectious diseases occurring in production birds. It is responsible for large financial losses for the poultry industry in Egypt and worldwide every year due to mortality, lost production, and condemnations [1]. Diagnosis of avian colibacillosis is primarily based on the clinical signs and characteristic lesions at necropsy, such as airsacculitis, perihepatitis, and pericarditis. If colibacillosis is suspected, isolation and identification of the pathogen is recommended [2]. The recorded *E. coli* serotypes are more than 1,000 but fewer have been implicated in poultry diseases, the most prevalent serotypes were O115, O142, O158, O55, O125, O114, O27, O20, and O15. Awad et al. [3] reported that by application of polymerase chain reaction (PCR), 83.3% (15/18) of the serotyped

isolates were confirmed to be *E. coli*, of which 93.3% (14/15), 46.6% (7/15), and 20% (3/15) of isolates harbored the *iss*, *iutA*, and *fimH* genes, respectively. These strains have specific virulence factors contributing to their ability to cause diseases in birds. Infections by these strains are mostly extra intestinal, with a majority being the cause of acute lung injury due to disruption of the lung endothelial and epithelial barriers.

Commercial antibiotics' nontherapeutic usage could cause tolerance or resistance in humans and animals. So, a worldwide ban has been forced on the usage of antibiotics in order to decrease antibiotic-resistant bacterial traits in poultry [4]. Oregano (*Origanum vulgare* L.), is a common species of genus *origanum*, Family Lamiaceae. Oregano essential oil is an aromatic herbal product that has been used as a growth promoter in the poultry farms [5]. Phenolic

*Corresponding author e-mail: drwaleedaboelhamed@gmail.com; (Waleed Abu El Hammed).

Receive Date: 15 July 2021, Revise Date: 31 July 2021, Accept Date: 02 August 2021

DOI: 10.21608/EJCHEM.2021.86333.4181

©2021 National Information and Documentation Center (NIDOC)

compounds such as carvacrol and thymol and their pre-cursors p-cymene and γ -terpinene constitute about 78 to 82% of the total Oregano's volatile compounds. Such compounds have been demonstrated to have synergistic/additive effects, such as antiviral and antifungal properties [6,7], acaricidal activity [8], antimicrobial activities [9-13], and antioxidant [14,15] properties. Also, carvacrol-rich oregano oil has high antibiofilm and antivirulence activities against uropathogenic *E. coli* [16]. The antimicrobial activity of oregano essential oil has been explored in many *in vitro* assays which showed that carvacrol, thymol, and eugenol have high antimicrobial activity against pathogenic bacteria such as *E. coli* and *Salmonella typhimurium* which are potential risk factors of enteric infections [17]. Oregano could be a viable alternative to antibiotic growth promoters provided that there are no negative effects on the birds' health and the efficiency of controlling the pathogen load in the gastrointestinal tract. M'Barek et al. [18] on the other side mentioned that, carvacrol and other oregano compounds can be cytotoxic at high doses indicating the need for optimizing the concentration of oregano in feed to achieve maximum positive effects without cytotoxic effects.

It has been reported that chicken infected with *E. coli* revealed pancytopenia [19] and elevation of the activities of serum enzymes AST and ALT and values of serum uric acid, creatinine and globulin with decrease of serum protein and albumin [20]. Therefore, this work aimed to evaluate efficacy of oregano essential oil 20% for treatment of chicks experimentally infected with Avian Pathogenic *E. coli* O27 (APEC O27) strain- local isolate-. Hematological, serum biochemical and histopathological changes in the vital organs (lungs, trachea, liver, spleen and kidneys) were utilized for assessment.

2. Material and Methods

2.1. Ethics statement

This experiment was conducted according to guidelines for animal experimentation and the protocol approved by the Institutional Animal Care and Use Committee, National Research Centre, Dokki, Giza, Egypt, the protocol approval No.: 1276072021.

2.2. Avian Pathogenic *Escherichia coli* O27 (APEC O27)

Avian pathogenic *E. coli* serotype O27 –local isolate from lungs of broiler chickens- was used in this experimental infection. The APEC O27 was identified at Animal Health Research Institute, Dokki, Giza, Egypt. The result revealed that APEC O27 was highly

pathogenic. The antibacterial sensitivity test for oregano oil has been determined at the concentration of 20% according to the antibacterial sensitivity test that has been done before using the method of Quinn et al. [21].

2.3. Oregano essential oil 20%

Oregano solution 20% (Ropadiar[®]) is derived from Oregano (*Origanum vulgare* L.), family Lamiaceae. It was purchased from ROPA Pharm International Co., Netherlands. It contains more than 60 active compounds. Carvacrol (62 – 68%), thymol (1 – 3 %), and p-cymene (~ 8%) are the major active components present in the *Origanum vulgare* essential oil. According to the manufacturer's instructions, oregano 20% was orally administered at a dose of 2 ml /5 liters in drinking water.

2.4. Antibacterial drug used

According to antibacterial sensitivity test, Difloxacin was the most sensitive antibacterial against APEC serotype O27. Diflobiotic[®] active principle is difloxacin. Each 1 ml contains Difloxacin hydrochloride 109.13 mg (equivalent to 100 mg Difloxacin base). Diflobiotic[®] was orally administered in drinking water at a dose of 10 mg/kg b.wt. of chicken according to the manufacturer's instructions. It was purchased from Atco Pharm Co., Egypt.

2.5. Chicks

A total number of 200 -one day old- chicks (Cobb 500) purchased from El-Wattania Co. were used in this experiment. Before the beginning of the experiment, five chicks were sacrificed randomly, and samples from liver, kidney, lungs, and trachea were examined bacteriologically for pathogenic *E. coli*. All the results were *E. coli* negative. These chicks were put under the required hygienic conditions, fed on a balanced commercial diet according to NRC [22], and supplied with clean water in sufficient quantities. The experimental chicks were subjected to traditional vaccine program for different viral diseases (Avian influenza, Newcastle, infectious bronchitis and infectious bursal disease) until the end of the experimental period.

2.6. Experimental design

Experimental chicks were assigned to 4 equal groups, 50 chicks each (G1-G4). Chicks in G1 were used as normal control (non infected non treated). At the 19th, 20th and 21st day of age, chickens of G2, G3 and G4 were infected with local isolate APEC O27 via intra tracheal route at a dose of 0.2 ml of bacterial suspension in saline containing 1×10^7 CFU/Chick according to the method of Rosenberger et al. [23]. At

the 22nd, 23rd and 24th day of age, chickens of G3 (Oregano treated) and G4 (Antibiotic treated) were treated orally in drinking water with oregano 20% at a dose of 2 ml / 5 liter and Diflobiotic at a dose of 10 mg/kg b.wt., respectively. In all groups, clinical signs and mortality rate were recorded during the period of experiment. At the 3rd, 6th, 10th, and 21st day post-infection (dpi), reisolation of APEC O27 from the lung, trachea, and liver was performed, as well as blood and tissue samples were collected from 5 chickens in each group.

2.7. Reisolation of APEC O27 serotype

At the 3rd, 6th, 10th, and 21st dpi, samples from lung, trachea, and liver were taken under aseptic condition and incubated over night at 37°C in nutrient broth then loopfulls from inoculated broth were streaked on MacConkey's agar medium and Eosin Methylene Blue agar (Oxoid). The inoculated media were incubated at 37°C for 24–48h. *E. coli* colonies appeared pink colonies on MacConkey's agar and shiny metallic green colonies on Eosin Methylene Blue agar [24].

2.8. Blood and tissue sampling

At the 3rd, 6th, 10th, and 21st dpi, blood and tissue samples were collected from all the experimental groups. Blood samples were collected from the wing vein of each bird and were divided into two portions. The first portion was collected into sterile tubes containing EDTA anticoagulant (Ethylene diamine tetra acetic acid) and used for evaluation of hematological investigations. The second portion was placed into a plain vacutainer tube, left to clot then centrifuged at 3000 rpm for 15 min. for separation of serum. Sera were stored at -20°C until used for biochemical analyses. Tissue specimens were collected from the lungs, trachea, liver, spleen, and kidneys of each bird for histopathological examination.

2.9.1. Hematological examination

Complete blood picture consisted of erythrogram [red blood cell counts (RBCs), hemoglobin (Hb), packed cell volume (PCV), mean corpuscular volume (MCV), mean corpuscular hemoglobin (MCH) and mean corpuscular hemoglobin concentration (MCHC)], leukogram [total and differential White blood cell counts] and thrombocytes count. It was investigated according to the method of Weiss and Wardrop [25] using Natt and Herrick's solution as a diluent [26].

2.9.2. Serum biochemical analysis

The activities of ALT and AST [27], and the levels of uric acid [28], creatinine [29], total proteins [30], and albumin [31] were determined spectrophotometrically (T80 UV/VIS PG instrument Ltd, UK) using commercial Test kits (Biodiagnostic Co., Egypt). Total globulins were calculated by subtracting the obtained value of albumin from the total proteins.

2.9.3. Histopathological examination

Tissue specimens were collected from the lungs, trachea, liver, spleen, and kidneys were immediately fixed in neutral buffered formalin 10%. Tissue specimens then were washed, dehydrated, cleared and embedded in paraffin. Paraffin blocks were sectioned at 4–5 µm thickness and stained with hematoxylin and eosin (H&E) according to Suvarna et al. [32]. Slides were examined under a light microscope (Olympus B x50, Japan).

2.10. Statistical analysis

All data were subjected to statistical analysis including the calculation of the mean ± standard error. Differences between the normal control and the treated groups were tested for significance using one-way analysis of variance (ANOVA) followed by Duncan's multiple range test. The differences were considered significant at $P < 0.05$ level [33] using Statistical Package for Social Sciences (SPSS) software version 20 computer program (SPSS Inc, Chicago, IL, USA).

3. Results

3.1. Clinical signs and mortality rate

Clinical signs appeared on infected birds (G2) were dullness, ruffled feather, gasping, loss of appetite and depression, while after treatment (birds of G3 & G4) showed mild symptoms. Mortality rates among experimental infected chicks of different groups were recorded in Table (1).

3.2. Reisolation of APEC O27

At the 3rd dpi, APEC O27 was isolated from the lungs of G3 and G4, while it was isolated from G2 at the 3rd, 6th, and 10th dpi.

Table 1. Mortality rate of chickens experimentally infected with avian pathogenic *E. coli* O27 during the experimental periods.

Groups	Chickens Number	Mortalities at different days post infection with <i>E. coli</i> serotype O27					Mortality rate (%)
		1-3	4-6	7-10	11-21	Total	
Normal control (G1)	50	0	0	0	0	0	0
Infected (G2)	50	3	6	4	2	15	30%
Oregano treated (G3)	50	2	0	0	0	2	4%
Antibacterial treated (G4)	50	2	1	1	0	4	8%

3.4. Hematological findings

3.4.1. Erythrogram

Erythrocytes' count and Hb concentration revealed significant ($P<0.05$) decrease in both infected (G2) and antibiotic treated (G4) groups at the 6th, 10th, and 21st dpi compared to normal control (G1) and oregano (G3). Values of PCV in infected chickens (G2) exhibited gradual decrease from the 3rd dpi till the 21st dpi which was significant ($P<0.05$) at the 6th and 10th dpi compared to the other treated groups. PCV values in the antibiotic treated (G4) birds revealed a marked ($P<0.05$) decrease at the 10th dpi only compared to both groups of normal control (G1) and oregano treated (G3). At the 6th, 10th and 21st dpi, MCV values indicated significant ($P<0.05$) increase while MCHC revealed marked ($P<0.05$) decrease in both groups of infected (G2) and antibiotic treated (G4) compared to the other groups (G1 & G3). MCH showed no significant changes in all groups during the experiment except at the 21st dpi only there was significant ($P<0.05$) increase in both infected and antibiotic groups. Evaluation of red cell indices revealed presence of macrocytic hypochromic type anemia in infected birds of G2 and antibiotic treated birds of G4. (Table 2)

3.4.2. Leukogram

Total WBCs and heterophil counts in both infected (G2) and antibiotic treated (G4) chicks were significantly ($P<0.05$) increased all over experimental period in comparison with the normal control (G1). Oregano treated chicks of (G3) revealed significant ($P<0.05$) increase in total WBCs and heterophils counts only at the 3rd, and 6th dpi. Chicks of G2 & G4 showed significant lymphopenia from the 3rd dpi till the end of the experiment in comparison with the other groups. Monocytes revealed significant ($P<0.05$) increase in infected (G2) and treated groups (G3 & G4) on the 6th and 21st dpi. Eosinophil count was significantly ($P<0.05$) increased in the infected group at the 6th and 21st dpi compared to the other groups. Basophils showed significant ($P<0.05$) increase in infected group (from the 3rd till the 21st dpi), and treated groups (at the 6th and 10th dpi). (Table 3)

3.4.3. Thrombocytes

Compared to control group (G1), chickens of the infected group (G2) revealed a significant decrease in thrombocyte count from the 6th dpi till the end of the experiment, while treated groups (G3&G4) thrombocytes count slightly decreased at the 10st dpi (Table 3).

Table 2. Erythrogram of chickens treated with oregano 20% after infection with avian pathogenic *E. coli* O27 during the different experimental periods (Mean \pm SE, N=5)

Parameters	Periods (dpi)	Groups			
		Normal Control (G1)	Infected (G2)	Oregano (20%) treated (G3)	Antibacterial treated (G4)
Red blood cell count ($\times 10^6/\mu\text{l}$)	0	2.01 \pm 0.03 ^a	1.97 \pm 0.04 ^a	2.08 \pm 0.12 ^a	1.99 \pm 0.08 ^a
	3	2.03 \pm 0.09 ^a	1.93 \pm 0.05 ^a	2.12 \pm 0.07 ^a	2.01 \pm 0.05 ^a
	6	2.11 \pm 0.05 ^a	1.88 \pm 0.01 ^b	2.04 \pm 0.06 ^a	1.91 \pm 0.04 ^b
	10	2.20 \pm 0.08 ^a	1.84 \pm 0.03 ^b	2.27 \pm 0.07 ^a	1.97 \pm 0.04 ^b
	21	2.34 \pm 0.05 ^b	2.03 \pm 0.03 ^d	2.51 \pm 0.06 ^a	2.19 \pm 0.05 ^c
Packed Cell volume (%)	0	27.80 \pm 0.26 ^a	28.22 \pm 0.18 ^a	27.84 \pm 0.24 ^a	28.16 \pm 0.34 ^a
	3	28.08 \pm 0.36 ^a	27.60 \pm 0.39 ^a	28.14 \pm 0.32 ^a	28.10 \pm 0.37 ^a
	6	28.44 \pm 0.09 ^a	27.28 \pm 0.12 ^b	28.14 \pm 0.17 ^a	27.94 \pm 0.27 ^a
	10	28.64 \pm 0.20 ^a	26.64 \pm 0.16 ^c	28.46 \pm 0.27 ^a	27.54 \pm 0.21 ^b
	21	28.12 \pm 0.33 ^a	27.62 \pm 0.16 ^a	28.52 \pm 0.29 ^a	27.96 \pm 0.11 ^a
Hemoglobin (g/dl)	0	9.00 \pm 0.07 ^a	9.16 \pm 0.13 ^a	9.18 \pm 0.09 ^a	9.16 \pm 0.11 ^a
	3	9.20 \pm 0.17 ^a	8.72 \pm 0.11 ^a	8.98 \pm 0.20 ^a	8.62 \pm 0.16 ^a
	6	9.10 \pm 0.14 ^a	7.94 \pm 0.12 ^b	9.28 \pm 0.16 ^a	7.86 \pm 0.10 ^b
	10	9.08 \pm 0.14 ^a	7.08 \pm 0.05 ^c	9.14 \pm 0.05 ^a	7.76 \pm 0.17 ^b

	21	9.04±0.13 ^a	8.28±0.12 ^b	9.40±0.10 ^a	8.56±0.13 ^b
Mean corpuscle volume (fl)	0	138.43±2.12 ^a	143.19±3.01 ^a	135.68±8.37 ^a	142.42±5.80 ^a
	3	139.24±6.95 ^a	143.54±3.96 ^a	133.31±2.61 ^a	140.43±4.08 ^a
	6	135.16±2.77 ^b	145.13±0.66 ^a	138.38±3.56 ^{ab}	146.80±2.81 ^a
	10	130.61±3.87 ^b	145.09±2.27 ^a	125.67±3.14 ^b	140.11±2.13 ^a
	21	120.42±3.22 ^c	136.16±1.53 ^a	113.95±1.52 ^c	127.76±2.34 ^b
Mean corpuscle hemoglobin (pg)	0	44.81±0.56 ^a	46.48±1.21 ^a	44.74±2.77 ^a	46.38±2.16 ^a
	3	45.63±2.39 ^a	44.39±1.53 ^a	42.51±0.88 ^a	43.10±1.54 ^a
	6	43.26±1.22 ^a	42.25±0.77 ^a	45.74±2.06 ^a	41.33±1.18 ^a
	10	41.45±1.61 ^a	38.59±0.92 ^a	40.40±1.35 ^a	39.52±1.30 ^a
	21	38.44±0.82 ^c	40.81±0.52 ^a	37.58±0.87 ^c	39.08±0.42 ^{ab}
Mean corpuscle hemoglobin concentration (g/dl)	0	32.38±0.22 ^a	32.45±0.31 ^a	32.97±0.21 ^a	32.53±0.27 ^a
	3	32.75±0.20 ^a	31.60±0.28 ^{bc}	31.90±0.47 ^{ab}	30.67±0.25 ^c
	6	32.00±0.50 ^a	29.11±0.42 ^b	32.99±0.71 ^a	28.14±0.42 ^b
	10	31.71±0.49 ^a	26.58±0.31 ^c	32.13±0.46 ^a	28.20±0.75 ^b
	21	31.96±0.63 ^a	29.97±0.34 ^b	32.97±0.41 ^a	30.61±0.36 ^b

Table 3. Leukogram of chickens treated with oregano 20% after infection with avian pathogenic *E. coli* O27 during the different experimental periods (Mean ± SE, N=5)

Parameters	Periods (dpi)	Groups			
		Normal Control (G1)	Infected (G2)	Oregano (20%) treated (G3)	Antibacterial treated (G4)
Total White blood cell count ($\times 10^3/\mu\text{l}$)	0	19.31±0.17 ^a	19.44±0.23 ^a	19.23±0.25 ^a	19.18±0.15 ^a
	3	19.68±0.21 ^b	24.10±0.50 ^a	24.56±0.26 ^a	24.35±0.44 ^a
	6	20.11±0.25 ^d	25.11±0.52 ^a	21.55±0.26 ^c	20.46±0.36 ^b
	10	20.63±0.25 ^c	24.62±0.52 ^a	21.08±0.26 ^{bc}	23.49±0.36 ^b
	21	20.30±0.23 ^b	22.09±0.24 ^a	20.46±0.27 ^b	19.16±0.22 ^c
Heterophils ($\times 10^3/\mu\text{l}$)	0	7.45±0.17 ^a	7.44±0.26 ^a	7.41±0.19 ^a	7.30±0.19
	3	7.63±0.14 ^b	12.89±0.12 ^a	12.92±0.17 ^a	12.64±0.29 ^a
	6	7.53±0.31 ^d	13.27±0.27 ^a	10.01±0.25 ^c	11.48±0.37 ^b
	10	8.30±0.20 ^c	13.15±0.42 ^a	8.77±0.18 ^c	9.85±0.27 ^b
	21	7.88±0.13 ^b	12.11±0.16 ^a	7.94±0.17 ^b	8.36±0.18 ^b
Lymphocytes ($\times 10^3/\mu\text{l}$)	0	9.77±0.08 ^a	9.64±0.14 ^a	10.00±0.21 ^a	10.14±0.23 ^a
	3	10.11±0.11 ^a	8.95±0.47 ^b	9.32±0.18 ^b	9.29±0.15 ^b
	6	10.69±0.18 ^a	8.24±0.39 ^c	9.14±0.22 ^b	10.06±0.08 ^{bc}
	10	10.36±0.18 ^a	8.90±0.17 ^c	10.11±0.09 ^{ab}	9.70±0.08 ^b
	21	10.56±0.16 ^a	7.02±0.17 ^c	10.54±0.17 ^a	8.97±0.15 ^b
Monocytes ($\times 10^3/\mu\text{l}$)	0	0.90±0.05 ^a	0.88±0.05 ^a	0.94±0.09 ^a	0.92±0.08 ^a
	3	0.99±0.08 ^a	1.00±0.09 ^a	0.90±0.07 ^a	1.20±0.07 ^a
	6	1.00±0.09 ^b	1.89±0.15 ^a	1.25±0.13 ^a	1.74±0.14 ^a
	10	1.02±0.18 ^a	1.19±0.11 ^a	1.31±0.12 ^a	1.26±0.11 ^a
	21	1.15±0.11 ^b	1.66±0.12 ^a	1.05±0.08 ^b	0.99±0.07 ^b
Eosinophils ($\times 10^3/\mu\text{l}$)	0	0.42±0.04 ^b	0.43±0.07 ^{ab}	0.39±0.06 ^a	0.46±0.05 ^a
	3	0.44±0.04 ^a	0.48±0.01 ^a	0.54±0.06 ^a	0.52±0.05 ^a
	6	0.44±0.04 ^b	0.74±0.10 ^a	0.49±0.05 ^b	0.57±0.06 ^b
	10	0.45±0.05	0.55±0.05 ^a	0.46±0.01 ^a	0.45±0.01 ^a
	21	0.45±0.01 ^b	0.53±0.05 ^a	0.50±0.04 ^b	0.45±0.03 ^b
Basophils ($\times 10^3/\mu\text{l}$)	0	0.66±0.05 ^a	0.62±0.03 ^a	0.60±0.06 ^a	0.67±0.06 ^a
	3	0.49±0.07 ^a	0.76±0.10 ^{ab}	0.69±0.10 ^b	0.68±0.01 ^b
	6	0.44±0.07 ^b	0.95±0.09 ^a	0.69±0.08 ^b	1.08±0.07 ^b
	10	0.54±0.05 ^b	0.84±0.07 ^a	0.42±0.07 ^b	0.48±0.08 ^b
	21	0.28±0.05 ^b	0.75±0.11 ^a	0.40±0.09 ^b	0.42±0.07 ^b
Platelets ($\times 10^3/\mu\text{l}$)	0	5.28±0.07 ^a	5.26±0.08 ^a	5.49±0.12 ^a	5.41±0.08 ^a
	3	5.61±0.15 ^a	5.35±0.10 ^a	5.68±0.11 ^a	4.41±0.10 ^a
	6	6.85±0.09 ^a	6.11±0.27 ^b	6.61±0.17 ^{ab}	6.49±0.10 ^a
	10	7.05±0.09 ^a	5.95±0.10 ^c	6.61±0.13 ^b	6.59±0.08 ^b
	21	6.21±0.06 ^a	5.39±0.18 ^c	5.91±0.09 ^{ab}	5.62±0.19 ^a

Means with different superscripts (a, b, c) in the same row are significantly different at $P < 0.05$.

3.5. Biochemical findings

Infected group (G2) exhibited a significant ($P<0.05$) increase in the activities of AST and ALT compared to normal control group starting from the 3rd till the end of the experimental periods. In both groups of treated chicks (G3 and G4), values of ALT activity significantly ($P<0.05$) elevated at the 3rd and 6th dpi, while values of AST activity were significantly

($P<0.05$) increased at the 3rd, 6th and 10th dpi then returned to the normal control values thereafter (Fig. 1)

Serum creatinine and uric acid levels in chicks of infected (G2) and antibiotic treated (G4) were increased from the 3rd till the 10th dpi then returned to normal levels at the 21st dpi compared to chicks of control (G1) and oregano treated (G3). (Fig. 1)

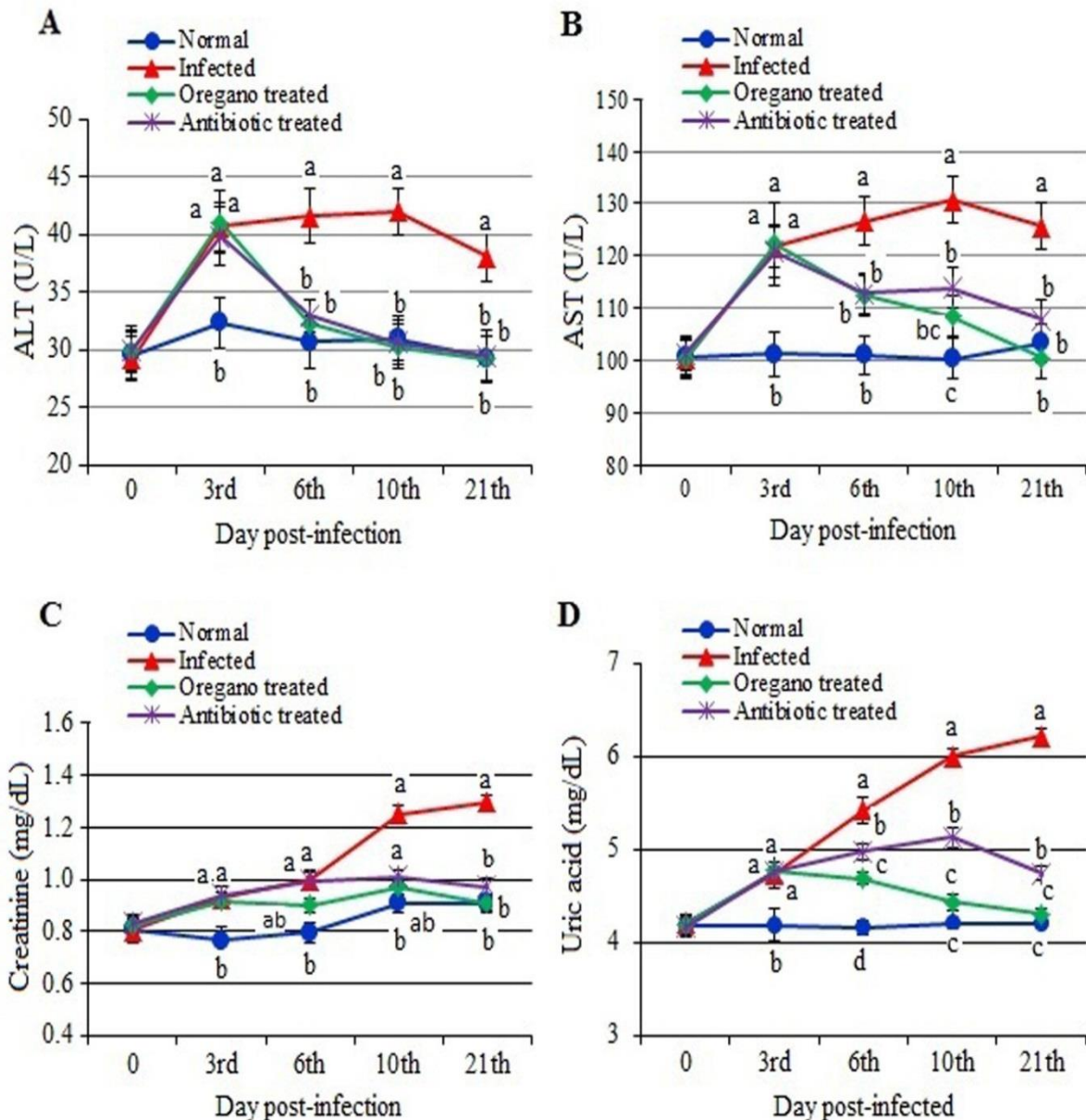


Fig. 1. Alanine aminotransferase (ALT) (A), aspartate aminotransferase (AST) (B), creatinine (C), and uric acid (D) levels in the serum of chickens treated with oregano after infection with avian pathogenic *E. coli* O27 during the different experimental periods (Mean±SE, N=5). Means with different letters (a, b, c, d) at the same period are significant at $P<0.05$.

From the 3rd dpi till the end of the experiment, values of total serum proteins, albumin, total globulins and A/G ratio significantly ($P < 0.01$) decreased in infected (G2) and antibiotic treated chickens (G4) compared to normal control ones. Oregano treated

chickens recorded marked decrease in the serum protein profile at the 3rd and 6th dpi. These parameters restored normal levels from the 10th day to the end of the experimental period. (Fig. 2)

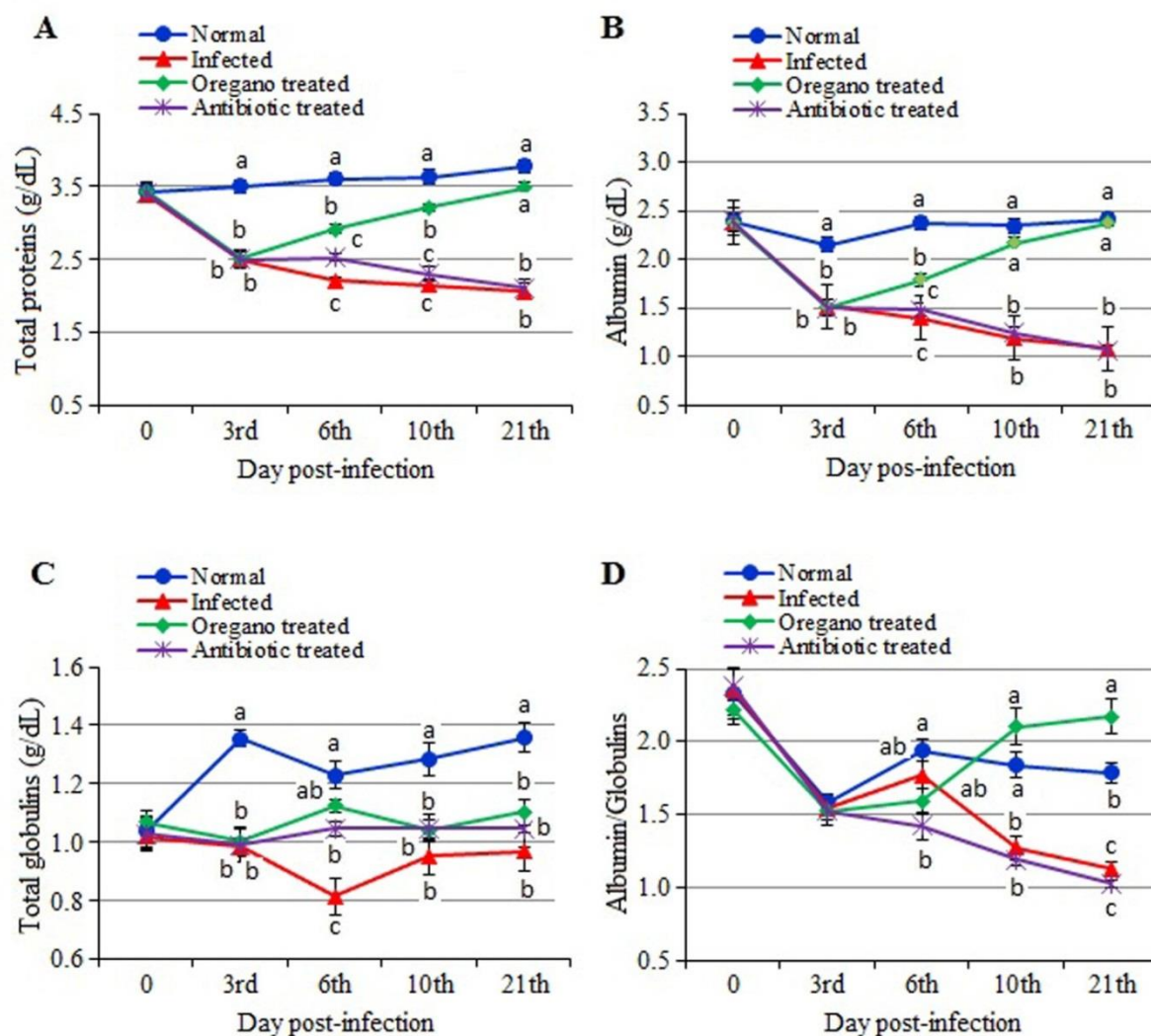


Fig. 2. Serum Protein profile; total proteins (A), albumin (B), total globulins (C), and Albumin/globulins (D) levels in the serum of chickens treated with oregano after infection with avian pathogenic *E. coli* O27 during the different experimental periods (Mean \pm SE, N=5). Means with different letters (a, b, c) at the same period are significant at $P < 0.05$.

3.6. Pathological findings

3.6.1. Post-mortem findings

No gross lesions were observed in chickens of the normal control group and oregano treated group all over the experimental period. Infected and antibiotic treated groups showed slight congestion at the 3rd and the 6th dpi in some lungs, livers, and kidneys. At the 10th and 21st dpi, severe congestion of lungs, liver, spleen and kidney was seen.

3.6.2. Microscopic findings

No microscopic alterations were observed in the lung, trachea, liver, spleen, and kidneys of the normal

control group (G1) during different experimental periods (Figs. 3A-7A).

Lungs: Microscopic examination of lung sections in infected group (G2), at the 3rd and 6th dpi, showed congestion of the peri air blood capillaries (Fig. 3B). At the 10th and 21st dpi, lung showed congestion of the peri air blood capillaries and interstitial blood vessels (Fig. 3C). Lungs of oregano group (G3) showed slight congestion of air capillaries in all periods (Fig. 3D). Lungs of antibiotic treated group (G4), showed congestion of the peri air blood capillaries at the 3rd and 6th dpi (Fig. 3E). By the 10th dpi, lung

demonstrated congestion of the peri air blood capillaries and interstitial blood vessels (**Fig. 3F**). By the end of experiment, lungs showed normal histological picture in all groups except infected group.

Trachea: In the infected group, (**Fig. 4B-C**) hyperplasia in the mucosal tracheal epithelium and edema of the submucosa was the constant finding in the trachea at the 3rd and 6th dpi (**Fig. 4B**). At the 6th & 21st dpi, proprial mononuclear cells infiltration with congestion of the blood vessels was observed in trachea (**Fig. 4C**). Also, at the 10th and 21st dpi, hyperplasia in the mucosal epithelium was detected in trachea of oregano group (**Fig. 4D**). In antibiotic treated group; at the 3rd dpi, trachea showed hyperplasia in the lining mucosa with increase in the number of goblet cells (**Fig. 4E**). At the 6th & 10th dpi, trachea displayed necrosis in the mucosal lining epithelium with mononuclear cells infiltration in the lamina propria (**Fig. 4F**). By the end of the experiment, trachea showed normal histological picture in all groups except infected group.

Liver: Microscopic examination of liver sections in infected group (**Fig. 5B-D**), at the 3rd day post infection (dpi), showed congestion of hepatic sinusoids, central veins and portal BVs (**Fig. 5B**). At the 6th dpi, some livers revealed congested central vein (**Fig. 5C**), by the 10th dpi, the liver showed aggregation of mononuclear cells infiltrations forming minute foci with multiple areas of diffuse hemorrhages (**Fig. 5D**). At the 6th dpi, after treated with oregano, livers showed normal hepatic parenchyma with normal hepatic architecture (**Fig. 5E**). However, antibiotic treated group; at the 3rd till 10th dpi, liver showed congested central vein with pericentral mononuclear cells infiltrations (**Fig. 5F**). By the end of experiment, histological picture of livers appeared normal in all groups except the infected group.

Spleen: In infected group (**Fig. 6B-C**), congestion of splenic red pulp was the constant finding in the spleen at the 3rd and 6th dpi (**Fig. 6B**). Also, hyperplasia of ellipsoidal reticular cells in the subcapsular sinuses and around capillaries was observed at the 10th dpi. Moreover, some spleens showed thickened muscular layer of blood vessels (**Fig. 6C**). In oregano group, spleen displayed focal areas of hemorrhage at the 6th dpi (**Fig. 6D**), and at the 10th dpi, spleen showed dilated blood vessels with thickened wall (**Fig. 6E**). At the 3rd and 10th dpi, spleen of antibiotic treated group demonstrated thickened muscular layer of the blood vessels (**Fig. 6F**). By the end of experiment histological picture of spleens appeared normal in all groups except the infected group.

Kidneys: Histopathological examination of kidney sections of infected group (**Figs. 7B-7D**), revealed congestion of interstitial blood vessels at the 3rd dpi in

infected group (**Fig. 7B**). Also, degenerative changes in the renal epithelium were seen. At the 6th dpi, slight degeneration of some renal tubules was noticed, as well as hemorrhage in the interstitial tissue of kidney was detected (**Fig. 7C**). By the 10th dpi, kidney showed hemorrhages in the interstitial tissue (**Fig. 7D**). At the 3rd dpi, kidneys of oregano group demonstrated necrosed renal tubules and focal areas of hemorrhage (**Fig. 7E**). At the 3rd dpi, kidneys of the antibiotic treated group displayed congestion of the interstitial blood vessels (**Fig. 7F**). By the end of experiment, kidneys histological picture appeared normal in all groups except the infected group.

4. Discussion

This study was conducted to evaluate the efficacy of oregano oil 20% for treatment of chicks -19-day-old experimentally infected with APEC O27 -local isolate-. Hematological, serum biochemical, and pathological alterations of the vital organs were investigated during the experimental periods.

Avian colibacillosis is one of the most common diseases causing significant economic losses to the poultry industry in the world [34]. Clinical signs demonstrated in the infected group began at the 3rd dpi in the form of dullness, ruffled feather, gasping, huddling together, loss of appetite and depression. Mortality rates among infected group, oregano treated and antibiotic treated were 30%, 4% and 8%, respectively. Similar results were previously observed by De Carli et al. [35].

Data of erythrogram revealed significant decrease in RBCs and Hb concentration beginning at the 3rd dpi and macrocytic hypochromic anemia was recorded. Similar results were previously mentioned by Huff et al. [36]. The decrease in hematological parameters may be due to break down of erythrocytes by hemolytic enzymes found in endotoxins that produced by *E. coli* [37] led to decrease in the values of RBCs count, and PCV and hemoglobin concentration [25]. Observation of the erythrocytic indices revealed an increase in the values of MCV and decrease in MCHC which indicated that chicks were suffering from macrocytic hypochromic anaemia. Saini [38] reported normocytic normochromic anemia in *E. coli* infection in broiler chicken. But, Petrov et al. [39] reported a decrease in MCV in the offspring of *E. coli* infected rabbits as well as in the experimentally infected rabbits. Haq et al. [40] reported decrease in MCV, MCH and MCHC in *E. coli* infection in pigeons. The erythrogram had a tendency to be affected till the end of experiment which indicated that APEC O27 affected strongly the erythrogram of chickens.

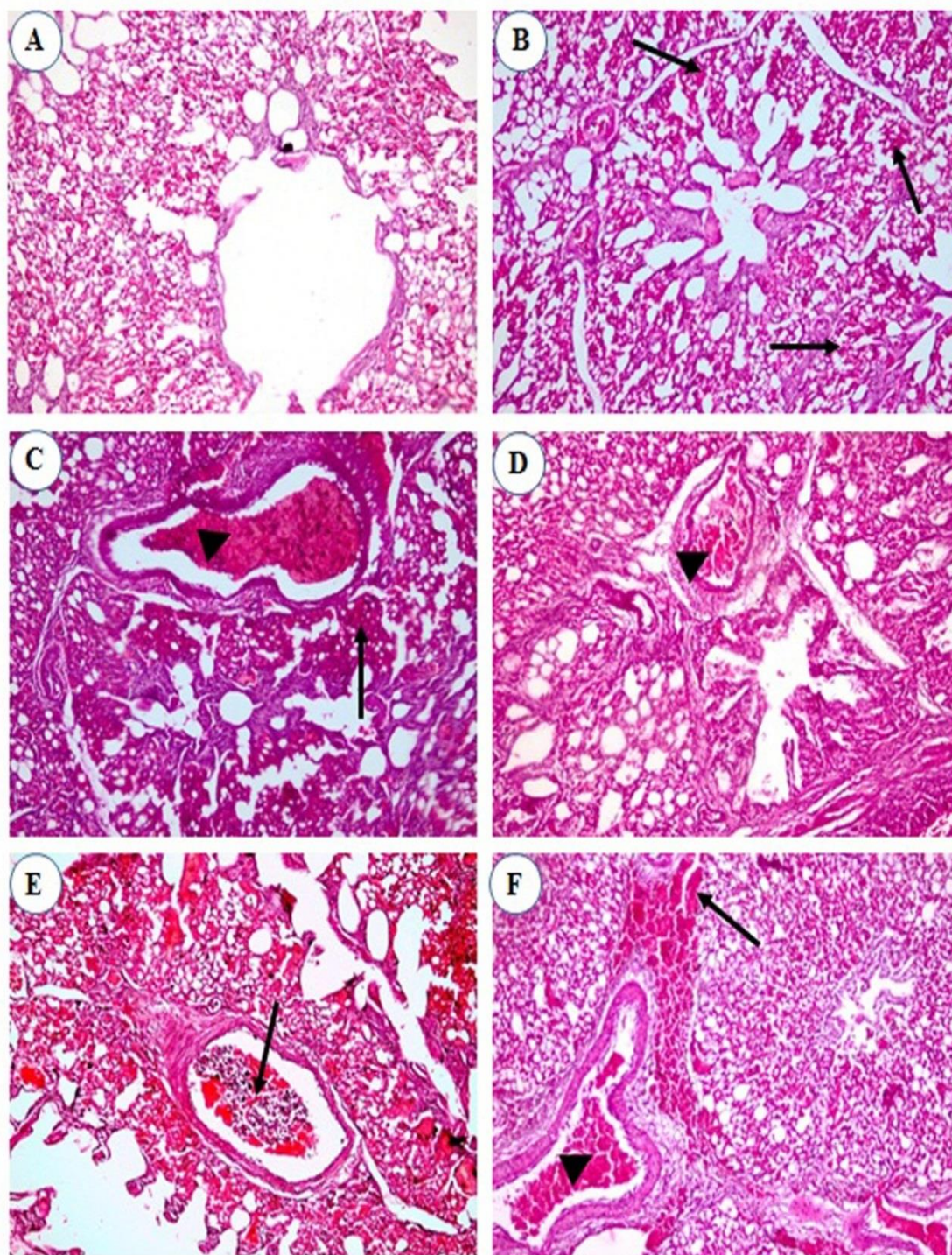


Fig. 3. Lung of broiler chickens: (A) Normal control group; showing, normal parenchyma of parabronchus and air capillaries, (B-D) Infected group; (B) showing congestion of the peri air blood capillaries (arrows) at the 3rd day post infection (dpi), (C) showing congestion of the peri air blood capillaries (arrow) and interstitial blood vessel (arrow head) at the 10th dpi, and (D) showing congestion of the interstitial blood vessel (arrow head) at the 21st dpi, (E) Oregano treated group; showing congestion of the air capillaries (arrows) at the 6th dpi, and (F) Antibiotic treated group; showing congestion of the peri air blood capillaries (arrow) and interstitial blood vessel (arrow head) at the 10th dpi. (H&E, x200)

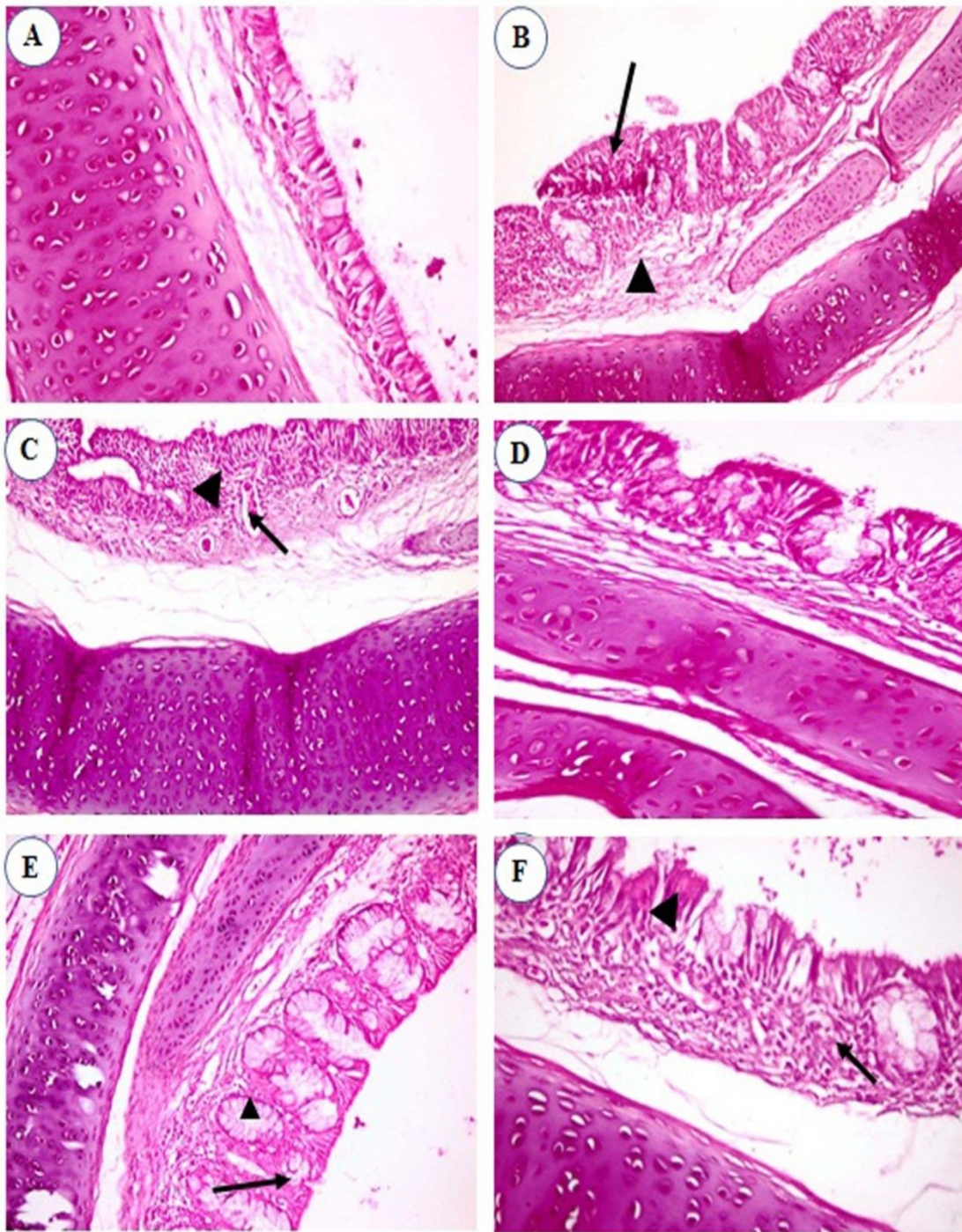


Fig. 4. Trachea of broiler chickens: (A) Normal control group; showing normal mucosa (H&E, x200), (B-C) Infected group; (B) showing hyperplasia in the mucosal epithelium (arrow) and edema of the submucosa (arrow head) at the 3rd day post infection (dpi) (H&E, x200), (C) showing proprial mononuclear cells infiltration (arrow head) with congested blood vessel (arrow) at the 6th dpi (H&E, x200), (D) Oregano group; showing hyperplasia in the mucosal epithelium at the 21st dpi (H&E, x400), (E-F) Antibiotic group; (E) showing hyperplasia in the lining mucosa (arrow) with goblet cell formation (arrow head) at the 3th dpi (H&E, x200), and (F) showing necrosis in the mucosal lining epithelium (arrow) with mononuclear cells infiltrations in the lamina propria (arrow head) at the 10th dpi (H&E, x400).

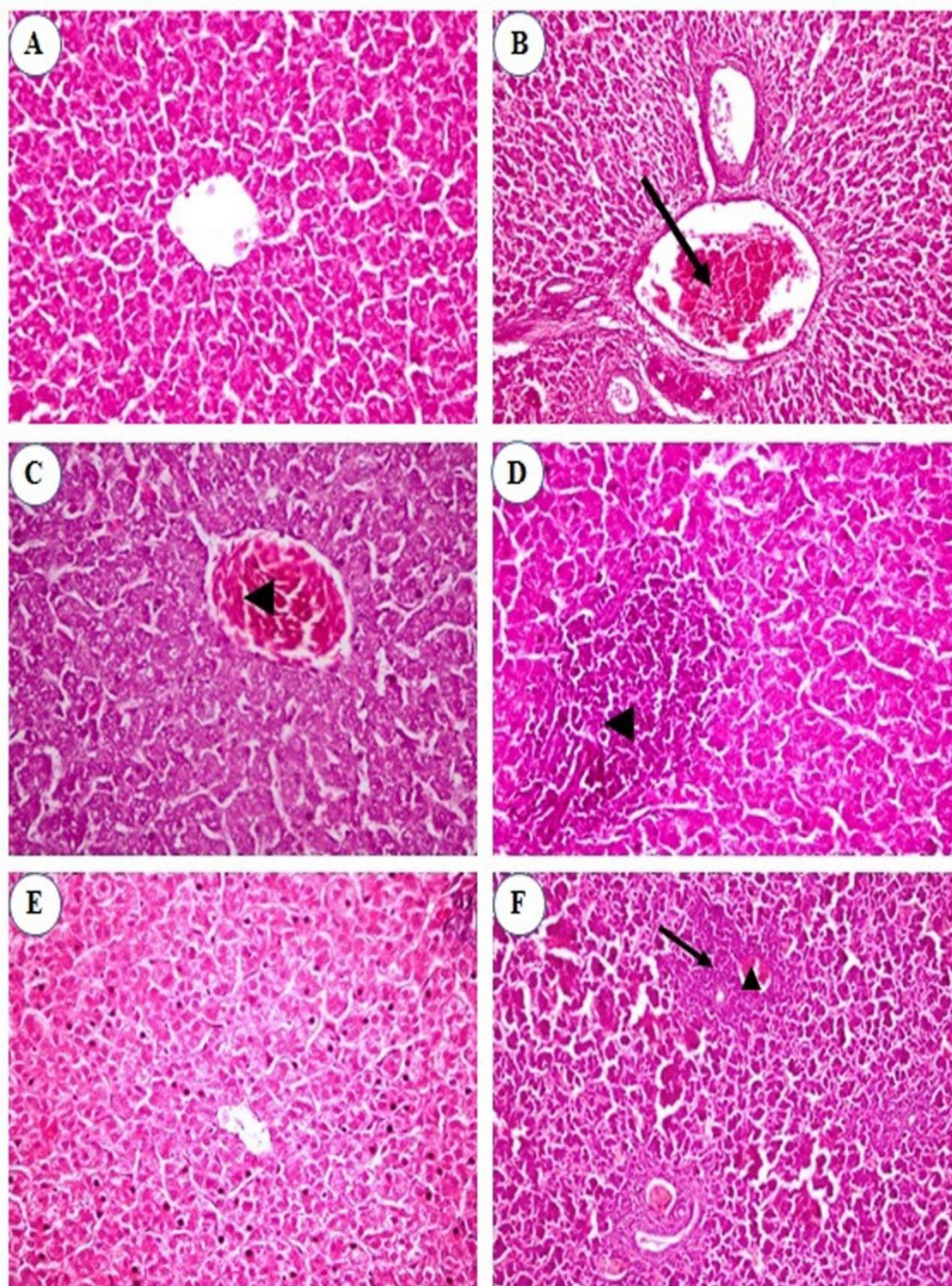


Fig. 5. Liver of broiler chickens: (A) Normal control group; showing healthy parenchyma of hepatocytes, central vein, and blood sinusoids (H&E x400), (B-D) Infected group; (B) showing congestion of the hepatoportal blood vessel (arrow) at the 3rd day post infection (dpi) (H&E x200), (C) showing congested central vein (arrow head) at the 6th dpi (H&E x400), and (D) showing large focal area of mononuclear cells infiltration (arrow head) at the 10th dpi (H&E x400), (E) Oregeno group; showing normal hepatic parenchyma at the 6th dpi (H&E x400), and (F) Antibiotic group; showing congested central vein (arrow head) with pericentral mononuclear cells infiltration (arrow) at the 3rd dpi (H&E x200).

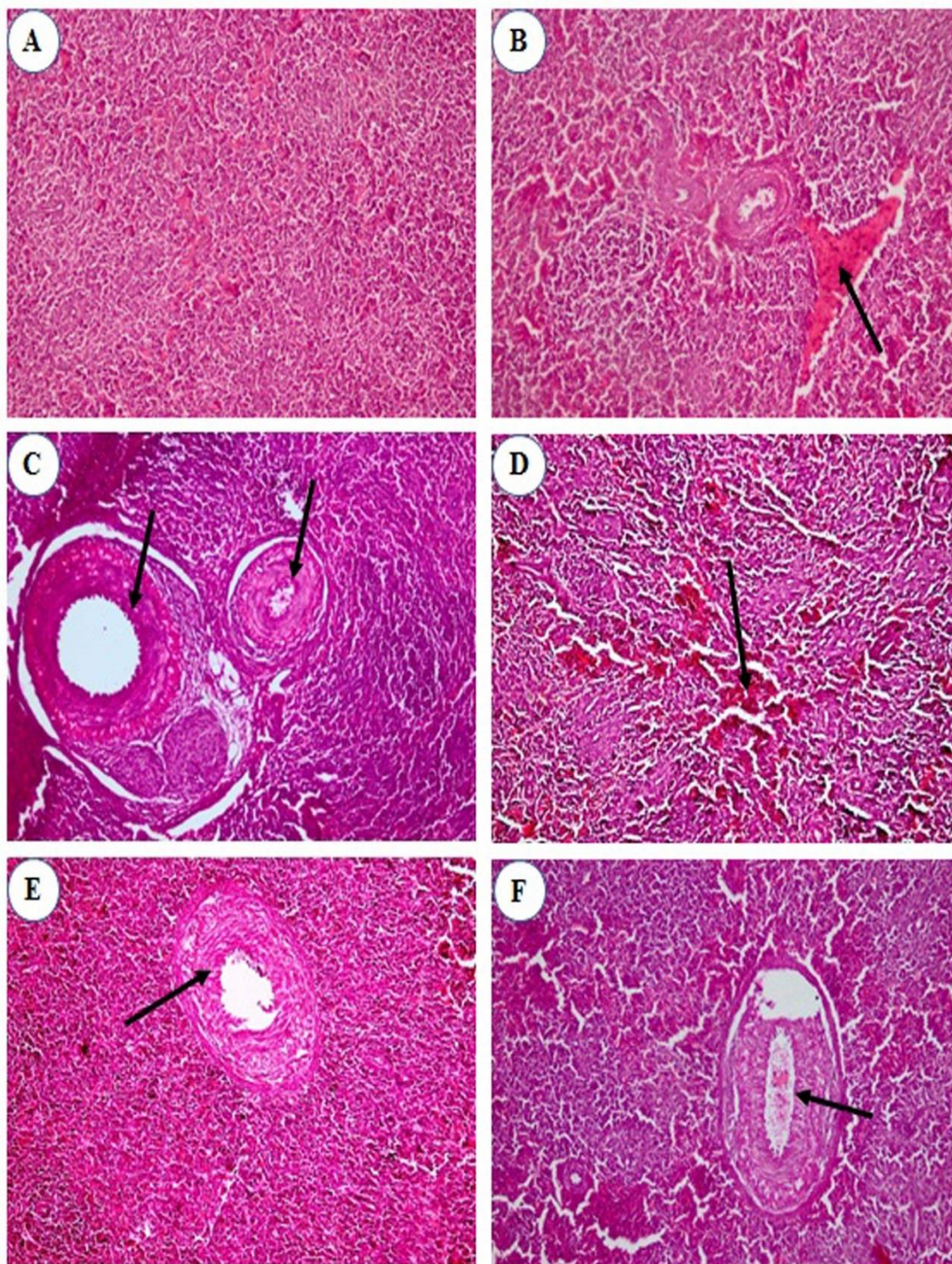


Fig. 6. Spleen of broiler chickens: (A) Normal control group; showing normal follicles, white pulps, and red pulps, (H&E, x200), (B-C) Infected group; (B) showing congestion of the blood vessel, (arrow) at the 3rd day post infection (dpi), (H&E, x200), and (C) showing thickened muscular layer of the blood vessel (arrows) at the 10th dpi (H&E, x400), Oregano group (D-E); (D) showing focal areas of hemorrhage (arrow) at the 6th dpi, and (E) showing dilated blood vessel with thickened wall (arrow) at the 10th dpi (H&E, x400), and (F) Antibiotic group, showing thickened muscular layer of the blood vessel (arrow) at the 3rd dpi (H&E, x400).

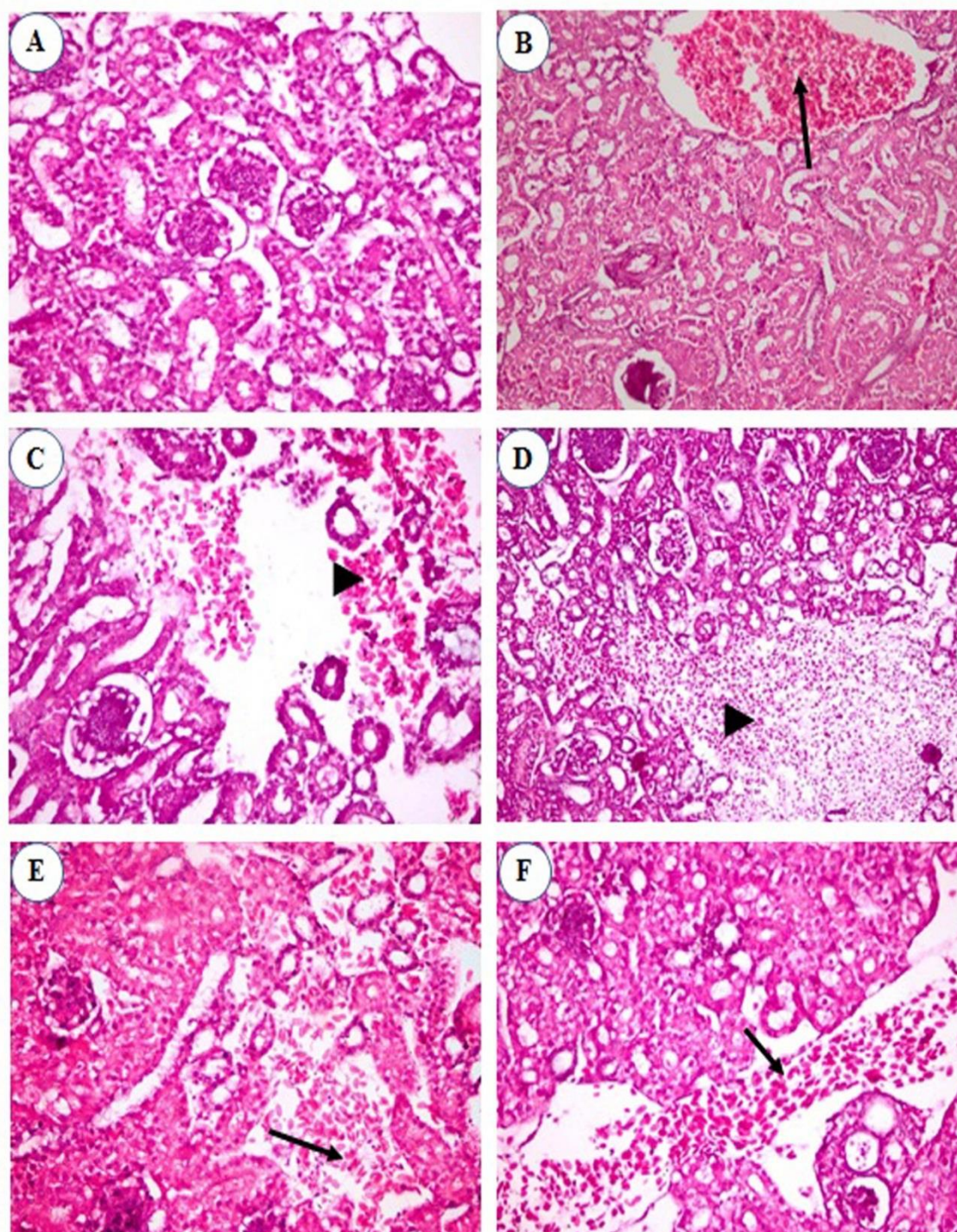


Fig. 7. Kidney of broiler chickens: (A) Normal control group; showing normal parenchyma of renal glomeruli and renal tubules (H&E, x400), (B-D) Infected group; (B) showing congestion of the interstitial blood vessel (arrow) at the 3rd day post infection (dpi) (H&E x400), and (C) showing hemorrhages in the interstitial tissue (arrow head) at the 6th dpi (H&E x400), and (D) showing hemorrhages in the interstitial tissue (arrow head) at the 10th dpi, (H&E, x200), (E) Oregano group; showing necrosed renal tubules and focal area of hemorrhage (arrow) at the 6th dpi (H&E, x400), and (F) Antibiotic group; showing congestion of the interstitial blood vessel (arrow) at the 3rd dpi (H&E, x400)

There was a significant increase in the total WBCs and absolute heterophils, eosinophils and basophiles in the infected groups as compared to control group. Leukocytes play an important role in infection and immune response. Leukocytosis is mainly encountered in localized or generalized infections, tissue necrosis, acute hemorrhages and acute hemolysis resulted from APEC O27 infection and its endotoxin [25]. Heterophils are the first line of defense which attack and engulf microorganisms. Heterophilia is a normal response to bacterial *E. coli* infection [25]. The observed heterophilia in the present experiment may be due to APEC infection that increased the inflammatory response as myeloperoxidase activity and production of cytokines, such as IL1 β , TNF- α , IL-6 of lung tissues [41]. This was confirmed by necrosis and hemorrhages in visceral organs on the basis of histopathological findings. Lymphopenia was recorded in our study. Lymphopenia may be due to stress of infection with APEC O27 and its endotoxin which stimulate the adrenal gland to secrete corticosteroid hormones, causing destruction of lymphocytes. The endogenous glucocorticoids cause heterophilia associated with lymphopenia. [42, 43]

There was a decrease in thrombocytes count in infected groups. It is may be due to endotoxins produced by APEC O27 [37] which was confirmed histopathological finding of congestion and hemorrhages in the internal organs.

Biochemical studies revealed significant increase in the serum AST and ALT activity of the infected group. Similar results have been reported by Kumari et al. [44,45] who worked on *E. coli* infection in broiler chickens. These increases could be attributed to hepatocellular damage. In the present study, the elevation of the hepatic enzymes activities was supported by the histopathological findings of the liver. These quantitative differences in the results of serum AST and ALT between the infected group and oregano treated group suggested that hepatoprotective and cardio protective effects of oregano essential oil supplementation that contain bioactive components (such as carvacrol, thymol and p-cymene) have antioxidant and antibacterial effects [12,13,15] which restored the normal enzymes activity compared to infected group.

The level of creatinine and uric acid is known to reflect the state of glomerular filtration rate and kidney functions. The present work showed a significant increase in serum creatinine and uric acid levels that may be attributed to kidney damage caused by the effect of APEC and its toxin on the kidney tissue. This result was confirmed by degenerative changes in the renal epithelium, slight degeneration of some renal tubules and hemorrhage in the interstitial tissue of infected group. Our results agree with Kumari et al. [44,45].

After treatment with oregano, the creatinine showed within the normal level. It may be due to its bioactive components which have antioxidant and antibacterial effects [12,13,15]. So, this result revealed that, the oregano has nephroprotective effect. In antibiotic group, creatinine level retained to the normal after the long time (at the 21st dpi). It is may be due to the adverse effect of both endotoxins produced by APEC O27 [37,44,45] and residue antibiotic (Difloxacin) on the kidney functions [46].

Regarding serum protein profile, results revealed significant reduction in the concentrations of total proteins, albumin, total globulins and A/G ratio in the serum of both infected and antibiotic treated chickens which started after infection with APEC O27 till the end of the experiment. However, serum protein profile of oregano treated chickens exhibited decreases from the 3rd till the 6th dpi then returned to the normal levels indicating the hepatoprotective effect of oregano essential oil. Similar results have been previously reported in chickens infected by APEC [45,47]. Hypoproteinemia may be due to liver damage which causes failure in plasma protein synthesis, and renal affection which leads to protein loss [48]. The liver is a site for all protein fractions synthesis except gamma globulin. In the present study, damage to liver and kidney as evidenced by gross and histopathological studies were observed, leading to decrease in total serum proteins and albumin concentration. In oregano treated chicken, protein profile restored normal levels from the 10th (dpi) to the end of the experimental period indicating the hepatoprotective, antioxidant and anti-inflammatory effects of oregano essential oil which contains bioactive phenolic compounds; such as carvacrol, thymol and p-cymene that have antibacterial and antioxidant activities [12,13,15] Our results disagree with Saini [38] who recorded hyperglobulinemia associated with liver cirrhosis, hepatitis, and Kupffer cells proliferation in broiler chicks infected with APEC.

Regarding the microscopical examination, lungs of chickens experimentally infected with APEC O27 noticed severe congestion of pulmonary blood vessels and capillaries with hemorrhage which were prevalent in most cases. These microscopical findings were previously mentioned by Reese et al. [49]. Hyperplasia in the mucosal tracheal epithelium and edema of the submucosa were the constant findings at the 3rd and 6th dpi for infected group. Moreover, proprial mononuclear cells infiltration with congested blood vessels were observed at the 6th till 21st dpi. Microscopical examination of the examined liver of chicks experimentally infected with APEC O27, revealed congestion of some portal blood vessels with inflammatory mononuclear cells infiltration. These findings were in complete agreement with Koutsianos et

al. [50]. At the 3rd and 6th dpi, congestion of splenic red pulp was the constant finding in infected and antibiotic treated groups. At the 10th dpi, hyperplasia of ellipsoidal reticular cells in the subcapsular sinuses and around capillaries in spleen was observed. In spleen of oregano group, focal areas of hemorrhage were observed at the 6th dpi and dilated blood vessels with thickened wall were observed at the 10th dpi. The obtained microscopic pictures were mostly compatible with the result of Antão et al. [51]. Histopathological examination of kidney sections of infected group revealed congestion of interstitial blood vessels at the 3rd dpi. Also, degenerative changes in the renal epithelium were seen. At the 6th and 10th dpi, slight degeneration of some renal tubules and hemorrhage in the interstitial tissue were noticed. These observations were previously mentioned by Rodriguez-Siek et al. [52], and Ewers et al. [53]. At the 3rd dpi, (before treatment), kidneys showed that necrosed renal tubules and focal areas of hemorrhage in oregano group, and congestion of the interstitial blood vessels in antibiotic treated group. It is may be due to the effect of APEC infection and its toxin on the kidneys. Similar results were recorded by Kumari et al. [44,45]. By the end of the experiment, kidneys showed normal histological picture in all groups of treatment except the infected group.

After treatment of infected chickens with oregano essential oil 20%, blood picture, liver and kidney functions were returned to the normal level. In addition, lung, trachea, liver, spleen, and kidneys were within the normal histopathological structures. It may be due to oregano essential oil content of bioactive phenolic compounds such as carvacrol, thymol and p-cymene that have antibacterial, anti-inflammatory and antioxidant activities [12,13,15,54]. Such compounds decrease the activity of reactive oxygen species levels that are produced by macrophage cells stimulated by APEC lipopolysaccharide [55]. The antibacterial activity has been recorded due to the synergetic effect of carvacrol and thymol constituents of oregano essential oil [56].

5. Conclusion

Experimental infection of chickens with APEC O27 caused macrocytic hypochromic anemia, leukocytosis, heterophilia, and lymphopenia, and alterations in the liver and kidney functions, as well as histopathological changes in the internal organs. These changes ranged from moderate to slight after treatment with antibiotic and returned to the normal levels after treatment with oregano essential oil 20%. Supplementation of oregano essential oil 20% could ameliorate the severity of the pathogenicity caused by APEC O27. So, it could be used as antibiotic, and hepato- and nephroprotective agent. It could be recommended using oregano essential oil 20% for treatment in poultry farms rather than antibiotics.

6. Acknowledgements

The authors are grateful to Dr. Ahmed Fotouh, Researcher of Pathology, Department of Parasitology and Animal Diseases, National Research Centre, for his help in the histopathology of this study and valuable support during this work.

7. Funding

None.

8. Conflict of Interest

There are no conflicts to declare.

9. References

- [1] A.H. Hussein, I.A.I. Ghanem, A.A.M. Eid, M.A. Ali, J.S. Sherwood, G. Li, L.K. Nolan, C.M. Logue, Molecular and phenotypic characterization of *Escherichia coli* isolated from broiler chicken flocks in Egypt, *Avian Dis.* 57 (2013) 602–611. doi: <https://doi.org/10.1637/10503-012513-Reg.1>
- [2] P. Stordeur, J. Mainil, La colibacillose aviare, *Ann. Méd. Vét.* 146 (2002)11–18.
- [3] A.M. Awad, N.A. El-Shall, D.S. Khalil, M.E. Abd El-Hack, A.A. Swelum, A.H. Mahmoud, H. Ebaid, A. Komany, R.H. Sammour, M.E. Sedeik, Incidence, pathotyping, and antibiotic susceptibility of avian pathogenic *Escherichia coli* among diseased broiler chicks, *Pathogens* 9 (2020) 114. <https://doi.org/10.3390/pathogens9020114>
- [4] M. Manafi, M. Hedayati, N. Pirany, A.A. Omede, Comparison of performance and feed digestibility of the non-antibiotic feed supplement (Novacid) and an antibiotic growth promoter in broiler chickens. *Poult Sci.* 98 (2019) 904–911. <https://doi.org/10.3382/ps/pey437>
- [5] M. Alp, M. Midilli, N. Kocabağlı, H. Yılmaz, N. Turan, A. Gargılı, N. Acar, The effects of dietary oregano essential oil on live performance, carcass yield, serum immunoglobulin G level, and oocyst count in broilers. *J. Appl. Poult Res.* 21 (2012) 630–636. <https://doi.org/10.3382/japr.2012-00551>
- [6] D.P. Thompson, Fungitoxic activity of essential oil components on food storage fungi, *Mycologia.* 81 (1989) 151–153. <https://doi.org/10.1080/00275514.1989.12025637>
- [7] N. Leyva-López, E.P. Gutiérrez-Grijalva, G. Vazquez-Olivo, J.B. Heredia, Essential oils of oregano: Biological activity beyond their antimicrobial properties, *Molecules.* 22 (2017) 989. <https://doi.org/10.3390/molecules22060989>
- [8] X. Shang, Y. Wang, X. Zhou, X. Guo, S. Dong, D. Wang, J. Zhang, H. Pan, Y. Zhang, X. Miao,

- Acaricidal activity of oregano oil and its major component, carvacrol, thymol and p-cymene against *Psoroptes cuniculi* *in vitro* and *in vivo*, *Vet. Parasitol.* 226 (2016) 93–96. <https://doi.org/10.1016/j.vetpar.2016.07.001>
- [9] R.J. Lambert, P.N. Skandamis, P.J. Coote, G.J. Nychas, A study of the minimum inhibitory concentration and mode of action of oregano essential oil, thymol and carvacrol. *J. Appl. Microbiol.* 91 (2001) 453–462. <https://doi.org/10.1046/j.1365-2672.2001.01428.x>
- [10] M. Llana-Ruiz-Cabello, D. Gutiérrez-Praena, S. Pichardo, F.J. Moreno, J.M. Bermúdez, S. Aucejo, A.M. Cameán, Cytotoxicity and morphological effects induced by carvacrol and thymol on the human cell line Caco-2, *Food Chem. Toxicol.* 64 (2014) 281–290. <https://doi.org/10.1016/j.fct.2013.12.005>
- [11] T.M. de Oliveira, R.B.F. de Carvalho, I.H.F. da Costa, G.A.L. de Oliveira, A.A. de Souza, S.G. de Lima, R.M. de Freitas, Evaluation of p-cymene, a natural antioxidant, *Pharm. Biol.* 53 (2015) 423–428. <https://doi.org/10.3109/13880209.2014.923003>
- [12] I. Rodriguez-Garcia, B.A. Silva-Espinoza, L.A. Ortega-Ramirez, J.M. Leyva, M.W. Siddiqui, M.R. Cruz-Valenzuela, G.A. Gonzalez-Aguilar, J.F. Ayala-Zavala, Oregano essential oil as an antimicrobial and antioxidant additive in food products, *Crit. Rev. Food Sci. Nutr.* 56 (2016) 1717–1727. <https://doi.org/10.1080/10408398.2013.800832>
- [13] H. Sakkas, C. Papadopoulou, [Antimicrobial activity of Basil, oregano, and thyme essential oils](#), *J. Microbiol. Biotechnol.* 27 (2017) 429–438. <https://doi.org/10.4014/jmb.1608.08024>
- [14] N. Ozdemir, Y. Ozgen, M. Kiralan, A. Bayrak, N. Arslan, M.F. Ramadan, Effect of different drying methods on the essential oil yield, composition and antioxidant activity of *Origanum vulgare* L. and *Origanum onites* L., *J. Food Meas. Charact.* 12 (2018) 820–825. <https://doi.org/10.1007/s11694-017-9696-x>
- [15] L. Diniz do Nascimento, A.A.B. Moraes, K.S.D. Costa, J.M. Pereira Galúcio, P.S. Taube, C.M.L. Costa, J. Neves Cruz, E.H. de Aguiar Andrade, L.J.G. Faria, Bioactive Natural Compounds and Antioxidant Activity of Essential Oils from Spice Plants: New Findings and Potential Applications, *Biomolecules.* 10 (2020) 988. <https://doi.org/10.3390/biom10070988>
- [16] J.-H. Lee, Y.-G. Kim, J. Lee, Carvacrol-rich oregano oil and thymol-rich thyme red oil inhibit biofilm formation and the virulence of uropathogenic *Escherichia coli*, *J. Appl. Microbiol.* 123 (2017) 1420–1428. <https://doi.org/10.1111/jam.13602>
- [17] H. Zhai, H. Liu, S. Wang, J. Wu, A.-M. Klünter, Potential of essential oils for poultry and pigs, *Anim. Nutr.* 4 (2018) 179–186. <https://doi.org/10.1016/j.aninu.2018.01.005>
- [18] L.A. M'Barek, H.A. Mouse, A. Jaâfari, R. Aboufatima, A. Benharref, M. Kamal, J. Bénard, N. El Abbadi, M. Bensalah, A. Gamouh, A. Chait, A. Dalal, A. Ziad, Cytotoxic effect of essential oil of thyme (*Thymus broussonettii*) on the IGR-OV1 tumor cells resistant to chemotherapy, *Braz. J. Med. Biol. Res.* 40 (2007) 1537–1544. <https://doi.org/10.1590/s0100-879x2007001100014>
- [19] M.S. Zaki, O. Fawzy, M.H. Osfor, Effect of *E. coli* OH157 on Baladi broiler chicken and some biochemical studies, *Life Sci. J.* 9 (2012) 91–94.
- [20] V. Sharma, K.K. Jakhar, V. Nehra, S. Kumar, Biochemical studies in experimentally *Escherichia coli* infected broiler chicken supplemented with neem (*Azadirachta indica*) leaf extract, *Vet. World*, 8 (2015) 1340–1345. <https://doi.org/10.14202/vetworld.2015.1340-1345>
- [21] P. Quinn, M. Bryan, M. Carter, G. Carter, *Clinical Veterinary Microbiology*. Second ed., Mosby Ltd., United States, pp. 327–344, 2013
- [22] NRC (National Research Council) *Nutritional Requirements of Poultry*, ninth Revised ed., The National Academy Press, Washington, DC, 1994. <https://doi.org/10.17226/2114>
- [23] J.K. Rosenberger, P.A. Fries, S.S. Cloud, R.A. Wilson, *In vitro* and *in vivo* characterization of avian *Escherichia coli*. II. Factors associated with pathogenicity, *Avian Dis.* 29 (1985) 1094–1107
- [24] D.E. Swayne, J.R. Glisson, M.W. Jackwood, J.E. Pearson, W.M. Reed, *Isolation and identification of avian pathogens*, fifth ed., University of Pennsylvania New Bolton Center, Kennett square, PA., 2008.
- [25] D.J. Weiss, K.J. Wardrop, *Schalm's Veterinary Hematology*, Sixth ed., Blackwell Publishing Ltd, Ames, Iowa, USA, 2010.
- [26] M.P. Natt, C.A. Herrick, A new blood diluent counting the erythrocytes and leukocytes of chickens, *Poult. Sci.* 31 (1953) 735–738.
- [27] S. Reitman, S. Frankel, A colorimeter method for determination of serum glutamic oxaloacetic acid

- and glutamic pyruvic acid transferases. *Am. J. Clin. Pathol.* 28 (1957) 56–63.
- [28] G.T. Sanders, A.J. Pasman, F.J. Hoek, Determination of uric acid with uricase and peroxidase. *Clin. Chim. Acta* 101 (1980) 299–303.
- [29] H. Bartels, M. Böhmer, C. Heierli, Serum creatinine determination without protein precipitation. *Clin. Chim. Acta* 37 (1972) 193–197.
- [30] A.G. Gornall, C.J. Bardawill, M.M. David, Determination of serum proteins by means of the biuret reaction. *J. Biol. Chem.* 177 (1949) 751–766
- [31] B.T. Dumas, W.A. Waston, H.S. Bigges, Albumin standards and the measurement of serum albumin with bromocresol green. *Clin. Chem.* 31 (1971) 87–96.
- [32] K.S. Suvarna, C. Layton, J.D. Bancroft, Bancroft's Theory and Practice of Histological Techniques, eighth ed., Elsevier Ltd., pp: 672; 2019. <https://doi.org/10.1016/C2015-0-00143-5>
- [33] G.W. Snedecor, W.G. Cochran, Statistical Methods, eighth ed., Ames, Iowa State Univ Press, 1989.
- [34] A.C. Paixão, A.C. Ferreira, M. Fontes, P. Themudo, T. Albuquerque, M.C. Soares, M. Fevereiro, L. Martins, M.I. Correa de Sa, Detection of virulence-associated genes in pathogenic and commensal avian *Escherichia coli* isolates, *Poult. Sci.* 95 (2016) 1646–1652. <https://doi.org/10.3382/ps/pew087>
- [35] S. De Carli, N. Ikuta, F.K.M. Lehmann, V.P. da Silveira, G.M. Predebon, A.S.K. Fonseca, V.R. Lunge, Virulence gene content in *Escherichia coli* isolates from poultry flocks with clinical signs of colibacillosis in Brazil, *Poult. Sci.* 94 (2015) 2635–2640. <https://doi.org/10.3382/ps/pev256>
- [36] G.R. Huff, W.E. Huff, N.C. Rath, N.B. Anthony, K.E. Nestor, Effects of *Escherichia coli* challenge and transport stress on hematology and serum chemistry values of three genetic lines of turkeys, *Poult. Sci.* 87 (2008) 2234–2241. <https://doi.org/10.3382/ps.2008-00128>
- [37] S.S. Justice, D.A. Hunstad, P.C. Seed, S.J. Hultgren, Filamentation by *Escherichia coli* subverts innate defenses during urinary tract infection, *Proceedings of the National Academy of Sciences of the United States of America*, 103 (2006) 19884–19889. <https://doi.org/10.1073/pnas.0606329104>
- [38] V. Saini, Studies on the effect of neem (*Azadirachta indica*) leaf extract on the pathology and pathogenesis of *E. coli* infection in broiler chicks, M.V.Sc. Thesis, Chaudhary Charan Singh Haryana Agricultural University, Hisar, 2004.
- [39] V. Petrov, M. Lyutskanov, D. Kanakov, Effects of spontaneous and experimental colibacteriosis on some haematological and blood biochemical parameters in weaned rabbits, *Bulg. J. Vet. Med.* 14 (2011) 238–246.
- [40] K.U. Haq, A.A. Khan., S. Ullah, G. Nabi, Comparative efficacy of norfloxacin, clarithromycin and cefpodoxime against experimentally induced colibacillosis in pigeons, *American-Eurasian Journal of Toxicological Sciences.* 7 (2015) 72–82. <https://doi.org/10.5829/idosi.ajejts.2015.7.2.93259>
- [41] L.-Y. Peng, M. Yuan, K. Song, J.-L. Yu, J.-H. Li, J.-N. Huang, P.-F. Yi, B.-D. Fu, H.-Q. Shen, Baicalin alleviated APEC-induced acute lung injury in chicken by inhibiting NF- κ B pathway activation, *Int. Immunopharmacol.* 72 (2019) 467–472. <https://doi.org/10.1016/j.intimp.2019.04.046>
- [42] J. de Groot, G.W. Harris, Hypothalamic control of anterior pituitary and blood lymphocytes, *J. Physiol.* 111 (1950) 335–340. <https://doi.org/10.1113/jphysiol.1950.sp004483>
- [43] C.G. Scanes, Biology of stress in poultry with emphasis on glucocorticoids and the heterophil to lymphocyte ratio. *Poult. Sci.* 95 (2016) 2208–2215 <https://doi.org/10.3382/ps/pew137>
- [44] M. Kumari, R.P. Gupta, R. Sharma, Biochemical and immunological response of *Ocimum sanctum* in chickens experimentally infected with *Escherichia coli*, *Indian J. Vet. Pathol.* 38 (2014) 98–102. <https://doi.org/10.5958/0973-970X.2014.01147.X>
- [45] M. Kumari, R.P. Gupta, D. Lather, P. Bagri, Ameliorating effect of *Withania somnifera* root extract in *Escherichia coli*-infected broilers, *Poult. Sci.* 99 (2020) 1875–1887. <https://doi.org/10.1016/j.psj.2019.11.022>
- [46] H.F. Mohamed, A.H. Atta, A.S. Darwish, M. Atef, Effect of Probiotics on the Pharmacokinetic Aspects and Tissue Residues of Difloxacin in Broiler Chickens. *Pak Vet J.* (2020). <http://dx.doi.org/10.29261/pakvetj/2021.013>
- [47] N. Arshad, C. Neubauer, S. Hasnain, M. Hess, *Peganum harmala* can minimize *Escherichia coli* infection in poultry, but long-term feeding may induce side effects, *Poult. Sci.* 87 (2007) 240–249. <https://doi.org/10.3382/ps.2007-00341>
- [48] J.J. Kaneko, Serum proteins and the dysproteinemias. In: J.J. Kaneko, J.W. Harvey,

- M.L. Bruss, (editors). Clinical Biochemistry of Domestic Animals. Acad. Press, New York, NY, 1997, pp. 117–138.
- [49] S. Reese, G. Dalamani, B. Kaspers, The avian lung-associated immune system, *Vet. Res.* 37 (2006) 311–324. <https://doi.org/10.1051/vetres:2006003>
- [50] D. Koutsianos, H. Gantelet, G. Franzo, M. Lecoupeur, E. Thibault, M. Cecchinato., K.S. Koutoulis, An assessment of the level of protection against colibacillosis conferred by several autogenous and/or commercial vaccination programs in conventional pullets upon experimental challenge, *Vet. Sci.* 7 (2020) E80. <https://doi.org/10.3390/vetsci7030080>
- [51] E.-M. Antão, S. Glodde, G. Li, R. Sharifi, T. Homeier, C. Laturus, I. Diehl, A. Bethe, H.-C. Philipp, R. Preisinger, L.H. Wieler, C. Ewers, The chicken as a natural model for extraintestinal infections caused by avian pathogenic *Escherichia coli* (APEC), *Microb. Pathog.* 45 (2008) 361–369. <https://doi.org/10.1016/j.micpath.2008.08.005>
- [52] K.E. Rodriguez-Siek, C.W. Giddings, C. Doetkott, T.J. Johnson, L.K. Nolan, Characterizing the APEC pathotype. *Vet. Res.* 36 (2005) 241–256. <https://doi.org/10.1051/vetres:2004057>
- [53] C. Ewers, G. Li, H. Wilking, S. Kiessling, K. Alt, E.-M. Antão, C. Laturus, I. Diehl, S. Glodde, T. Homeier, U. Böhnke, H. Steinrück, H.-C. Philipp, L.H. Wieler, Avian pathogenic, uropathogenic, and newborn meningitis-causing *Escherichia coli*: how closely related are they? *Int. J. Med. Microbiol.* 297 (2007) 163–176. <https://doi.org/10.1016/j.ijmm.2007.01.003>
- [54] R.P. Turcu, C. Tabuc, P.A. Vlaicu, T.D. Panaite, M. Buleandra, M. Saracila, Effect of the dietary oregano (*Origanum vulgare* L.) powder and oil on the balance of the intestinal microflora of broilers reared under heat stress (32°). *Scientific Papers. Series D. Animal Science*, LXI (2018) 77–86.
- [55] N. Leyva-López, V. Nair, W.Y. Bang, L. Cisneros-Zevallos, J.B. Heredia, Protective role of terpenes and polyphenols from three species of Oregano (*Lippia graveolens*, *Lippia palmeri* and *Hedeoma patens*) on the suppression of lipopolysaccharide-induced inflammation in RAW 264.7 macrophage cells, *J. Ethnopharmacol.* 187 (2016) 302–312. <https://doi.org/10.1016/j.jep.2016.04.051>
- [56] M.J. de Rostro-Alanis, J. Báez-González, C. Torres-Alvarez., R. Parra-Saldívar, J. Rodriguez-Rodriguez, S. Castillo, Chemical composition and biological activities of oregano essential oil and its fractions obtained by vacuum distillation, *Molecules*, 24 (2019) 1904. <https://doi.org/10.3390/molecules24101904>