

## Arthrodiastasis for Treatment of Perthes' Disease

M.O.Hegazy, A.E.Abd El- Aleem, M.S.Mohammed

Orthopedic Surgery Dept, Faculty of Medicine, Benha Univ, Benha, Egypt

E-Mail:rody\_remo22@yahoo.com

### Abstract

Arthrodiastasis is an efficient method to treat Perthes' disease. Is to study the effect of arthrodiastasis in the treatment of Legg-calvé-Perthes' disease. Also, the advantages, disadvantages, complications and results of this treatment. Reported indications for arthrodiastasis were assorted to the treatment of Legg-calvé-Perthes', based on the underlying pathology. Arthrodiastasis is the best minimally invasive treatment of late cases of Perthes' disease either alone or with soft tissue release with or without containment osteotomy . Arthrodiastasis or articulated distraction of the hip either alone or with soft tissue release proved to be a good contribution to the lines of treatment of Perthes' disease. The aim of this work is to study the effect of arthrodiastasis in the treatment of Legg-Calvé-Perthes disease. Arthrodiastasis is the best minimally invasive treatment of late cases of Perthes' disease either alone or with soft tissue release with or without containment osteotomy . Arthrodiastasis or articulated distraction of the hip either alone or with soft tissue release proved to be a good contribution to the lines of treatment of Perthes' disease.

**Keywords:** Arthrodiastasis, Perthes' disease.

### 1.Introduction

Legg- Calvé -Perthes disease is an uncommon condition [1 in 5,000] that affects one, or sometimes both, hips of a child between the ages of 3 and 15 years. The disease is named after Arthur Legg, Jacques Calve, and Georg Perthes, who all independently identified the disease in the early part of the 20th century, shortly after x-ray diagnostic tools became available. The disease is commonly known as Perthes, or simply by the abbreviation LCPD[1].

Legg-Calvé-Perthes disease [LCPD] is a syndrome in which an avascular event affects the capital epiphysis [head] of the femur. Following the avascular event, the growth of the ossific nucleus stops and the bone becomes dense. The dense bone is subsequently resorbed and replaced by new bone, during which the mechanical properties of the femoral head are altered such that the head tends to flatten and enlarge. Once new bone is in place, the head slowly remodels until skeletal maturity is achieved. The management of Perthes, disease remains controversial despite the extensive literature on this subject[2].

The term arthrodiastasis is derived from the Greek words arthro [joint], dia [through], and taxis [to stretch out]. The method has been used to treat a variety of hip conditions, such as avascular necrosis, osteoarthritis, chondrolysis, neglected hip dislocation, unstable capital femoral epiphysis, and the adolescent arthritic hip [3].

The distraction method was first applied to active Perthes patients by Dr. Paley in 1989. The technique uses an external fixator which is attached to the patient's femur and pelvic bones. The fixator is

attached to the body through pins that are drilled through the skin into the femur and pelvis. Once installed, the fixator carries the weight of the body, relieving that task from the injured femur, reducing the pressure that crushes the femoral head. This allows the femoral head to regrow more rapidly and regain its spherical shape. Distraction treatment is also called arthrodiastasis[4].

### 2.Methods

Any condition that involves the loss of articular cartilage leads to pain and stiffness due to increased friction and decreased lubrication. Irregularity of the joint surfaces results in decreased surface area and increased contact stresses across the joint. Through the symmetric reconstitution of the joint surface, distraction permits repair of the articular cartilage, regaining the physiologic muscle action force across the joint and restoration of ligament balance and the joint axis [5,6].

The aim of the articulated distraction method is to neutralize muscle and weight-bearing forces, to prevent stress fractures of subchondral immature bone, to encourage synovial circulation and to promote creeping substitution.It also aims to relieve pain, allowing patients to return to normal activity [7,8].

It is thought that by creating a space between the bony surfaces and minimizing mechanical stresses, via arthrodiastasis, and maintaining movement, via the hinge, the synovial circulation will be restored [9]

### 2.1Inclusion Criteria

Distraction treatment has successfully applied for children between 6 and 15 years of age.

A child older than 6 years of age, greater than 50% involvement of the femoral head or 50% loss in the height of the lateral pillar, and signs of femoral head extrusion or subluxation .

**2.2 Exclusion criteria**

Patients under 7 years of age, of group II and III not at risk. Cases in which healing is established. Cases in which serious head shape changes have occurred .

**2.3 Surgical Technique**

**2.4 Technique of hip Arthrodiastasis**

**- Type of Fixator**

All reported experiences of hip arthrodiastasis in the literature used a hinged external fixator with two varieties, the circular Ilizarov frame and the hinged monoplanar fixator [10].

**2.5 Technical Considerations of Application of the Fixator**

**I-Application of Shanz pins or wires and frame assembly**

In the Ilizarov frame, through a 2-cm to 3-cm incision over the iliac crest, the crest is exposed and 3 shanz pins are placed in a convergent manner. The

entry points of the pins are approximately 3 cms apart. All 3 pins are fixed to the pelvic arch, after this, 3 shanz pins are placed laterally at the subtrochanteric area, perpendicular to the anatomical axis of the femoral diaphysis, and fixed to another pelvic arch. An alternative to this step is to place 2 crossing Kirschner wires through the femoral condylar area which are also perpendicular to the anatomical axis, and fix these to a ring[11].

Kucukkaya et al. placed shanz pins in the supra-acetabular area in addition to the iliac wing and the femoral diaphysis[11].

In the monoplanar fixator, accurate alignment of the external fixator with its rotating axis in line with the hip joint flexion-extension arc is critical. The cortical half pins are placed in the pelvis, engaging the outer and inner tables [1].

The proximal or pelvic fixation can be accomplished either axially with a straight clamp or transverse with a T-clamp attachment. The distal two cortical half pins are placed in the femoral diaphysis according to the template. The template is then removed and the actual fixator applied over the four half pins Fig (1). A third half pin can be added to one or both clamps to improve fixation[11].

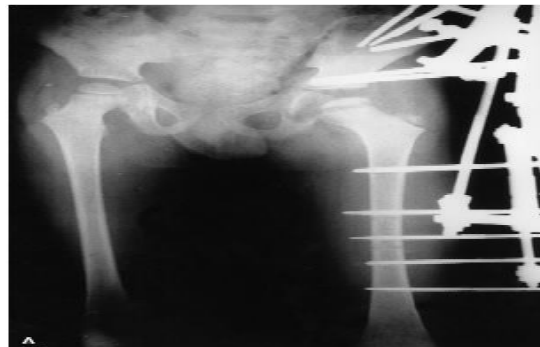
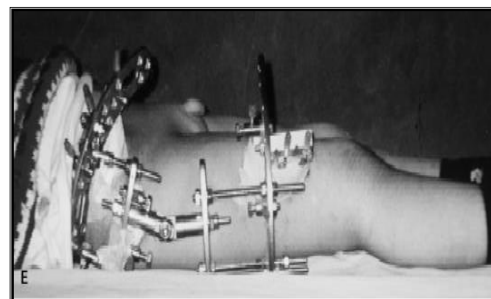
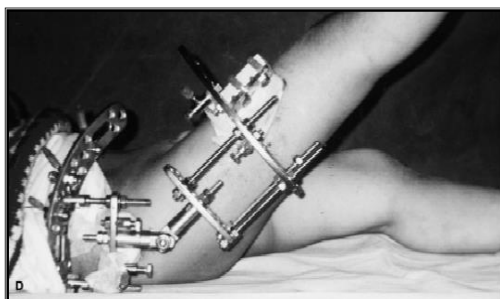


Fig (1) Position of pins[11].

**II- Position of the hinge**

A hinge mechanism used to provide only one plane movement in the saggittal plane [12].

Placement of the hinge at the level of the center of rotation of the femoral head permits the patients both hip flexion and extension Fig. (2) [13].



**Fig (2)** Hinge placed at center of the head allows full A-flexion, B-extension[13].

### III-Position of the hip joint

Kocaoglu et al. stated that the best position for hip containment, identified through hip abduction manoeuvre is generally 20 degrees of abduction<sup>[11]</sup>.

Aldegheri et al. <sup>[14]</sup> state that they applied their monolateral fixator with the hip held in 10-15 degrees of abduction.

Lopez assembled his Ilizarov frame with the limb in a position of abduction and slight flexion<sup>[15]</sup>.

### IV- Soft tissue Procedures used during arthrodiastasis

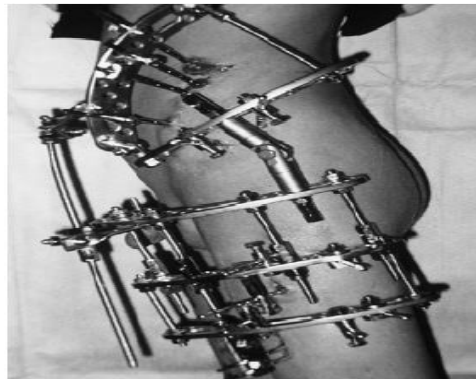
Kocaoglu et al. stated that in the presence of a flexion contracture, the hip flexors are released from their insertion area according to the Soutter technique and the iliopsoas muscle is fractionally lengthened

through its musculotendinous insertion area. If an adduction contracture is present in the hip, adductor release has to be performed <sup>[11]</sup>.

### V- The application of extension rod inside Ilizarov frame:

In the study of Kocaoglu et al., if the release has been performed for a flexion contracture, an anterior extension rod is placed to protect extension, the rod is removed during the rehabilitation sessions Fig (3) [11].

The study of Kuccukkaya et al., an extension rod was added to the Ilizarov frame, and all hip movements were fully restricted. This was done as a temporary, 3 week procedure to prevent pain and joint contracture in the postoperative period.[13]



**Fig (3)** Ilizarov frame with extension rod[13].

In the Ilizarov frame, through a 2-cm to 3-cm incision over the iliac crest, the crest is exposed and 3 shanz pins are placed in a convergent manner. The entry points of the pins are approximately 3 cms apart. All 3 pins are fixed to the pelvic arch, after this, 3 shanz pins are placed laterally at the subtrochanteric area, perpendicular to the anatomical axis of the femoral diaphysis, and fixed to another pelvic arch. An alternative to this step is to place 2 crossing Kirschner wires through the femoral condylar area which are also perpendicular to the anatomical axis, and fix these to a ring[11].

Kuccukkaya et al. placed shanz pins in the supra-acetabular area in addition to the iliac wing and the femoral diaphysis[11].

In the monoplane fixator, accurate alignment of the external fixator with its rotating axis in line with the hip joint flexion-extension arc is critical. The cortical half pins are placed in the pelvis, engaging the outer and inner tables [12].

The proximal or pelvic fixation can be accomplished either axially with a straight clamp or

transverse with a T-clamp attachment. The distal two cortical half pins are placed in the femoral diaphysis according to the template. The template is then removed and the actual fixator applied .

#### 2.4.1 Duration of the fixator:

According to Kocaoglu et al., the overall duration of the fixator in their series of patients ranged from 73-150 days with the average of 106 days[13].

In the study of Kuccukkaya et al., the mean duration of the fixator was 3.5 months [16].

#### 2.4.2 The post-operative period:

Patients are allowed to bear weight until the fixator is extracted. Hip movements are initiated as a part of the physical therapy program, movements start after removal of the extension rod if present. The patient's parents are educated about pin site care and rehabilitation program[11].

#### 2.4.3 Distraction rate in Perthes' disease:

According to Kocaoglu et al., distraction is started on the second post-operative day at a rate of 0.25mm four times per day, distraction is continued until the Shenton line is radiographically overcorrected by approximately 1-2mm, controlling the continuity of reduction[17].

Kuccukkaya et al. used distraction at a rate of 1 mm/day, performed 5mm of joint distraction[13].

**2.4.4 Removal of the fixator and after-treatment:**

When the formation of the lateral pillar is identified in control radiographs, the fixator is removed under general anesthesia, during the operation a gentle range of motion evaluation is performed, and contractures if present are corrected surgically, forced passive movement of the hip joint under general anesthesia is not recommended because of the risk of subchondral fractures, 2 days after fixator removal 50% weight bearing is allowed and rehabilitation of the hip and the knee range of motion is continued. The objective of this partial weight bearing is to prevent collapse and stress fractures through the pin holes. After 8 week rehabilitation program, full weight bearing is allowed[18,19].

**Table (1)** Results reported by different authors.

| Study                 | No. of cases | The mean age | Type of fixator                                | Duration of fixation | Outcome               |
|-----------------------|--------------|--------------|--|----------------------|-----------------------|
| Hosny et al., 2011    | 29           | 9.2years     | Ilizarov                                       | 2.5-5 months         | 27 cases had improved |
| Khanfour et al., 2011 | 30           | 9.7 years    | Ilizarov                                       | 4-5 months           | All cases improved    |
| Laklouk et al.2012    | 53           | 9.3 years    | -21 cases by Ilizarov<br>-32 cases by orthofix | 4-5 months           | 83.3% improved        |
| Singh et al., 2014    | 12           | 9.7 years    | orthofix                                       | 4 months             | All cases improved    |

**4.Discussion**

Rationale of Arthrodiastasis in Perthes' disease

The theory of stress and trauma:

It is thought that initially an ischemic episode creates osteonecrosis of the femoral head. Once the condition is established, revascularization and endochondral ossification begins to spread from the

peripheral to the central area of the necrotic bone. At this point the necrotic bone is removed, in turn, immature bone is produced during this period, which is called [creeping substitution]. There are no clinical manifestations in this period and Salter and Thompson refer to it as [potential Perthes' disease]. In this stage, the subchondral area of the femoral head becomes vulnerable and a subchondral fracture may easily occur if it is complicated by trauma. In the majority of children, this fracture is the result of normal vigorous activity, Tachdjian also suggests that normal muscular activity during bed rest or cast treatment can cause a subchondral fracture. The femoral head deformity that develops in Perthes' disease is believed to occur during this fragmentation phase, because the subchondral fracture is painful, Salter and Thompson call this period [true Perthes' disease].

removed under general anesthesia, during the operation a gentle range of motion evaluation is performed, and contractures if present are corrected surgically, forced passive movement of the hip joint under general anesthesia is not recommended because of the risk of subchondral fractures, 2 days after fixator removal 50% weight bearing is allowed and rehabilitation of the hip and the knee range of motion is continued. The objective of this partial weight bearing is to prevent collapse and stress fractures through the pin holes. After 8 week rehabilitation program, full weight bearing is allowed[18,19].

If the avascular necrosis of the femoral head is not complicated by subchondral fracture, the process is resolved by the resumption of endochondral

ossification with no clinical manifestations, deformity, subchondral collapse or subluxation.

After the subchondral fracture, a collapse of the trabecular bone structure occurs. This obliterates the vascular channels and creates the second ischaemic episode which is defined by [breakage of the process of creeping substitution],because the process of creeping substitution is blocked, the healing process of the femoral head avascular necrosis is prolonged, this creates a [vicious circle], where the healing of the necrosis is continually being slowed down by blocking creeping substitution [20].

The aim of articulated distraction in Perthes' disease is to neutralize muscle and weight bearing forces to prevent stress fractures of the immature subchondral bone, and to encourage synovial circulation, and promote creeping substitution by breaking the vicious circle of necrosis [21].

Effect on containment:

Kocaoglu et al. reported that arthrodiastasis can help to achieve containment in hips that are non-containable with the conventional methods and can relieve the hinge abduction. The containment could

also be maintained in the fixator as long as necessary [11].

### 5. Conclusions

Arthrodiastasis or articulated distraction of the hip either alone or with soft tissue release proved to be a good contribution to the lines of treatment of Perthes' disease. Its advantages include: Easy technique, Safe technique with minimal complications, Short hospital stay, Less limitation of activity in comparison to other treatment modalities of Perthes' disease.

### References

- [1] A.R.Amer, A.A.Khanfour, "Arthrodiastasis for late onset Perthes' disease using a simple frame and limited soft tissue release: early results." *Acta Orthop Bleq*, Vol.77(4), PP.472-9, 2011.
- [2] G.A .Hosny , "Articulated distraction" *Orthop Clin N Am*, Vol.42, PP.361–364, 2011.
- [3] G.A.Hosny, El-DeebK, FadelM, M.A.Lakloulk , "Arthrodiastasis of the Hip" *Journal of Pediatric Orthopaedics*, Vol.31, PP.S229–S234, 2011.
- [4] M.A.Lakloulk, G.A.Hosny, " Hinged distraction of the hip joint in the treatment of Perthes disease: evaluation at skeletal maturity." *J Pediatr Orthop B*, Vol.21(5), PP.386-393, 2012.
- [5] J.Canadell, F.Gonzalez, R.H.Barrios, S.Amillo, Arthrodiastasis for stiff hips in young patients. *International Orthopaedics*, Vol.17, PP.254-258, 1993.
- [6] J.J.Gagnier, H.Huang, M.Mullins, D.Marinac-Dabic, A.Ghambaryan, B.Eloff, F. Mirza, M.Bayona, Measurement properties of patient-reported outcome measures used in patients undergoing total hip arthroplasty: a systematic review. *JBJS reviews*, Vol.6(1), PP.22-29, 2018.
- [7] N.C.Lopez, Treatment of Legg-Calve-Perthes' disease utilizing Arthrodiastasis with Ilizarov frame: clients netsivao nfrancac, Vol.44, PP.215-259, 2001.
- [8] M.Thacker, D.Feldman, S.Madan, J.Straight, D.Scher, Hinged distraction of the adolescent arthritic hip: *Journal of Paeditric Orthopaedics*, Vol.25, PP.178-182, 2005.
- [9] D.Tönnis, Congenital dysplasia and dislocation of the hip in children and adults. *Springer Science & Business Media*; Dec 6 , Vol.3, PP.102-111, 2012.
- [10] JA.Gomez, H.Matsumoto, Jr. D.P. Roye, M.G.Vitale, J.E.Hyman, H.J.Van Bosse, S.Marangoz, D.A.Sala, M.I.Stein, D.S.Feldman, Articulated hip distraction: a treatment option for femoral head avascular necrosis in adolescence. *Journal of Pediatric Orthopaedics*, Vol. 29(2), PP.163-9, 2009.
- [11] S.L.Maxwell, K.J.Lappin, W.D.Kealey, B.C.McDowell, A.P.Cosgrove, Arthrodiastasis in Perthes' disease: preliminary results. *The Journal of bone and joint surgery. British volume*, Vol.86(2), PP.244-50, 2004.
- [12] S.I.Maxwell, K.J.Lappin, W.D.Kealy, B.C.McDowell, A.D.Cogrove, Arthrodiastasis in Perthes' disease, preliminary results, *JBJS [Br]*, Vol.86(2), PP.244-50, 2004.
- [13] M.Kucukkaya, Y.Kabukcuoglu, I.Ozturk, V.Kuzgun, Avascular necrosis of the femoral head in childhood, the results of treatment with articulated distraction: *Journal of Paeditric Orthopaedics*, Vol.20, PP.722-728, 2002.
- [14] R.Aldegheri, G.Trivella, A.Saleh, Articulated distraction of the hip. *Clin Orthop*, Vol.301, PP.94-101, 1994.
- [15] A.R.Amer, A.A.KhAnFOuR, Arthrodiastasis for late onset Perthes' disease using a simple frame and limited soft tissue release: Early results. *Acta Orthopaedica Belgica*, Vol.77(4), PP.472-480, 2011.
- [16] D.V.Appleyard, J.R.Schiller, C.P.Eberson, M.G.Ehrlich, Idiopathic chondrolysis treated with etanercept. *Orthopedics*, Vol. 32[3], PP.47-54, 2009.
- [17] D.Tönnis, General radiography of the hip joint. In: *Congenital dysplasia and dislocation of the hip. Springer [English edition]*, Berlin, Vol. 23(2) PP.100–142, 1986.
- [18] D.R.Wenger, W.T.Ward, J.A.Herring, Current concept review Legg-Calve-Perthes' disease. *JBJS*, Vol.73-A, PP.778-782, 1991.
- [19] F.Lafeber, J.P.Veldhuijzen, J.L.Vanroy, O.Huber Bruning, J.W.Bijlsma, Intermittent hydrostatic compressive force stimulates exclusively the proteoglycan synthesis of osteoarthritic human cartilage. *British Journal of Rheumatology*, Vol.31 (7) , PP.437-42, 1992.
- [20] D.S.Epstein, R.C.Hamdy, Articulated Hip Joint Distraction. In *Pediatric Pelvic and Proximal Femoral Osteotomies. Springer, Cham*, Vol. 14(1) , PP.421-430, 2018.
- [21] Y.Kalairajah, K.Azurza, C.Hulme, S.Molloy, K.J.Drabu, Health outcome measures in the evaluation of total hip arthroplasties a comparison between the Harris hip score and the Oxford hip score. *J Arthroplasty*, Vol.20, PP.1037-1042, 2005.