

Changes in the Patellar Height Following Open Wedge High Tibial Osteotomy

Hatem E. Elgohary^a, Abd Al Rahman Z. Al Shewehi^a, Hesham A. Al Attar^b, Samir M. Zahed^b

^a Department of orthopedic surgery, Faculty of medicine, Kafr elsheikh University, Egypt. ^b Department of orthopedic surgery Benha faculty of medicine, Benha University, Egypt.

Correspondence to: Abd Al Rahman Z. Al Shewehi, Department of orthopedic surgery, Faculty of medicine, Kafr elsheikh University, Egypt.

Email:

redoctober600@yahoo.com

Received: 16 August 2019

Accepted: 17 May 2021

Abstract:

Background: Genu varum of the knee is a predisposing factor for osteoarthritis of the medial femoro-tibial compartment. High tibial osteotomy is the surgery of choice for such patients. Patello-femoral abnormalities have a negative effect on the prognosis of high tibial osteotomy. Both pre-existing patellar pain and patello-femoral joint space narrowing are reported to be more severe after high tibial osteotomy. The idea of high tibial osteotomy is to unload an overloaded compartment, to slow down the progress of osteoarthritis and to allow healing of articular cartilage. **Aim of this work:** was to assess and analyze the changes in patellar height after medial open wedge high tibial osteotomy. **Patients and Methods:** This was a prospective and retrospective case series study performed in the period from 2011 till 2019 on 30 patients at Kafr El Sheikh University Hospital. The age ranged between 19-54 years. There was 16 male (53.33%) and 14 females (46.66%). In 19 knees the left side was affected (63.33%), 11 knees (36.66%) on the right side and three bilaterally (10%). **Results:** After medial opening wedge high tibial osteotomy and measurement the patellar height preoperatively and postoperatively, we found the patellar height on the Caton-Deschamps ratio method the patella was lowered in 22 cases, remained constant in 8 cases.

Key-words: Genu varum, Patello-femoral joint, High tibial osteotomy.

Introduction:

Knee osteoarthritis (OA) is a disease common in older adults that can result in significant disability because of pain, stiffness, and loss of joint motion. Current treatment is aimed at minimizing pain,

maintaining or improving joint mobility, and decreasing functional impairment. Although the pathogenesis of knee OA is not well understood, biomechanical stresses that affect the articular cartilage and

subchondral bone have been implicated as important inciting factors.^[1-3]

Varus angulation deformity results in medial compartment knee OA and contribute to the progression of OA by causing increased load to the medial knee compartment, with subsequent damage to the articular cartilage and subchondral bone in that area.^[4]

Medial opening wedge osteotomy is a relatively simple procedure that involves a single osteotomy and few dissections. The technique does not necessitate either a fibular osteotomy that has been associated with neurovascular complications or bone resection of lateral tibia. Accordingly, the normal anatomical tibial bone shape is maintained after the procedure, which allows for conversion to TKA. The level of correction can be identified and adjusted intraoperatively on coronal and sagittal planes and shortening of lower limbs can be prevented.^[5]

High tibial osteotomy is the surgery of choice for such patients. Patello-femoral abnormalities have a negative effect on the prognosis of high tibial osteotomy. Both pre-existing patellar pain and patello-femoral joint space narrowing are reported to be more severe after high tibial osteotomy.^[6-7]

The idea of high tibial osteotomy (HTO) is to unload an overloaded compartment, to slow down the progress of OA and to allow healing of articular cartilage. To obtain successful results in HTO not only requires the application of a good surgical technique but also depends on appropriate patient selection.^[8-9]

Description of this technique is dating back to the 50s, with Jackson and Dehaven. However, it was not until the 70s, with the publications of Coventry and Insall, that high tibial osteotomy became common practice.^[9-11] At that time, closing wedge osteotomies were performed, despite the greater technical difficulty and risks involved, as there were no fixation materials available that could enable opening wedge osteotomy. Only after the development of medial wedge plate fixation that opening wedge osteotomy became applicable.^[12]

Research regarding the effects of HTO on the patellofemoral joint has shown an alteration of patellar height. The change in patellofemoral indices, patellar height, patellar tilt and patellar shift can be a potent cause of deranged patellofemoral kinematics and subsequent patellofemoral arthrosis. Patellar infera is associated with a decreased range of motion, a decreased lever arm, extensor lag, anterior knee pain, increased energy expenditure and a

possibility of rupture of patellar or quadriceps tendons.^[13-15]

The principal causes of change of patellar height with medial opening wedge high tibial osteotomy are known to be from patellar ligament scarring, distal transfer of the tibial tubercle and the elevation of tibiofemoral joint line.^[16]

Aim of the work

A prospective and retrospective study to assess and analyze the changes in patellar height after medial open wedge high tibial osteotomy.

Patients and Methods:

a. Patients:

Our study was performed in Kafr El Sheikh University Hospital, Orthopedic Department, during the period 2018-2019 on 30 patients. There were 16 males and 14 females with an age range of 19-54 years.

Preoperative inclusion criteria included:

1. Medial uni-compartmental osteoarthritis with lower extremity varus malalignment.

Preoperative exclusion criteria included:

1. Mal-united tibial or femoral fractures that need correction by high tibial osteotomy.

2. Lower limb varus deformities that need intervention other than high tibial osteotomy.
3. Failed high tibial osteotomy.
4. Old aged patient more than 60 years old

Demographic data:

Age:

The age ranged from 19 to 54 years with a mean age of 40.77 years.

Sex:

There were 16 males (53.33%) and 14 females (46.66%).

Side affected:

In this work the left knee was affected in 19 patients (63.33%) while 11 patients (36.66%) complained of their right knee and there was bilateral affection in three patients (10%).

Occupation:

There were 14 workers (mainly farmers) (46.66%), 4 teachers (13.33%), 2 students (6.66%) and 10 were house wives (33.33%).

b. Methods

All patients were subjected to thorough clinical and radiological examination according to the following sheet

Methods of examination:

1. Personal data:

- A. Name.
- B. Age.
- C. Sex.
- D. Side affected.
- E. Occupation.

2. History:

- A. Onset and duration of the disease.
- B. Whether activity is affected or not.
- C. Aggravating factors.
- D. Pain.
- E. Swelling.

3. General Examination:

- A. Body weight.
- B. Gait.

4. Knee examination:

- A. Inspection while standing.
- B. Range of motion.
- C. Tenderness and its site.
- D. Effusion.
- E. Presence of ligamentous laxity.
- F. Quadriceps muscle wasting.

5. Radiological evaluation:

- Plain radiographs ; All patients' knees were subjected to:

- 1. AP view in a standing position.
- 2. Lateral view in 30 degrees flexion.
- 3. Skyline' view knee flexion 45 degrees.
- 4. Weight bearing leg film from hip to ankle of both lower limbs in standing AP view to identify the site of deformity (whether femoral or tibial).

The femoral mechanical axis is drawn from the center of femoral head to the center of the knee. A tangent is then drawn along the distal femoral condyles. The mechanical lateral distal femoral angle (mLDFA) is then measured between those two lines. Normal values for this angle usually range from 85 to 90, with values greater than 90 degrees indicating varus of the distal femur. Thereafter, the axis of the tibia is drawn, and another line tangential to the tibial plateau. Between those two lines the medial proximal tibial angle (MPTA) is measured. Normal values for this angle are identical to those of the mLDFA (i.e 85-90), with values less than 85 indicating varus of the proximal tibia.

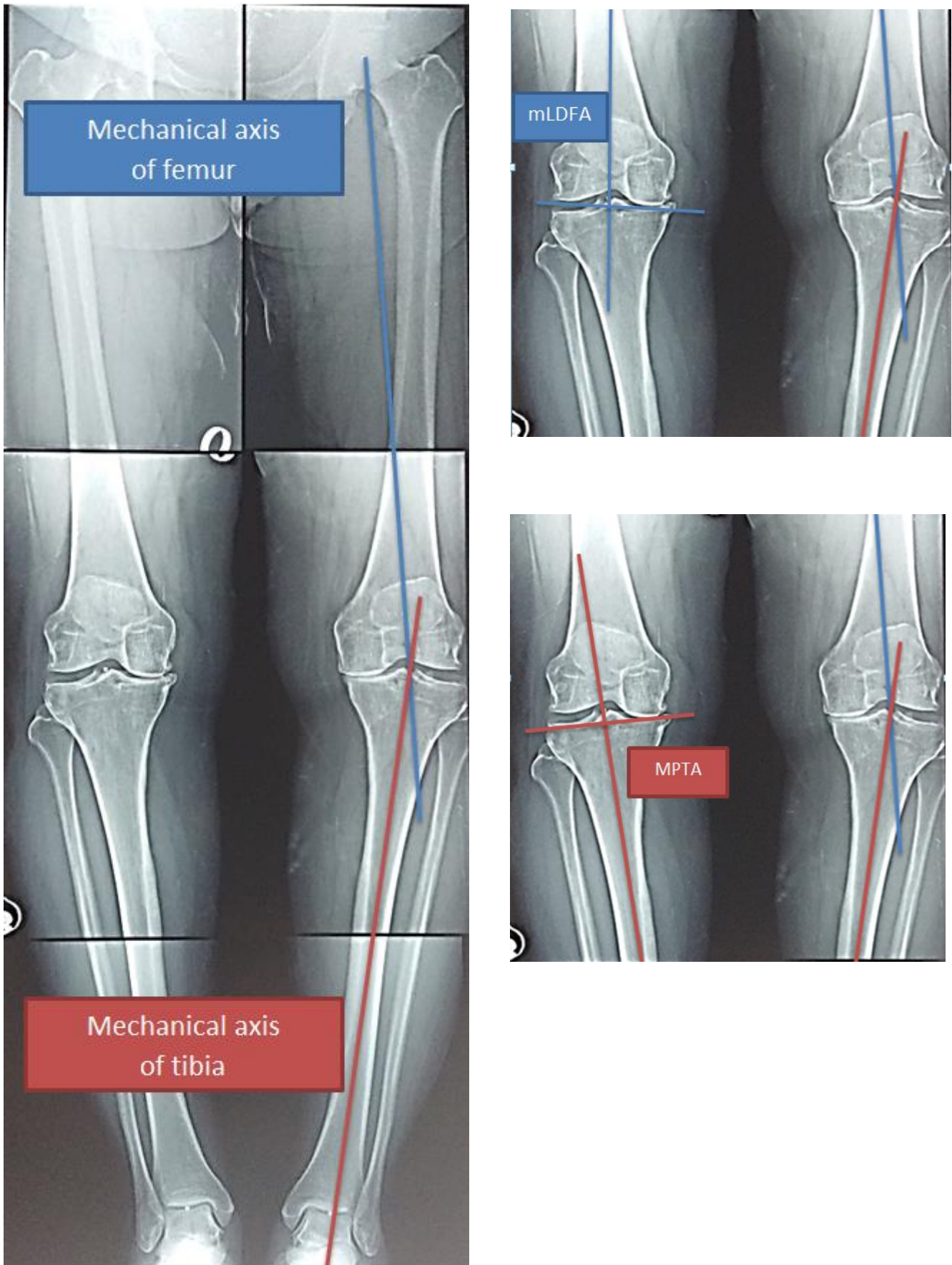


Figure [1]: Calculation of femoro-tibial angle, mL DFA and MPTA

Methods of treatment:

All patients were treated using medial open wedge high tibial osteotomy with fixation using the appropriate size of Puddu plate.

Technique: Medial opening wedge osteotomy The patient was positioned supine on a radiolucent operating table allowing intra-operative fluoroscopic visualization. The patients were given a spinal analgesia and a thigh tourniquet was applied to the operative limb, fourth generation cephalosporin antibiotics were administered just before inflating the tourniquet to 450 mmHg. Then standard limb preparation and draping was performed.

A vertical incision, six cm in length, was made about three cm medially from the tibial tubercle and started about four cm from the medial joint line. The sartorial fascia was incised and the superficial medial collateral ligament was identified.

The c-arm was manipulated until a true AP of the knee was visualized. Two 3.0mm K-wires were passed obliquely under image intensifier guidance from the metaphyseal flare of the proximal medial tibia towards the head of the fibula, in which one of them lies anterior and the other posterior. The osteotomy is always done beneath the guide wire to protect the joint.

An oscillating saw was then passed under image guidance from medial to about one cm away from the lateral cortex staying proximal and in direct contact with the two K-wires. The anterior and posterior cortices were then osteotomized in the same plane, guided by the K-wires and the broad tissue elevators were kept to protect the posterior neurovascular structures and the patellar tendon throughout the procedure.

At all times, when using the saw, saline lavage was employed to prevent local soft tissue damage. The osteotomy was then done using stacked osteotomes slowly inserted under image guidance from medial to lateral to within one cm of the lateral cortex; the osteotomy was opened with a valgus force until the desired degree of opening was obtained.

At this point the osteotomy was fixed using a Puddu plate, which was applied to the proximal tibia using two cancellous screws and distally using two cortical screws.

The subcutaneous tissues and skin were then closed using interrupted sutures over a negative pressure suction drain. A standard dressing and a bandage were used over the wound and a hinged knee brace applied with analgesia and I.V fourth generation cephalosporin antibiotic prescription for one week.

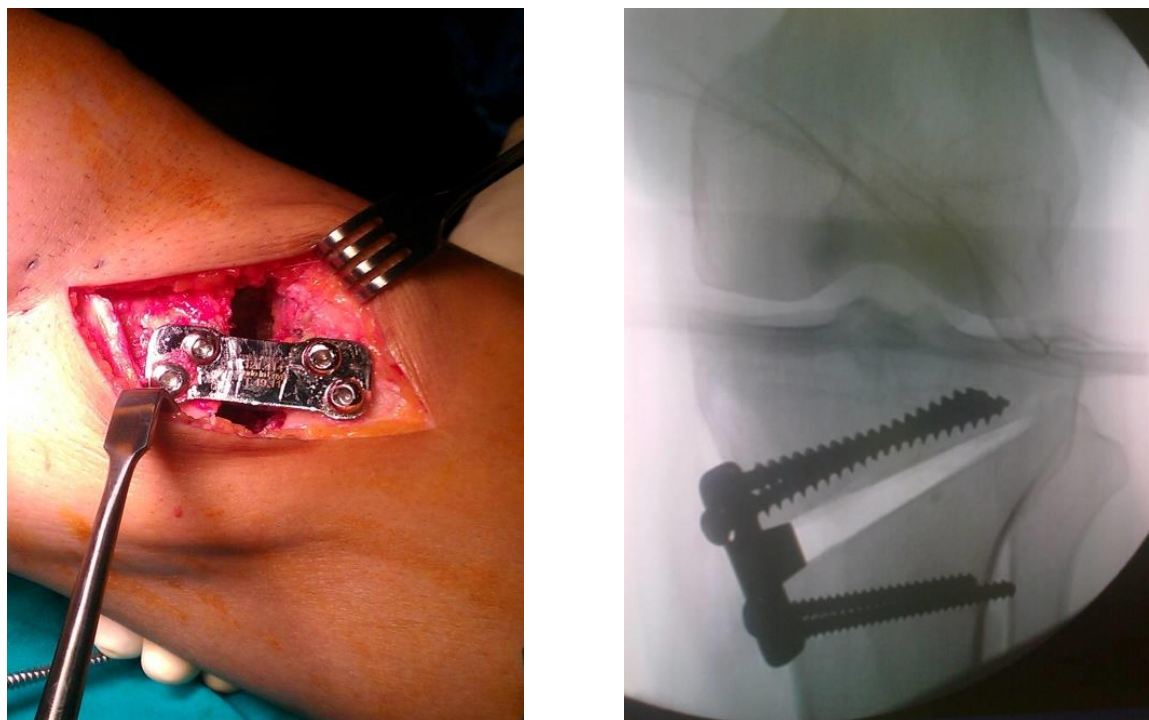


Figure [2]: The Puddu plate

Postoperative management:

All patients were instructed to perform gentle active exercises with assisted weight bearing using crutches for at least 2 months.

Radiographic check was obtained to assess correction and union in both AP and lateral views in repeated outpatient clinic visits.

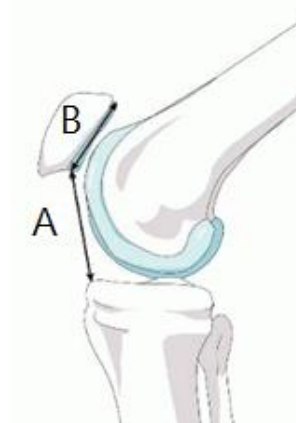
Methods of assessment of the results:

Radiographs were evaluated for the patellar height: Classified as Alta, Norma or Infra according to the values by the Caton-Deschamps ratio method.^[17]

Plain X ray lateral view in 30 degrees flexion then measures the distance between the distal point of the patellar articular

surface and the anterosuperior border of the tibia divided by the length of the articular surface of the patella.^[17]

Method	Patella	Patella	Patella
	Alta	Norma	Infra
Caton-Deschamps	> 1.2	0.8-1.2	< 0.8



Methods of statistical analysis:

Data entry into the computer was done followed coding, processing and analyzing. Analysis was done using SPSS-20.0 (Statistical package for Social Sciences version 20.0) and the results were considered significant when the P value was less than **0.05**

Informed consent:

Study protocol was submitted for approval by IRB, an approval of local ethics

committee of Kafr Elsheikh University in which the study was conducted was obtained before initiation of the study, informed verbal consent was obtained from each participant shared in the study, Confidentiality and personal privacy was respected in all the levels of the study .

Case example

A 49 year-old-male, works as a mechanic, complaining of pain in the medial compartment of the left knee joint after excessive activities.

Preoperative planning data:

Tibio femoral angle (TFA)	173 °
Varus angle	7 °
Lateral Distal Femoral Angle - (mLDFA)	87.5 °
Medial Proximal Tibia Angle – (MPTA)	85 °

Operative data:

Type of osteotomy	Oblique
Plate type	Puddu plate
Plate size	12
Plate site	Posteromedial
Arthroscopic finding	Complex tear of the posterior horn of medial meniscus

Perioperative Patellar Height Measurements

Using the Caton-Deschamps index:

Preoperative Patellar Height	1.3
postoperative Patellar Height	1

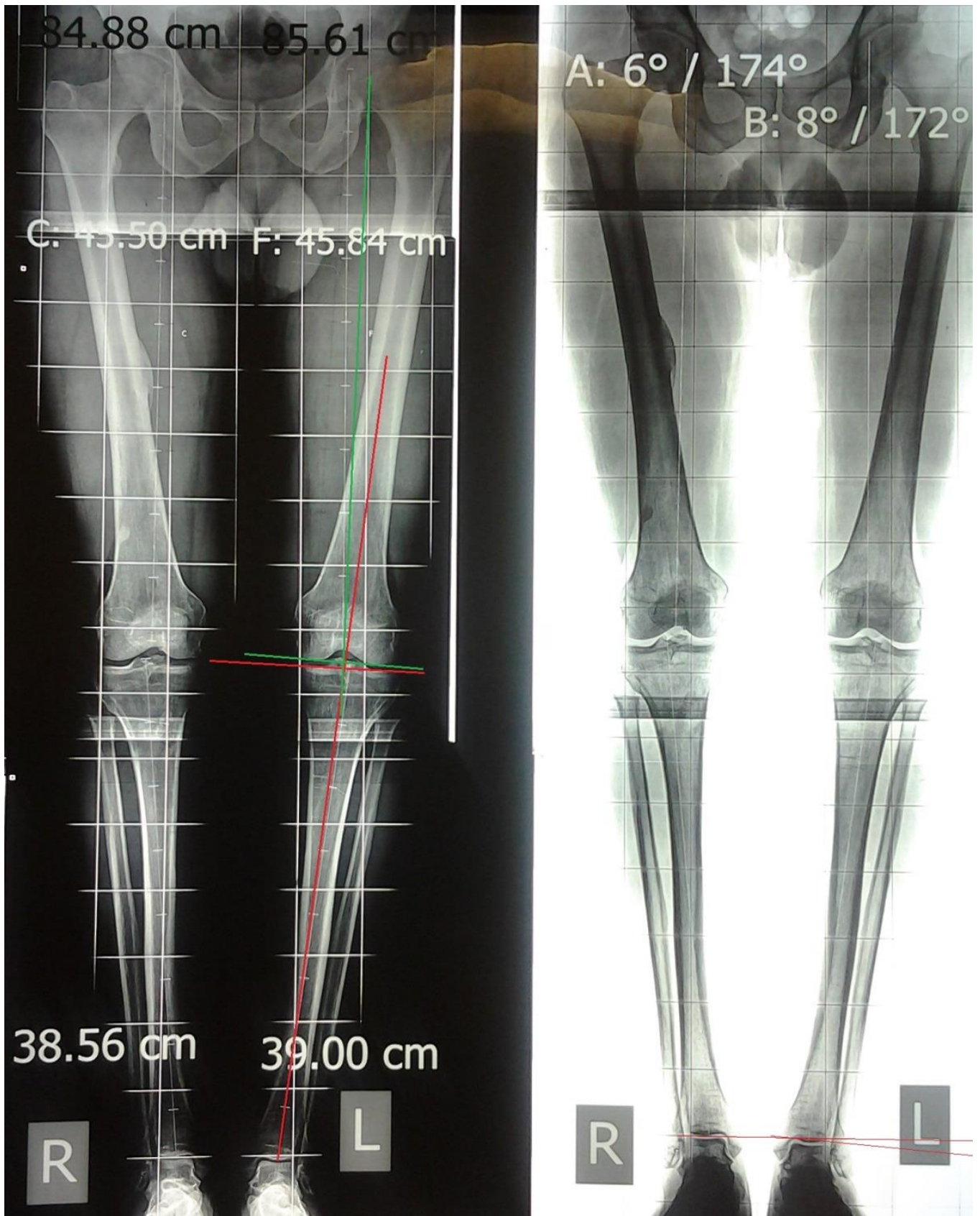


Figure [3]: Stitching films of both lower limbs

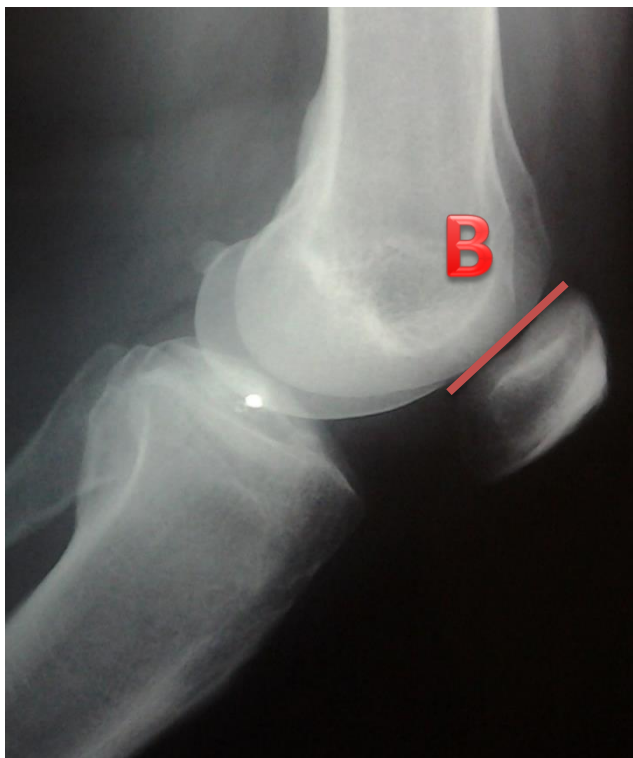

Figure [4]: Preoperative Plain X ray in lateral view shows patellar height measurement

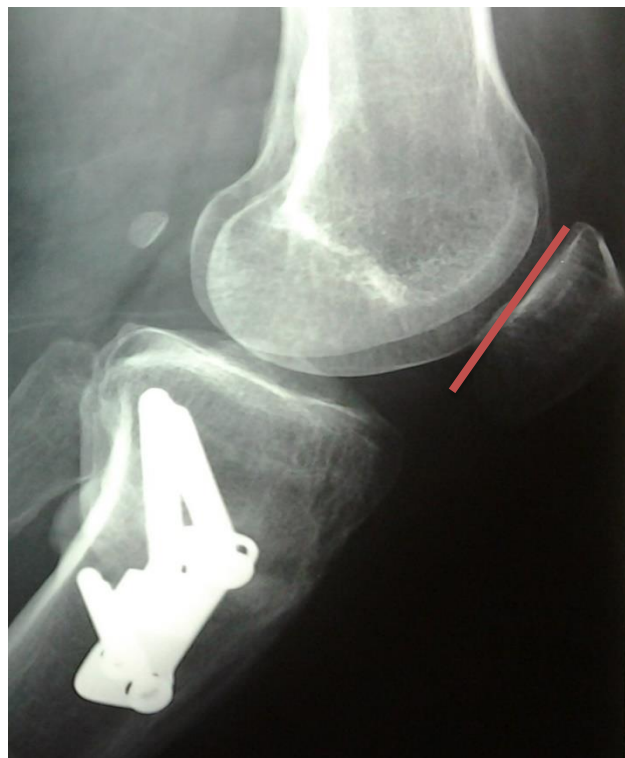

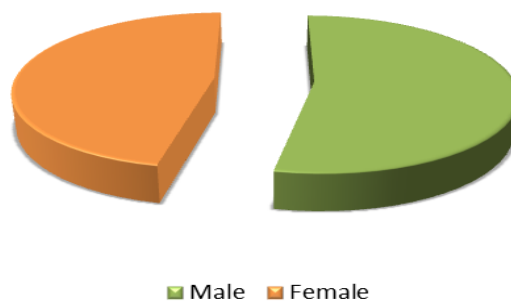
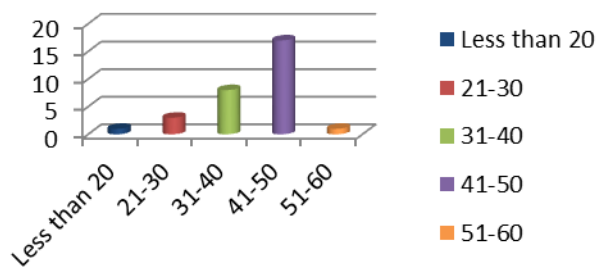
Figure [5]: Postoperative Plain X ray in lateral view shows patellar height measurement

Results:

This work involved the study of a prospective and a retrospective case series including 30 patients admitted to kafr el sheikh university hospital with medial compartment knee OA who were treated using a medial open wedge high tibial osteotomy.

Assessment of Personal data: The mean age was 40.77 ± 8.86 (range 19-54 years). There were 16 males (53.33%) and 14 females (46.66%). In 19 patients the left side was affected (63.33%), 11 patients (36.66%) the right side was affected and 3 patients were bilaterally affected (10%).

Age Distribution



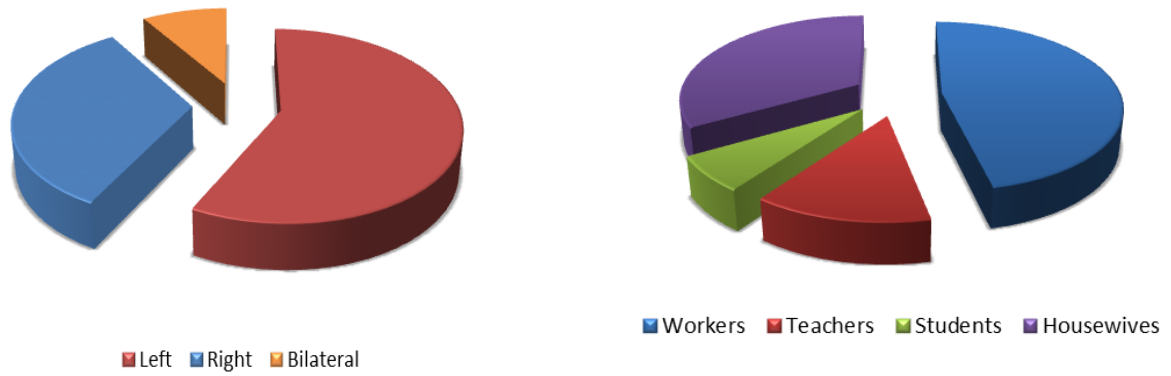


Table [1]: Personal data of the studied patients

Age (years)	n	%
Less than 20	1	3.33
21 - 30	3	10
31 - 40	8	26.66
41- 50	17	56.66
More than 50	1	3.33
Gender		
Male	16	53.33
Female	14	46.66
Side affected		
Left	19	63.33
Right	11	36.66
Bilateral	3	10
Occupation		
Workers	14	46.66
Housewives	10	33.33
Students	2	6.66
Teachers	4	13.33

Assessment of Pre-operative varus deformity:

The mean pre-operative varus deformity (Mechanical femoro-tibial angle) as measured on the AP standing stitching films was 11.8 ± 3.65 (range, 4-18 degrees).

The mean mL DFA was 92.20 ± 2.69 (range, 86.0 – 96.0) and the mean MPTA was 82.25 ± 3.48 (range, 73.0 – 87.0)

Table [2]: Clinical and radiographic aspects of the studied knees

Clinical characteristics	Studied knees (n=30)	
Degree of varus deformity		
Min-Max	4-18	
Mean \pm SD	11.8 \pm 3.65	
Radiological evaluation	Studied knees(n=30)	
	Min-Max	Mean \pm SD
Mechanical lateral distal femoral angle (mL DFA)	86.0 – 96.0	92.20 \pm 2.69
Medial proximal tibial angle (MPTA)	73.0 – 87.0	82.25 \pm 3.48

Assessment of operative data:

1- Method of fixation:

Table [3]: Details of operative data

Operative characteristics	Studied knees (n=30)	
	n	%
Type of plate		
Puddu plate	24	80
Assal plate	4	13.33
TomoFix plate	2	6.66
Size of Puddu plate		
8	1	4.16
10	6	25
12	9	37.5
14	7	29.17
16	1	4.16

2- Preoperative Patellar Height: The mean preoperative patellar height was 0.92 ± 0.2 , Range (0.5 to 1.3)

4- Patellar Height change: The mean patellar height change was 0.13 ± 0.13 , Range (0 to 0.6)

3- Postoperative Patellar Height: The mean postoperative patellar height was 0.79 ± 0.14 , Range (0.5 - 1.1)

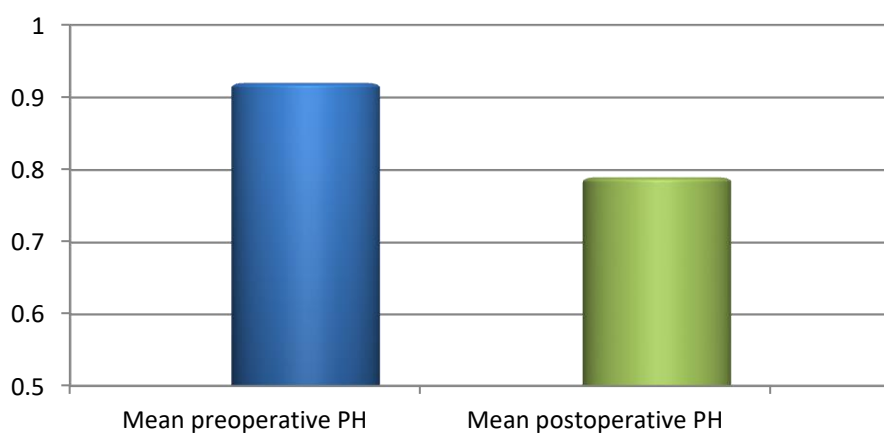


Figure [7]: Difference in pre and postoperative patellar height

Analytic Statistics:

1- Correlation between pre and postoperative patellar height:

There was significant decrease of patellar height from (mean 0.92 ± 0.2 , range: 0.5 to 1.3) preoperatively to (mean 0.79 ± 0.14 , range: 0.5 to 1.1) postoperatively; this difference was statistically highly significant (Z: 4.168, P value: <0.00).

Table [4]: Correlation between preoperative and postoperative PH change

		Preoperative	Postoperative	Z	P
PH Change	Mean ± SD	0.92 ± 0.2	0.79 ± 0.14	4.168*	0.000**
	Min-Max	0.5 to 1.3	0.5 to 1.1		

*Z: Wilcoxon Signed Ranks

**P: significant <0.05

2-Correlation between patellar height change and size of the Puddu plate: There was strong positive correlation between size of the puddu plate and patellar height

change after surgery compared with preoperative levels. (Rho 0.957, P value: 0.00)

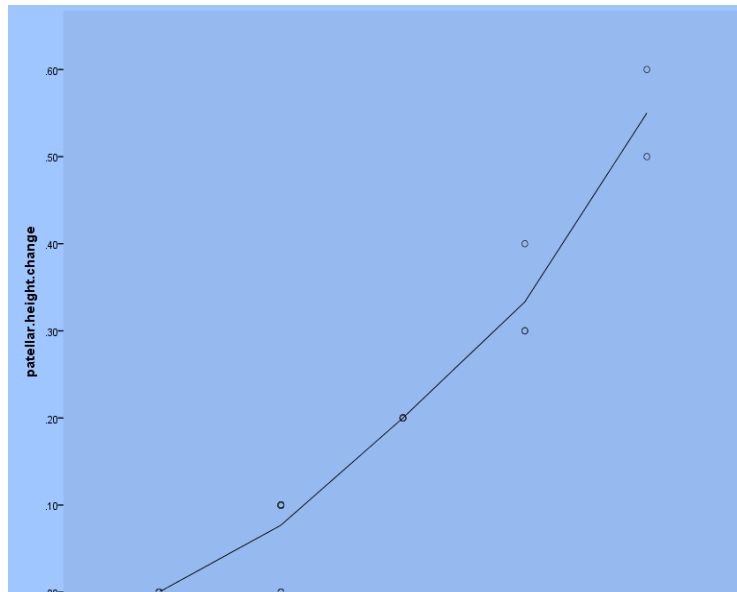


Figure [8]: Correlation between patellar height change and size of the Puddu plate

Discussion:

In normal knees, approximately 60% of weight bearing forces is transmitted through the medial compartment and 40% through the lateral compartment. In varus knees, more loads are transmitted to the medial compartment leading to arthritic changes in this compartment. High tibial osteotomy is a classic operation to treat such deformity and redistribute loads. [18]

Earliest techniques of high tibial osteotomy were developed by Jackson in 1965. [19]

They were all in the form of lateral closing wedge osteotomy. The medial opening wedge osteotomy came about 20 years later by Hernigou in 1987. [20] Puddu plate was developed by 1990 to provide additional stability to the osteotomy. [18]

The success of the osteotomy does not depend exclusively on the appropriate selection of patients, but also on the use of a good surgical technique. The use of a stable osteotomy fixation material greatly influences the results of this technique.

Seeking to provide a stable fixation of the open wedge osteotomy, various plates were developed, such as the Puddu plate. [21]

In this study, 30 patients were involved. Their mean age was 31.93 (range, 19-54 years). In 24 cases medial opening wedge osteotomy was done and fixed by Puddu plate which varied in size from 8 mm to 16 mm (14 and 10 mm were most commonly used). In 4 cases El Assal plate was used with varied size from 10 mm to 14 mm, two osteotomies were fixed by TomoFix plate fixator. Our final results were comparable to the literature.

Method of fixation:

The use of short wedge plates as Puddu plate should be confined to a stable situation with an intact lateral hinge in selected patients who are not obese and with good bone quality. The use of longer locking compression plate systems as Tomofix can provide an obvious advantage in patients who are obese, with questionable bone quality, in large corrections and in the unstable situation following fracture of the lateral tibial cortex. [22]

A study compared the biomechanical properties of the modified Puddu plate and the TomoFix plate. The authors concluded that both plates create immediate stability, but with a lateral hinge fracture the TomoFix plate showed enough residual

stability, while the Puddu plate required additional lateral fixation. [23]

Use of pre-operative arthroscopy:

During arthroscopy, debridement of the degenerate tissues and meniscal tears if present was performed. Arthroscopy also serves to verify the integrity of the lateral compartment articular cartilage. If there is affection of the articular cartilage of the lateral compartment the decision to proceed with medial opening wedge high tibial osteotomy was cancelled. Pre-operative arthroscopic evaluation was done in 23 knees (76.6%) to detect and treat any intra-articular pathology prior to the osteotomy. Of them 20 knees had positive findings in the form of medial meniscal tears and chondral damage of the medial femoral condyle.

El-Azab et al, performed pre-osteotomy arthroscopy in all patients and partial meniscectomy was performed in 26 patients, micro-fracture in 3 patients, and shaving and debridement in 4 patients. [24]

Intra-operative assessment:

Many techniques were described to assess the limb alignment intra-operatively, such as visual inspection, cable method, and grid board or navigation system. However, all of these methods ignore the effect of weight bearing and ligamentous laxity on the mechanical axis of the lower limb. In this

work, visual inspection and the cable method were used in the 30 knees.

All patients were divided into two groups: corrected (24 knees) and under corrected group (6 knees) depending on the size of Puddu plate used in relation to the pre-operative measurement. In the under corrected group the Puddu plate size was 2mm less than the pre-operative measured deformity and that was due to reaching adequate clinical alignment by the cable method or starting of lateral cortex cracking.

The same methods were used before ^[24], however they had an overall inaccurate correction in 14% of cases, which underlines the effect of soft tissue slackness or laxity on the measurement of mechanical axis.

Effect of medial opening wedge high tibial osteotomy on PH:

The main aim of our study was to find out the effect of medial opening wedge high tibial osteotomy on patellar height. Our study confirmed that the medial open wedge high tibial osteotomy is accompanied by reduction of the patellar height.

There are many different justifications for this occurrence: shortening of the patellar tendon due to interstitial scarring due to surgical manipulation, bone neoformation at the insertion of the patellar tendon and

relative shortening after tibial translation due to change to the slope of the tibial plateau following osteotomy as postulated before^[25]

Decreased patellar height can be a combined effect of shortening of the patellar tendon, distalization and lateralization of tibial tuberosity and elevation of the tibiofemoral joint line.^[16]

It was reported earlier ^[26] that 100% of the studied patients presented with a decrease in patellar height. They hypothesized that medial opening wedge high tibial osteotomy when performed above the level of tibial tubercle increases the relative distance between tibial tubercle and tibial articular surface. This rearrangement of osseous structures repositions the patella distally in relation to femoral trochlea and accounts for decreased patellar height.^[26]

The Caton - Deschamps index has generally been used to evaluate patellar height, The index ratio for normal patellar height is between 0.6 and 1.3, patella infera is diagnosed if the index is equal to or below 0.6 while patella alta is diagnosed if index is equal to or more than 1.3.^[27]

Although Insall-Salvati index is the most widely used method, it does not reflect patellar height but rather is an index of patellar tendon length.^[27]

Blackburne-Peel index has the lowest inter observer variability; it has a critical limitation in evaluating a change in patellar height after high tibial osteotomy which is that BPI may depend on a change in posterior tibial slope, which occurs in opening wedge high tibial osteotomy. [27]

The CD index appeared to be the most interesting in analyzing the present results. It shows better reproducibility, and also distinguishes between low patella and patella infra. In the present study, all patellae that were preoperatively in the lower region for low patellae (CD near 0.6) proved infra at follow up visits and clinically associated with anterior knee pain. [27]

The most important finding of this study was that after medial opening wedge high tibial osteotomy, the patella was lowered.

In this study, 30 patients were involved; the mean difference in patellar height after opening wedge high tibial osteotomy was 0.13 indicating that opening wedge HTO decreased patellar height by 13 % after surgery compared with preoperative levels. These results are consistent with previously published results in the literature.

Of 23 studies done, 1150 knees underwent opening wedge HTO. The patellar height measured by CDI showed a 10% decrease [28]

Studies performed on 264 knees, reported that the mean difference in patellar height after opening wedge HTO was 0.10 indicating that opening wedge HTO decreased patellar height by 10 % after surgery compared with preoperative levels. [29-30]

In another research which studied 50 knees, reported that the mean difference in patellar height after opening wedge high tibial osteotomy was 0.12 indicating that opening wedge HTO decreased patellar height by 12 % after surgery compared with preoperative levels. [31]

In a different research which studied 130 knees, it was reported that the mean difference in patellar height after opening wedge high tibial osteotomy was 0.14, indicating that opening wedge HTO decreased patellar height by 14 % after surgery compared with preoperative levels. [32]

The rehabilitation program:

All our patients were instructed to perform gentle active exercises and partial weight bearing for 6 weeks.

Patients, in one study, were mobilized on the first post-operative day. Partial weight bearing was allowed for 6 weeks. During the early post-operative period, all patients received physiotherapy in the form of

mobilization, continuous passive motion, and isometric exercises.^[24]

The limitations of this study should be noted:

1. This study was based on radiological values. Thus, the correlations between the patellar height and clinical outcome were not evaluated.
2. No control group.
3. No postoperative assessment of the degree of correction of the mechanical axis deviation due to logistic and financial reasons.
4. Small number of patients.

Conclusion:

High tibial osteotomy using the medial opening wedge technique causes reduction in patellar height due to relative joint line elevation and obliquity and it may be almost inevitable after this type of osteotomy.

References:

1. Baliunas AJ, Hurwitz DE, Ryals AB, Karrar A, Case JP, Block JA, et al.: Increased knee joint loads during walking are present in subjects with knee osteoarthritis. *Osteoarthritis Cartilage* 2002; 10(7):573-579.
2. Sharma L, Cahue S, Song J, Hayes K, Pai YC, Dunlop DD: Physical functioning over three years in knee osteoarthritis: Role of psychosocial, local mechanical, and neuromuscular factors. *Arthritis Rheum* 2003; 48(12):3359-3370.
3. Jackson BD, Wluka AE, Teichtahl AJ, Morris ME, Cicutini FM: Reviewing knee osteoarthritis A biomechanical perspective. *J Sci Med Sport* 2004; 7(3):347-357.
4. Cerejo R, Dunlop DD, Cahue S, Channin D, Song J, Sharma L: The influence of alignment on risk of knee osteoarthritis progression according to baseline stage of disease. *Arthritis Rheum* 2002; 46(10):2632-2636.
5. Dong Chul Lee, Seong Joon Byun: High Tibial Osteotomy. *Knee Surg Relat Res* 2012; 24(2): 61-69.
6. Goutallier D, Delepine G, Debeyre J: The patello-femoral joint in osteoarthritis of the knee with genu varum. *Rev Chir Orthop Reparatrice Appar Mot* 1979; 65:25-31.
7. Hernigou P, Goutallier D: Outcome of the femoropatellar joint in osteoarthritic genu varum after tibial wedge osteotomy for angulation. 10 to 13 year regression. *Rev. Chir. Orthop. Reparatrice Appar Mot* 1987; 73:43-48.
8. Jackson JP: Osteotomy for osteoarthritis of the knee. *Proceedings and Reports of Universities Colleges, Councils and Associations, United States of America* March 1958. *The Journal of Bone and Joint Surgery* 1958; 40(4)826:301-620.
9. Coventry MB: Stepped staple for upper tibial osteotomy. *The Journal of Bone and Joint Surgery* 1969; 51(5)1011:440-475.
10. Coventry MB: Osteotomy about the knee for degenerative and rheumatoid arthritis. *The Journal of Bone and Joint Surgery* 1973; 55(1):315-390.

11. Insall JN: High tibial osteotomy in the treatment of osteoarthritis of the knee. *Surgery Annual* 1975; 7:347-359.
12. Puddu G: High tibial osteotomy. 4th World Congress on Sports Trauma 2004: 446-447.
13. Stoffel K, Willers C, Korshid O, Kuster M: Patellofemoral contact pressure following high tibial osteotomy: a cadaveric study. *Knee Surg Sports Traumatol Arthrosc* 2007; 15:1094-1100.
14. Flahiff CM, Kraus VB, Huebner JL, Setton LA: Cartilage mechanics in the guinea pig model of osteoarthritis studied with an osmotic loading method. *Osteoarthritis Cartilage* 2004; 12:383-388.
15. Backstein D, Meisami B, Gross AE: Patella baja after the modified Coventry-Maquet high tibial osteotomy. *J Knee Surg* 2003; 16:203-208.
16. Gaasbeek RD, Sonneveld H, Heerwaarden RJ, Jacobs WC, Wymenga AB: Distal tuberosity osteotomy in open wedge high tibial osteotomy can prevent patella infera: a new technique. *Knee* 2004; 11:457-461.
17. Caton J, Deschamps G, Chambat P, Lerat JL, Dejour H: Patella infera: apropos 128 cases. *Rev Chir Orthop Reparatrice Appar Mot* 1982; 68:317-325.
18. Cipolla M, Cerullo G, Franco V, Gianne E, Puddu G: Open Wedge High Tibial Osteotomy. *Techniques in Knee Surgery* 2012; 11(2): 68-77.
19. Coventry MB: Osteotomy of the upper portion of the tibia for degenerative arthritis of the knee. A preliminary report. *J Bone Joint Surg Am* 1965; 47:984-990.
20. Hernigou P, Medvielle D, Debeyre J, et al.: Proximal tibial osteotomy for osteoarthritis with varus deformity. A ten to thirteen- year follows up study. *J Bone Joint Surg Am* 1987; 69:332-354.
21. Lobenhoffer P, Agneskirchner JD: Improvements in surgical technique of valgus high tibial osteotomy. *Knee Surg Sports Traumatol Arthrosc* 2003; 11:132-138.
22. El-Assal MA , Yasser K , Mohamed A , Hatem S, Hatem G: Opening Wedge High Tibial Osteotomy without Bone Graft up to 14mm. *Knee Surg Sports Traumatol Arthrosc* 2010; 18: 961-966.
23. Stoffel K, Stachowiak G, Kuster M: Open wedge high tibial osteotomy: biomechanical investigation of the modified Arthrex Osteotomy Plate (Puddu Plate) and the TomoFix Plate. *Clin Biomech. Bristol, Avon* 2004; 19:944-950
24. EL-Azab H, Morgenstern M, Ahrens P, Schuster T, Imhoff AB, Lorenz S: Limb Alignment After Open-wedge High Tibial Osteotomy and Its Effect on the Clinical Outcome. *Orthopedics* 2011; 34: 622-628.
25. Kaper BP, Bourne RB, Rorabeck CH, Macdonald SJ: Patellar infera after high tibial osteotomy. *J Arthroplasty* 2001;16 (2):168-173.
26. Wright JM, Heavrin B, Begg M, Sakyrd G, Sterett W: Observations on patellar height following opening wedge proximal tibial osteotomy. *Am J Knee Surg* 2001; 14:163-173.
27. Berg EE, Mason SL, Lucas MJ: Patellar height ratios. A comparison of four measurement methods. *Am J Sports Med* 1996; 24:218-221.
28. Seong-Il Bin, Hyun-Jung Kim, Hyeong-Sik Ahn, Daniel Sungku Rim, Dae-Hee Lee: Changes in Patellar Height After Opening Wedge and Closing Wedge High Tibial Osteotomy: A Meta-analysis. *Arthroscopy: The Journal of Arthroscopic and Related Surgery* 2016: 1-8.

29. Amzallag J, Pujol N, Maqdes A, Beaufils P, Judet T, Catonne Y: Patellar height modification after high tibial osteotomy by either medial opening-wedge or lateral closing-wedge osteotomies. *Knee Surg Sports Traumatol Arthrosc* 2013; 21:255-259.
30. El Amrani MH, Levy B, Scharycki S, Asselineau A: Patellar height relevance in opening-wedge high tibial osteotomy. *Orthop Traumatol Surg Res* 2010; 96:37-43.
31. El-Azab H, Glabgly P, Paul J, Imhoff AB, Hinterwimmer S: Patellar height and posterior tibial slope after open- and closed-wedge high tibial osteotomy: A radiological study on 100 patients. *Am J Sports Med* 2010; 38:323-329.
32. La Prade RF, Oro FB, Ziegler CG, Wijdicks CA, Walsh MP: Patellar height and tibial slope after opening-wedge proximal tibial osteotomy: A prospective study. *Am J Sports Med* 2010; 38:160-170.

To cite this article: Hatem E. Elgohary, Abd Al Rahman Z. Al Shewehi , Hesham A. Al Attar , Samir M. Zahed Changes in the Patellar Height Following Open Wedge High Tibial Osteotomy. *BMFJ* 2021; 38 (orthopedic surgery): 66-85. DOI: 10.21608/bmfj.2021.15927.1035

