

## Efficacy of Cybele Scagel Phonophoresis on Post-Burn Hypertrophic Scar

Rofaida Mohie Eldeen Ali Sobh<sup>1</sup>, Haidy Nady Asham<sup>1</sup>,  
Sameh Mohammed El-Taheer<sup>2</sup>, Karim Ibrahim Saafan<sup>1</sup>

<sup>1</sup>Department of Physical Therapy for Surgery, Faculty of Physical Therapy, Cairo University, Egypt.

<sup>2</sup>Department of Plastic and reconstructive Surgery, Faculty of Medicine, Ain Shams University, Egypt.

\*Corresponding Author: Rofaida Mohie Eldeen Ali Sobh, Mobile: (+20) 01270214420,

E-mail: rofaida.sobh202m@yahoo.com

### ABSTRACT

**Background:** Hypertrophic scar (HTS) formation after burn remains a major issue for burned patients and is considered a huge problem for clinicians because the hypertrophic scar is painful, reddish, elevated, pruritic, and aesthetically unacceptable. **Objective:** To evaluate the therapeutic efficacy of Cybele Scagel phonophoresis on the treatment of hypertrophic scar post burn cases. **Patients and methods:** Thirty patients who had hypertrophic scar after wound closure with ages ranged from 20 to 45 years were selected randomly and divided into two equal groups in number (15 patients each). **Group A (study group):** received Cybele scagel phonophoresis, 3 sessions per week for 8 weeks (24 sessions), while patients in **group B (control group):** received topical cybele scagel for 8 weeks. Methods of assessment before and after the study included Modified Vancouver scar scale (VSS) to assess hypertrophic scar characteristics (height, vascularity, pigmentation and pliability) and digital imaging for visual assessment of the scars.

**Results:** the results of the study showed that between groups comparison, there was no significant difference in VSS between both groups pre-treatment ( $p > 0.05$ ). Comparison between group A and group B post-treatment revealed a significant decrease in VSS of the group A compared to that of group B ( $p > 0.05$ ).

**Conclusion:** It could be concluded that Cybele Scagel phonophoresis is an effective and safe modality that can be used for improving appearance of post burn hypertrophic scar.

**Keywords:** Post burn hypertrophic Scar, Cybele Scagel, Phonophoresis, Modified Vancouver Scale and Digital imaging.

### INTRODUCTION

After thermal injuries, hypertrophic scars are a serious problem. Scar contractures form and spread to the connective tissue beneath the skin, then to the muscles, reducing joint range of motion and interfering with daily activities<sup>(1)</sup>. The majority of superficial injuries do not leave visible scars, but deep cutaneous injuries can result in serious problems such as hypertrophic scars and keloids<sup>(2)</sup>. Depending on the depth of the wound, hypertrophic scarring rates range from 40 % to 70 % after surgery to up to 91 % after a burn injury<sup>(3)</sup>. Apart from a variety of personal issues, patients frequently report itching, redness, and hard nodular scar tissue, along with unusual sensations<sup>(4)</sup>. Hypertrophic scars and keloids can have a significant impact on patients' quality of life, physical status, and psychological health due to cosmetic issues, functional issues such as contractures, and patients' subjective complaints such as itching and pain<sup>(5)</sup>.

Transdermal drug delivery is a viable alternative to the traditional drug delivery methods of injection and oral administration. The stratum corneum, on the other hand, works as a barrier, preventing substances from penetrating the skin. The use of ultrasound on the skin improves its permeability (phonophoresis) and allows various substances to be delivered into and through the skin<sup>(6)</sup>. Phonophoresis is a non-invasive technique that converts electrical energy into mechanical energy using piezoelectric potential. In practice, this effect is obtained by using a therapeutic ultrasound apparatus to generate high-frequency oscillation sound waves (US).

This action provides a controlled and safe technique to increase the transdermal absorption of a wide range of ionizable drugs. As a result, many medications that are delivered to the surface layer of the skin, such as anti-inflammatories and analgesics, are potentiated as they penetrate deeper into the underlying tissue<sup>(6)</sup>. Scar-improving agents such as Allium cepa extract, Centella asiatica extract, Aloe vera extract, paper mulberry extract, and nanohydroxypropylsilane CN are among the herbal extracts plus silicone derivatives in Cybele Scagel (Bangkok Botanica, Bangkok, Thailand). It was created to prevent the formation of scars from surgical wounds<sup>(7)</sup>. This agent can decrease pain and itching after epithelialization of burn wound, as well as preventing hypertrophic scar formation following a burn injury<sup>(8)</sup>.

### PATIENTS AND METHODS

This study was carried out on thirty patients who had hypertrophic scar after wound closure and their ages ranged from 20 to 45 years. The participants were selected from Outpatient Clinic at Faculty of Physical Therapy, Cairo University. The patients were randomly divided into two equal groups in number (15 patients each). Group (A): the patients received cybele scagel phonophoresis, 3 sessions per week for 8 weeks (24 sessions). While, patients in group (B): received topical cybele scagel for 8 weeks. Methods of assessment pre-treatment and 2 months post-treatment for both groups included Modified Vancouver scar scale (VSS) to assess hypertrophic scar characteristics (height, vascularity, pigmentation and pliability) and digital imaging for visual assessment of the scars.



This article is an open access article distributed under the terms and conditions of the Creative Commons Attribution (CC BY-SA) license (<http://creativecommons.org/licenses/by/4.0/>)

**Ethical approval:**

The study’s protocol was approved by the Ethical Committee of Faculty of Physical Therapy, Cairo University. Each patient gave an informed consent before beginning of the study. This work has been carried out in accordance with The Code of Ethics of the World Medical Association (Declaration of Helsinki) for studies involving humans.

**Inclusion criteria:** The patients were selected according to the following criteria: both genders (males and females) shared in this study, their ages ranged from 20-45 years, all patients suffered from hypertrophic scars and were free from any other pathological conditions or histories except hypertrophic scars and all patients received the same approach of medication and received a good explanation of treatment and measurement procedures.

**Exclusion criteria:** The study was excluded the following criteria: patients who had open wound at or near the treatment site, patients who had skin abnormalities (i.e: psoriasis or carcinoma of the skin), patients who had autoimmune disease or any pathological conditions which may influence the outcomes, patients who had keloids, patients who had metallic implants at or near treatment site, uncooperative patients and who missed more than 3 sessions.

**Equipment:**

**Evaluation equipment**

**1. Modified Vancouver burn scar assessment scale:**

The Modified Vancouver burn scar assessment scale uses a numerical assessment of four skin characteristics including: Height (range, 0–4), Pliability (range, 0–4), Vascularity (range, 0–3), and Pigmentation (range, 0–3). The larger the number the worse is the scar. The assessors choose a numerical value for each of these characteristics based on a comparison with normal skin (9).

**2. Digital imaging:** Each wound site was photographed using Nikon COOLPIX B500 Digital Camera, 16.0 megapixels 40× optical zoom lens with a focal length of 4-160 mm.

**Therapeutic equipment:**

**1. Ultrasonic unit:** The therapeutic ultrasound device was Nonius Sonopuls 590 S.N 0.03-202 type 14663.900 (Enraf, Holland) used for phonophoresis.

**2. Cybele scagel:** With ultrasound device we used Cybele scagel, which is a combination of herbal extracts and a silicone derivative in a gel preparation.

**Evaluation procedures:**

The evaluation was conducted pre-treatment and post-treatment (after 2 months).

**1. Modified Vancouver Procedure:** To assess 4 variables of scar characteristics: vascularity, thickness, pliability and pigmentation. Vancouver scale was explained for every patient. Put a right mark at the score

for each point of the parameter. The total score was estimated for each patient.

**2. Digital imaging:** All patients were photographed before and after the 2 months of the treatment. Nikon digital camera was placed vertically to the scar area. The lights of the room were perfect to get a good picture. At each evaluation time, the digital camera was at a fixed distance from each patient’s scar, and all factors such as lighting, magnification, background, and film exposure were the same for each patient. The picture was taken facing the affected surface while the patient was lying in a relaxed position (10).

**Therapeutic procedures:**

The treatment duration was 8 weeks. Frequency of sessions: 3 times/week. Duration of session: 5 minute for phonophoresis.

**1. Procedures of Cybele scagel:** Ensure that the area for application is clean and dry. Apply Cybele Scagel with sufficient amount to spread thinly on to the area.

**2. Procedures of ultrasound:** The patient was resting in a relaxed position .After applying the gel (Cybele scagel), the ultrasound (Pulsed, frequency: 1 MHz, intensity: 0.5 W/cm) (11) was applied in a slow circular motion directly over the scar for 5 minutes.

**Statistical analysis**

All statistical analysis was conducted through the statistical package for social studies (SPSS) version 25 for windows (IBM SPSS, Chicago, IL, USA). Descriptive statistics and unpaired t-test were conducted for comparison of age between both groups. Chi-squared was carried out for comparison of sex distribution between groups. Normal distribution of data was checked using the Shapiro-Wilk test. Levene’s was used to test for homogeneity of variances. Unpaired t-test was conducted to compare the mean values of VSS between groups. Paired t-test was conducted for comparison between pre- and post-treatment in each group. The level of significance for all statistical tests was set at  $p \leq 0.05$ .

**RESULTS**

**Patients’ characteristics:**

Table (1) showed the patients characteristics of groups A and B. There was no significant difference between groups in the mean age and sex distribution ( $p > 0.05$ ).

**Table (1):** Comparison of patients’ characteristics between group A and B

	Mean ± SD		p-value
	Group A	Group B	
<b>Age (years)</b>	32 ± 6.71	33.13 ± 7.51	0.66
<b>Sex</b>			
<b>Females</b>	7 (47%)	8 (53%)	0.71
<b>Males</b>	8 (53%)	7 (47%)	

SD, standard deviation; p value, probability value.

**Effect of treatment on VSS:**

**Within group comparison:**

There was a significant decrease in VSS post-treatment compared to pre-treatment in groups A and B ( $p < 0.001$ ). The percent of decrease in VSS in group A was 35.43%, while that in group B was 16.5% (Table 2, Figure 1).

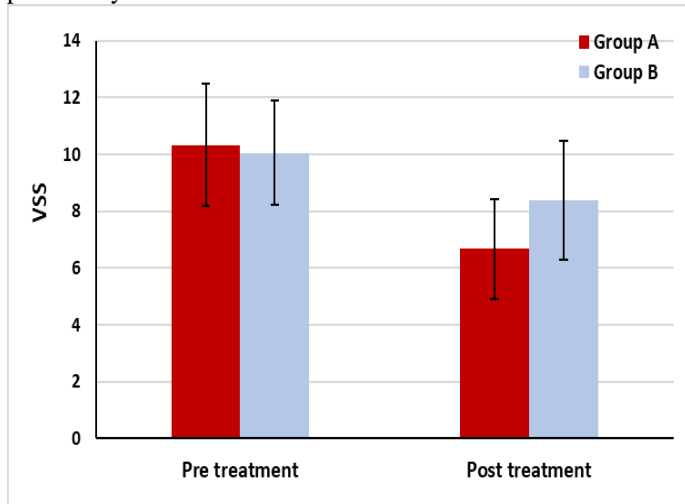
**Comparison between groups:**

There was no significant difference in VSS between both groups pre-treatment ( $p > 0.05$ ). Comparison between group A and B post-treatment revealed a significant decrease in VSS of group A compared to that of the group B ( $p < 0.05$ ) (Table 2 and Figure 1).

**Table (2):** Mean VSS pre and post treatment of group A and B

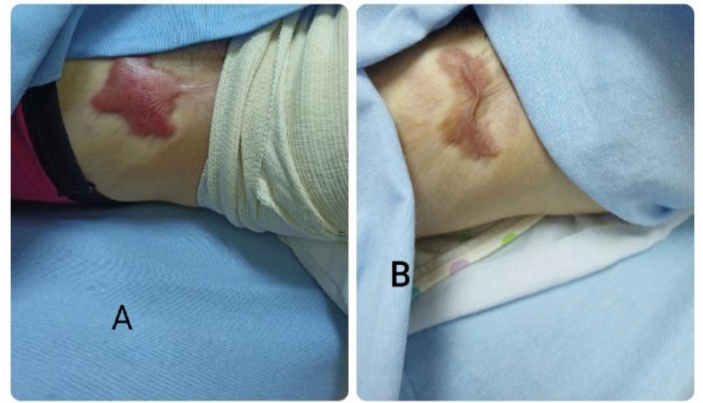
	Group A	Group B	MD	t-value	p value
	Mean ± SD	Mean ± SD			
<b>VSS</b>					
<b>Pre treatment</b>	10.33 ± 2.16	10.06 ± 1.75	0.27	0.37	0.71
<b>Post treatment</b>	6.67 ± 1.83	8.4 ± 2.09	-1.73	-2.4	0.02
<b>MD</b>	3.66	1.66			
<b>% of change</b>	35.43	16.5			
<b>t- value</b>	17.39	10.45			
	<i>p = 0.001</i>	<i>p = 0.001</i>			

SD, standard deviation; MD, mean difference; p-value, probability value



**Figure (1):** Mean VSS pre- and post-treatment of group A and B.

Photographs of the study group showed more improvement in scar appearance (Figure 2).



**Figure (2):** Changes in scar appearance in the study group; (A): before treatment & (B): after treatment

**DISCUSSION**

Hypertrophic scarring (HS) is a skin condition characterized by excessive fibrosis from skin fibroblasts, as well as disorganized collagens (12). HS develops during the wound healing phase after a deep thickness trauma or burn injury, impairing normal function and causing patients physical, psychological, and aesthetic problems (13).

This study was designed to evaluate the therapeutic efficacy of Cybele Scagel phonophoresis on the treatment of hypertrophic scar in post-burn cases. This study was carried out on thirty patients who had hypertrophic scar after wound closure and their ages ranged from 20 to 45 years. The participants were selected from Outpatient Clinic at Faculty of Physical Therapy, Cairo University.

Our results showed that within group comparison, there was a significant decrease in VSS post-treatment compared to pre-treatment in groups A and B ( $p < 0.001$ ). The percent of decrease in VSS in group A was 35.43%, while that in group B was 16.5%.

Current study showed that, there was no significant difference in VSS between both groups pre-treatment ( $p > 0.05$ ). Comparison between group A and group B post-treatment revealed a significant decrease in VSS of group A compared to that of group B ( $p < 0.05$ ). In agreement with the results of the current study, **Lee and Zhou** (14) found that phonophoresis has been claimed to improve the percutaneous absorption of some pharmacological drugs into the underlying subcutaneous structures using ultrasound, therefore increasing their effectiveness. **Park et al.** (15) found that the breakdown of the stratum corneum lipids, which allows the drug to pass through the skin, is the mechanism of transdermal permeation. After cavitation, microstreaming, and heat generation, a corresponding decrease in skin resistance was observed. The result of this study comes in accordance with three studies utilizing cybele scagel, **Jenwitheesuk et al.** (7) used cybele scagel following excision of pre-sternal hypertrophic scars ( $n = 60$ ), **Chuangsuwanich et al.** (16) used it after skin grafts ( $n = 15$ ) and **Muangman et al.** (8) used it after partial thickness due to burns ( $n = 63$ ),

which concluded that the treatment led to a better response, with respect to scar appearance and symptoms, than untreated wounds. In agreement with the results of the current study, **Draelos** <sup>(17)</sup> found that *Allium cepa* (the bulb onion) extract, the main component, has a range of health benefits, including anticarcinogenic properties, antiplatelet activity, antithrombotic activity, antihistamine effects, and antibiotic effects. **Boots et al.** <sup>(18)</sup> found that quercetin could inhibit lipopolysaccharide-induced tumor necrosis factor  $\alpha$  (TNF- $\alpha$ ) production and it has an anti-inflammatory effect.

The results of this study come in accordance with **Cho et al.** <sup>(19)</sup> who found that depending on the concentration and time of exposure to the compound, quercetin, a bioflavonoid produced from the *Allium cepa* plant, affect cell proliferation by decreasing cell protein content and reducing the mitotic index. MMP-1 expression is upregulated by onion extract and quercetin in a dose-dependent manner. Onion extract appears to be a promising material for minimizing scar development, based on these findings. **Ju et al.** <sup>(20)</sup> found that asiaticoside from *Centella asiatica* also suppress collagen synthesis via inhibit TGF- $\beta$  signaling. **Tang et al.** <sup>(21)</sup> reported that type I and type III collagen expression, as well as keloid fibroblast proliferation, were inhibited by asiaticoside.

**Baek et al.** <sup>(22)</sup> found that the impact of kazinol F from the bark and root of the paper mulberry, which inhibits the synthesis of the tyrosinase enzyme is responsible for the formation of melanin and skin pigmentation, may be responsible for the recovery of skin pigmentation. **Phetdee et al.** <sup>(23)</sup> found that mulberry and tamarind extract have the potential to reduce skin pigmentation.

**Draelos et al.** <sup>(24)</sup> found that in a randomized, controlled, blinded-investigator study of onion extract gel versus no treatment on new scars, onion extract gel improved the appearance of new scars.

**Spencer** <sup>(25)</sup> found that the polarization between silicone and skin helps to rearrange collagen fibers during the wound healing process. It has already been demonstrated to help with scar reduction. **Tandara and Mustoe** <sup>(26)</sup> found that silicone can maintain moisture and prevent water from evaporating. These mechanisms effectively reduce keratinocyte stimulation, cytokine production, and inhibit excessive collagen synthesis. In agreement with the results of the current study, **Viera et al.** <sup>(27)</sup>, **Campanati et al.** <sup>(28)</sup> and **Sahin et al.** <sup>(29)</sup> found that, in vitro and in vivo studies, using of onion extract 2 to 3 times a day for 3 to 6 months improves the appearance of postsurgical scars, adhesions, stretch marks, and hypertrophic scars.

## CONCLUSION

It can be concluded that the significant improvement in the results of the study concerning the hypertrophic scar in all measured parameters strongly proved the effectiveness of Cybele scagel phonophoresis which improved vascularity,

pigmentation, thickness, and pliability of HTS. Accordingly, it could be concluded that Cybele scagel phonophoresis is an effective therapeutic modality, which can be used successfully in treatment of hypertrophic scar.

## ACKNOWLEDGMENTS

The authors would like to express their gratitude to all patients who participated in this study.

## REFERENCES

1. **Dewey W, Richard R, Parry I (2011):** Positioning, splinting, and contracture management. *Phys Med Rehabil Clin N Am.*, 22 (2): 229-34.
2. **Chiang R, Borovikova A, King K et al. (2016):** Current concepts related to hypertrophic scarring in burn injuries. *Wound Repair Regen.*, 24: 466-477.
3. **Gerd G, Hans C, Korting T et al. (2011):** Hypertrophic Scarring and Keloids: Pathomechanisms and Current and Emerging Treatment Strategies. *Mol Med.*, 17: 113-25.
4. **Schneider J, Holvanahalli R, Helm P et al. (2006):** Contractures in burn injury: defining the problem. *J Burn Care Res.*, 27 (4): 508-13.
5. **Ogawa R (2017):** Keloid and Hypertrophic Scars Are the Result of Chronic Inflammation in the Reticular Dermis. *Int J Mol Sci.*, 18: 606-13.
6. **Farcic T, Lima R, Machado A et al. (2012):** Aplicação do ultrassom terapêutico no reparo tecidual do sistema musculoesquelético. *Arq Bras Ciênc Saúde.*, 37: 149-153.
7. **Jenwitheesuk K, Surakunprapha P, Kuptarnond C et al. (2012):** Role of silicone derivative plus onion extract gel in presternal hypertrophic scar protection: a prospective randomized, double blinded, controlled trial. *Int Wound J.*, 9 (4): 397-402.
8. **Muangman P, Aramwit P, Palapinyo S et al. (2011):** Efficacy of the combination of herbal extracts and a silicone derivative in the treatment of hypertrophic scar formation after burn injury. *Afr J Pharm Pharmacol.*, 5 (3): 442-446.
9. **Nedelec B, Correa J, Rachelska G et al. (2008):** Quantitative measurement of hypertrophic scar: intrarater reliability, sensitivity, and specificity. *J Burn Care Res.*, 29: 489-500.
10. **Välisuo P, Kaartinen I, Tuchin V et al. (2011):** New closed-form approximation for skin chromophore mapping. *J Biomed Opt.*, 16: 46012-46018.
11. **Muller S (2007):** About Scars, Scarring and Treatment options. *Blackwell Dermatology News*, 8: 1-4.
12. **Gauglitz G, Korting H, Pavicic T et al. (2011):** Hypertrophic scarring and keloids: Pathomechanisms and current and emerging treatment strategies. *Mol Med.*, 17: 113-25.
13. **Brewin M, Lister T (2014):** Prevention or treatment of hypertrophic burn scarring: A review of when and how to treat with the pulsed dye laser. *Burns*, 40: 797-804.
14. **Lee K, Zhou Y (2015):** Quantitative evaluation of sonophoresis efficiency and its dependence on sonication parameters and particle size. *J Ultrasound Med.*, 34 (3): 519-526.
15. **Park D, Park H, Seo J et al. (2014):** Sonophoresis in transdermal drug delivery. *Ultrasonics*, 54 (1): 56-65.
16. **Chuangsuwanich A, Arunakul S, Kamnerdnakta S (2013):** The efficacy of combined herbal extracts gel in

- reducing scar development at a split-thickness skin graft donor site. *Aesthet Plast Surg.*, 37 (4): 770–777.
17. **Draelos Z (2008):** The ability of onion extract gel to improve the cosmetic appearance of postsurgical scars. *J Cosmet Dermatol.*, 7: 101–104.
  18. **Boots A, Wilms L, Swennen E et al. (2008):** In vitro and ex vivo anti-inflammatory activity of quercetin in healthy volunteers. *Nutrition*, 24: 703–710.
  19. **Cho J, Cho S, Lee S et al. (2010):** Onion extract and quercetin induce matrix metalloproteinase-1 in vitro and in vivo. *Int J Mol Med.*, 25: 347–52.
  20. **Ju-Lin X, Shao-Hai Q, Tian-Zeng L et al. (2009):** Effect of asiaticoside on hypertrophic scar in the rabbit ear model. *J Cutan Pathol.*, 36: 234–9.
  21. **Tang B, Zhu B, Liang Y et al. (2011):** Asiaticoside suppresses collagen expression and TGF- $\beta$ /Smad signaling through inducing Smad7 and inhibiting TGF- $\beta$ RI and TGF- $\beta$ RII in keloid fibroblasts. *Arch Dermatol Res.*, 303 (8): 563–572.
  22. **Baek Y, Ryu Y, Curtis-Long M et al. (2009):** Tyrosinase inhibitory effects of 1,3- diphenylpropanes from *Broussonetia kazinoki*. *Bioorg Med Chem.*, 17: 35–41.
  23. **Phetdee K, Rattanamane K, Teaktong T et al. (2012):** Tamarind seed coat extract reduces melanin production via tyrosinase in melanocyte. *J Biol Sci.*, 12: 239–45.
  24. **Draelos Z, Baumann L, Fleischer A et al. (2012):** A new proprietary onion extract gel improves the appearance of new scars: a randomized, controlled, blinded-investigator study. *J Clin Aesthet Dermatol.*, 5: 18–24.
  25. **Spencer J (2010):** Case series: evaluation of a liquid silicone gel on scar appearance following excisional surgery a pilot study. *J Drugs*, 9: 856–858.
  26. **Tandara A, Mustoe T (2008):** The role of the epidermis in the control of scarring: evidence for mechanism of action for silicone gel. *J Plast Reconstr Aesthet Surg.*, 61: 1219–1225.
  27. **Viera M, Patel J, Konda S et al. (2010):** A comparative study evaluating the tolerability and efficacy of two topical therapies for the treatment of keloids and hypertrophic scars. *J Drugs Dermatol.*, 9 (5): 514–518.
  28. **Campanati A, Savelli A, Sandroni L et al. (2010):** Effect of allium cepa-allantoin-pentaglycan gel on skin hypertrophic scars: clinical and video capillareoscopic results of an open-label, controlled nonrandomized clinical trial. *Dermatolog Surg.*, 26 (9):1439–1444.
  29. **Sahin M, Inan S, Ozturkcan S et al. (2012):** Comparison of the effects of contractubex® gel in an experimental model of scar formation in rats: an immunohistochemical and ultrastructural study. *J Drugs Dermatol.*, 11 (1): 74–81.