

قسم : التشريح والهستولوجيا •  
كلية الطب البيطري - جامعة أسيوط •  
رئيس القسم : أ.د. حلمي محمد بدوي •

### مورفولوجي الأكياس الزلالية لمنطقة الكفل في الحمار

عبدالله حفني، اسماعيل عبدالعزيز، علي عبدالقادر، ط.ب/محمد طه

أجري هذا البحث على عدد واحد جنين وآخر مولود حديثا وثلاثة حيوانات صغيرة و ٣٥ حمارا بالغا ذات أعمار وأجناس مختلفة وقد اعدمت هذه الحيوانات عن طريق قطع الشريان السباتي العام ثم حقنت بمادة الفورمالين (١٠%)، ولدراسة المواصفات التشريحية حقنت الأكياس الزلالية بمادة المطاط • وتم حصر الأكياس الزلالية لمنطقة الكفل في الحمار وتم دراسة الشكل المورفولوجي لها وكذلك تحديد موقعها وشكلها وعلاقتها بالتراكيب المجاورة وتحديد أنسب الأماكن لحقنها جراحيا ومقارنتها ومثيلاتها في الحيوانات المختلفة من حيث الشكل وتشمل الأكياس الزلالية لمنطقة الكفل في الحمار الأكياس الآتية :

الغدة الزلالية تحت الجلدية المدورية، وتحت الجلدية للحدبة العجزية وتحت الجلدية للحرقفة الوحشية الدانية والقاصية وتحت الجلدية الوركية وتحت اللفافة المدورية وتحت الجلدية للمدور الثالث والكياس الزلالي المدوري للعضلة الكفلية السطحية والعضلة الكفلية الوسطى وتحت الوتر للعضلة السادة الداخلية والمدورية للعضلة ذات الراسين الفخذية والوركية والعضلة نصف وترية وتحت الوتر للجزء الوحشي لمنشأ العضلة المستقيمة الفخذية عند مستوى المدور الثالث لعظمة الفخذ •

Dept. of Anatomy & Histology.  
Faculty of Vet. Med., Assiut University,  
Head of Dept. Prof. Dr. H. Badawi.

**THE MORPHOLOGY OF THE SYNOVIAL BURSAE  
OF THE HIP REGION IN DONKEY  
(*Equus asinus*)  
(With One Figure)**

By  
**A. HIFNY; I.A. IBRAHIM; A.A. MANSOUR and M. TAHA**  
(Received at 25/7/1987)

**SUMMARY**

The hip region in donkey has a relatively largest size and number of synovial bursae. These include: B. subcutanea trochanterica, the subcutaneous bursa of the tuber sacrale, Bb. subcutanae iliaca (coxae) laterale proximalis et distalis, B. subcutanea ischiadica, B. subfascialis trochanterica, B. subcutanea trochanterica tertis, B. trochanterica M. glutei superficialis, B. trochanterica M. glutei medii, B. subtendinea M. obturatorii interni, B. trochanterica M. bicipitis femoris, B. ischiadica M. semitendinosi, the subtendinous bursa of the lateral tendon of origin of M. rectus femoris and the subtendinous bursa of the biceps femoris muscle at the level of third trochanter of the femur.

From the clinical point of view, there is no communication between the bursae and adjacent joint capsule of the hip joint.

**INTRODUCTION**

The bursae are synovial sacs of different size and shape contain a synovial fluid and surrounded by a connective tissue capsule. They are usually loculated or they may be communicated with tendon sheaths or joint capsule, a fact which can be of considerable clinical significance. Accordingly the attention was attracted to study the morphology of the synovial bursae of the hip region in donkey, as the available literatures lack any informations about these bursae in this animal. However, OTTAWAY/WORDEN (1940); BRADLEY (1946) and BERG (1973) in horse and GIGOV (1964) as well as RAGHAVAN/KACHROO (1964) in cattle mentioned only the frequency of the occurrence of these bursae in the studied animal.

**MATERIAL and METHODS**

This work was carried out on one fullterm fetus with C.V.R.L. 78 cm, one newlyborn, 3 young and 35 adult donkeys of different ages and sexes. After bleeding the animal through the common carotid artery and injection with 10% formalin, the materials were subjected to different techniques for studying the morphology of the bursae using Gum milk (latex).

The nomenclature used in this work is that adopted by the N.A.V. (1983) if it was possible.

A. HIFNY, *et al.***RESULTS****B. subcutanea trochanterica :**

This bursa is recorded in six limbs of the examined adult donkeys. It is subcutaneously located on the tendon of insertion of *M. gluteus superficialis* at the level of the convexity of the greater trochanter of the femur.

**The subcutaneous bursa of the tuber sacrale :**

In the present work this bursa is observed in both sides of 9 of the adult examined cases. The bursa is situated above the tuber sacrale. Its latex cast appears semicircular in outline, with 2.6 cm in diameter (1/3). For injecting this bursa the tuber sacrale must be palpated and then the needle is introduced obliquely through the skin for about 1.5 cm.

**Bb. subcutanae iliaca (coxae) laterale :**

These bursae are observed in both sides in 15 cases and in one side in 4 cases of the examined adult donkeys. They were not observed in fetus, newlyborn or young animals. They are subfacially situated on the prominent area of the tuber coxae. The bursae are represented by a proximal and distal ones which communicate with each other in 11 case and they are independent in 5 examined ones. The two bursae are represented by a common bursa which is intersected by connective tissue lamellae which subdivide the bursa into many small cavities, therefore the latex cast of this bursa is not uniform in outline.

The proximal bursa is smaller and is situated above the proximal end of the tuber coxae (1/1). Its latex cast appears oval in outline with a wide proximal end and a narrow distal one. It measures about 2.8 cm proximodistally and 1.7 cm transversly. Its long axis is directed obliquely, distally and cranially.

The distal bursa is larger than the preceding one and lies over the distal end of the tuber coxae (1/2). Its latex cast appears triangular in outline with its apex directed proximally while its base is directed distally. It measures about 5.5 cm proximodistally and 2.5 transversly.

**B. subcutanea ischiadica :**

In donkey this bursa was observed in one of the examined cases. It is subcutaneously situated on the vertebral part of *M. semitendinosus* above the ventral part of the tuber ischii. The latex cast of the bursa measures about 5 cm mediolaterally and 2 cm proximodistally.

**The subfascial trochanteric bursa :**

In the present work this bursa is recorded in 16 of the examined specimens. It was not recorded in fetus, newlyborn or young donkeys. It is situated subfascially under the gluteal fascia between the caudal edge of *M. gluteus superficialis* and the vertebral head of *M. biceps femoris*.

**The subcutaneous bursa of the third trochanter of the femur :**

This bursa was observed only in two of the examined cases. It is situated subcutaneously above the tendon of insertion of *M. gluteus superficialis* at the third trochanter of the femur.

**B. trochanterica M. glutei superficialis :**

This bursa is recorded in both sides in 13 and in one side only in 4 of the examined

## THE SYNOVIAL BURSAE OF THE HIP REGION IN DONKEY

cases. It was not observed in fetus, newborn and young animals. This bursa is situated between the tendon of insertion of *M. gluteus superficialis* and *M. gluteus medius* at the cranial part of the greater trochanter of the femur with its long axis directed obliquely, cranially and slightly distally.

The latex cast appears comma shaped where its circular end is situated cranially and its narrow end is caudally directed. The latex cast appears formed from several layers as indication of the intersection of the cavity of this bursa by fibrous connective tissue lamellae. It measures about 4.2 cm proximodistally and 5.7 cm craniocaudally.

### **B. trochanterica M. glutei medii :**

It is situated between the tendon of insertion of *M. gluteus medius* and the cranial part (convexity) of the greater trochanter of the femur with its long axis directed obliquely, cranially and slightly distally (1/5).

The latex cast of the bursa appears oval in outline measures about 5 cm craniocaudally and 3.5 cm proximodistally.

For injection of this bursa the cranial part of the greater trochanter of the femur must be palpated firstly. Just in front to the cranial margin of this bony projection the needle is inserted underneath the tendon of *M. gluteus medius* and is directed proximally and caudally where it passes into the bursa.

### **B. trochanterica M. bicipitis femoris :**

This bursa is observed in both sides of 9 and in one side only in 2 of the examined adult cases. The bursa is interposed between the vertebral head of *M. biceps femoris* and the lateral surface of the summit of the greater trochanter of the femur (1/6).

When the bursa is injected with latex and hardened in situ, its cast appears quadrilateral in outline. The cast is large with 6.2 cm length proximodistally and 4 cm width medio-laterally.

In donkey the bursae subtendinae trochantericae comprise; *B. trochanterica M. glutei superficialis*, *B. trochanterica M. glutei medii* and the *B. trochanterica M. bicipitis femoris* (the latter one is observed inconstantly in adult cases). This latter bursa in addition to *B. trochanterica M. glutei superficialis* were not observed in fetus, newly born or young animals, therefore they can be considered as acquired bursae. Their position varies considerably according to the movement of the hip joint. In case of extension; the bursa *trochanterica M. bicipitis femoris* facilitates the play of *M. biceps femoris* over the lateral surface of the caudal part of the greater trochanter of the femur, the *B. trochanterica M. glutei superficialis* facilitates the play of its tendon of insertion over the tendon of insertion of *M. gluteus medius*. While the *B. trochanterica M. gluteus medius* facilitates the play of its tendon over the cranial part of the greater trochanter of the femur and this bursa becomes projected beyond the cranial margin of the tendon of this muscle where a part of the tendon of insertion of *M. gluteus superficialis* passes on this part of the bursa. In case of flexion the tendon of insertion of *M. gluteus superficialis* moves cranialwards so the *B. trochanterica M. glutei superficialis* facilitates the passage of tendon of insertion of this muscle as well as the cranial part of the vertebral head of *M. biceps femoris*, while the cranially projected part of the bursa *trochanterica M. glutei medii* becomes covered with the cranial part of the muscle.

### **B. subtendinea M. obturatorii interni :**

This bursa is observed in all of the examined specimens. It is irregularly triangular in

**A. HIFNY, et al.**

outline, situated under the tendon of *M. obturator internus* as it passes on the lateral border of the ischium through the lesser ischiatic foramen (1/7).

**B. ischiadica *M. semitendinosi* :**

It is relatively large bursa, observed in both limbs of one adult donkey. This bursa is interposed between the vertebral head of *M. semitendinosus* and the rough caudal surface of the ventral protruded part of tuber ischii.

When the bursa is injected with latex and hardened in situ, it appears quadrilateral in outline with its axis directed distally.

**B. iliaca *M. recti femoris* :**

This bursa is interposed between the tendon of origin of *M. rectus femoris* and the body of the ilium above the acetabulum (1/8). When the bursa is injected with latex and hardened in situ, the cast appears nearly triangular in outline and flattened from side to side. Its base is 1.5 cm length and is placed caudadistally while its apex is placed proximally and cranially.

**B. trochanterica tertis *M. bicipitis femoris* :**

This bursa is observed in 20 of the examined adult donkeys. It was not observed in fetus, newlyborn and young animals. It is situated between the caudal surface of the third trochanter of the femur and the cranial head of *M. biceps femoris* (1/9). Its long axis is parallel to the long axis of the femur.

When the bursa is injected with latex and hardened in situ, its cast appears semicircular in outline, measures about 2.2 X 1.9 cm proximodistal and mediolateral diameters respectively.

For injection of this bursa, the third trochanter of the femur must be palpated, then the needle is introduced obliquely through the skin behind and parallel to the caudal surface of the third trochanter of the femur.

### **DISCUSSION**

In donkey the *B. subcutanea trochanterica* was found subcutaneously situated above the cranial part of the greater trochanter of the femur a result which is similar to that stated in horse by BERG (1973) and SEIFERLE/FREWEIN (1986) however, OTTAWAY/WORDEN (1940) in the same animal recorded this bursa on the summit of the greater trochanter of the femur.

The present investigation shows that the *Bb. subcutanae iliaca (coxae) laterale* are usually represented by proximal and distal bursae in which the proximal one is smaller than the distal, however, in horse OTTAWAY/WORDEN (1940) and SEIFERLE/FREWEIN (1986) mentioned that the proximal bursa is larger than the distal one. In agreement to the obtained results in donkey the latter authors added that the two bursae are usually communicated.

The subfacial trochanteric bursa is commonly found in donkey like that in horse as mentioned by OTTAWAY/WORDEN (1940). The present work suggests the name of this bursa as *B. subfacialis trochanterica*.

Regarding the subcutaneous bursa of the third trochanter of the femur, the obtained literatures lack any information about it. The name is suggested by the present work as *B. subcutanea trochanterica*.

### THE SYNOVIAL BURSAE OF THE HIP REGION IN DONKEY

The presence of B. trochanterica M. glutei superficialis, B. trochanterica M. glutei medii and B. trochanterica M. bicipitis femoris show a great variance among the domestic animals. In donkey the bursa trochanterica M. glutei medii and B. trochanterica M. glutei superficialis are constant and the other bursa is inconstant. While in horse, ELLENBERGER/BAUM (1943), BARON (1980) and SEIFERLE/FREWEIN (1986) reported synovial trochanteric bursae under the tendon of insertion of superficial, middle and deep gluteal muscles and not present under the biceps femoris.

In cattle the authors antagonized each other, in regard to the presence or the absence of these bursae. SEIFERLE/FREWEIN (1986) reported the presence of a synovial bursa under the M. gluteobiceps, M. gluteus medius and M. gluteus profundus, while ELLENBERGER/BAUM (1943) reported the absence of synovial trochanteric bursa under the tendon of M. gluteus medius and M. gluteus profundus.

The site of injection of B. trochanterica M. glutei medii in the present work is similar to that recorded in horse by VAN KRUIJNINGEN (1963) who added that, an alternative method may be employed by directing the needle medially through the muscle directly over the bursa inward the trochanter; the injection is made after touching the bone with the tip of the needle a method which is not desirable in the present work.

In donkey the B. subtendinea M. obturatorii interni is relatively large, which extends cranially around the iliac head of this muscle in a form of sheath and caudally is interposed between the muscle and the ischium. However, in horse OTTAWAY/WORDEN (1940) and SEIFERLE/FREWEIN (1986) stated that M. obturator internus is enclosed in a tendon sheath as it leaves the pelvic cavity through the lesser ischiatic notch.

Regarding the position and occurrence of the bursa iliaca M. recti femoris, similar result was observed in horse by OTTAWAY/WORDEN (1940), BRADLEY (1964). In ox between the lateral tendon of origin of M. rectus femoris and the capsular ligament of the hip joint there is a synovial bursa (McLEOD, 1958; RAGHAVAN/KACHROO, 1964).

### REFERENCES

- Baron, R. (1980): Anatomie comparee des Mammifere Domestiques. Arthologie et Myologie, Tome 2. Laboratoire d'Anatomie, Ecole Nationale Veterinaire, Lyon.
- Berg, R. (1973): Angewandte und Topographische Anatomie der Hausriehere, Veb Gustav Fischer Verlag Jena.
- Bradley, O.C. (1946): The topographic anatomy of the limbs of the horse. 2nd edition. Edinburgh, W. Green and Son, Limited.
- Ellenberger, W. und H. Baum (1943): Handbuch der Vergleichenden Anatomie der Haustiere 18. Auflage. Springer, Berlin. Cited by Olensky (1978).
- Gigov, Z. (1964): Uber den Bau, die Blutversorgung und dielnervation der Gelenkkapsel der Extremitaten beim Rind. Anat. Anz. Bd. 114.
- McLeod, W.M. (1958): Bovine Anatomy. 2nd edition. Burgess publishing compay; Maneapolis, Minneseta.
- Nomina Anatomica Veterinaria (1983): Third edition. Published by the international committe on Veterinary Gross Anatomical Nomenclature under the financial responsibility of the world Association of Veterinary Anatomists. Ithaca, New York.
- Ottaway, C.W. and A.N. Worden (1940): Bursae and tendon sheaths of the horse, Vet. record Vol., 52, No. 26.
- Raghavan, D. and P. Kachroo (1964): Anatomy of the ox. First edition. Indian council of agricultural research, New Delhi.

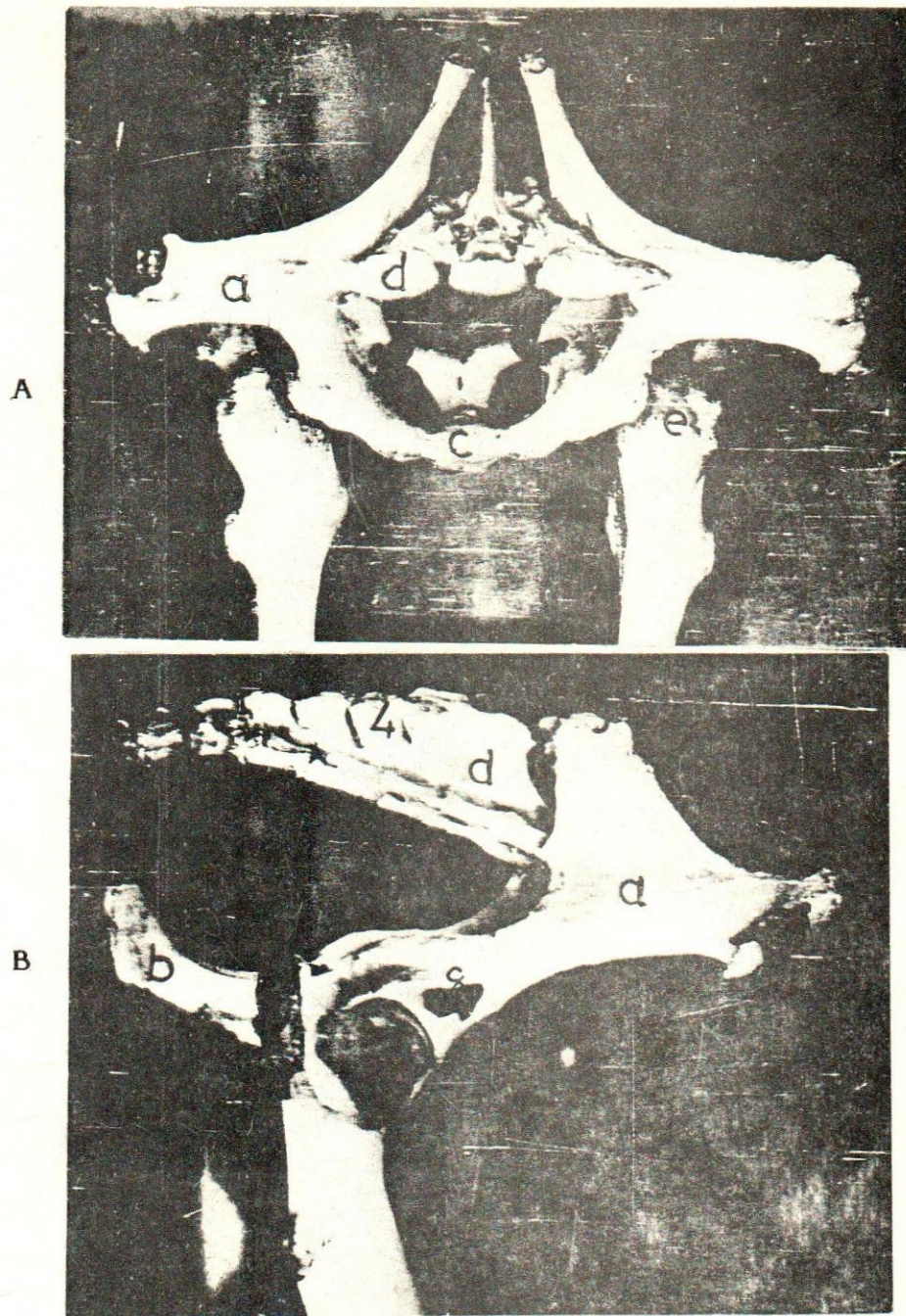
**A. HIFNY, et al.**

- Seiferle, E. and Frewein (1986): Active locomotor system in Nickel, R.; A. Schummer; E. Seiferle; J. Frewein; H. Wilkens and K.H. Wille; The locomotor system of the domestic Mammals. Verlag Paul Parey Berlin, Hamburg.
- Van Kruiningen, H.J. (1963): Practical techniques for making injections into joints and bursae of the horse. J.A.V.M.A. Vol. 143, No. 10.

THE HISTORY OF

Faint, illegible text at the top of the page, possibly a title or introductory paragraph.





**Fig. (1):** Latex casts of the hip region.

**A-** Cranial view.      **B-** Lateral view.

**a-** Ilium.   **b-** Ischium.   **c-** Pubis.   **d-** Sacrum.  
**e-** Proximal extremity of the femur.

- 1-B. subcutanea iliaca laterale proximalis.
- 2-B. subcutanea iliaca laterale distalis.
- 3-B. subcutanea iliaca mediale.
- 4-B. subcutanea supraspinalis sacrale III-IV.
- 5-B. trochanterica M. glutei medii.
- 6-B. trochanterica M. bicipitis femoris.
- 7-B. subtendinea M. obturatorii interni.
- 8-B. iliaca M. recti femoris.
- 9-B. trochanterica tertis M. bicipitis femoris.

