

## Different Grafts used In Closure of Central Small Tympanic Membrane Perforations

H.A.Gad, H.F.Hashem and M.A.Ismail

Otorhinolaryngology, Dept., Faculty of Medicine, Benha Univ., Benha, Egypt

Email: drmohamedent@yahoo.com

### Abstract

Background: Large number of patient seek ENT consultation for central perforation of tympanic membrane. A significant portion of these cases are often found with very small central perforation. Minimizing myringoplasty is a very simple procedure to close such small perforations. Objective: the aim of the present study is to compare the surgical and audiological results of temporalis fascia versus more simple methods ( fat graft, fat graft with hyaluronic acid and platelet rich plasma) in myringoplasty. Patient and Methods: a randomized prospective study concerned with 80 patients for whom myringoplasty was done. Patients were randomly assigned into four groups; in the first group fat graft was used (20 patient) and fat graft with hyaluronic acid was used in the second group (20 patients), and platelet rich plasma was used in third group (20 patients) and temporalis fascia was used in fourth group (20 patients). Results: our study included 80 patients, 45 males and 35 females with a range from 18- 55 years. Surgical success rates 75% , 80%, 75% and 75% for fat graft, fat graft with hyaluronic acid, platelet rich plasma and temporalis fascia respectively. There was 6.5 dB, 7db , 6 db and 5.5 db mean hearing improvement in fat graft, fat graft with hyaluronic acid, platelet rich plasma and temporalis fascia respectively. Conclusions: The myringoplasty with fat graft, fat graft with hyaluronic acid and PRP is a minimally invasive effective procedure in management of the small central tympanic membrane perforations . Also it is safe and feasible procedure In this study we have achieved High success rate of repair of tympanic membrane perforation.

**Keywords:** Temporalis Fascia, fat graft, hyaluronic acid Myringoplasty.

### 1. Introduction

TM perforations can be the product of inflammation, perforation, or perforation of the tympanic membrane (TMT) despite the fact that about 88% of perforations recover without operation, the remaining percent of perforations must be treated surgically. This kind of puncture usually has to be treated by ophthalmologists (specialists who treat eye disorders). Lately, less costly, non-invasive non-surgical approaches to treat various causes have been mandatory. [1]

Though complicated procedures have their place, simple treatments don't: they involve hospitalisation, are costly, and patients can't function or attend school during treatment. And if the amount of anaesthesia is provided to a restricted area of the eardrum to specific calibre of the ear canal, there is low chance of the anesthetic's invasion, so the procedure is appropriate for the elderly with certain medical conditions and other comorbidities. [2]

Fat grafting myoplastomy (FGM) was first used in 1962 for the treatment of this kind of hole in omental myoplasty. nasal microincision can be done as an office operation, and no middle ear perforation is generally seen, however, and since the microincision persists, the patient is dissatisfied with the recovery, but generally also unable to do a fresh incision. [3]

antibiotic HA for middle ear drops (liquid form) was first used in the treatment of the middle ear. since HA is an important part of the extracellular matrix in several different parts of the body, it is widely accepted as a tissue feature. Guner et al. studied the beneficial impact of topical HA on the healing of acute punctures and fistulas in this. [4] Prior et al previously used a HA polyester product called Epim (Xomed; Xomed Surgical Products, Sherbourne House, UK) They found that the treatment of TM perforations with ester films was effective in just five of the ten patients, but they

nevertheless agreed that they only do it as a final resort [5]. A recent procedure incorporating fat transfer with the use of HA myoplasty (FAT) yielded improved outcomes for fat grafting across the temporalis muscle and the use of temporalis fascia: Saliba and Woods (2008). [3]

Platelet-rich plasma produces elevated levels of growth factors derived from the patient's own blood. Since it was first used by Ferrari et al. in open-heart surgery in 2008, it has since been used in several healthcare specialties. Autologous platelet-rich plasma was found to significantly improve tympanic membrane perforation closure in the research conducted by Erkilat et al. in 2009. glamorous plan

The most widely used temporalis fascia graft is taken from autologous tissue because of its accessibility and durability. As Heerman stated in '58, temporalis fascia is the first to be used for this procedure. The temporalis fascias profit is valued for their uncomplicated harvest, plentiful supply, and excellent quality of the grafts. [9]

### 2. Aim of the work

The aim of this analysis is to see one of the three simpler approaches (altering the proportions of the fat graft or using hyaluronic acid or platelet rich plasma) may help in the recovery of central tympanic membrane perforations.

### 3. Patients and Methods

It was planned as a prospective research on 80 patients with a complaint of intermittent ear drainage, hearing loss, and small tubal perforation for 3 weeks or less, performed until they were initiated on any interventions that could affect the inner or middle ear.

**3.1. Exclusion criteria are**

- Evidence of cholesteatoma, Previous ear surgery, Recent Traumatic perforation, Severe Tympanosclerosis, Chronic otitis externa, Systemic diseases as Diabetes Mellitus, Tuberculosis and large or marginal tympanic membrane perforation.
- All procedures of the operations were explained to te patient and we have got written consents from them .

**3.2. Preoperative assessment:**

- Each patient was subjected to:Detailed history taking, full clinical examination with special ,general&local otolaryngological examination and compelete Investigations for surgical fitness.
- Audiological investigations include: pure tone audiometry

All audiometers were performed by one audiometrist whom kepted blind to the procedure that was used in myringoplasty.  
Hearing results are assessed by comparing both air conduction and air-bone gap (ABG) between preoperative and postoperative averagerster

Patients were randomly distributed between four groups:

**Group 1:** myringoplasty was done using fat graft

**Group 2:** myringoplasty was done using fat graft hylaronic acid

**Group 3:** myringoplasty was done using patelet rich plasma

**Group 4:** myringoplasty was done using temporalis fascia graft

**Surgical procedures:**

**a. Position:**

Supine with face turned to one side: the ear to be operated is up.

**b.Surgical approach:**

Trans canal approach myringoplasty under local anathesia in cases of minimyringoplasty using (fat graft, hyaluronic acid fat graft or platelet rich plasma) postauricular approach under general anaesthesia in cases of using temporalis fascia graft.

**c. Surgical Steps**

**1.Sterilization**

Standard antiseptic measures are taken.

**Anesthesia**

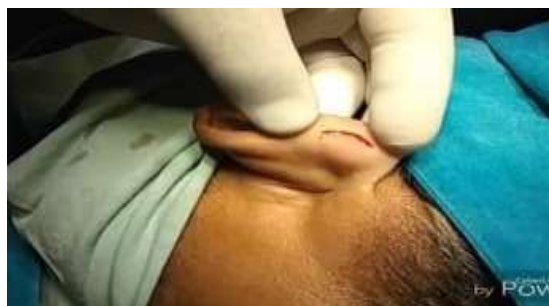All cases of minimyringoplasty using ( fat graft, hyaluronic acid fat graft or platelet rich plasma) were done under local anesthesia by injection of 5 ml of 2% lignocaine with adrenaline [1:100,000] in four quadrants of external ear canal and behind the ear lobule,also topical application of 10% lidocaine(emla cream.)

All cases which will be done using temporalis fascia graft will be done under general anaesthesia


**Harvesting the graft:**

**A)The Fat graft:**

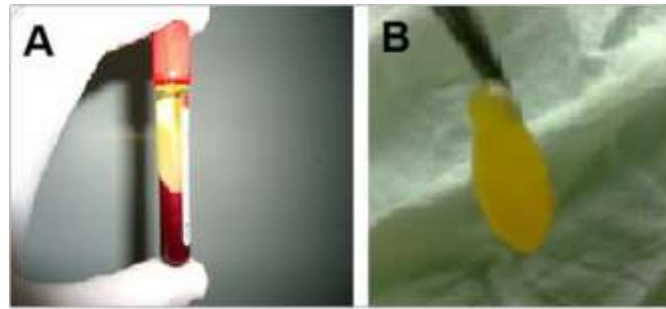
A small [1 cm] horizontal incision was made on the skin behind the ear lobule. The skin was undermined using a delicate sharp dissecting scissor. And adequate piece of fat according to the size of perforation was collected from Ear lobule and preserved in normal saline. The incision was closed with a 5-0 nylon suture.



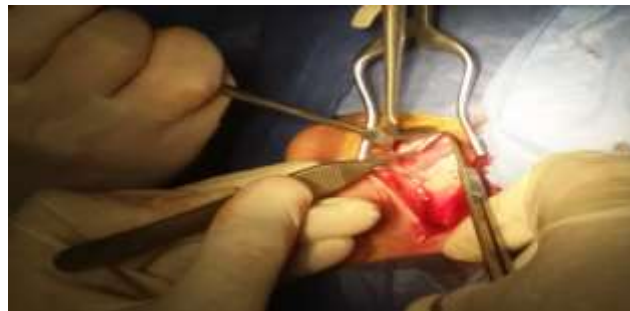**Fig. (1)** showing incision in ear lobule to obtain fat graft for myringoplasty B)Hyaluronic acid is obtained from already prepared syringes.



**Fig. (2)** showing hyaluronic acid in already prepared syringes.



**Fig. (3)** PRP preparation and insertion: [A] blood was separated out into the three layers; the middle layer contains the PRP. [B] PRP could be easily obtained.



**Fig. (4)** showing obtaining of temporalis fascia graft.

#### **C) Preparing the platelet rich plasma:**

5ml of peripheral venous blood was drawn from the patient after application of topical anesthesia with a 16 or 18 gauge butterfly needle, this blood was kept in a 5 ml plain vacuum tubes, then immediately centrifuged using a tabletop centrifuge for 12 minutes at 3200 rpm.

This causes the blood to be separated out into the three layers, the middle layer consisted of PRP. A single piece of the PRP, approximately double the size of the perforation was obtained from the patient intravenous blood sample.

#### **D) preparation of temporalis fascia graft :**

Temporalis fascia harvested, cleaned from muscle fibers and left to dry for few minutes before use

#### **Preparing the TM for grafting:**

The margin of the perforation is de-epithelialized circumferentially with a Rosen's needle and cup forceps. Remove also a strip of mucosal layer from the inner side of perforation.

Trimming of the perforation margin.

#### **Placing the graft**

##### **A) Fat graft**

A proper-sized fat graft was placed so that its edges extend under the margins of perforation all round keeping a small part of the graft just plugging through the perforation. A small part also extended over the posterior canal wall, gel foam were inserted filling the EAC to support the fat graft. This procedure was described by Ringenberg, 1962 (13)

##### **B) Hyaluronic acid fat graft**

First, de-epithelization with a sharp prick was performed to the perforation margins. The fat graft was inserted through the perforation as an hourglass shape. The HA should cover the fat graft and the medial edge of the external ear canal skin. The HA and the ear canal are supported with sponge gels. Patients were instructed to keep their ears dry and were prescribed to use topical ciprofloxacin as prescribed by Saliba 2008(17) .

#### **C) PRP Placement procedure.**

The platelet-rich plasma was prepared while the anesthesia was taking effect. Patients were placed in a supine position with their head turned so that the ear with the perforation was up.. The margin of each perforation was freshened, and a single piece of platelet-rich plasma, approximately double the size of the perforation, was prepared. Via a transcanal approach, the platelet-rich plasma was inserted through the perforation and placed in an hourglass configuration, with nearly equal portions lying medial and lateral to the perforation. Next, a second, larger piece of platelet-rich plasma was placed in the external auditory canal over the hourglass piece. A meatal pack of soft paraffin-impregnated gauze was placed for 1 week. No ear dressing was used, and patients were discharged after the procedure with postoperative instructions as prescribed by El-anwar et al 2015 (23) .

#### **D) temporalis fascia graft**

All operations was performed under general anesthesia.

Xylocaine 1% with adrenalin 1: 100000 was infiltrated into postaural area and the meatal skin.

The perforation edges was refreshed using fine probe to stimulate growth of tympanic membrane remnants over the graft.

Post-aural incision , followed by elevation of tympano-meatal flap.

The auricle together with the tympanomeatal skin flap was held forward by self retaining retractors.

Ossicular chain mobility must be judged as good before the graft is inserted.

Temporalis fascia harvested, cleaned from muscle fibers and left to dry for few minutes before use.

The fascia will be used they inserte below tympanic membrane remnants and handle of malleus(under-lay technique).

Skin flap reposition and pledges of gel- foam were put on the graft and the ear will be packed.

Suitable antibiotic was given to the patient daily for five days postoperatively.

Stitches were removed after 7 days while the pack will remove on the 10th day, after which antibiotic ear

drops prescribe for 10 days. Gel- foam usually left for spontaneous absorption after 3 weeks. as prescribed by Kumar et al., (2014)(24)

**Intra operative data :**

The following data was recorded: -

1. Time of surgery.
2. Complications.

**Postoperative care**

1. Stitches and dressing [behind the ear lobule] were removed after 6-7 days.
2. Ear pack was removed after 6-7days.
3. Otoscopic follow up at 6 weeks, 3 months and 6 months was done.
4. Audiologic assessment [PTA] after 3 months

**Follow up:** Minimal follow up period was six months.

**During follow up, the following data were recorded**

1. Presence of infection, granulation or recurrent TM perforation.
2. Pure tone average [PTA].
3. Air bone gap [ABG]

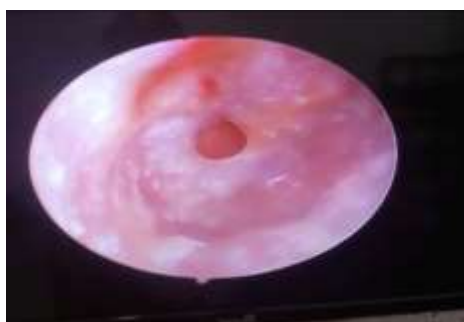**4. Results**

**Table (1)** Comparison between the studied groups regarding graft taken

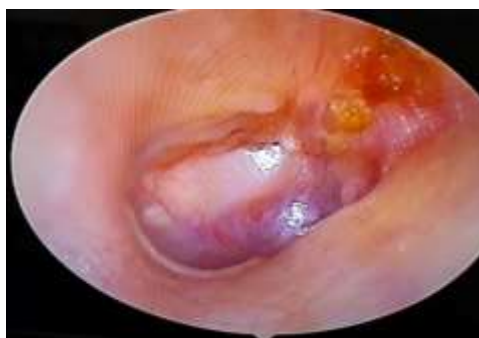	Fat graft group	Fat graft with hyaluronic acid group	Platelet rich plasma group	Temporalis fascia graft group	$\chi^2$	p
	N=20 (%)	N=20 (%)	N=20 (%)	N=20 (%)		
Not uptaken	5 (25)	4 (20)	5 (25)	5 (25)	0.71	0.873
Uptaken	15 (75)	16 (80)	15 (75)	15 (75)		

$\chi^2$  chi square test

This table shows that there is statistically non-significant difference between the studied groups regarding fate of graft. Larger percentages within all the studied groups (75%, 80%, 75% and 75% of patients within fat graft, fat graft with hyaluronic acid, PRP and temporalis fascia graft groups respectively) showed that graft was uptaken.



**Fig 5:** showing preoperative small right ear perforation



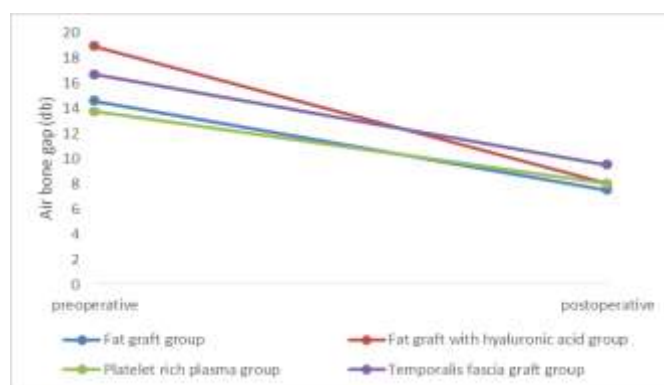
**Fig 6:** showing post-operative fat graft uptake and healing of the perforation.

**Table (2)** Comparison between the studied groups regarding air bone gap pre and postoperatively.

	<b>Fat graft group</b> N=20 (%)	<b>Fat graft with hyaluronic acid group</b> N=20 (%)	<b>Platelet rich plasma group</b> N=20 (%)	<b>Temporalis fascia graft group</b> N=20 (%)	F/KW	p
<b>Preoperative</b>						
Mean $\pm$ SD	14.6 $\pm$ 3.93	17.05 $\pm$ 4.26	14.15 $\pm$ 2.73	16.3 $\pm$ 4	2.649	0.055
Range	10 – 20	10 – 25	11 – 20	10 – 25		
<b>Postoperative</b>						
Median	7.5	8	8	9.5	3.089	0.283
Range	4 - 20	5 – 20	5 – 17	5– 25		
<b>P (Wx)</b>	<0.001**	<0.001**	<0.001**	<0.001**		

F one way ANOVA Wx Wilcoxon signed test

This table shows that there is statistically non-significant difference between the studied groups regarding preoperative air bone gap. Mean preoperative air bone group of patients were 14.6, 17.05, 14.15 and 16.3 db within fat graft, fat graft with hyaluronic acid, PRP and temporalis fascia graft groups respectively. This table shows that there is statistically non-significant difference between the studied groups regarding postoperative air bone gap. Median postoperative air bone group of patients were 7.5, 8, 8 and 9.5 db within fat graft, fat graft with hyaluronic acid, PRP and temporalis fascia graft groups respectively. On comparing pre and postop values, there is statistically significant decrease.

**Fig. (7)** Multiple line graph showing comparison between the studied groups regarding pre and postoperative air bone gap**Table (3)** Comparison between the studied groups regarding hearing improvement.

	<b>Fat graft group</b> N=20 (%)	<b>Fat graft with hyaluronic acid group</b> N=20 (%)	<b>Platelet rich plasma group</b> N=20 (%)	<b>Temporalis fascia graft group</b> N=20 (%)	KW	p
<b>Improvement</b>						
Mean $\pm$ SD	6.5	7	6	5.5	4.863	0.182
Range	0 – 10	0 – 15	0 – 7.5	0 – 10		

KW Kruskal Wallis test \*p<0.05 is statistically significant

This table shows that there is statistically non-significant difference between the studied groups regarding change in air bone gap postoperatively. Median change were 6.5, 7, 6 and 5.5db in patients within fat graft, fat graft with hyaluronic acid, PRP and temporalis fascia graft groups respectively.

**Table (4)** Comparison between the studied groups regarding patients with no hearing improvement.

	<b>Fat graft group</b> N=20 (%)	<b>Fat graft with hyaluronic acid group</b> N=20 (%)	<b>Platelet rich plasma group</b> N=20 (%)	<b>Temporalis fascia graft group</b> N=20 (%)	$\chi^2$	p
<b>Improvement:</b>						
<b>No</b>	4 (20)	4 (20)	4 (20)	7(35)	1.864	0.677
<b>Yes</b>	16 (80)	16 (80)	16 (80)	13 (65)		

$\chi^2$  chi square test

This table shows that there is statistically non-significant difference between the studied groups regarding patients with no hearing improvement. No improvement presented in 20%, 20%, 20% and 35% of patients within fat graft, fat graft with hyaluronic acid, PRP and temporalis fascia graft groups respectively.

## 5. Discussion

Uncomplicated surgical perforations typically provide a high success rate of complete perforation closure. More and less recent research recorded performance of 60 to be 60% to 99% in adults, than the previously reported 18 to 94% success rate in children (10&11).

Myringoplasty by injection [12].

A analysis of various grafts was carried out to select the most economical and least invasive technique in regard to minor central tympanic membrane perforations

Ringenberg, 1962: Effective perforations have been seen to occur in per centimetre strip anastomosing PGT with an incidence of 87% . [14]. approximately 75% of the patients of fat myoplasty who had the procedure under local anaesthesia had effective fat grafting, with a mean increase of 6.5 dB in hearing.

Repair of tympanic membrane perforations with hyaluronic acid alone should not be used, as mentioned by Prior et al (2007). The edges of the perforation were freshened, and a layer of HA 2 mm in diameter was passed to form a nest around the perforation. The HA dissolved in all five patients, but the openings were the same number. the experiment was thus discontinued. We present a hyaluronic acid/fat graft myringoplasty approach in our research.

extracellular polysaccharate It is found outside of the cell membranes, rendering it biocompatible [16]

After an 18 months, Saliba (the plastic surgeon) registered a global success rate of 92.7% in adults and 87% in children with HAFGM (hyaloconeoplasty)

20 cases using hyaluronidase under local anaesthesia had a successful outcome with afer fat graft, which is 80% and a rate of 7 decibels.

Autologous platelets reflect an evolving biotechnology in today's tissue engineering and cellular therapy that can be put directly into the lesion. [8]

Autologous Platelet-Rich Plasma is simple to make and free of side effects. in addition, there are more white blood cells in the blood component called platelets, which acts as a bacteriostatic. [20]

Platelet-rich plasma facilitates the endothelial, epithelial, hemostatic, and dermal wound regeneration, triggers angiogenesis, and assists in the formation of collagen, and soft tissue repair. [21]

Without general anaesthesia or hospitalisation, the use of platelet rich plasma to mend the tiny tympanic membrane perforates is completely secure. It has several other benefits in comparison to the standard office-based methods. In fat grafting, no incisions are needed to obtain the graft. So we don't need to do several band-aids, myopl

Unlike most office-based myoplasty operations, the durability of the tympanic cavity and mobility of the ossicular chain cannot be explored during platelet-rich plasma (PRP) injection.

membrane in offices, which is able to provide considerable benefits, we believe office-based plasma hourglass implantation to be a good substitute for small, dry central ear perforation. Since it is noninvasive, low-

risk, efficient, and minimally invasive, this treatment is appropriate for treating minor tympanic membrane perforations. With topical anaesthesia and without donor-site side effects, the surgery may be done. Finally, the effective treatment performance is equal to that of the surgical approaches.

Patients who went to a single office for their perforation repair in the El-an and El-wari et al [23] discovered that 84% of such patients had perfor lesions corrected with a single office visit

in our pilot report, 20 cases experienced PRP myotomy with a progress rate of 75% for take-up and a hearing improvement of 6 dB

The mean increase in temporalis hearing patch performance in the report of Kumar et al. (2014) is 9.5 dB

Research studies of implantation by Gibb used the temporal fascia substance used as an underlay, and yielded an 87.5% take-up rate. [25]

In our sample, 20 people (15 women and 5 men) received a temporalis muscle transplant using general anaesthesia and an overall success rate of 75%.

## 6. Conclusion

Despite its intrusive nature, the myringoplasty with a mesh fat graft using hyaluronic acid and PRP yields excellent results in the treatment of tympanic membrane perforations This is not just an option, but it is also secure and feasible. in this research, tympanic membrane perforation was successfully attained.

## References

- [1] C.Sharma, J.Singh, V.Kakkar, S.Yadav, P.Malik, S.Bishnoi. Fat graft myringoplasty in small central perforations. *Indian J Otol*.vol.20,pp.211–215,2014.
- [2] JC. Ringenberg. 'Closure of tympanic membrane perforations by the use of fat. *Laryngoscope*.vol. 88,pp.982–993,1978.
- [3] I. Saliba, O.Woods. Hyaluronic acid fat graft myringoplasty: a minimally invasive technique. *Laryngoscope*.vol. 121,pp.375–380,2011.
- [4] Guneri . The effects of hyaluronic acid, epidermal growth factor, and mitomycin in an experimental model of acute traumatic tympanic membrane perforation. *Otol Neurotol*.vol. 24,pp. 371–6,2003.
- [5] prior. Hyaluronic acid ester in myringoplasty. *J Laryngol Otol*.vol.122,pp.3-5,2008.
- [6] Ferrari. A new technique for hemodilution, preparation of autologous platelet-rich plasma and intraoperative blood salvage in cardiac surgery. *Int J Artif Organs*.vol.10(1),pp.47-50 ,1987.
- [7] Erkiel .Platelet-rich plasma improves healing of tympanic membrane perforations: Experimental study. *J Laryngol Otol*.vol.123(5),pp.482-7, 2009.
- [8] L.Creaney, B.Hamilton. Growth factor delivery methods in the management of sports injuries: the state of play. *British journal of sports medicine*.vol. 42(5),pp. 314-320,2008.
- [9] Indorewala . Dimensional stability of the free fascia grafts: A human study.



- Laryngoscope.vol.114,pp.543-7, 2004.
- [10] JL.Inwood, HC.Wallace and SE.Clarke. Endaural or postaural incision for myringoplasty; does it make a difference to the patient? Clin Otolaryngol Allied Sci .vol.28,pp. 396-398,2003.
- [11] S.Sarkar, A.Roychoudhury and BK.Roychaudhuri. Tympanoplasty in children. Eur Arch Otorhinolaryngol .vol.266,pp.627-633,2009.
- [12] R.Landsberg, G.Fishman, A.DeRowe, E. Berco, and G.Berger. Fat graft myringoplasty: results of a long-term follow-up. Journal of otolaryngology ..vol.35,pp.(1), 2006.
- [13] J.C. Ringenberg. Fat graft tympanoplasty. The Laryngoscope.vol.72(2), pp.188-192,1962.
- [14] RM. Terry.Fat graft myringoplasty: Aprospective trial. ClinOtolaryngol.vol.13(3),pp.227-229,1988.
- [15] M.prior, N.Gibbins, G.John. Hyaluronic acid ester in myringoplasty. J. Laryngol. Otol. vol. 122 epub ,2007.
- [16] TC. Laurent .The structure of hyaluronic acid. In: Balazs EA, ed. Chemistry and Molecular Biology of the Intercellular Matrix. New York, NY: Academic Press.vol.1970,pp.703-732,1997.
- [17] I. Saliba .Hyaluronic acid fat graft myringoplasty: how we do it. Clin Otolaryngol.vol.33(6),pp.610-61419126140,2008.
- [18] CA. Jameson. Autologous platelets concentrate for the production of platelet gel. Lab Med.vol.38,pp. 39-42,2007.
- [19] AH. Salaheldin and A. Hussein. Effect of platelet-rich plasma on nasal mucociliary clearance after submucous diathermy of inferior turbinate, Egyptian Journal of Ear, Nose, Throat and Allied Sciences.vol.13,pp.71-75,2012.
- [20] T.M.Bielecki, T. S.Gazdzik, J.Arendt, T.Szczepanski, W.Krol, T.Wielkoszynski. Antibacterial effect of autologous platelet gel enriched with growth factors and other active substances: an in vitro study. Bone & Joint Journal.vol. 89(3),pp. 417-420,2007.
- [21] R.G.Smith, C.J.Gassmann, and M.S.Campbell. Platelet-rich plasma: properties and clinical applications. The Journal of Lancaster General Hospital.vol.2(2), pp.73-77,2007.
- [22] A.Golz, D.Goldenberg, A.Netzer. Paper patching for chronic tympanic membrane perforations. Otolaryngol Head Neck Surg.vol.128(4),pp.565-70,2003.
- [23] M.W.El-Anwar, M.A.S.El-Ahl, A.A.Zidan, and M.A.R.A.S. Yacoup. Topical use of autologous platelet rich plasma in myringoplasty. Auris Nasus Larynx .vol. 42(5), pp.365-368, 2015.
- [24] R.Kumar, R S. Kumar, YogeshA .Comparative Study of Underlay Tympanoplasty with Temporalis Fascia and Tragal Perichondrium.Journal of Dental and Medical Sciences.vol.13(5),pp. 89-98,2014.
- [25] AG.Gibb, Chang. Myringoplasty (A review of 365 operations). Journals of Laryngology and Otology Oct.vol. 96(10).vol.915-30,1982.