
Original Article

PERIPAPILLARY RETINAL NERVE FIBER LAYER THICKNESS CHANGES IN DIABETIC PATIENTS AFTER PANRETINAL PHOTOCOAGULATION

Tamam, K.^{1(*)}, Mohamed, M.¹, Elmoddather, M.¹ & Sayed, Kh.²¹Ophthalmology dept., Faculty of Medicine, AL-Azhar Univ., Assuit, Egypt²Ophthalmology dept., Faculty of Medicine, Sohag Univ., Sohag, Egypt* E-mail: karimangamal88@gmail.com

Received 27/2/2021

Accepted 16/5/2021

Abstract

Aim of the work: This study aimed to assess the effect of Panretinal photocoagulation (PRP) on the peripapillary Retinal Nerve Fiber (RNFL) thickness in diabetic patients using Optical Coherence Tomography Angiography. **Methods:** A prospective study was conducted on 100 eyes of 62 patients who had severe non-proliferative (SNPDR) or proliferative diabetic retinopathy (PDR) and underwent PRP treatment. The study population underwent 4.5x4.5 MM scans centered on the optic nerve head using Optical Coherence Tomography Angiography (OCTA) (RTVue XR Avanti Optovue, Fremont, CA) for measuring the peripapillary RNFL thickness before and after PRP by 2 months and 6 months. **Results:** Mean age of the study population was 49.85± 8.26 years (25-64 years). There was a significant increase in thickness of the nasal, temporal, superior and inferior peripapillary RNFL from baseline to 2 months post-PRP (all P value <0.05) and then decreased significantly from 2 months to 6 months (all P value <0.05). However, the thickness decreased significantly to amount less than baseline after 6 months for superior and inferior quadrants (P value <0.05) and decreased insignificantly for nasal and temporal quadrants (P value > 0.05). **Conclusions:** Peripapillary RNFL thickness at 6 months has decreased post-PRP, suggesting that PRP had neuronal insult.

Keywords: Diabetic retinopathy, proliferative, photocoagulation, Optical Coherence, Angiography

1. Introduction

Diabetic retinopathy (DR) is the most prevalent micro vascular complication of diabetes. DR is presented by progressive vascular abnormalities in the retina. These abnormalities remain asymptomatic at the beginning, but may cause vision-threatening conditions [1]. PRP prevents severe visual loss in patients with proliferative DR, however laser treatment has a few complications

due to retinal inflammation triggered by laser burns itself. In spite of the fact that PRP has been proven to be a beneficial treatment strategy for severe diabetic retinopathy, most ophthalmologists concur that the laser intensity causes damage to the entire retinal layer and should be avoided [2]. In case the high intensity laser beam leads to the destruction of the entire retinal layer, including the GCL, it

will result in a loss of RNFL and cause a consecutive diminishing the RNFL thickness [3]. In addition, PRP-induced retinal inflammation and macular edema can occur because PRP increases retinal vascular permeability due to the collection of leukocytes [4]. This study aimed to assess

the effect of Panretinal photocoagulation on the peripapillary retinal nerve fiber layer thickness in diabetic patients after PRP using a relatively new imaging technique (Optical Coherence Tomography Angiography).

2. Subjects and Methods

This was a prospective study that included 100 eyes of 62 patients with diabetic retinopathy at Sohag investigation center from December 2017 to December 2019. The patients received conventional Panretinal photocoagulation (PRP). All patients should have severe non-proliferative or proliferative diabetic retinopathy. Subjects with a history of intraocular surgery including cataract, glaucoma, and vitreoretinal surgery, significant cataracts or other media opacity, pathologic myopia, uveitis, retinal detachment, glaucoma, clinically significant macular edema, and any diabetic patient treated by any type of intravitreal injection were excluded. Subjects received a complete

ophthalmologic examination including determination of best-corrected visual acuity (BCVA), slit-lamp biomicroscopy, fundus photography, intraocular pressure (IOP), fluorescein angiography and OCTA at baseline and each follow-up visit. Collected data included age, gender, duration and type of diabetes. An argon laser delivery system was done for PRP by the same physician. It was done at 2 to 3 consecutive sessions. All subjects had the following settings; Spot size 250 μm , laser energy ranges from 200 to 500 mW which will be titrated to achieve an optimal burn and laser duration will be 0.15 seconds.

2.1. Optical coherence tomography angiography

The instrument used for the OCTA images was based on the RTVue XR Avanti (Optovue Inc., Fremont, CA). The tissue resolution is 5 μm axially and there

is a 15- μm beam width. The scanning area was captured in 4.5 \times 4.5 mm sections, which was on the optic disc head.

2.2. Follow up

OCTA was used for measuring the peripapillary RNFL thickness before and after PRP by 2 month and 6 months. We

used the thickness map for follow up, fig. (1).

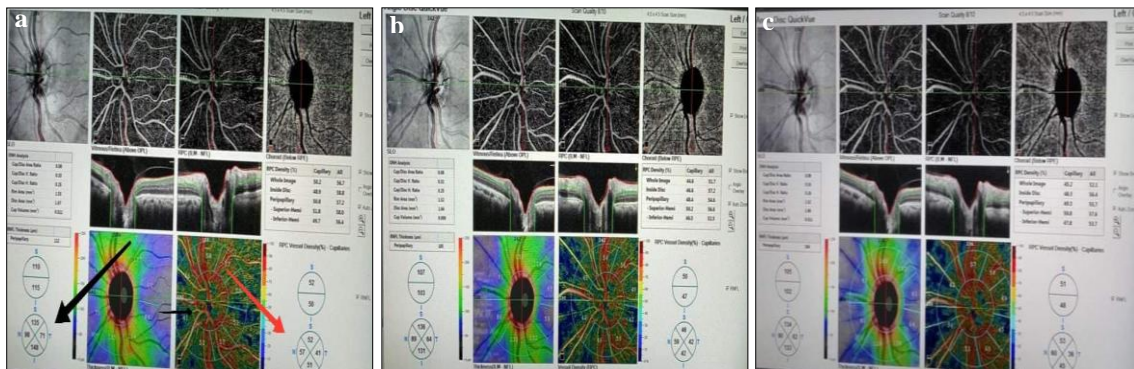


Figure 1. Print out of OCTA; **a.** pre-PRP, **b.** 2 months Post-PRP, **c.** 6 months post-PRP, left black arrow indicates peripapillary RNFL thickness map and right red arrow indicates peripapillary capillary density map.

2.3. Statistical analysis

It was carried out using SPSS (the Statistical Package for Social Sciences) Version 24. Repeated-measures analysis of the variance (ANOVA) corrected by the Bonferroni method was used to compare the peripapillary RNFL thickness before and after laser during the follow-up period

(2 months and 6 months post-PRP). The significant difference value was determined by P-value <0.05. All subjects were informed of the goals and procedures in the study, and written informed consent was obtained from all subjects before enrollment.

3. Results

The study included a total of 100 eyes of 62 patients who underwent pan-retinal photocoagulation. Age was ranged

from 25 to 64 years. Table (1) demonstrates the demographic and clinical characteristics of the patients.

Table 1: Descriptive statistics of the study

Characteristics	Value
No. of Eyes	100
Age in Yrs (mean± SD)	49.85± 8.26
Duration of DM (mean± SD)	14.53± 7.19
Male/ Female	45/55
Right/Left	52/48
Type1/Type2	19/81
PDR/Severe NPDR	53/47
Insulin TTT/Oral TTT	79/21
NVD	13
Non significant DME	26
smokers	10
Systemic Hypertension	35

Values are presented as the mean ± standard deviation. NPDR = non-proliferative diabetic retinopathy; PDR = proliferative diabetic retinopathy. DME = Diabetic macular edema, NVD = Neovascularization on the disc.

3.1. Changes in the thickness of the peripapillary RNFL

The average thickness of the peripapillary RNFL changed significantly after 6 months (ANOVA test; $p < 0.001$), fig. (2). By comparing each follow up, there was a significant increase in thickness from 110.09 ± 17.40 (Mean±SD) at baseline to 113.79 ± 17.50 at 2 months Post-PRP ($p < 0.001$). On the other hand, there was a significant decrease in thickness from 113.79 ± 17.50 at 2 months Post-PRP to 108.18 ± 19.46 at 6 months post-PRP ($p < 0.001$). However, the average peripapillary RNFL thickness showed no significant decrease from 110.09 ± 17.40 at baseline to 108.18 ± 19.46 at 6 months post-PRP ($p = 0.08$). By evaluating quadrant by

quadrant, the nasal quadrant thickness of the RNFL at each follow-up changed significantly ($p < 0.001$), fig. (3). By comparing each follow up, there was a significant increase in thickness from 99.28 ± 28.47 at baseline to 102.86 ± 29.04 at 2 months Post-PRP ($p = 0.01$). On the other hand, there was a significant decrease in thickness from 102.86 ± 29.04 at 2 months to 97.05 ± 30.23 at 6 months post-PRP ($p = 0.001$). However, the nasal peripapillary RNFL thickness showed no significant decrease from 99.28 ± 28.47 at baseline to 97.05 ± 30.23 at 6 months post-PRP ($p = 0.1$). The Temporal quadrant thickness of the RNFL at each follow-up

changed insignificantly ($p=0.05$), fig. (4). By comparing each follow up, there was significant increase in thickness from 77.78 ± 19.37 at baseline to 80.25 ± 20.52 at 2 months Post-PRP ($p=0.02$). On the other hand, there was significant decrease in thickness from 80.25 ± 20.52 at 2 months to 77.65 ± 20.40 at 6 months post-PRP ($p=0.01$). However, the Temporal peripapillary RNFL thickness showed no significant decrease from 77.78 ± 19.37 at baseline to 77.65 ± 20.40 at 6 months post-PRP ($p=0.9$). The Superior quadrant thickness of the RNFL at each follow-up changed significantly ($p<0.001$), fig. (5). By comparing each follow up, there was a significant increase in thickness from 127.2 ± 22.83 at baseline to 130.79 ± 24.25 at 2 months Post-PRP ($p=0.001$). Also, there was a significant decrease in thickness from 130.79 ± 24.25 at 2 months

to 123.42 ± 25.80 at 6 months post-PRP ($p<0.001$). The Superior peripapillary RNFL thickness showed no significant decrease from 127.2 ± 22.83 at baseline to 123.42 ± 25.80 at 6 months post-PRP ($p=0.007$). The Inferior quadrant thickness of the RNFL at each follow-up changed significantly ($p<0.001$), fig. (6). By comparing each follow up, there was a significant increase in thickness from 127.2 ± 22.83 at baseline to 130.79 ± 24.25 at 2 months Post-PRP ($p=0.008$). On the other hand, there was a significant decrease in thickness from 130.79 ± 24.25 at 2 months to 123.42 ± 25.80 at 6 months post-PRP ($p<0.001$). The Inferior peripapillary RNFL thickness showed no significant decrease from 127.2 ± 22.83 at baseline to 123.42 ± 25.80 at six months post-PRP ($p=0.05$).

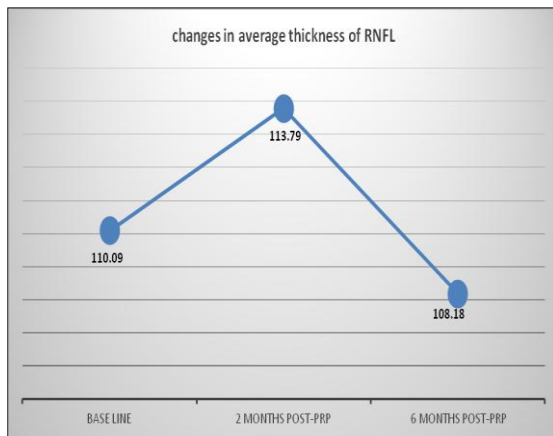


Figure 2. Changes in the average peripapillary RNFL

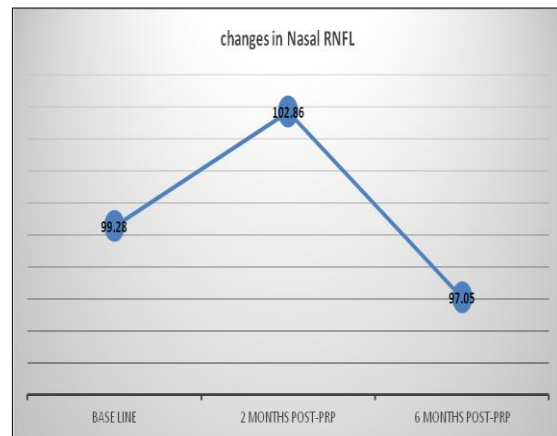


Figure 3: Changes in the nasal peripapillary RNFL

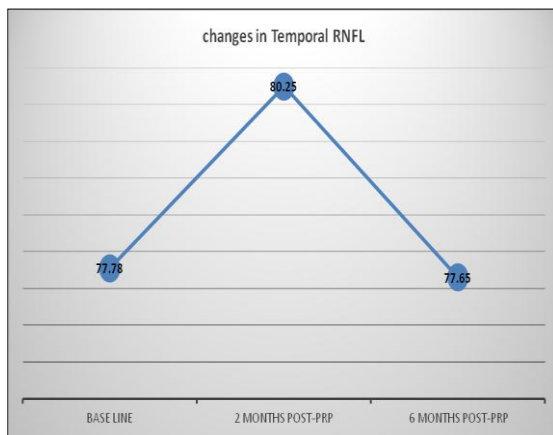


Figure 4. Changes in the temporal peripapillary RNFL.

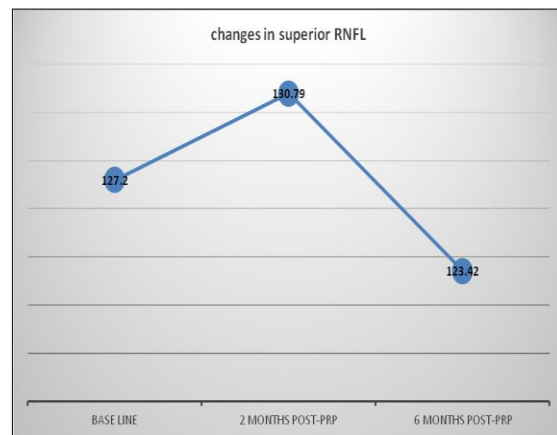


Figure 5: Changes in the superior peripapillary RNFL.

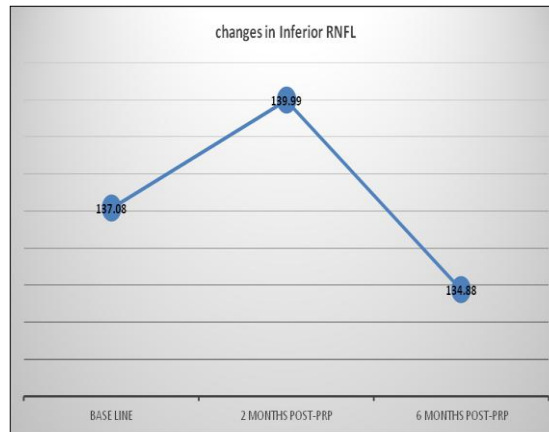


Figure 6: Changes in the inferior peripapillary RNFL

4. Discussion

Several imaging methods are used to assess RNFL: scanning laser polarimetry (SLP), confocal scanning laser ophthalmoscopy, and optical coherence tomography (OCT) [5]. Several studies have studied the use of SLP or time-domain OCT (TD-OCT) or spectral-domain OCT (SD-OCT) for the detection of post-PRP RNFL changes [3, 6]; however, there are only a few studies employing the use of OCTA. OCTA devices help to make more precise assessment of peripapillary RNFL thickness and flow with respect of retinal quadrants, as they provide high definition images of retinal layers and capillary density [7]. The effect of diabetes on RNFL has been evaluated in some studies. It has been suggested that diabetes does not cause thinning of RNFL in the absence of PRP [8]. As it was reported previously by Lim, et al. who did not find any significant difference in RNFL thickness between diabetic and control eyes [9]. Similarly, Park and Jee did not find a significant change in RNFL in patients with DM through 1-year follow-up [3]. In this study, we analyzed Changes between each follow up visits following PRP for patients with PDR or severe NPDR. We found that there was a significant increase in average peripapillary RNFL thickness from baseline to two months Post-PRP and significant decrease in thickness from two months Post-PRP to six months post-PRP. This finding was explained by

that PRP has been found to cause an increase in the RNFL thickness in the short term due to laser-induced retinal inflammation and edema that resolved later on [10]. However, there was no significant reduction from baseline to six months post-PRP. In addition, we compared quadrant by quadrant peripapillary RNFL thickness. By analyzing difference between each follow up, there was a significant increase in thickness from baseline to 2 months Post-PRP and significant decrease in thickness from 2 months Post-PRP to 6 months post-PRP. However, there was no significant reduction in RNFLT within each retinal quadrant at 6 months post-PRP compared to its baseline values except for superior peripapillary RNFL thickness that showed significant reduction from baseline to 6 months post-PRP. This significant decrease in the superior quadrant is similar to the previously published data. Authors have reported that superior retina has more microaneurysms and acellular capillaries and greater alterations in the retinal blood flow possibly accounting for the reported changes [11]. In the long term, PRP has been found to have a negative effect on RNFL thickness which may be attributed to axonal loss secondary to direct or indirect effects of PRP treatment [12]. Our result was similar to Kim and Cho who found that there was no statistically significant change in time-domain based

RNFL thickness scores when the mean RNFL thickness of 118 patients with severe NPDR at the sixth month of post laser was compared with mean RNFL thickness scores of 164 diabetic patients without retinopathy [13]. However, we were different in that, this study showed a significant decrease in superior quadrant. Moreover, Maia et al. performed RNFL Thickness assessment with time-domain OCT at the first week as well as the first, third and sixth months after PRP. They illustrated that there is no reduction in RNFL thickness after 6 months [14]. Most of reports that showed insignificant changes in the RNFL thickness post PRP had short term and medium term follow up. In contrary in long term follow up, in a time-domain OCT based retrospective study conducted by Kim et al., statistically significant reduction in the average RNFL thickness at 2 years after PRP treatment was reported, whereas the mean RNFL thickness score slightly increased during the initial 3 months after photocoagulation [15]. Also, Meenakshi et al. reported that average RNFL measurements showed a significant decrease for up to 3 years after PRP. Superior and inferior quadrants showed a continued reduction in RNFL thickness 3 years post PRP. Nasal RNFL measurements showed an initial decrease at 1 year post PRP but stabilized thereafter. Temporal quadrant RNFL measurements did not show any significant change at 1 or 3 years post PRP [12]. However, Muqit et al. prospectively assessed the RNFL thickness changes on 10 eyes with PDR after PRP treatment performed with 514 nm green laser. The Stratus OCT system was utilized in their study to measure peripapillary RNFL thickness [16]. Authors mentioned statistically significant RNFL thickness increase (+8 μm ; $p < 0.05$) at 10 weeks after photocoagulation, however significant reduction in RNFLT (-4 μm ; $p < 0.05$) was assessed after the sixth month of post treatment follow up. They concluded that conventional PRP may increase the RNFL thickness in

the short term with progressive diminishing of the nerve fiber layer in the long term. They attributed the early thickening of RNFL following the PRP to inner retinal axon damage by thermal diffusion around the 100-ms burn and axonal edema. With time, axonal edema and direct damage initiated by the laser treatment can cause axonal cell death and progressive diminishing of the nerve fiber layer [16]. Lee et al. [6] informed that the peripapillary RNFL thickness increased at six months after conventional PRP and then diminished at 24 months when compared to baseline. In addition, Park and Jee compared the effect of conventional PRP and pattern scanning laser (PASCAL) photocoagulation on RNFL. The PASCAL system reduces the total pulse energy effectively by lessening the laser shot duration. They found that conventional PRP produced significant RNFL thinning, whereas the PASCAL system was protective against RNFL loss [3]. We find that most studies reported that conventional PRP produced RNFL thinning but they differ in the timing that RNFL thinning start to occur after PRP. One hypothesis to explain the different findings in the literature related to RNFL changes after PRP is that different laser delivery settings that may cause different degrees of inner retinal changes and duration of follow up after PRP. While in our study a spot size of 250 μm was used, a larger spot size or laser intensity may be related to greater inner retinal damage and, therefore, more decrease in RNFL thickness due to retrograde axonal loss. In addition to the previous studies, hazards of photocoagulation were reported including the fusion and expansion of laser burns in late phases. Laser burns may enlarge even until the fourth year of post treatment follow-up, and the annual rate for laser burn expansion was found to be as high as 16.5%. Therefore progressive damage in RNFL and visual field loss can be seen after PRP treatment [17]. This study had some limitations as the

follow-up was a relatively short-term. second, During the imaging process, many artifacts may interfere with OCTA measurements. Further longitudinal studies using a larger number of subjects and

longer follow-up period are needed to determine if there is a Significant decrease in peripapillary RNFL Thickness that lead to atrophy of peripapillary RNFL beyond a two-year period.

5. Conclusion

In our study, a significant increase in peripapillary RNFL Thickness at the second month of follow up may be related to laser induced intraretinal inflammation which triggers increased capillary permeability and ensuing axonal edema due to the cytokine release. Significant decrease in peripapillary RNFL Thickness from two months to the sixth month of follow-up can be attributed to resolved laser induced intraretinal inflammation. However, insignificant decrease from base line to six months post PRP as short term follow up which one of our limitation of this study. As reported before, significant change need longer fellow up period. OCTA is a very valuable tool to document the RNFL thickness and capillary density changes following PRP. We recommend future studies should focus on comparing the conventional PRP and PASCAL photocoagulation system regarding their effects on the retinal blood flow and RNFL thickness.

References

1. Venugopal D., Lal B., Fernandes S., et al. Awareness and knowledge of diabetic retinopathy and associated factors in Goa: A hospital-based cross-sectional study. *Indian J. of Ophthalmology*. 2020; 68 (2): 383----
2. Shin J. & Lee Y. Changes in macular retinal layers and peripapillary nerve fiber layer thickness after 577-nm pattern scanning laser in patients with diabetic retinopathy. *Korean J. of Ophthalmology*. 2017; 31 (6): 497-507.
3. Park Y-R. & Jee D. Changes in peripapillary retinal nerve fiber layer thickness after pattern scanning laser photocoagulation in patients with diabetic retinopathy. *Korean J. of Ophthalmology*. 2014; 28 (3): 220-225.
4. Nonaka A., Kiryu J., Tsujikawa A., et al. Inflammatory response after scatter laser photocoagulation in nonphotocoagulated retina. *Investigative Ophthalmology & Visual Science*. 2002; 43 (4): 1204-1209.
5. Kanamori A., Nagai-Kusuhara A., Escaño M., et al. Comparison of confocal scanning laser ophthalmoscopy, scanning laser polarimetry and optical coherence tomography to discriminate ocular hypertension and glaucoma at an early stage. *Graefe's Archive for Clinical and Experimental Ophthalmology*. 2006; 244 (1): 58-68.
6. Lee S., Kwag J., Lee H., et al. The longitudinal changes of retinal nerve fiber layer thickness after panretinal photocoagulation in diabetic retinopathy patients. *Retina*. 2013; 33 (1): 188-193.
7. Huang D., Jia Y., Gao S., et al. Optical coherence tomography angiography using the optovue device. *OCT Angiography in Retinal and Macular Diseases*. 2016; 56: Karger Publishers: p. 6-12.
8. Sugimoto M., Sasoh M., Ido M., et al. Detection of early diabetic change with optical coherence tomography in type 2 diabetes mellitus patients without retinopathy. *Ophthalmologica*. 2005; 219 (6): 379-385.
9. Lim M., Tanimoto S., Furlani B., et al. Effect of diabetic retinopathy and panretinal photocoagulation on retinal nerve fiber layer and optic nerve appearance. *Archives of Ophthalmology*. 2009; 127 (7): 857-862.
10. Yazdani S., Samadi P., Pakravan M., et al. Peripapillary RNFL thickness changes after panretinal photocoagulation. *Optometry and Vision Science*. 2016; 93 (9): 1158-1162.

11. Kim J., Im J., Shin J., et al. One-year follow-up of macular ganglion cell layer and peripapillary retinal nerve fibre layer thickness changes after panretinal photocoagulation. *British J. of Ophthalmology*. 2014; 98 (2): 213-217.
12. Wadhvani M., Bali S., Bhartiya S., et al. Long term effect of panretinal photocoagulation on retinal nerve fiber layer parameters in patients with proliferative diabetic retinopathy. *Oman J. Ophthalmol*. 2019; 12 (3): 181-185.
13. Kim H. & Cho H. Peripapillary retinal nerve fiber layer thickness change after panretinal photocoagulation in patients with diabetic retinopathy. *Korean J. of Ophthalmology*. 2009; 23 (1): 23-26.
14. Júnior M., de Oliveira O., Vessani R., et al. Examination of the retinal nerve fiber layer in diabetic retinopathy treated by argon laser panphotocoagulation. *Arquivos Brasileiros de Oftalmologia*. 2008; 71 (2): 187-190.
15. Kim J., Woo S., Ahn J., et al. Long-term temporal changes of peripapillary retinal nerve fiber layer thickness before and after panretinal photocoagulation in severe diabetic retinopathy. *Retina*. 2012; 32 (10): 2052-2060.
16. Muqit M., Wakely L., Stanga P., et al. Effects of conventional argon panretinal laser photocoagulation on retinal nerve fibre layer and driving visual fields in diabetic retinopathy. *Eye*. 2010; 24 (7): 1136-----.
17. Maeshima K., Utsugi-Sutoh N., Otani T., et al. Progressive enlargement of scattered photocoagulation scars in diabetic retinopathy. *Retina*. 2004; 24 (4): 507-511.