

Protective Effect Of Melatonin, Methionine And Zink On Cadmium Nephrotoxicity: Histopathologically, Histochemically And AgNORs Quantitation

Sonia L. El Sharkawy; Hafiza A. sharaf; and Nabila S. Hassan.

The Basic Medical Sciences Department, Pathology Researches, National Research Center

Abstract

Cadmium (Cd) is a highly toxic heavy metal that is naturally present in the environment. Chronic exposure to Cd causes hepatotoxicity and nephrotoxicity. The present study aimed to study the protective effect of melatonin, methionine and zinc against histopathological, histochemical and proliferative effects of cadmium on the kidney of rats. A total of 80 female albino rats were included in this study and divided into 8 groups. They were injected intraperitoneally with cadmium chloride (CdCl₂) (2 mg / kg b.w.), melatonin (10 mg / kg b.w.), methionine (42.8 mg / b.w.) or zinc (20 mg / kg b.w.) with or without CdCl₂ daily for 10 days.

Treatment with CdCl₂ induced marked tubular cell degeneration with large areas of interstitial hemorrhage. There were marked destruction of the brush borders with decrease in glycogen and protein contents of the degenerated tubules. AgNORs count significantly increased.

Injection of melatonin or methionine to CdCl₂ treated rats resulted in improvement of Cd-induced histopathological and histochemical changes. AgNORs count significantly decreased. Zinc injection partially protected the kidney from Cd-induced effects.

In conclusion, melatonin and methionine have a more protective effect than zink against Cd nephrotoxicity.

Introduction

Cadmium (Cd) is a highly toxic element that is naturally present in the environment, including food, water, and soil (Sherlock, 1984). It is a trace element which has no known metabolic function. However, it is toxic to cellular processes by disrupting mitochondrial function (Miccadei and Floridi, 1993 ; Koizumi et al., 1994) and can interfere with the transport and metabolism of many essential elements, such as iron and copper (Crowe and Morgan, 1997). Cd was recently designated as a human carcinogen where it has been linked to prostate, lung, and male reproductive

tumours (IARC, 1993 ; Waalkes and Rehm, 1994). In animals Cd is associated with tumours of the prostate, testes, lung, and the injection site (Magos, 1991 ; Waalkes and Misra, 1996).

The nucleolus plays a vital role in the control of cell proliferation and protein synthesis, as it is the only part of the nucleus where ribosomal ribonucleic acid (rRNA) is transcribed. The region of the nucleolus perform this function is nucleolar organizer regions (NORs) (Egan and Crocker, 1992). These NORs are defined as nucleolar components

containing a set of argyrophilic proteins, which are selectively stained by silver methods. After silver staining, the NORs can be easily identified as black dots exclusively localized throughout the nucleolar area, and are called "Ag-NORs" (Trere, 2000). Silver staining of NORs and subsequent quantification by image analysis are used increasingly in human pathological specimens and experimental models as a marker of cellular proliferation (Duskova and Povysil, 1995; Orsea et al., 2001).

Kidney is the main target organ of Cd toxicity. Cd induced nephrotoxicity is thought to be caused by the Cd-metallothionein complex (CdMT) that leaks out of the liver and is taken by the kidney (Lui et al., 1998). CdMT is freely filtered through the renal glomeruli and efficiently absorbed by the proximal tubular epithelial cells, where it is rapidly degraded by lysosomal enzymes (Cherian and Shaikh, 1975 ; Squibb et al., 1979). Cd selectively affects the proximal tubular cells without inducing changes in the glomerular or distal tubular cells (Friberg, 1984 ; Dudley et al., 1985). The morphological changes produced by Cd are mainly degenerative. There are only a few reports of morphological effects of tubular atrophy and interstitial fibrosis (Goyer, 1989).

Previous studies showed that the oxidative stress is the primary mechanism of chronic Cd-induced hepatotoxicity and nephrotoxicity (shaikh et al.1999). The pineal hormone melatonin MLT, N-acetyl methoxytryptamine, exhibits antioxidant and anti-inflammatory effects (Reiter et al., 1994 ; Cuzzocera and Caputi, 1999). Melatonin was also reported to be more effective than glutathion (GSH) in scavenging the highly toxic hydroxyl radical (Tan et al., 1993) and more efficient than vitamin E in neutralizing

the peroxy radical (Piere et al., 1994). Moreover, this indole was shown to be an efficient protector of nuclear DNA (Tan et al. 1994), protein (Abe et al. 1994), and lipids in cellular membranes against free radical attack (Melchiorri et al. 1995).

Methionine is one of the essential amino acids which has a protective effect against many oxidant drugs (Sai et al. 1995). It is an important methyl donor for some of the reactions involved in protein and DNA synthesis. An in vitro cell culture study showed that the growth of most malignant cells was arrested when methionine was replaced by its immediate precursor, homo-cysteine (Hoffman,1984). A subsequent study by Guo et al., (1993) showed that proliferation of human cancer cells was arrested at the S/G2 cell cycle in methionine-free cell culture media. Methionine has been reported to reduce glutathione (GSH) levels in tumors, because methionine is degraded to cysteine, which is a precursor for GSH synthesis (Yoshido, 1999).

Zinc has a protective role against heavy metals toxicity. Zinc pretreatment protects against CdMT nephrotoxicity (Squibb and Fowler,1984).The proposed mechanism involves the induction of MT by zinc and sequestration of Cd²⁺ released from lysosomal degradation of exogenous CdMT by newly synthesized renal MT (Lui et al., 1996). Other factors, such as glutathione (GSH), may also be involved because protection is offered even in MT-null mice (Tang et al., 1998).

This study aimed at studying Cd induced histological and histochemical changes in renal tissue. Also Cd effect on cellular proliferation was studied using Ag-NOR silver staining. The protective effect of melatonin, methionine, and zinc against Cd toxicity was evaluated.

Material And Methods

Chemicals: The chloride salts of cadmium and zinc as well as D-melatonin were purchased from Sigma chemical Co. (St. Luis, Mo). L-methionine was obtained from BDH Co., England.

Animals: A total of 80 female albino rats weighing 150-200g b.w (purchased from animal house Colony, N. R. C., Dokki, Cairo) were used in this study. All animals were maintained on ad libitum concentrate ration (protein:16.04%; fat: 3.63%; fibers: 4.1% and metabolic energy 2887 Kcal/Kg), and housed in a room free from any sources of chemical contamination, artificially illuminated and thermally controlled, at the animal house Lab. National Research Center, Dokki, Cairo, Egypt.

Experimental Design:

Rats were randomly divided into eight equal groups treated for 10 successive days with the following treatments:

G1: control

G2: intraperitoneally (i.p.) injected with cadmium chloride (CdCl₂) (2 mg/kg b.w) dissolved in 0.1 ml saline according to Yamano *et al.* (1998)

G3: i.p. injected with D-melatonin (10 mg/kg b.w) according to Kim *et al.* (1998)

G4: i.p. injected with L-methionine (42.8 mg/kg b.w) dissolved in 0.1 ml saline according to Reynolds (1991).

G5: i.p. injected with zinc chloride (20 mg/kg b.w) dissolved in 0.1 ml saline according to Poirer (1996).

G6: i.p. injected with CdCl₂ plus melatonin.

G7: i.p. injected with CdCl₂ plus methionine .

G8: i.p. injected with CdCl₂ plus zinc chloride.

On the end of 10th day, all animals were sacrificed by decapitation. The kidneys

of each animal were removed and fixed in 10% neutral formalin and processed to prepare 4µm-thick paraffin sections.

Sections were stained with:

Hematoxylin and eosin stain for histological exam.

Periodic acid Schiff (PAS) stain for demonstration of glycogen content (Pears 1980).

Mercuric-Bromophenol blue stain for the total protein determination (Pears 1980).

Argyrophilic silver stain for Ag-NORs staining and quantitation (Ploton *et al.* 1986). In brief, hydrated sections were put in a solution of ethanol and acetic acid in a proportion of 50% before the incubation with the solution formulated by dissolving 2g gelatin in 1% aqueous formic acid to two parts of 50% aqueous silver nitrate solution. The sections were incubated in this solution for 30 min at 45°C and then washed in distilled water, dehydrated in ethanol, cleared in xylene and mounted in Canada balsam. No counterstaining was performed.

Using the CAS 200 Image Analyzer, AgNORs were counted in 100 nuclei from the most significant areas of each specimen under 1000X magnification. By careful focusing, only well-defined and sharply stained intra- and extra-nucleolar AgNOR dots were included in the counting regime, as well as larger dots representing the total nucleolus where AgNOR dots were wholly aggregated. The means of the AgNORs counts in different groups were compared statistically using the student t-test. P value < 0.05 was considered statistically significant.

Results

Histopathological examination

Microscopic examination of kidney sections of the control group as well as groups treated with melatonin, methionine or zinc alone showed

normal histological structure of renal tubules and glomeruli (figure 1).

Histological examination of kidney sections of rats treated with CdCl₂ revealed marked tubular cell degeneration in the form of cloudy swelling and hydropic degeneration. Some tubules showed tubular cell necrosis with pyknotic nuclei. All over the kidney sections there were dilated and congested blood vessels with many large areas of interstitial hemorrhage (figure 2).

Kidney sections of rats treated with CdCl₂ plus melatonin or methionine revealed improvement of the degenerative changes of the tubular epithelial cells (figure 3). Whereas examination of kidney sections of rats treated with CdCl₂ plus zinc did not show any improvement of Cd-induced pathological changes (figure 4).

Histochemical results

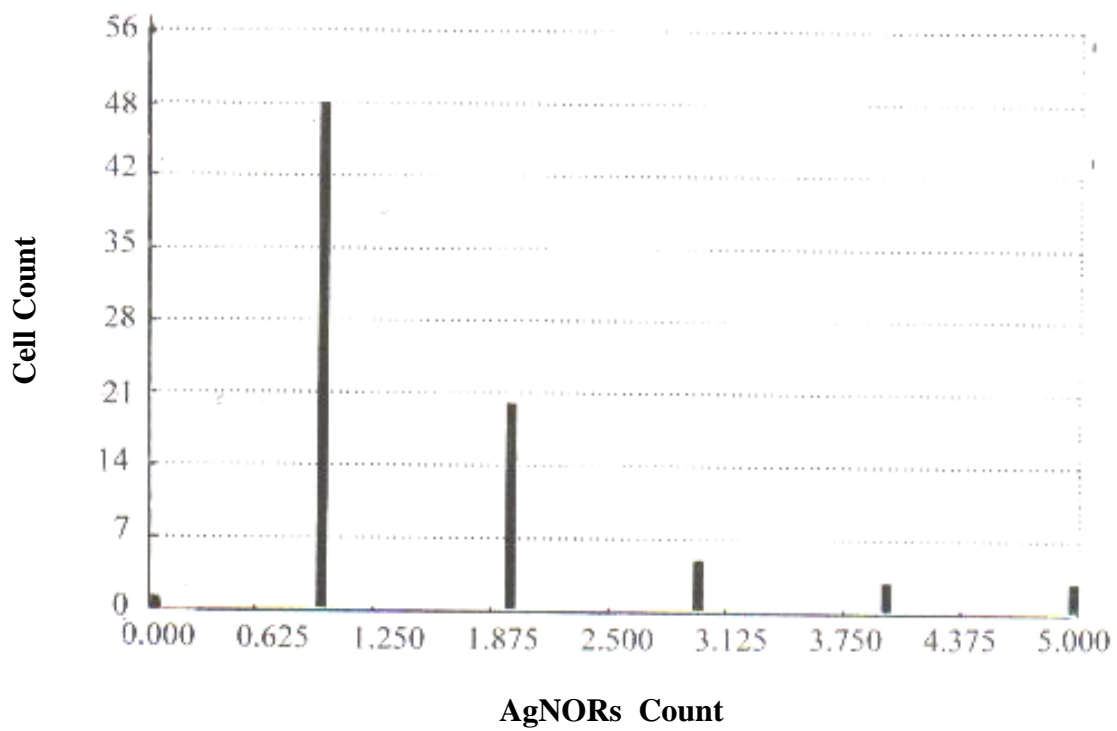
The histochemical study of kidney sections of control rats revealed PAS-positive material in the brush borders of the proximal tubules and the basement membrane of the renal tubules and glomeruli (figure 5). PAS staining of kidney sections of rats treated with CdCl₂ showed marked destruction of the brush borders of the proximal tubules with marked decrease of the glycogen content (figure 6). Treatment with CdCl₂ plus melatonin or methionine resulted in improvement of the brush borders with increase of the glycogen content (figure 7). Whereas examination of kidney sections of rats treated with CdCl₂ plus zinc revealed no improvement of the destructed brush

borders and the glycogen content (figure 8).

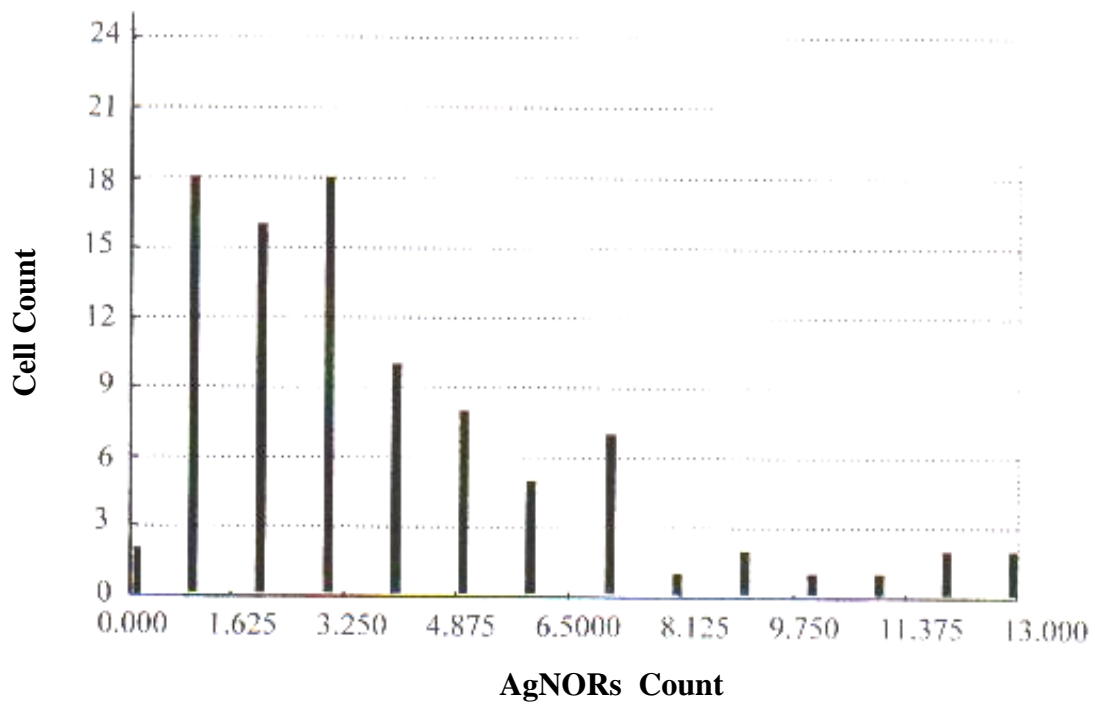
Bromophenol blue stained kidney sections from control rats revealed strong protein deposits in the cytoplasm and nuclei of the renal tubular epithelial cells (figure 9). The renal tubules of the kidney of rats treated with CdCl₂ showed decrease in the protein contents of the degenerated tubules (figure 10). There was an improvement of the protein content of the renal tubules in rats treated with CdCl₂ plus melatonin nearly similar to the control group (figure 11). Whereas kidney sections of rats treated with CdCl₂ plus methionine or zinc revealed decreased protein content of the renal tubular epithelial cells (figure 12).

AgNORs staining and quantitation

Argyrophilic silver staining of kidney sections revealed AgNORs as black or brown dots within the nuclei of the epithelial cells. Histograms (1-5) showed the mean \pm SD of AgNORs counts in different groups. The lowest AgNORs count was observed in the control group (1.5 ± 1.04) (figure 13). In CdCl₂ treated group, it was significantly higher than that of the control group (3.9 ± 2.9 , $P < 0.05$) (figure 14). AgNORs count in rats treated with CdCl₂ plus melatonin or methionine was significantly less than that of CdCl₂ treated ones (2.1 ± 1.4 and 2.3 ± 2.1 respectively, $P < 0.05$). While in CdCl₂ plus zinc treated group, the AgNORs count was non-significantly less than that of CdCl₂ treated group (3.5 ± 3.1 , $P > 0.05$).

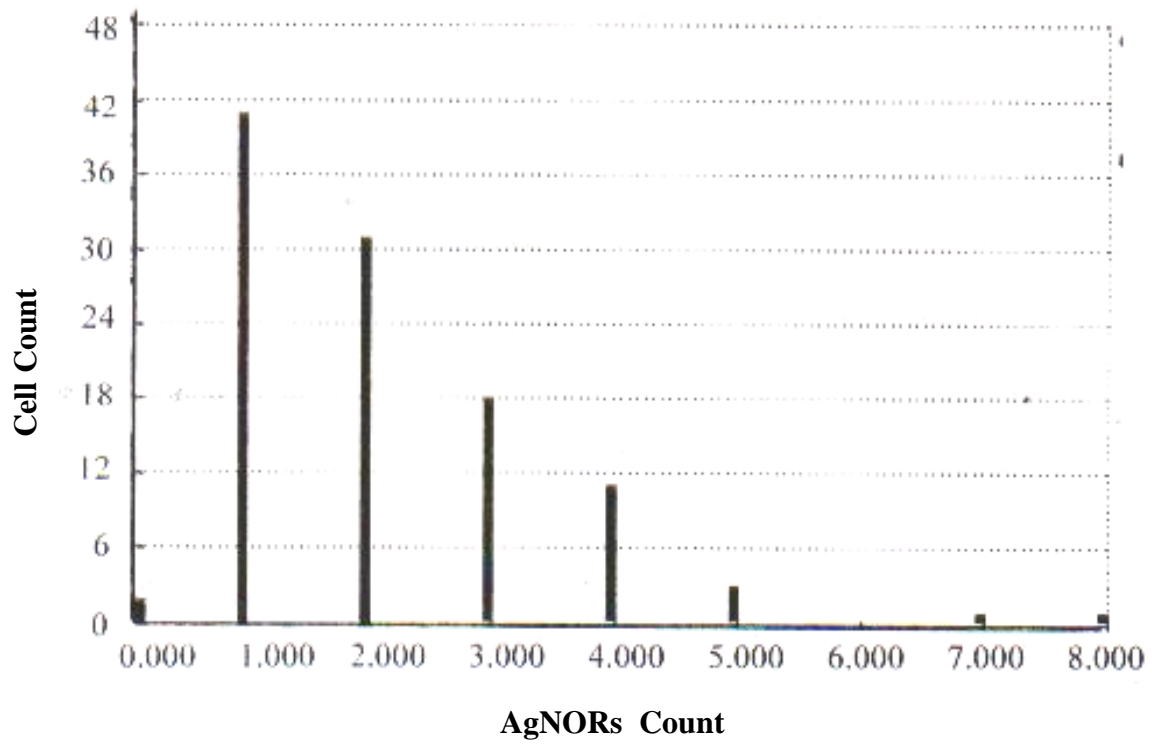


Histogram (1): Mean AgNORs count in control group (1.5 ± 1.04).

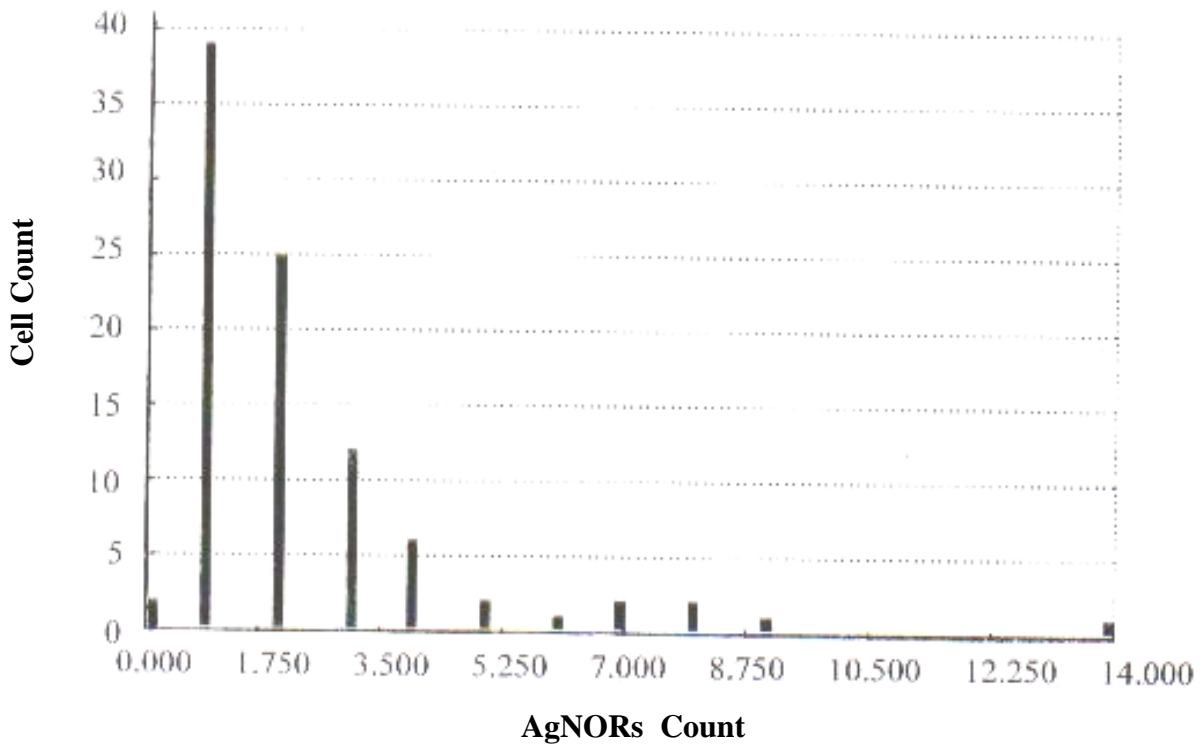


Histogram (2): Mean AgNORs count in CdCl₂ treated group (3.9 ± 2.9).

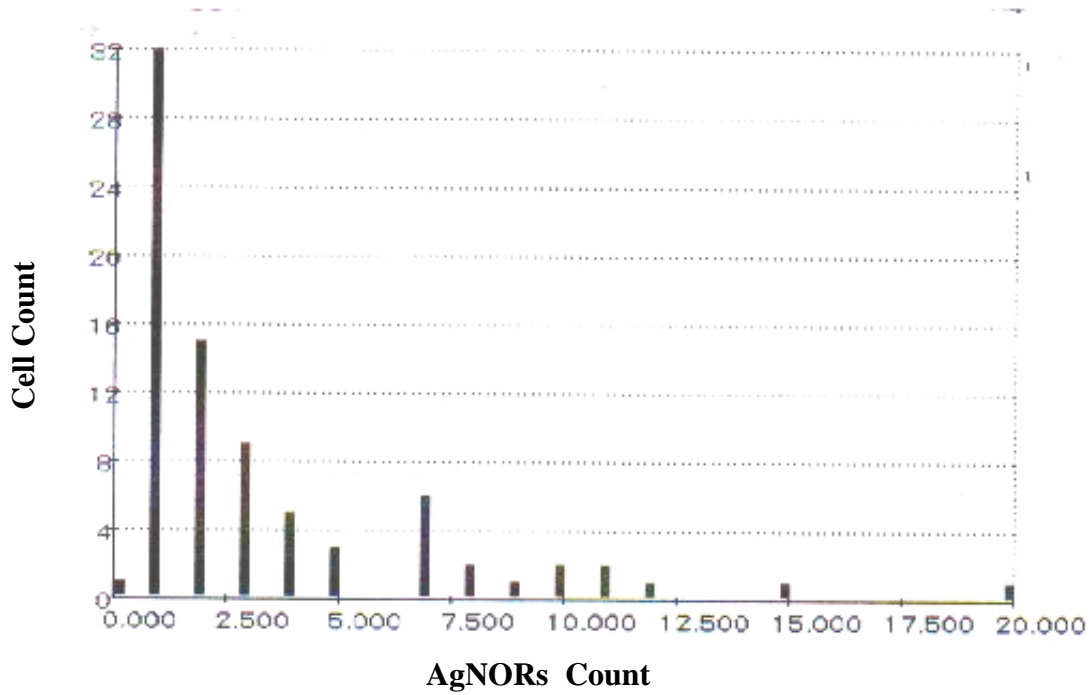
Protective Effect Of Melatonin, Methionine



Histogram (3): Mean AgNORs count in rats treated with CdCl₂ plus melatonin (2.1 ± 1.4).



Histogram (4): Mean AgNORs count in CdCl₂ plus methionine treated group (2.3 ± 2.1).



Histogram (5): Mean AgNORs count in rats treated with CdCl₂ plus zinc (3.5 ± 3.1).

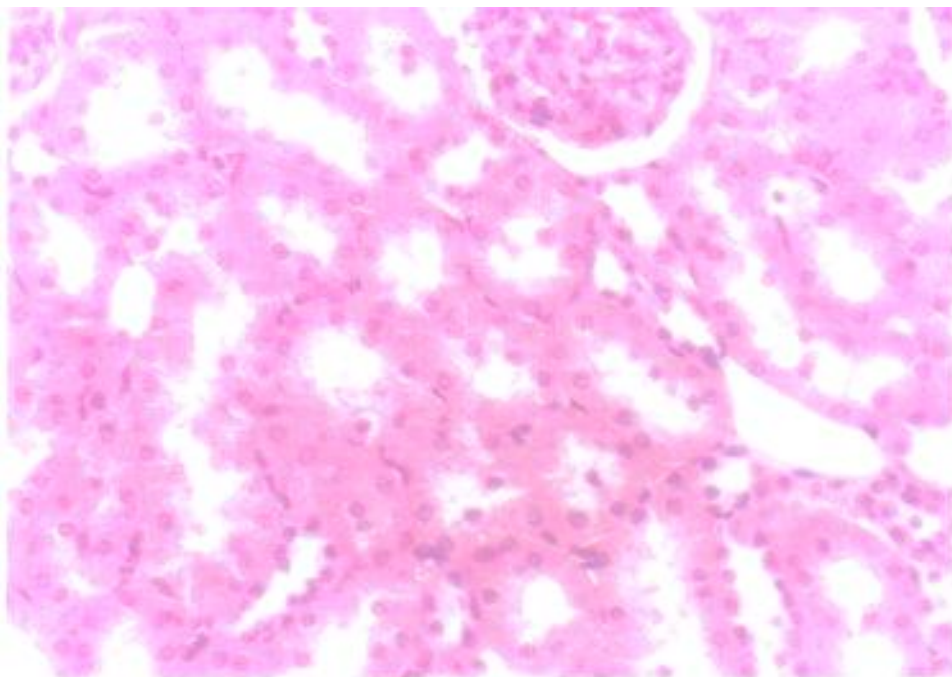


Figure (1): Cross section in the cortex of control kidney illustrated the normal appearance of the glomeruli and renal tubules.

(H & E X 300).

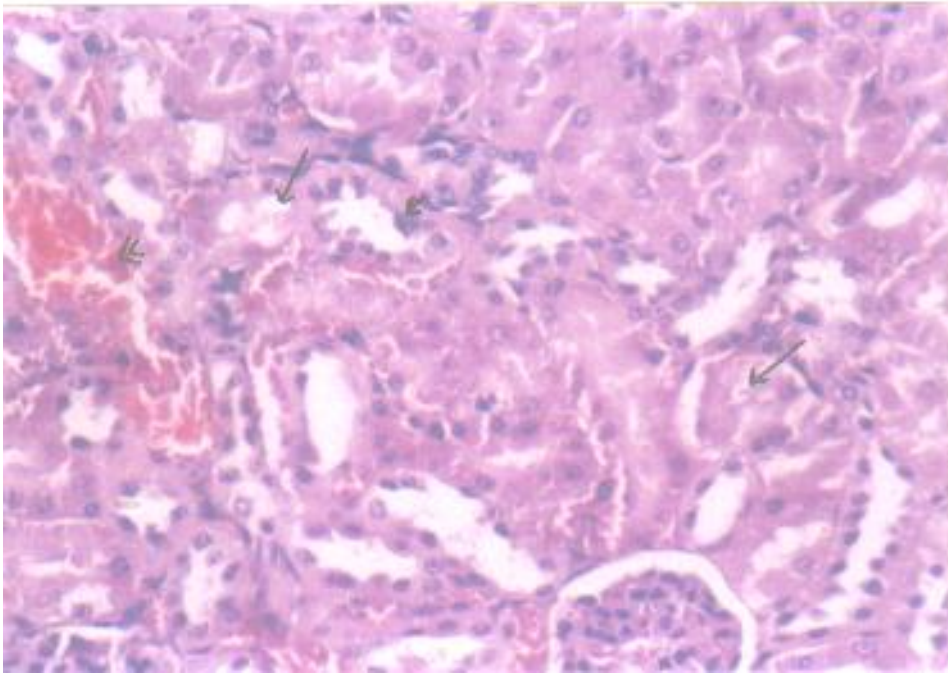


Figure (2): Kidney section of CdCl₂ treated group showing tubular epithelial cell degeneration (long arrows). Some tubules showed cell necrosis (short arrow). There was a large area of interstitial hemorrhage (head arrows). (H & E X 300).

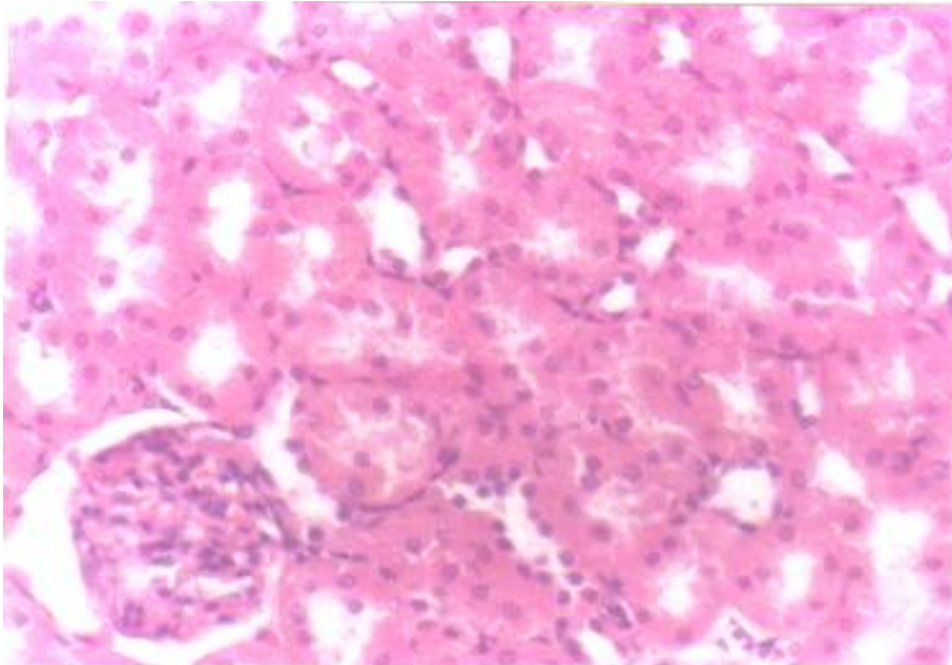


Figure (3): In rat treated with CdCl₂ plus melatonin, kidney section revealing improvement of tubular epithelial cell lining. (H & E X 300).

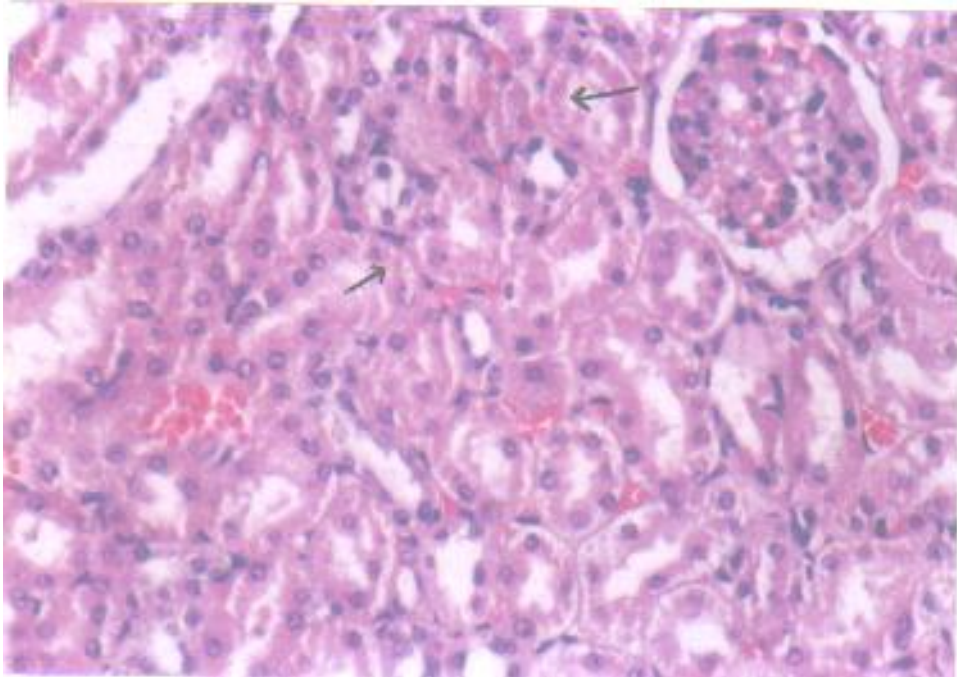


Figure (4): Kidney section of rat treated with CdCl₂ plus zinc showing tubular epithelial cell degeneration (arrows) with small area of interstitial hemorrhage.

(H & E X 300).

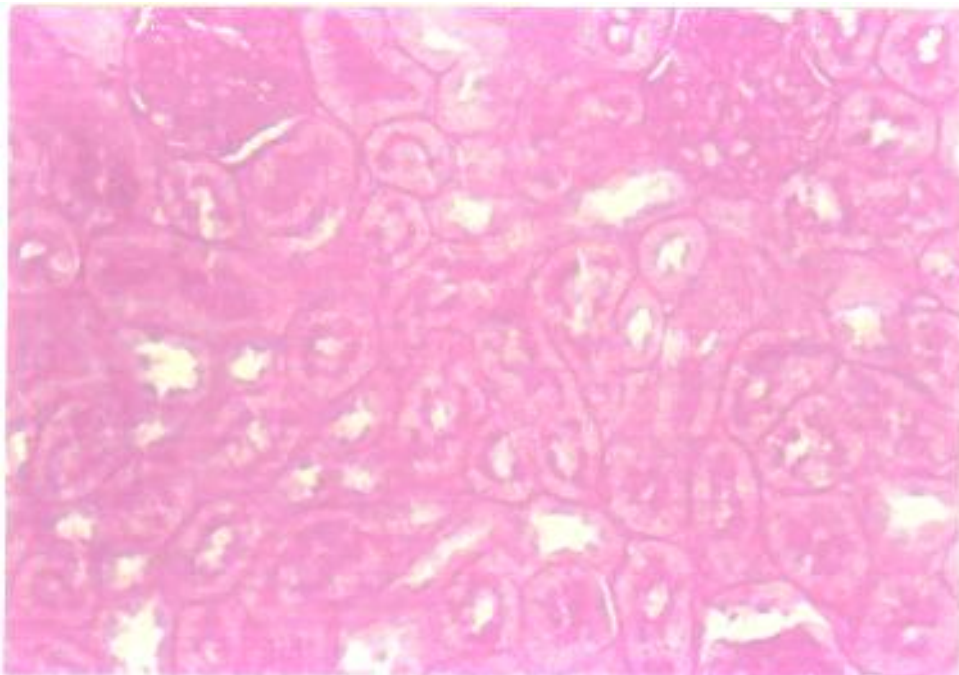


Figure (5): Section of renal cortex of control group showing strong PAS reactivity in renal glomeruli and tubules.

(PAS X 300).

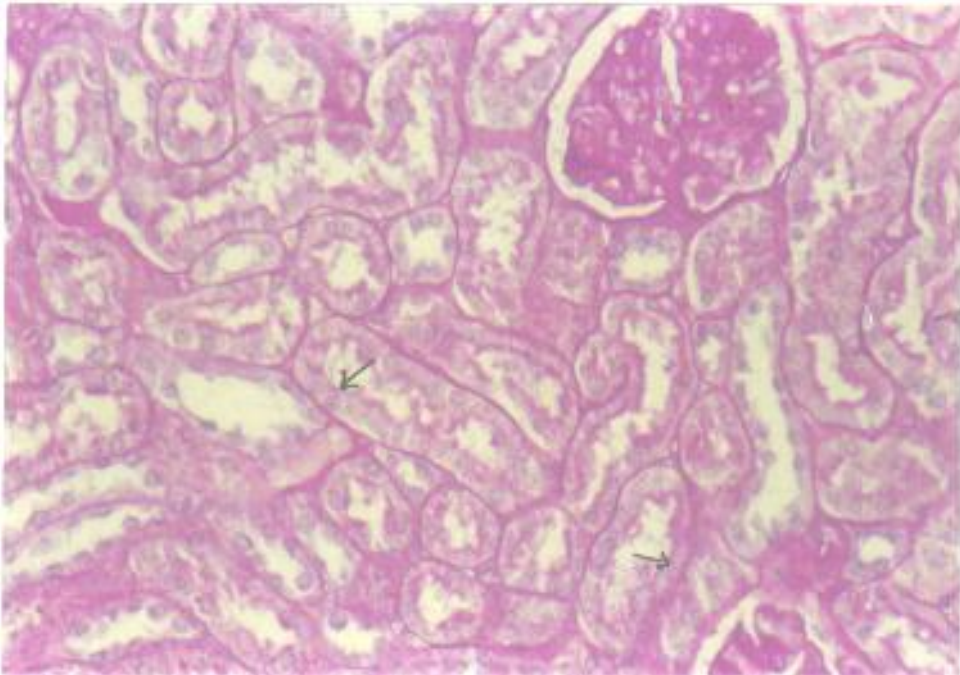


Figure (6): In CdCl₂ treated rats kidney section revealing destruction of brush borders of renal tubules (arrows) and decreased glycogen content.
(PAS X 300).

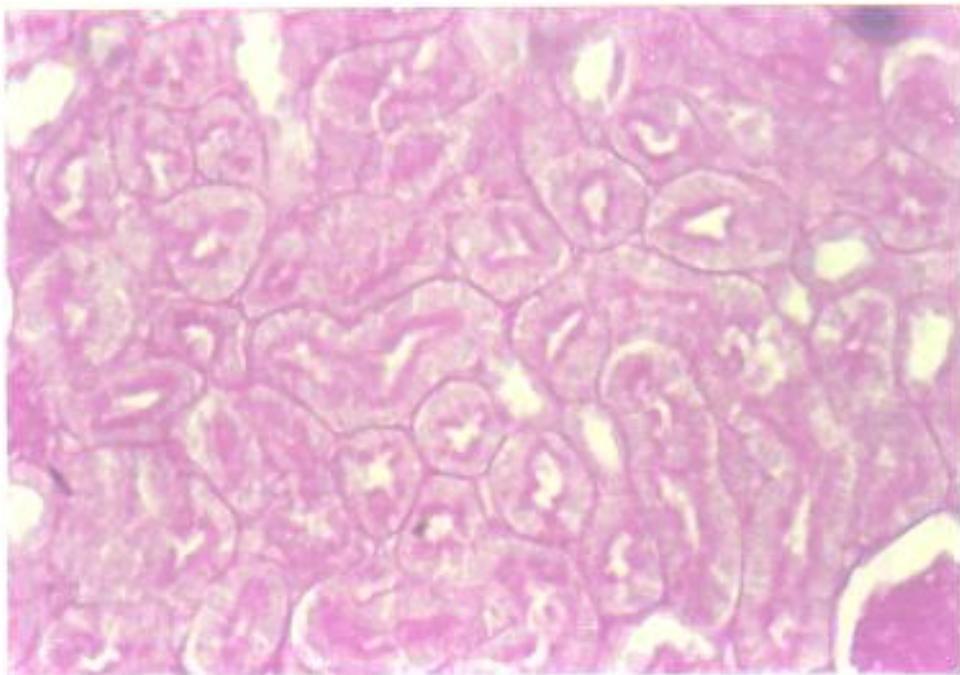


Figure (7): Kidney section of rats treated with CdCl₂ plus methionine illustrating increased glycogen content with improvement of brush borders of renal tubules.
(PAS X 300).

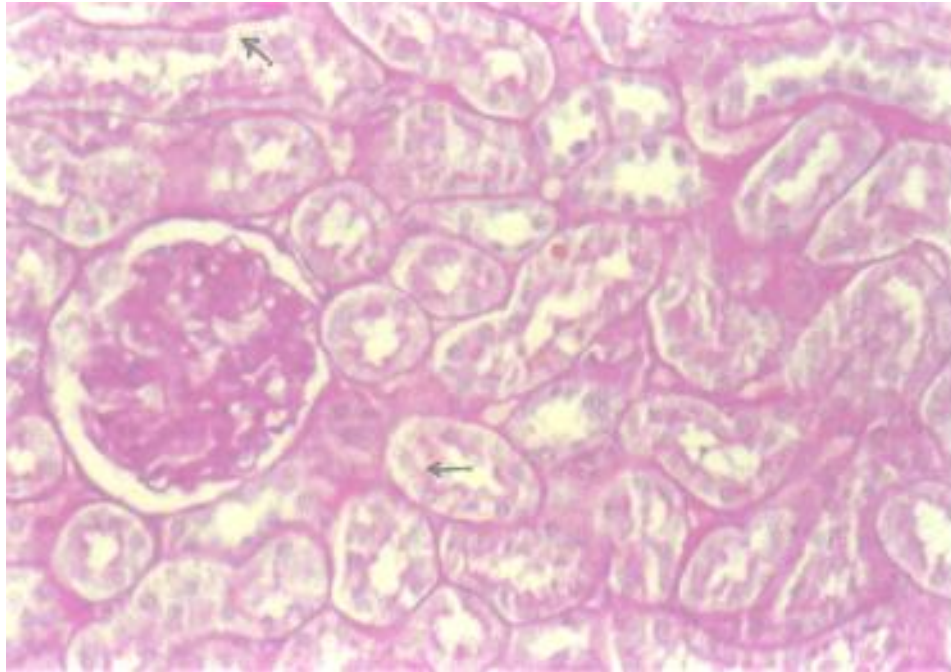


Figure (8): Section of renal cortex of CdCl₂ plus zinc treated group revealing decreased glycogen content and destroyed brush borders of renal tubules (arrows).

(PAS X 300).

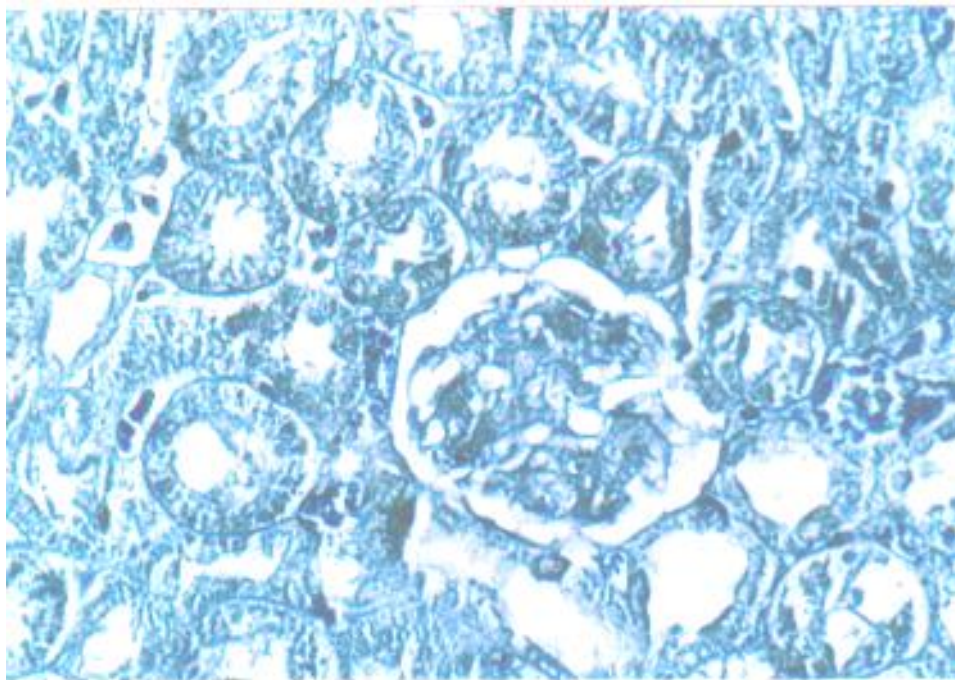


Figure (9): Section of renal cortex of control rat showing normal distribution of protein granules.

(Bromophenol blue stain X 300).

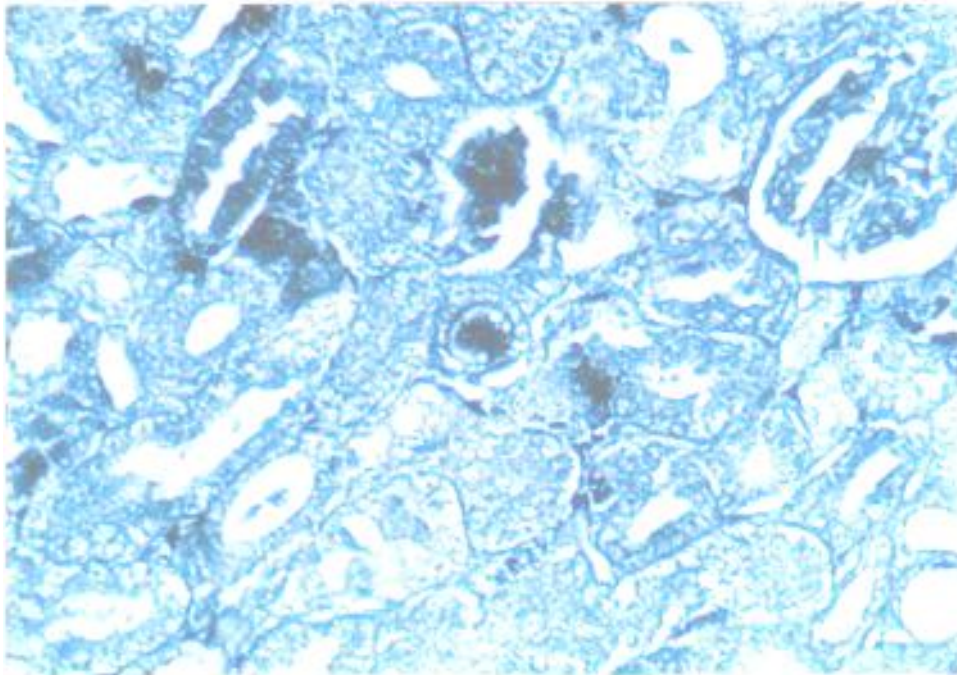


Figure (10): Kidney section of CdCl₂ treated rat revealing decreased protein content of degenerated tubules.

(Bromophenol blue stain X 300).

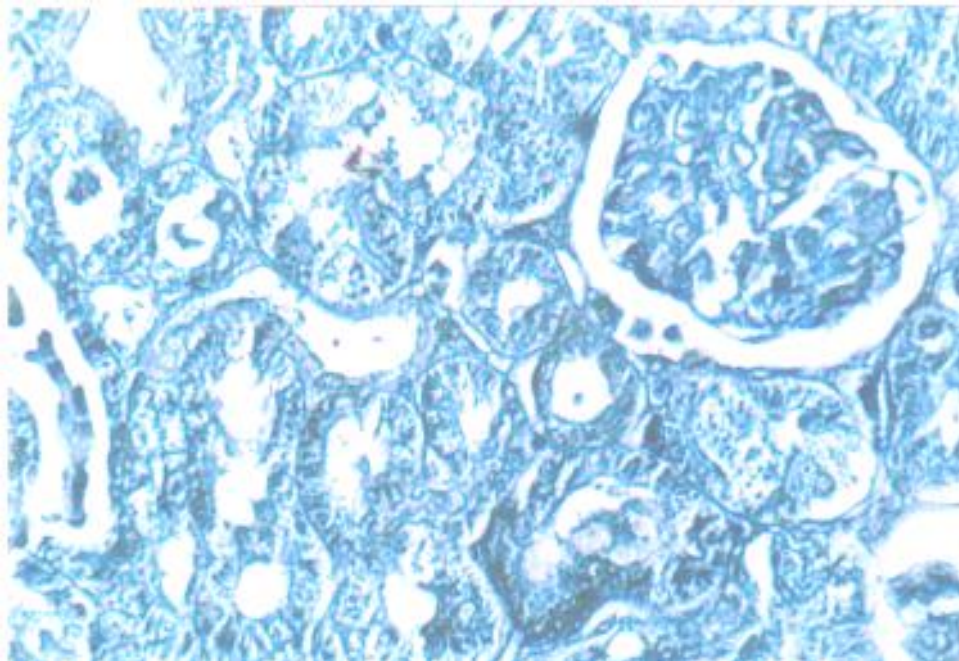


Figure (11): In rats treated with CdCl₂ plus melatonin, kidney sections showed increased protein content nearly similar to normal.

(Bromophenol blue stain X 300).

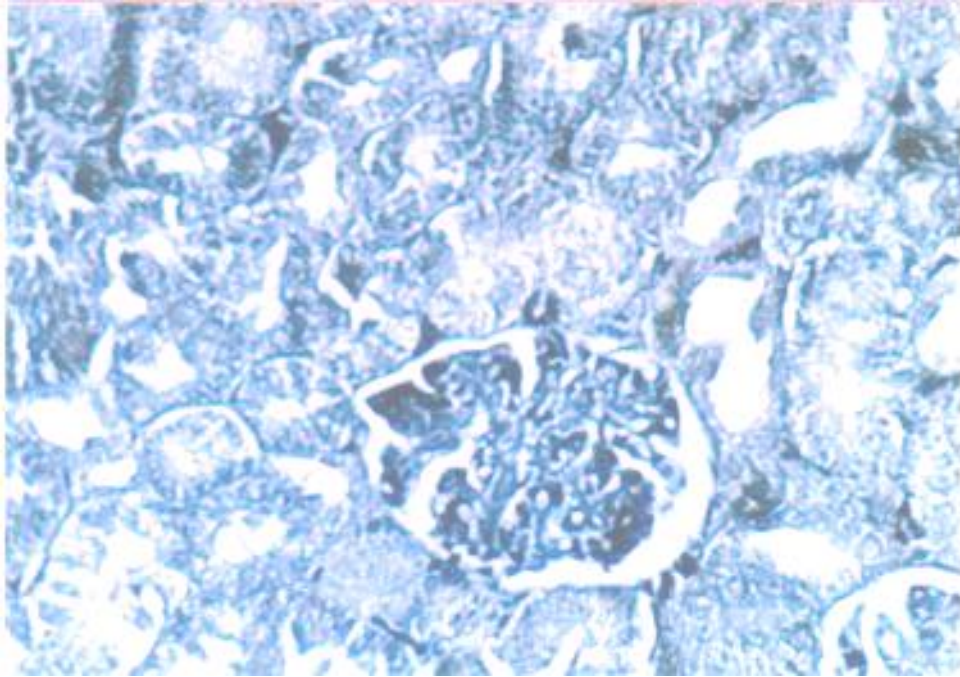


Figure (12): Kidney section with low protein content in rats treated with CdCl₂ plus zinc.

(Bromophenol blue stain X 300).

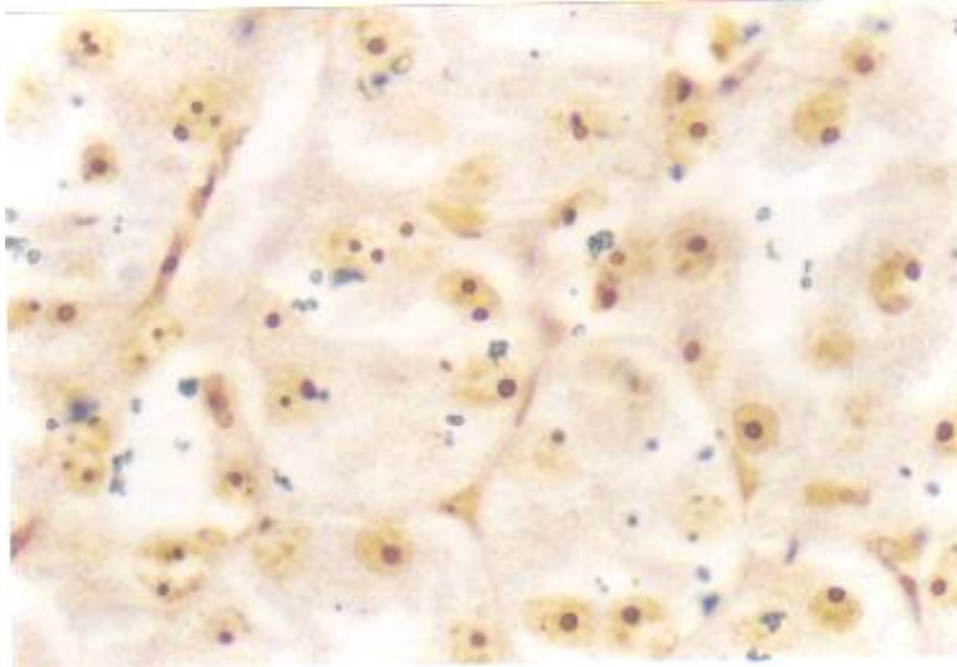


Figure (13): Kidney section of control group showing AgNOR dots. Note that most of the nuclei had one or two AgNOR dots.

(Silver stain X 1000).

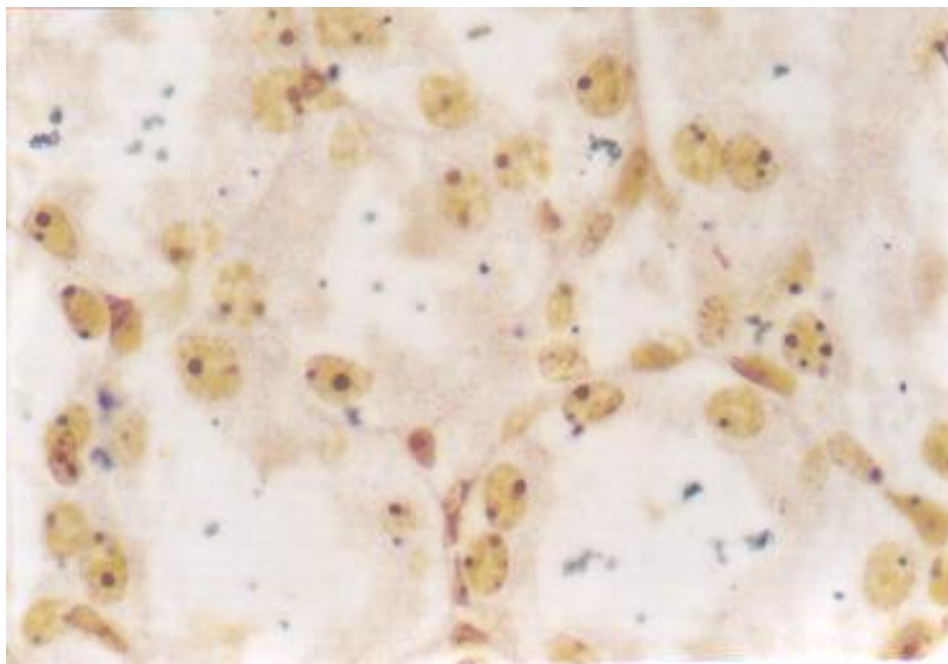


Figure (14): Kidney section of rats treated with CdCl₂. The nuclei contain 1-4 AgNOR dots.

(Silver stain X 1000).

Discussion

Cadmium is a known human carcinogen and one of the components of tobacco which together with water and food contamination represent the main sources of non-occupational exposure in the general population (Tiran et al., 1995). Chronic exposure to cadmium (Cd) causes hepatotoxicity and nephrotoxicity (Friberg 1984 ; Dudley et al., 1985). Cd accumulates mainly in the liver and to a lesser extent in the kidney and other organs. In all tissues Cd induces and binds to metallothionein (MT) and is stored as a non-toxic CdMT complex (Webb 1986; Shaikh and Smith 1997). As a result of normal turnover of hepatocytes and hepatic injury CdMT is translocated from the liver to the kidney (Dudley et al., 1985 ; Chan et al., 1993). CdMT is reabsorbed by the renal proximal tubules and is quickly degraded by lysosomal enzymes, liberating Cd ions

that bind to preexisting or newly synthesized renal MT (Squibb et al., 1979 and Zhou et al., 1999). Non-MT bound Cd induces nephrotoxicity when MT synthesis becomes insufficient to keep up with the demand (Nomiyama and Nomiyama, 1986 ; Goyer, 1989 ; Dorian et al., 1992). Moreover, free Cd ions liberated in the proximal tubular cytoplasm may directly interact with luminal plasma membrane and impair Na⁺ transport system, which may be one of the mechanisms for Cd-induced attenuation of the proximal tubular transport capacity (Ahn et al., 1999).

In the present study, we evaluate the protective effects of melatonin, methionine, and zinc against Cd-induced renal toxicity. The selected dose of Cd, melatonin, methionine and zinc were based on the previous work reported in the literature (Friberg, 1984 and Ahn et al., 1999).

The histological changes observed in the kidney of rats treated with CdCl₂ have been documented previously (Webb and Chain, 1982; Friberg, 1984; Dudely et al., 1985). We also observed tubular cells degeneration, hydropic degeneration, necrotic cells with pyknotic nuclei and interstitial hemorrhages. Although the principal target organ for CdCl₂ is the liver, necrosis and hemorrhages may also occur in other organs (i.e. heart, testis, and lungs) depending on variables such as animal species, dose, route, and treatment protocol (Hirastuka et al., 1999). The histochemical results reported in the present study revealed a marked decrease in PAS-positive materials in the brush borders of the renal tubular epithelial cells suggesting the damage of cell membrane including its microvilli. These results were in agreement with the results of Friberg et al., (1974) and Pisator (1986) who reported that Cd affects the carbohydrate metabolism resulting in the depletion of tissue glycogen as well as the changes in renal function involves abnormalities of tubular reabsorption manifested by such conditions as low-molecular weight proteinuria, glucosuria, aminoaciduria, and phosphaturia. These results also supported our findings regarding the decrease in protein content in the cytoplasm of renal tubules.

Among the protective agents evaluated in this study, zinc was shown to be ineffective in preventing the renal toxicity in rats. While the changes in kidney induced by CdCl₂ were eliminated by cotreatment with melatonin or methionine. Although several reports have been documented that zinc protects against Cd toxicity (Paras and Beck, 1996), our results revealed that zinc was not effective. This may be due to the difference in treatment protocol.

The previous results when compared with our results clearly indicated that zinc pretreatment might be more effective than zinc cotreatment in preventing Cd-induced renal toxicity. On the other hand, treatment with melatonin or methionine plus Cd were found to induce a protection against Cd-toxicity. The mechanism by which these agents can induce these protective effects may be due to their role in restoring the reduction of renal glutathione (GSH) level (Kim et al., 1998). Moreover, methionine undergoes several biochemical reactions involved in the biosynthesis of cysteine (Murray et al., 1993) which has a protective role in detoxification mechanism (Maiorino et al., 1990). Methionine also might increase the bioavailability of glutathione facilitating the prevention of binding of Cd to different compartments and reversing Cd-induced disorders. Melatonin induces its protective effects via the protection of antioxidant capacity in cells and its ability to scavenge hydroxyl radicals directly due to its structural features (Dorian et al., 1995).

Counting mitoses in routine hematoxylin and eosin-stained sections provides the simplest assessment of cell proliferation. Argyrophilic nucleolar organizer regions counts (AgNOR) give an indirect estimate of cell proliferation (Dervan et al., 1989). However the exact significance of changes in AgNOR counts from one lesion to another is not fully understood. AgNOR counts rise with increased cell ploidy, increased transcriptional activity and in stages of active cell proliferation (Derenzini, 2000). Moreover, AgNOR counts may not be a good indicator of cell proliferation but rather represent variation in metabolic or transcriptional activity (Coleman et al., 1996).

In the present study silver staining of nucleolar organizer regions (NORs)

and their subsequent counting by image analysis was performed as an indicator of cellular proliferation and transcriptional activity. It was found that AgNORs count significantly increased after CdCl₂ treatment. Treatment with melatonin or methionine plus CdCl₂ resulted in significant decrease in AgNORs count. In rats treated with CdCl₂ plus zinc, it was found that the AgNORs count was non-significantly less than that of CdCl₂ treated group. *In conclusion*, this study demonstrated that melatonin and methionine have a more protective role than zinc against Cd nephrotoxicity.

References

1. **Abe, M.; Reiter, R.J.; Orhii, P.H.; Hara, M.; Poeggeler, B.; and Barlow-walden, L.P. (1994).** Inhibitory effect of melatonin on cataract formation in newborn rats : evidence of an antioxidative role for melatonin. *J. Pineal. Res.* 17 : 94-100.
2. **Ahn, D.W.; Kim, Y.M.; Kim, K.R.; and Park, Y.S. (1999).** Cadmium binding and sodium-dependent solute transport in renal brush border membrane vesicles. *Toxicol. Appl. Pharmacol.* 154 : 212-218.
3. **Chan, H.M.; Zhu, L.F.; Zhong, R.; Grant, D.; Goyer, R.A.; and Cherian, M.G. (1993).** Nephrotoxicity in rats following liver transplantation from cadmium exposed rats. *Toxicol. Appl. Pharmacol.* 123 : 89-96.
4. **Cherian, M.G.; and Shaikh, Z.A. (1975).** Metabolism of injected cadmium-binding proteins. *Biochem. Biophys. Res. Commun.* 65 :863-869.
5. **Coleman, H.G.; Altini, M.; and Goeneveld, H.T. (1996).** Nucleolar organizer regions (AgNORs) in odontogenic cysts and ameloblastomas. *J. Oral. Pathol. Med.* 25 : 436-440.
6. **Crowe, A.; and Morgan, E.H. (1997).** Effect of dietary cadmium on iron metabolism in growing rats. *Toxicology and applied pharmacology* 145,136-146.
7. **Cuzzocera, S.; and Caputi, A.P. (1999).** Protective effect of melatonin on zymosan-induced cellular damage. *Biol. Signals. Recept.* 8 (I-2) : 136-142.
8. **Derenzini, M. (2000).** The Ag NORs. *Micron* 31 : 117-120.
9. **Dervan, P.A.; Gilmartin, L.G.; Loftus, B.M.; and Carney, D. (1989).** Breast carcinoma kinetics. Argyrophilic nucleolar organizer region counts correlated with Ki-67 scores. *Am. J. Clin. Pathol.* 92 : 401-407.
10. **Dorian, C. Gattone, V.H.; and Klassen, C.D. (1992).** Accumulation and degradation of the protein moiety of cadmium-metallothionein (CdMT) in the mouse kidney. *Toxicol. Appl. Pharmacol.* 117 : 242-248.
11. **Dorian, C.; Gattone, V.H.; and Klassen, C.D. (1995).** Discrepancy between the nephrotoxic potencies of cadmium-metallothionein (CdMT) and cadmium chloride and the renal concentration of cadmium in the proximal convoluted tubules. *Toxicol. Appl. Pharmacol.* 130 : 161-168.
12. **Dudley, R.E.; Gammal, L.M.; Klassen, C.D. (1985).** Cadmium-induced hepatic and renal injury in chronically induced rats : Likely role of hepatic cadmium-metallothionein in nephrotoxicity. *Toxicol. Appl. Pharmacol.* 77 : 414-426.

13. **Duskova, J.; and Povysil, C. (1995).** Measurement of nucleolar organizer regions (Ag NOR) using the LUCIA-M colour image analysis system. *Cesk Patol.* Feb. 31(1): 17-20.
14. **Egan M.J. ; and Crocker, J. (1992).** Nucleolar organizer regions in pathology : Review. *Br. J. Cancer* 65:1-7.
15. **Foulkes, E.C. (1978).** Renal tubular transport of cadmium-metallothionein. *Toxicol. App. Pharmacol.* 45 : 505-512.
16. **Friberg, L. (1984).** Cadmium and the kidney. *Environ. Health Perspect.* 54 : 1-11.
17. **Friberg, L.; Piscator, M.; Nordberg, G.F.; and Kjellstrom, T. (1974).** Cadmium in the environment, second ed. CRC Press, Cleveland, OH.
18. **Goyer, R.A. (1989).** Mechanisms of lead and cadmium nephrotoxicity. *Toxicol. Lett.* 46 : 153-162.
19. **Guo, H.; Herrera, H.; Groce, A.; Hoffman, R.M. (1993).** Expression of the biochemical defect of methionine dependence in fresh patient tumours in primary histoculture. *Cancer Res.* 53 : 2479-2484.
20. **Hirastuka, H.; Satoh, S.; Satoh, M.; Nishijima, M.; Katsuki, Y.; etal. (1999).** Tissue distribution of cadmium in rats given minimum amounts of cadmium-polluted rice or cadmium chloride for 8 months. *Toxicol. Appl. Pharmacol.* 190 : 183-191.
21. **Hoffman, R.M. (1984).** Methionine dependence in cancer cells : A review. *In Vitro* 18: 421-430.
22. **IARC (1993).** International Agency for Research on Cancer Monographs. Vol. 85. Beryllium, Cadmium, Mercury and Exposures in the Glass Industry. PP. 119-238.
23. **Kim, C.Y.; Lee, M.J.; Lee, W.C.; and Kim, J.S. (1998).** Effect of melatonin on cadmium-induced hepatotoxicity in male Sprague-Dawley rats. *Tohoku J. Exp. Med.* 186 (3) : 205-213.
24. **Koizumi, T., Yokota, T.; and Suzuki, K.(1994).** Mechanism of cadmium-induced cytotoxicity in rat hepatocytes. *Biol. Trace Elem. Res.* 42,31-41
25. **Liu, J. ; Habeebu, S.S.; Liu, Y. ; and Kluussem, D. (1998).** Acute CdMT injection is not a good mode to study chronic Cd nephropathy: Comparison of chronic CdCL2 and CdMT exposure with a cute CdMT injection in rats. *Toxicol. App. Pharmacol.* Nov., 153(1) : 48-58.
26. **Lui, J.; Lui, Y.; Michalaska, A.E.; Choo, K.H.A.; and Klaassen, C.B. (1996).** Metallothionein plays less of a protective role in cadmium-metallothionein - induced nephrotoxicity than in cadmium chloride-induced hepatotoxicity. *J. Pharmacol. Exp. Ther.* 276 : 1216-1223.
27. **Magos, L. (1991).** Epidemiological and experimental aspects of metal carcinogenesis : physiological properties, kinetics and the active species. *Envir. Health. Prespect.* 95, 157-189.
28. **Maiorino, R.M.; Jonathan, M.A.; Blaha, K.; Greter, D.E.; and Aposhian, H.V. (1990).** Determination and metabolism of dithiol chelating agents: X. In human, meso-2,3-dimercatosuccinic acid bound to plasma proteins via mixed disulfide formation. *J. Pharmacol. Exp. Ther.* 254 (2) : 570-577.
29. **Melchiorri, D.; Reiter, R.J.; Sewerynek, E.; Chen, L.D.; and Nistico, G. (1995).** Melatonin reduces kainate-induced lipid peroxidation in homogenates of different

- brain regions. *FASEB J.* 9 : 1205-1210.
30. **Miccadie, S., and Floridi, A. (1993).** Sites of inhibition of mitochondrial electron transport by cadmium. *Chem. Biol. Interact.* 89, 159-167.
 31. **Murray, R.K.; Garnner, D.K.; Mayes, P.A.; and Rodwell, V.W. (1993).** *Harper's Biochemistry.* 23 ed. Middle East Appleton and Lang, California, pp. 320-350.
 32. **Nomiyama, K.; and Nomiyama, H (1986).** Critical concentration of unbound cadmium in the rabbit renal cortex. *Experientia* 42 : 149-150.
 33. **Orsea, S.C.; Tomasi, V.H. ; Schwint, A.E. ; and Itoiz, M.E. (2001).** Modified silver staining of nucleolar organizer regions to improve the accuracy of image analysis. *Biotech. Histochem.* Mar. 16(2): 67-73.
 34. **Parasad, A.S.; and Beck, W.J.B. (1996).** Metal-metal interactions. In *Toxicology of metals* (Chang, L.W.; Magos, L.; Suzuki, T. Eds.). CRC Press, Inc. Boca, Raton, Florida, pp. 189-197.
 35. **Pears, E.A.(1980).** *Histochemistry-theoretical and applied,* 4 ed., Churchill, Livingston, London, pp. 20.
 36. **Piere, C.; Mara, M.; Morani, F.; Rechionni, R.; and Marcheselli, F. (1994).** Melatonin : A peroxy radical scavenger more effective than vitamin E. *Life Sci.* 55 : 171-176.
 37. **Pisator, M. (1986).** The nephropathy of chronic cadmium poisoning. In *Handbook of Experimental Pharmacology : Cadmium* (Foulkes, E.C., Ed), Vol. 80, pp. 180-194. Springer Verlag Press, New York.
 38. **Ploton, D.; Menager, M.; Jeannesson, P.; Humber, G.; Pigeon, F.; and Adnet, J.J. (1986).** Improvement in the staining and in the visualization of the argyrophilic proteins of the nucleolar organizer region of the optical level. *Histochem. J.* 18-5-14.
 39. **Poirer, L.A. (1996).** An introduction to selected concepts in metal carcinogenesis. In *Toxicology of metals* (Chang, L.W.; Magos, L.; Suzuki, T. Eds.). CRC Press, Inc. Boca Raton, Florida, PP 287-298.
 40. **Reiter, R.J.; Tan, D.X.; Poeggeler, B.; Mennendez-pelaez, A.; and Chen, L.D. (1994).** Melatonin as a free radical scavenger : Implication for aging and age-related diseases. *Ann. NY Acad. Sci.* 719 : 1-12.
 41. **Reynolds, J.E.F. (1991).** *Martindale : The extrapharmacopoeia,* 29th ed. The pharmaceutical Press, London, UK.
 42. **Sai, K.K.; Umemura, T.; Takaji, A.; Hasegama, R.; Tanimura, A.; and Kurokawa, Y. (1995).** Pentachlorophenol-induced oxidative DNA damage in mouse liver and protective effect of antioxidants. *Food Chem. Toxicol.* 33 : 877-882.
 43. **Shaikh, Z.A.; and Smith, J.C. (1997).** The mechanism of hepatic and renal metallothionein biosynthesis in cadmium-exposed rats. *Chem. Biol. Interact.* 19 : 161-171.
 44. **Shaikh, Z.A.; Vu, T.T.; and Zaman, K. (1999).** Oxidative stress as mechanism of chronic cadmium induced hepatotoxicity and renal toxicity and protection by antioxidants. *Toxicol. App. Pharm.* 154 : 256-263.
 45. **Sherlock, J.C. (1984).** Cadmium in foods and the diet. *Experientia* 40 : 152-156.
 46. **Squibb, K.S.; and Fowler, B.A. (1984).** Intracellular metabolism and effects of circulating cadmium metallothionein in the kidney. *Environ. Health Perspec.* 54 : 31-35.

47. **Squibb, K.S.; Ridlington, J.W.; Carmichael, N.G.; and Fowler, B.A. (1979).** Early cellular effects of circulating cadmium-thionein in kidney proximal tubules. *Environ. Health Perspect.* 28 : 287-296.
48. **Tan, D.X.; Chen, L.D.; Poggeler, B.; Monchester, L.C.; and Reiter, R.J. (1993).** Melatonin : a potent endogenous hydroxyl radical scavenger. *Endocrin. J.* 1 : 57-60.
49. **Tan, D.X.; Reiter, R.J.; Chen, L.D.; Poeggeler, L.C.; and Barlow-walden, L.R. (1994).** Both physiological and pharmacological levels of melatonin reduce DNA adduct formation induced by carcinogen safrole. *Carcinogenesis* 15 : 215-218.
50. **Tang, W.; Sadovic, S.; and Shaikh, Z.A. (1998).** Nephrotoxicity of cadmium-metallothionein: rotection of zinc and role of glutathione. *Toxicol. App. Pharmacol. Agu.* 151(2): 276-82.
51. **Tiran, B.; Karpf, E.; and Tiran, A. (1995).** Age dependency of selenium and cadmium content in human liver, kidney and thyroid. *Arch. Environ. Health.* 50(3):242-246.
52. **Trere, D. (2000).** Ag NOR staining and quantification. *Micron, Apr.* 31(2):127-31.
53. **Waalkes, M.P.; and Rehm, S. (1994).** Cadmium and prostate cancer. *J. Toxicol. Environ. Health.* 43, 251-269.
54. **Waalkes, M.P.; Rehm, S.; and Devor, D.E. (1997).** The effect of continuous testosterone exposure on spontaneous and cadmium-induced tumours in the male fisher (F344/NCr) rat : Loss of testicular response. *Toxicol. APP. Pharm.* 142:40-46.
55. **Waalkes, M.P; and Misra, R.R. (1996).** Cadmium carcinogenicity and genotoxicity. In *metal toxicology*, PP.229-241.CRC press, Boca Raton.
56. **Webb, M. (1986).** Role of metallothionein in cadmium metabolism. In *handbook of experimental pharmacology*. Vol. 80 : cadmium (E.C. Foulkes, Ed.) pp. 281-337, Springer-Verlag. New York.
57. **Webb, M.; and Cain, K. (1982).** Functions of metallothionein. *Biochem. Pharmacol.* 31 : 137-142.
58. **Yamano, T.; Shimizu, M.; Noda, T. (1998).** Comparative effects of repeated administration of cadmium on kidney, spleen, thymus, and bone marrow in 2-,4- and 8-month-old male wister rats. *Toxicol. Sci.* 46(2) : 393-402.
59. **Yoshido, S. (1999).** Application of methionin0free nutrition as an anticancer treatment. *Nutrition* 15 (5) : 422-424.
60. **Zhou, T.; Zhou, G.; Song, W.; Eguchi, N.; etal. (1999).** Cadmium-induced apoptosis and changes in expression of P53, C-jun and MT-1 genes in testes and ventral prostate of rats. *Toxicology*, 142(1) : 1-13.

الدور الوقائي للميلاتونين و الميثيونين و الزنك على التأثير السمي للكادميوم فى

الكلية : هستوباثولوجيا وهستوكيميائيا و عدد مناطق المنظم النووى.

سونيا لبيب عبد الفتاح الشرقاوى, حفيظة عبد السميع شرف, نبيلة صلاح
حسن

قسم العلوم الطبية الأساسية- مجال الباثولوجى- المركز القومى للبحوث

إن الكادميوم من المعادن الثقيلة التى لها تأثير سمي و الموجودة فى الطبيعة. قد وجد ان التعرض المستمر للكادميوم يسبب تسمم للكبد و الكلية. إستهدفت هذه الدراسة تقييم الدور الوقائي للميلاتونين و الميثيونين و الزنك على التأثير الهستوباثولوجى و الهستوكيميائى و التكاثرى للكادميوم على كلى الفئران.

إشتمل هذا البحث على ثمانين من أنثى الفئران البيضاء قسمت إلى ثمانى مجموعات. تم حقن الحيوانات تحت الغشاء البريتونى بمادة كلوريد الكادميوم (٢ مجم / كجم وزن جسم) او الميلاتونين (١٠ مجم / كجم وزن جسم) او الميثيونين (٤٢,٨ مجم / كجم وزن جسم) او الزنك (٢٠ مجم / كجم وزن جسم) مع او بدون كادميوم كلوريد يوميا لمدة ١٠ أيام.

أوضحت النتائج أن كلوريد الكادميوم قد أحدث تغيرات باثولوجية للخلايا المبطنة للأنايب الكلوية و مساحات كبيرة من النزيف فى الأنسجة الضامة. كما أحدث تغيرات هستوكيميائية شملت نقص فى الجليكوجين و البروتين. كذلك زاد عدد مناطق المنظم النووى زيادة ذات دلالة إحصائية بالمقارنة بالحيوانات الغير معالجة. كما أثبتت الدراسة أن معاملة الحيوانات بالميلاتونين أو الميثيونين مع كلوريد الكادميوم أدت إلى تحسن كبير من الناحية الباثولوجية و الهستوكيميائية و كذلك نقص ذات دلالة إحصائية فى عدد مناطق المنظم النووى. بينما أدى معاملة الحيوانات بالزنك مع كلوريد الكادميوم إلى تحسن جزئى فى تأثيرات الكادميوم السمية على الكلى.

نستخلص من هذا البحث أن الميلاتونين و الميثيونين أكثر كفاءة من الزنك فى التخلص من سمية الكادميوم على كلى الفئران.