

قسم : التشريح والهستولوجيا •
كلية الطب البيطري - جامعة أسيوط •
رئيس القسم : أ.د. / حلمي بدوي •

دراسات جراحية تشريحية على الاكياس الزلالية للكتف في الحمار

عبدالله حفني ، اسماعيل عبدالعزيز ، علي عبدالقادر ، ط.ب. • محمد طه

أجرى هذا البحث على عدد واحد جنين وآخر مولود حديثا وثلاثة حيوانات صغيرة و ٣٥ حمارا بالغاً ذات أعمار وأجناس مختلفة وقد اعدمت هذه الحيوانات عن طريق قطع الشريان السباتي العام ثم حقنت بمادة الفورمالين (١٠%)، ولدراسة المواصفات التشريحية حقنت الاكياس الزلالية بمادة المطاط وكذلك مادة الباربيوم (٤٠%) واليوروجرافين •

وتم في هذا البحث حصر الاكياس الزلالية لمنطقة الكتف في الحمار وتم دراسة الوصف التشريحي لها وذلك بتحديد موقعها وشكلها وعلاقتها بالتراكيب المجاورة وتقدير حجمها وتحديد أنسب مكان لحقنها جراحيا ومقارنتها ومثيلاتها في الحيوانات المختلفة وقد وجد أن الاكياس الزلالية للكتف في الحمار هي:

الكيس الزلالي تحت جلدي لشوكة عظمة اللوح ، تحت وتر العضلة الفغرافية العضدية ، تحت وتر العضلة التحت شوكية وتحت اللثوية وتحت وتر العضلة المبرومة الصغرى والكيس الزلالي البين حديبي (تحت وتر العضلة ذات الراسين العضدية) والكيس الزلالي الداني والقاصي تحت وتر العضلة العضدية الدماغية وكيس زلالي العضلة تحت ترقوية •

Dept. of Anatomy & Histology,
Faculty of Vet. Med., Assiut University,
Head of Dept. Prof. Dr. H. Badawi.

**SURGICAL ANATOMICAL STUDIES ON THE SYNOVIAL BURSAE
OF THE SHOULDER IN DONKEY
(*Equus asinus*)
(With 4 Figures)**

By
A. HIFNY; I.A. IBRAHIM; A.A. MANSOUR and M. TAHA
(Received at 25/7/1987)

SUMMARY

This work was carried out on one fetus, one newborn, 3 young and 35 adult donkeys of different sexes and ages. The morphology of the bursae was studied as regard to the shape, position, relation as well as the frequency of its occurrence and the suitable site of injection. The bursae of the shoulder include; the subcutaneous bursa of the spine of the scapula, B. subtendinea M. coracobrachialis, B. subtendinea M. infraspinati, B. subtendinea M. subscapularis, B. subtendinea M. teretis minoris, B. intertubercularis, the proximal subtendinous bursa of the brachiocephalic muscle, the distal subtendinous bursa of the brachiocephalic muscle and the bursa of the M. subclavius. From the clinical point of view there is no communication between these bursae and the adjacent joint capsule of the shoulder joint.

INTRODUCTION

The study of the synovial bursae forms an important link between the anatomy and surgery. However, available literatures lack many informations about the surgical anatomical characters of the bursae in donkey. MULLER (1936), OTTAWAY/WORDEN (1940), BERG (1973), and SEIFERLE/FREWEIN (1986) in horse, M'cLEOD (1958), GIGOV (1964) and RAGHAVAN/KACHROO (1964) in cattle, stated only the frequency of the occurrence of these bursae in the studied animal. Therefore the present study discuss the clinical importance of these bursae, site of their location and methods of injection and their communication or loculation with the joint capsule.

MATERIAL and METHODS

This work was carried out on one fullterm fetus with C.V.R.L. 78 cm, one newly born, 3 young and 35 donkeys of different ages and sexes. These materials were subjected to different methods of techniques for studying the bursae, by injection of Gum milk (latex) and Radioopaque materials after bleeding the animal through the common carotid artery, then injected with 10% formalin. The morphology of the bursae was studied as regard to the shape, position, relation as well as the frequency of its occurrence and the suitable site of injection. The nomenclature used in this work is that adopted by N.A.V. (1983) whenever if it was possible.

RESULTS**Subcutaneous bursa of the spine of the scapula :**

This bursa was observed only in 4 of the examined cases. It is subfascially situated above the proximal end of the spine of the scapula just proximal to the tuber spinae. Its long axis is parallel to the long axis of the spine of the scapula. Its cavity is intersected by connective tissue fibers which give it a multilocular appearance. When the bursa is injected with latex and hardened in situ, the latex cast appears oval in outline, wide proximally and narrow distally. It measures about 3.1 cm proximodistally and 2 cm transversely.

B. subtendinea M. coracobrachialis :

This bursa was observed in all of the examined specimens. It is relatively large and lies 1.3 cm distal to the coracoid process on the medial aspect of the shoulder joint between the tendon of origin of the M. coracobrachialis, as well as its adjacent fleshy part medially and the tendon of insertion of the M. subscapularis laterally (1/1,2). The wall of this bursa is firmly attached to the tendon of origin of the M. coracobrachialis and easily detached from the tendon of insertion of the M. subscapularis. When the bursa is injected with latex and hardened in situ, its latex cast appears quadrilateral in outline, measures about 3.7 cm proximodistally and 1.7 cm craniocaudally in adult donkeys while in newly born donkey it measures about 3 X 1.5 cm.

B. subtendinea M. infraspinati :

This bursa was observed in all of the examined specimens. It is situated between the long tendon of insertion of the M. infraspinatus and the lateral surface of the caudal part of the greater tubercle of humerus as well as the adjacent area on its lateral surface.

When the bursa is injected with latex and hardened in situ, the cast appears quadrilateral in outline with its long axis directed obliquely, distally and cranially (1/3, 2/4 A,B,C). It measures about 2.8 cm length and 1.9 cm width. It was observed that there is no connection between the bursa and the articular capsule of the shoulder joint.

This bursa projects cranially beyond the long tendon of insertion of the M. infraspinatus and projects caudally to come in contact with the M. teres minor. The cranially projected part is considered the suitable site for injection of this bursa.

B. subtendinea M. subscapularis :

In the present work this bursa is observed in 14 cases. It is small and irregularly semicircular in outline. It lies between the tendon of insertion of M. subscapularis without reaching its cranial or caudal borders and the medial wall of the joint capsule of the shoulder joint on the lesser tubercle of the humerus. Its wall is intimately attached to the tendon of insertion of M. subscapularis medially and the articular capsule of the shoulder joint laterally.

B. subtendinea M. teretis minoris :

This bursa was not observed in fetus, newly born and young donkeys and recorded in 12 of the adult examined specimens. It is situated between the M. teres minor and the articular capsule of the shoulder joint above the cranio-lateral part of the head of the humerus. The bursa is small and semicircular in outline (about 1 X 1 cm).

THE SYNOVIAL BURSES OF THE SHOULDER

B. intertubercularis :

The intertubercular bursa is the largest one of these of the bursae of the shoulder of donkey and is recorded in all dissected specimens. It is situated between the tendon of origin of the *M. biceps brachii*, as well as its adjacent fleshy part from one side and sulcus intertubercularis, as well as the adjacent part of the cranial surface of the humerus on the other side (2/1,2,3; 1/4). It is separated from the articular capsule of the shoulder joint by a pad of fat.

The permanent occurrence of this bursa may be due to the fibrocartilaginous tendon of origin of the *M. biceps brachii* and its gliding on sulcus intertubercularis at the angle of the shoulder.

The wall of the bursa intertubercularis is firmly attached to the tendon of origin of the *M. biceps brachii* and the sulcus intertubercularis. Its area of attachment to the humerus is smaller than that to the *M. biceps brachii*.

When the bursa intertubercularis is injected with latex and hardened in situ, its cast appears quadrilateral in outline, measures about 5.3 X 5.4 cm proximodistally and medio-laterally in adult donkeys and 4 X 4.1 cm in newly born one.

The shape of the deep surface of the latex cast differs according to the type of movement of the shoulder joint. In normal standing position (4 A/1) the middle third of the deep surface of the cast moulds the intertubercular sulcus while the other two thirds are smooth. In case of flexion (4 B/1) the bursa extends proximal to the limit of the sulcus intertubercularis, therefore the distal third of the surface moulds the intertubercular sulcus while the remaining part of this surface is smooth. On the other hand, in case of extension (4 C/1) the bursa extends distally beyond the sulcus intertubercularis. Therefore, the proximal third of the deep surface moulds the sulcus intertubercularis while the distal two thirds are smooth.

In the present work the suitable site of injection of this bursa is between the borders of the tendon of origin of the *M. biceps brachii* and the cranial parts of the greater or lesser tubercles of the humerus as in these parts the bursa reflects around the tendon of *M. biceps brachii*.

The proximal subtendinous bursa of the brachiocephalic muscle :

This bursa is recorded in both limbs in 6 cases and in one limb in two cases of the examined adult donkeys. It is situated between *M. brachiocephalicus* and the tendon of insertion of *M. infraspinatus* above the caudal part of the greater tubercle of the humerus. The latex cast of this bursa takes a variable shape and size, it varies from semicircular to irregular quadrilateral in outline and its measurements ranges from (2 X 1.5 cm) to (2 X 3 cm). It has a deep surface which is concave and smooth adapted to the bone, and a superficial surface which is convex and related to *M. brachiocephalicus*.

The distal subtendinous bursa of the brachiocephalic muscle :

This bursa is recorded in both limbs in 4 cases and in one limb in 3 cases of the examined adult donkeys. It is situated above the cranial part of the greater tubercle of the humerus. This bursa is semicircular in outline, its wall is attached to the cranial part of the greater tubercle of the humerus and is separated by a tendinous sheet from the laterally evaginated part of the bursa intertubercularis.

The bursa of the M. subclavius :

This bursa was observed only in two of the examined adult donkeys. It is situated between the M. subclavius from one side and the medial insertion of the M. supraspinatus, the medial part of the tendinous sheet covers the medially reflected part of the B. intertubercularis as well as the cranial part of the lesser tubercle of the humerus on the other side. The bursa is relatively large, semicircular in outline, and measures 2.8 cm in diameter. Its wall is loosely attached to the M. subclavius and is firmly attached to the other related structures.

DISCUSSION

The permanent occurrence of this bursa in donkeys is similar to that observed in horses by OTTAWAY/WORDEN (1940) and BERG (1973) and in cattle by McLEOD (1958) and GIGOV (1964). The subcutaneous bursa of the spine of the scapula was not recorded in N.A.V. (1983), however, OTTAWAY/WORDEN (1940), BERG (1973) and SEIFERLE/FREWEIN (1986) in horse, observed a subcutaneous bursa on the tuber spinae but they did not mention its terminology. This bursa can be termed B. subcutanea spinae scapularis.

The situation of the B. subtendinea M. coracobrachialis in donkey is similar to that recorded in horse by OTTAWAY/WORDEN (1940) and SEIFERLE/FREWEIN (1986). In donkey this bursa is located distal to the coracoid process for about 1.3 cm while in horse it extends proximally to gain the coracoid process (EICHBAUM, 1883 and OTTAWAY/WORDEN, 1940). In horse OTTAWAY/WORDEN (1940) stated that a few authors refer to this bursa as a synovial sheath which is antagonistic to that stated by MULLER (1936) in horse and to the obtained result in donkey. The bursa subtendinea M. coracobrachialis is recorded also in cattle by RAGHAVAN/KACHROO (1964).

The situation of B. subtendinea M. infraspinati in donkey is similar to that mentioned by OTTAWAY/WORDEN (1940), SISSON (1975) and SEIFERLE/FREWEIN (1986) in horse, as well as McLEOD (1958), GIGOV (1964) and RAGHAVAN/KACHROO (1964) in cattle. In this work the B. subtendinea M. infraspinatus was observed projecting cranially and caudally beyond its tendon a result which is similar to that mentioned by BERG (1973) in horse, while in contrast to this result SEIFERLE/FREWEIN (1986) recorded that this bursa is protruded from the cranial margin of the M. infraspinatus and considered it a suitable site for injection of this bursa. This site is also the accurate one for injecting this bursa in our work. It was observed that there is no connection between the bursa and the articular capsule of the shoulder joint in donkey a result which is in agreement with that reported by BERG (1973) in horse and GIGOV (1964) in cattle.

From the clinical point of view, the situation of the M. infraspinatus and its underlying bursa on the lateral surface of the shoulder joint gives it some tendency for exposure to trauma. Moreover, sliding or slipping or falling down of the animal may expose the tendon for sprain or strain of the bursae for inflammation. The preceding causes are similar to those stated in case of bursitis of the bursa subtendinea M. infraspinatus in horse by BONE/CATCOTT/GABEL/JOHNSON/RILEY (1963). The signs that reflected on the animal is abduction of the entire limb. These signs are in agreement with that reported by SKERRITT/McLELLAND (1984), the foot is placed outwards to relieve tension on the inflamed tendon.

The B. subtendinea M. teretis minoris was recorded in horse by OTTAWAY/WORDEN (1940) and SISSON (1975). The first author mentioned that this bursa may communicate with the cavity of the shoulder joint while the second author mentioned its possibility to communicate with the bursa subtendinea M. infraspinati, a result which was not observed in the present work.

Bone, J.E., Catcott, A.A., Gabel, L.E., Johnson and W.F., Riley (1963): Equine medicine and surgery. A text and reference work. 1st ed. American Veterinary Publications, Kansas City, Mo., U.S.A.

THE SYNOVIAL BURSES OF THE SHOULDER

VAN KRUIJNINGEN (1963), SKERRITT/McLELLAND (1984) stated that the suitable site of injection of the B. intertubercularis in horse is performed at the level of the proximal end of the deltoid tuberosity and at the sides of the M. biceps brachii the needle has to be directed proximally along the bone. ATTIA/OTHMAN (1986) in donkey mentioned that the bicipital bursa (intertubercular bursa) can be injected 2 cm just below the cranial part of the greater tubercle of the humerus and about 0.5 : 1 cm caudally, the needle was inserted between M. biceps brachii and the lateral border of the humerus. The needle was then directed caudomedially for a depth of about 3 cm.

The permanent occurrence of this bursa in donkey is similar to that observed in horse by OTTAWAY/WORDEN (1940), and in cattle by McLEOD (1958), GIGOV (1964), RAGHAVAN/KACHROO (1964) and BERG (1973) while the latter author added that, in pig the tendon of origin of the M. biceps brachii is invaginated in the capsule of the shoulder joint and so the articular capsule forms a synovial sheath around the tendon (Vagina synovialis intertubercularis) but not an independent bursa intertubercularis a result which is not observed in donkey.

In horse (BERG, 1973) as well as in cattle (GIGOV, 1964) the bursa intertubercularis extends distally on the humerus to a transverse line which connects the base of its greater and lesser tubercles, while in donkey the lateral half of the bursa extends 0.5 cm beyond this level. The attachment of the wall of the bursa intertubercularis to the M. biceps brachii in the present work is similar to that recorded in horse by OTTAWAY/WORDEN (1940), and SIEFERLE/FREWEIN (1968) and in cattle by BERG (1973). In the present work the attachment of the bursa to the deep surface of the biceps brachii muscle include the tendinous origin proximally and the fleshy part distally, however in horse and cattle it is attached only to the deep surface of its tendon (BERG, 1973 and GIGOV, 1964).

From the clinical point of view any severe traumatism to the point of the shoulder or strain of the biceps brachii muscle causes inflammation to the bursa intertubercularis. This inflammation affects on the flexor action of the M. biceps brachii and the M. extensor carpi radialis on the elbow joint, therefore the expected signs of the intertubercular bursitis is shortening of the stride due to restricted use of biceps and the animal can not make any attempt to lift the foot off the ground and usually the toe being dragged along the ground during progression. These expected findings are in accordance with those stated by O'CONNOR (1958), ADAMS (1962), BONE et al. (1963) and SKERRITT/McLELLAND (1984).

The obtained literatures lack any information about the proximal and distal subtendinous bursae of brachiocephalic muscle. The present work can be suggests that, the name of these bursae as, Bb. subtendinae M. brachiocephalicus proximalls et distalis. The obtained literatures as well as N.A.V. (1983) does not give any information about this bursa therefore the suggested name of the present work is B. M. subclavius.

REFERENCES

- Adams, O.R. (1962): Lameness in Horses. Lea and Febiger, Philadelphia.
- Attia, M. and G.M. Othman (1986): Pilot studies on the techniques for arthrocentesis and intraarticular and intrabursal injections in konkeys. Ass. Vet. Med. J. Vol. 17, No. 34.
- Berg, R. (1973): Angewandte und Topographische Anatomie der Haustiere. Veb. Gustav Fischer Verlag Jena.
- Bone, J.F.; E.J. Catcott; A.A. Gabel; L.E. Johnson and W.F. Riley (1963): Equine medicine and surgery. A text and reference work. 1st ed. American Veterinary Publications, I.N.C.

A. HIFNY et al.

- Eichbaum, F. (1883): Zur Anatomie und Histologie der Schleimbeutel und Sehnenscheiden des Pferdes. Archiv F. Wissensch. U. Prakt. Thierheilk. Jg./Bd. 9.
- Gigov, Z. (1964): Über den Bau, die Blutversorgung und die Innervation der Gelenkkapseln der Extremitäten beim Rind. Anat. Anz. Bd. 114.
- M'Cleod, W.M. (1958): Bovine Anatomy. 2nd edition. Burgess publishing company; Manneapolis, Minnesota.
- Muller, F. (1936): Schleimbeutel und sehnenscheiden des pferds. Arch. Miss. Parkt. Tierheilk. No. 70, Cited by OTTAWAY, C.W. and A.N. WORDEN (1940).
- Nickel, R.; A. Schummer; K.H. Wille and H. Wilkens (1986): Passive locomotor system in NICKEL, R.; A. Schummer; E. Seiferle, J. Frewein, H. Wilkens and K.H. Wille (The Locomotr system of the Domestic Mammals). Verlag Paul parey. Berlin. Hamburg.
- Nomina Anatomica Veterinaria (1983): Third edition. Published by the International committee on Veterinary Gross Anatomical Nomenclature under the financial responsibility of the world Association of Veterinary Anatomists. Ithaca, New York.
- O'Connor, J.J. (1958): Dollar's Veterinary Surgery 4th edition. Bailliere. Tindall and Cox. London.
- Ottaway, C.W. and A.N. Worden (1940): Bursae and tendon sheaths of the horse. Vet. record Vol., 52, No. 26.
- Raghavan, D. and Kachroo (1964): Anatomy of the ox. First edition. Indian council of agricultural research, New Delhi.
- Seiferle, E. and J. Frewein (1986): Active locomotor system in Nickel, R.; A. Schummer; E. Seiferle, J. Frewein; H. Wilkens and K.H. Wille, the locomotor system of the Domestic Mammals.
- Sisson, S. (1975): Equine dMyology in SISSON and GROSSMAN'S, The Anatomy of The Domestic fAnimals, 5th ed. W.B. SAUNDERS COMPANY. Philadelphia-London-Toronto.
- Skerritt, G.C. and . McLelland (1984): An Introduction to the functional Anatomy of the limbs of the Domestic Animals. Wright. Bristol.
- Van Kruiningen, H.J. (1963): Practical techniques for making injections into joints and bursae of the horse. J.A.V.M.A. Vol. 143, No. 10.



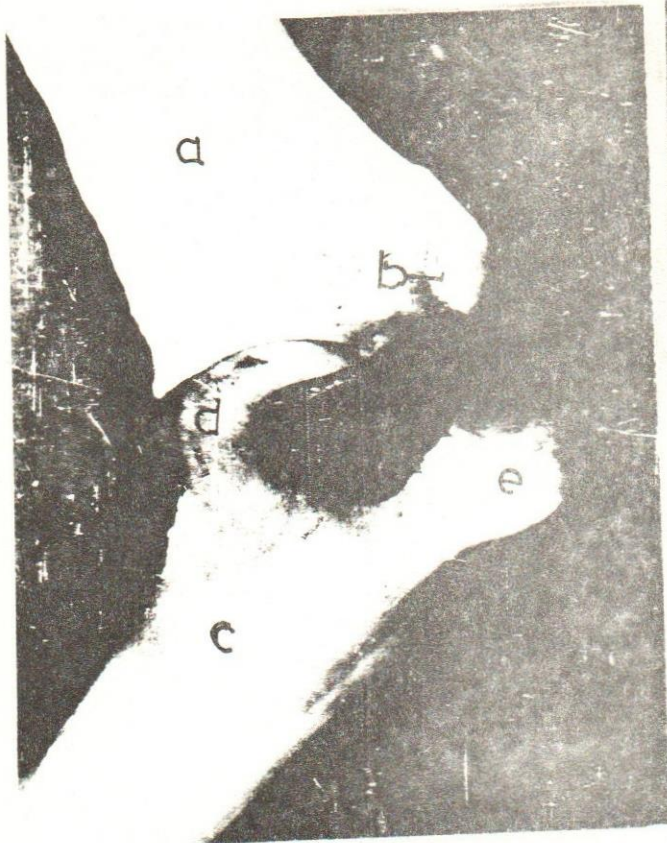


Fig. (1): Latex casts of the bursae of the left shoulder (Medial view).

1- B.subtendinea M.coracobrachialis.

a- Scapula. b- Coracoid process. c- Humerus. d- Head of the humerus.
e- Cranial part of lesser tubercle of the humerus.

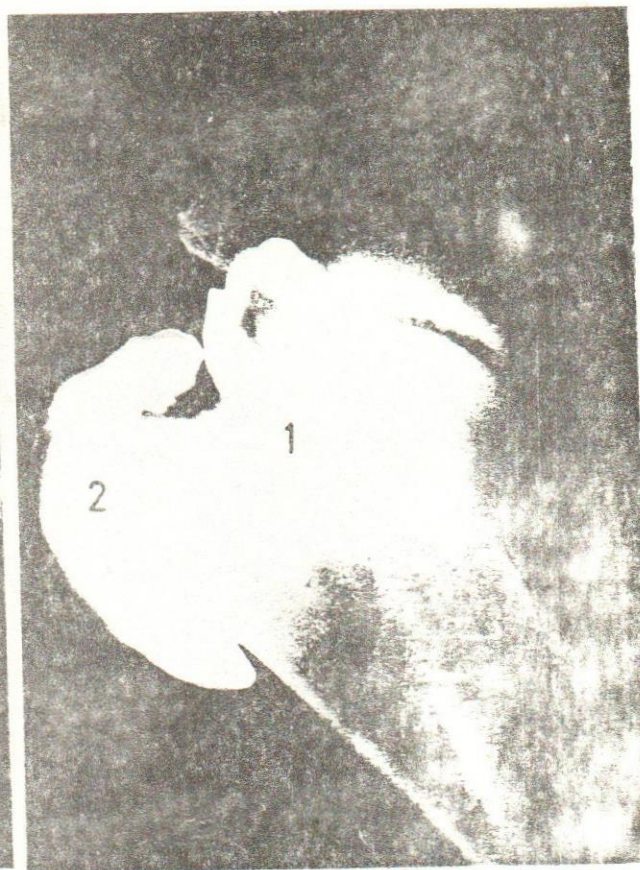

Fig. (2): Mediolateral radiograph showing the bursae of the right shoulder.

2- B.intertubercularis.

Fig. (3): Latex casts of the bursae of the right shoulder (lateral view):

1- B.subtendinea M. infraspinati.

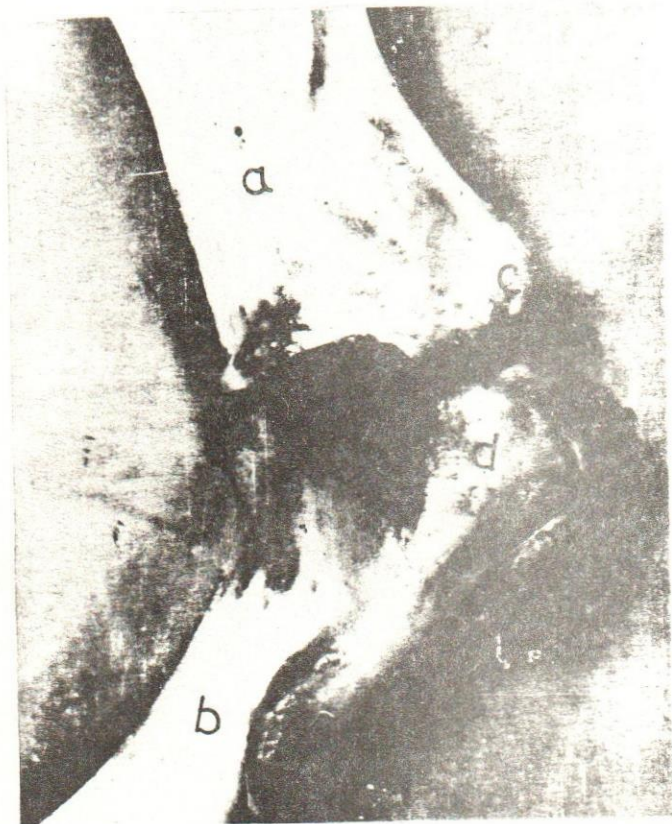
2- B. intrtubercularis.

a. Scapula.

b. Humerus.

c. Supraglenoid tubercle.

d. Cranial part of greater tubercle of the humerus.





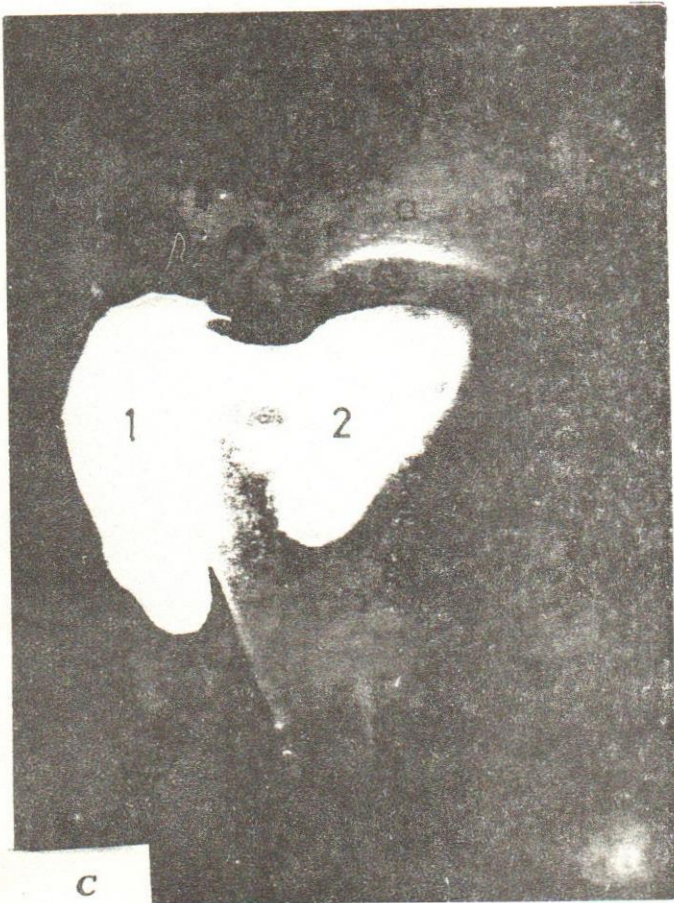
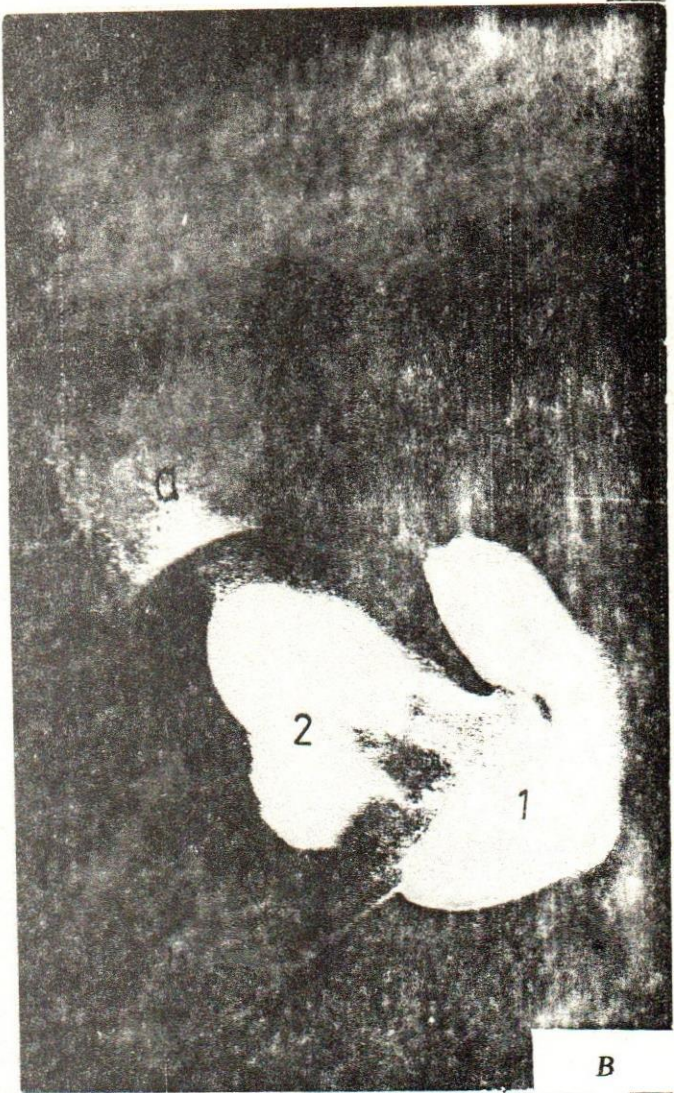


Fig. (4): Radiographs showing the bursae of the right shoulder.

- A- Normal standing position.
- B- The shoulder joint is flexed.
- C- The shoulder joint is extended.
- 1- B.intertubercularis.
- 2- B.subtendineae m. infraspinati.
- a- Scapula.
- b- Humerus.



The following figures show the
 results of the experiment
 in which the effect of
 the temperature on the
 rate of reaction was
 studied. The results are
 shown in the following
 table.

