

Estrogenic Effect of Orthopedic DDT on the Female Genital Organs of Mice

Raifa F. El Garieb

National Centre for Radiation Research and Technology

Abstract :

Insecticide DDT (an organochlorine compound) has been used excessively and widely all over the world. It was shown that orthopedic DDT (o-p'-DDT) a major constituent of technical grade preparation of the pesticide- DDT exhibited estrogenic activity in several animals species (Welch et al., 1969 and Bitman et al., 1968).

The aim of this work is to study the estrogenic effects of o-p'-DDT on the female reproductive organs (ovary, uterus and vagina) of mice in its neonatal period.

In this study fifty of newly-born female mice were used and divided into five groups; three groups of them were received ten intraperitoneal injections of o-p'- DDT in doses of 0.25, 0.5 and 1mg/injection. The study included two control groups, the first one was injected with 10 ugm estrogen for 10 injections and considered as positive control, while the second group injected with sesame oil only. The animals were scarified 2 days after the last injection. Paraffin and frozen sections were prepared for both histological and histochemical studies. Different staining techniques were used including Hx., E., modified gomori stain for alkaline phosphatase enzyme, methyl green pyronin for RNA and PAS stain for glycogen content.

The results showed a distinct increase in number and size of ovarian growing follicles in those animals treated with o-p'-DDT, also, increased activity of the alkaline phosphatase enzyme, as well as increased content of RNA and glycogen was noticed. The effect of o-p'-DDT on the uterine structure were in the form of hypertrophy of the endometrial epithelium, also increase in number of uterine glands. Marked increase in the activity of alkaline phosphatase enzyme and also in RNA content as well as glycogen deposition.

It was noticed also that high dose of o-p'-DDT leads to accelerated development of the vaginal epithelium with evidence of keratinization. The histochemical changes in the vagina were similar to those obtained in the uterus.

It can be finally concluded that the obtained results after use of o-p'-DDT were similar to those obtained by estrogen, and this may interfere with implantation of ova and pregnancy.

Introduction :

The toxicity of various pesticides is of general importance because of their wide use in agriculture. While these pesticides destroy insects, they may have a direct action on the reproduction of birds and mammals confined to the treated fields. Diminished reproduction of various species following consumption of diets containing residues of DDT (organochlorine compound) have been suggested by several reports (Bitman et al., 1968; Welch et al., 1969; and Kupfer & Bulger, 1976).

It has found that DDT and its closely related compounds exhibited estrogenic effects (Heinrichs et al., 1971). Technical commercial preparation of DDT contained o-p'-DDT and p,p'-DDT isomers, constituting about 20% to 80% of the pesticide preparation, respectively. Reports indicate that o-p'-DDT and p-p'-DDT mimic various hormonal actions of oestrogen in various species of birds and mammals (*Bitman et al, 1968*).

In birds and mammals estrogen plays a critical role in female reproduction. In mammals, structural changes in vagina, uterus and duct are affected by estrogens and proper ovarian structure and ovarian structure and function becomes critical for reproduction (*Turner and Bagnara, 1976*).

Treatment of immature chickens, rat and Japanese quail with o-p'-DDT produced an increase in weight, water content, glycogen and RNA in uteri and oviducts (*Levin et al, 1968; Conney and Btirns, 1972*).

The o-p'-DDT isomer also advanced puberty, induced persistent estrus and caused ovaries to develop follicular cysts and reduced the number

of corpora lutea in rats (*Heinrichs et al, 1971; Wren et al, 1971*).

Injection of o-p'-DDT into neonatal rats produced vascularization and hypertrophy of the cells in the endometrium, metaplastic changes which interfere with implantation of the fertilized ova, these findings and the decrease of gonadotropins suggest that neonatal exposure to estrogenic pesticides such as o-p'-DDT may permanently affect the sensitivity of hypothalamic-hypophysial axis and the uterus to endogenous estrogen (*Gellert et al, 1972; 1974*).

Estrogen plays an important role in increasing the activity of alkaline phosphatase activity in female genital organs (*Filipe and Dowson, 1968*) also it was found that estrogen produced an increase in the endometrial mucopolysaccharide concentration (*Huber, 1965*).

The functional relationship between DNA and RNA mediated protein synthesis was under the control of estrogen (*Edwards 1967*).

Laguens (1964) suggested that estrogen act upon the nuclear synthesis and secondary release of nuclear RNA into the cytoplasm.

It was reported that human breast milk is contaminated with DDT and its analogs (*Wilson et al, 1973*).

Another report indicates that o-p'-DDT and p,p'-DDT are not only found in mother milk but also in baby's formula milk and consequently the babies are exposed to the same toxic hazards as breast fed babies (*Cockson and Morgan, 1976*).

The passage of estrogenic pesticides through mother's milk to the developing offspring will have a critical influence on the development of female as well as male reproductive organs.

Current studies indicate that there is a critical period in the development during which the undifferentiated hypothalamus is sensitive to gonadal hormones in circulation. In species such as rat or mouse, the sensitivity period is up to 8 days afterbirth (Turner and Bagnara, 1976). It was felt advisable that the study of the mechanism of action of DDT and its effects on the reproductive systems of different species of animals in neonatal period is highly indicated.

This study was planned to evaluate the morphological and histological changes after the use of o-p'-DDT on the female reproductive organs namely (ovary, uterus and vagina) early in the post-natal life which represent the critical period in the development of such organs.

Material and Methods:

In this study fifty Swiss-Webster female mice were used and divided into 5 groups; three groups were injected intraperitoneally with o-p'-DDT in a doses of 0.25 mg, 0.5 mg and 1 mg /injection dissolved in 0.1 ml sesame oil for ten days, the fourth group received 10 injections of 10 ug/injection of estradiol, while the last group received sesame oil only and considered as control. The injection started on the first day after birth. The animals were terminated 2 days after the last injection.

The entire reproductive organs from each female mice were removed, paraffin and frozen sections were prepared and cut for both morphological and histochemical studies.

Different staining techniques were used; hematoxylin and eosin (Culling, 1974) for the morphological changes, modified Gomori stain for localization of the alkaline phosphatase enzyme activity (Pearse 1968). Methyl

green pyronin stain for staining the RNA (Drury and Walington, 1980) and finally PAS stain for study the glycogen content (Drury and Walington, 1980).

Results :

(I) The morphological results :

a- Ovary :

It was noticed that ovaries from a 12-day-old mouse which injected with sesame oil only showed a large number of primary oocytes and few number of small growing follicles. After injection with o-p'-DDT in doses of 0.25 mg and 0.5 mg/injection for ten injections the ovaries were characterized by mild increase in the number of growing follicles. However, a distinct increase in both the number and the size of growing follicles was evident in ovaries after the injection with 1mg/injection of o-p'-DDT for ten days specially when compared with those of the control ovaries (Fig. 1,2).

b- Uterus :

In this study, it was noticed that the endometrial changes was variable. After injection with o-p'-DDT in doses of 0.25 mg or 0.5 mg/injection endometrial epithelial hypertrophy was noticed together with increase number of glands. After the injection of 1 mg/injection of o-p'-DDT for ten days the endometrial epithelium was of tall columnar type with numerous glands (Fig. 3,4).

c- Vagina :

In this study, the vaginal epithelium of a 12-day-old mouse injected with sesame oil only was formed of two or three cuboidal cells resting on loose stromal C.T. After the injection of o-p'-DDT in doses of 0.25 mg and 0.5 mg/injection for 10 days, thickening of vaginal epithelium was a prominent feature, while daily injection of 1 mg o-p'-DDT for ten days induced a more

rapid development of vaginal epithelium which exhibited a distinct basal cell layer, stratum spinosum and stratum granulosum with dark-staining keratohyaline granules and extensive keratinization. The vaginal canal contains desquamated keratinized cells with leucocytes (Fig. 5,6).

(II) The histochemical results :

a- Changes in the alkaline phosphatase enzyme :

It was noticed that the injection of o-p'-DDT in its different doses greatly affect the activity of alkaline phosphatase enzyme also, such enzymatic changes were dose related.

A definite increase in alkaline phosphatase activity was noticed in the ovarian follicles, epithelial lining of both uterus and vagina together with the endometrial glands (Fig. 7-12).

b- Changes in the ribonucleic acid (RNA) content :

It was noticed that the injection of o-p'-DDT does not affect the DNA content in the different organ studied. While the RNA content was greatly affected after the injection of different doses of such insecticide. The amount of RNA was noticed to be increased in the ovarian follicles, lining epithelium of both uterus and vagina together with cells of the endometrial glands. Such changes were dose related to the injected insecticide (Fig. 13-18).

c- Changes in the glycogen content :

Increase in the glycogen contents in the ovarian follicles, epithelial lining of both uterus and vagina, as well as uterine glands was observed in animals injected with different doses of o-p'-DDT specially when compared with those of the control group (Fig. 19-25).

It was noticed that morphological and histochemical change observed in reproductive organs of the female mice

after receiving estrogen daily for ten days were similar to that showed in animals injected with high dose of o-p'-DDT.

Legend of Figures

◀ Collective

photomicrograph (A) (1-6) :

Fig. (1):Control mice ovary showing few number of growing follicles (Hx. E.X 100).

Fig. (2):Mice ovary, treated with 1 mg/injection of o-p'-DDT showing increased number and size of growing follicles (Hx.E.X. 100).

Fig. (3):Control mice uterus showing lining epithelium and few number of uterine glands (Hx.E.X 100).

Fig. (4):Mice uterus, treated with 1 mg/injection of o-p'-DDT showing tall columnar epithelium and increased number of uterine glands (Hx.E.X 100).

Fig. (5):Control mice vagina showing lining epithelium of 3 cuboidal cells (Hx.E.X 250)

Fig. (6):Mice vagina treated with 1 mg/injection of o-p'-DDT showing increased epithelial stratification with keratinization (Hx.E.X 100).

◀ Collective

photomicrograph (B) (7-12)

Fig. (7):Control mice ovary showing distribution of alkaline phosphatase activity (Modified Gomori, X 100)

Fig. (8):Mice ovary, treated with 1 mg/injection of o-p'-DDT showing increased alkaline phosphatase activity in growing follicles (Modified Gomori, X 100).

Fig. (9):Control mice uterus showing the distribution of alkaline pho

-sphatase activity (Modified Gomori, X100).

Fig. (10):Mice uterus, treated with 1 mg/injection of o-p'-DDT showing increased alkaline phosphatase activity in surface epithelium and uterine glands (Modified Gomori, X 100)

.Fig. (11):Control mice vagina showing the distribution of alkaline phosphatase activity (Modified Gomori, X250).

Fig. (12):Mice vagina treated with 1 mg/injection of o-p'-DDT showing increased alkaline phosphatase activity in surface epithelium (Modified Gomori X 250).-

◀ **Collective photomicrograph (C) (13-18) :**

Fig. (13):Control mice ovary showing the distribution of RNA (Methyl green pyronin stain X 100)

Fig. (14)Mice ovary njected with 1 mg/injection of o-p'-DDT showing an increase in the amount of RNA at the growing follicles (Methyl green pyronin stain X 100).

Fig. (15) Control mice uterus showing the distribution of RNA (Methyl green pyronin X 100).

Fig. (16) Mice uterus injected with 1 mg/injection of o-p'-DDT showing an increase in the amount of RNA at the surface

epithelium (Methyl green pyronin stain X 100).

Fig. (17) Control mice vagina showing the distribution of RNA (Methyl green pyronin stain X 250).

Fig. (18) Mice vagina injected with 1 mg/injection of o-p'-DDT showing an increase in the amount of RNA at the surface epithelium (Methyl green pyronin stain X 100).

◀ **Collective photomicrograph (D) (19-24):**

Fig. (19)Control mice ovary showing the distribution of glycogen (P.A.S. stain X 100).

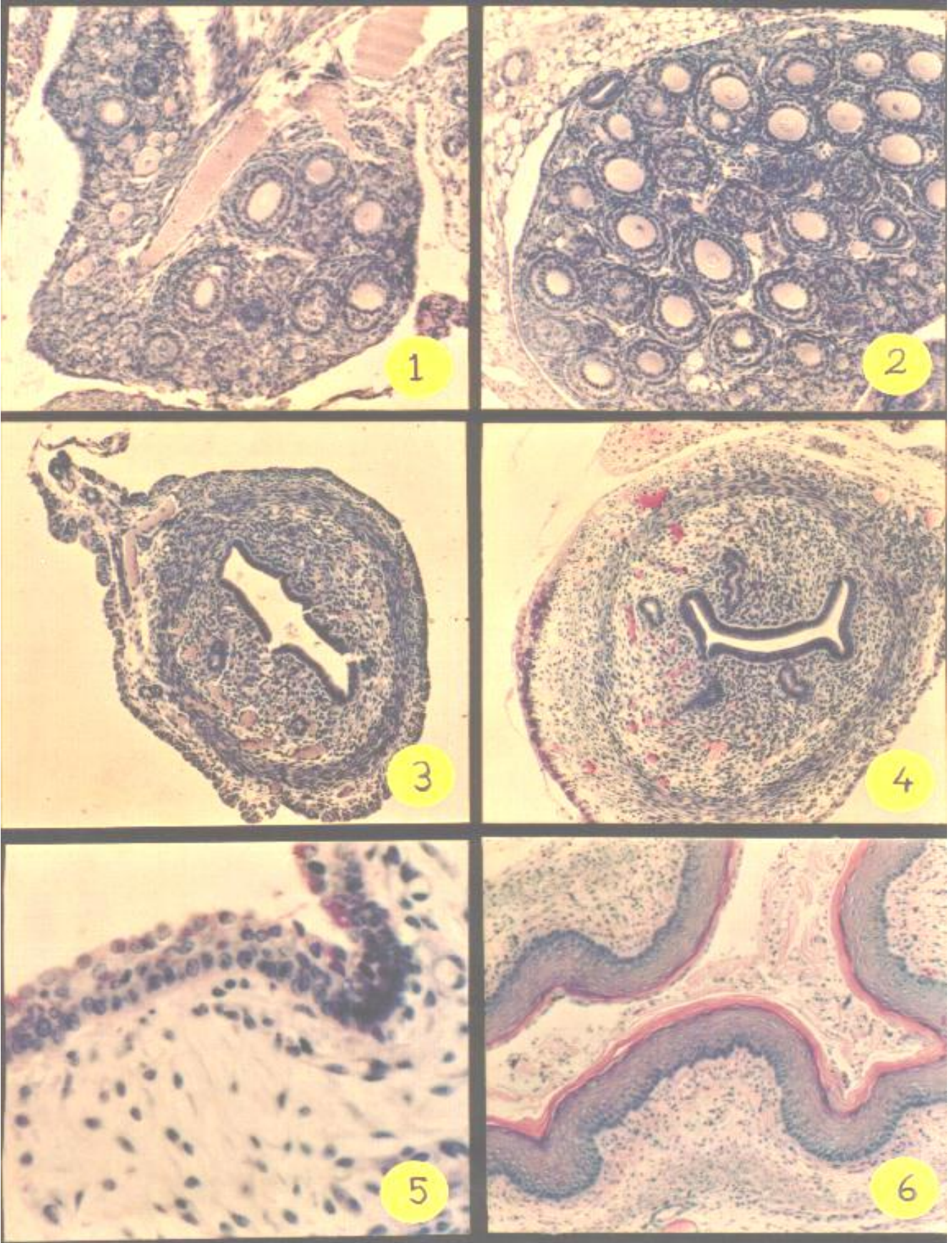
Fig. (20)Mice ovary treated with 1 mg/injection of o-p'-DDT showing increase glycogen content in the growing follicles (P.A.S. stain X 100).

Fig. (21)Control mice uterus showing the distribution of glycogen (P.A.S. stain X 100).

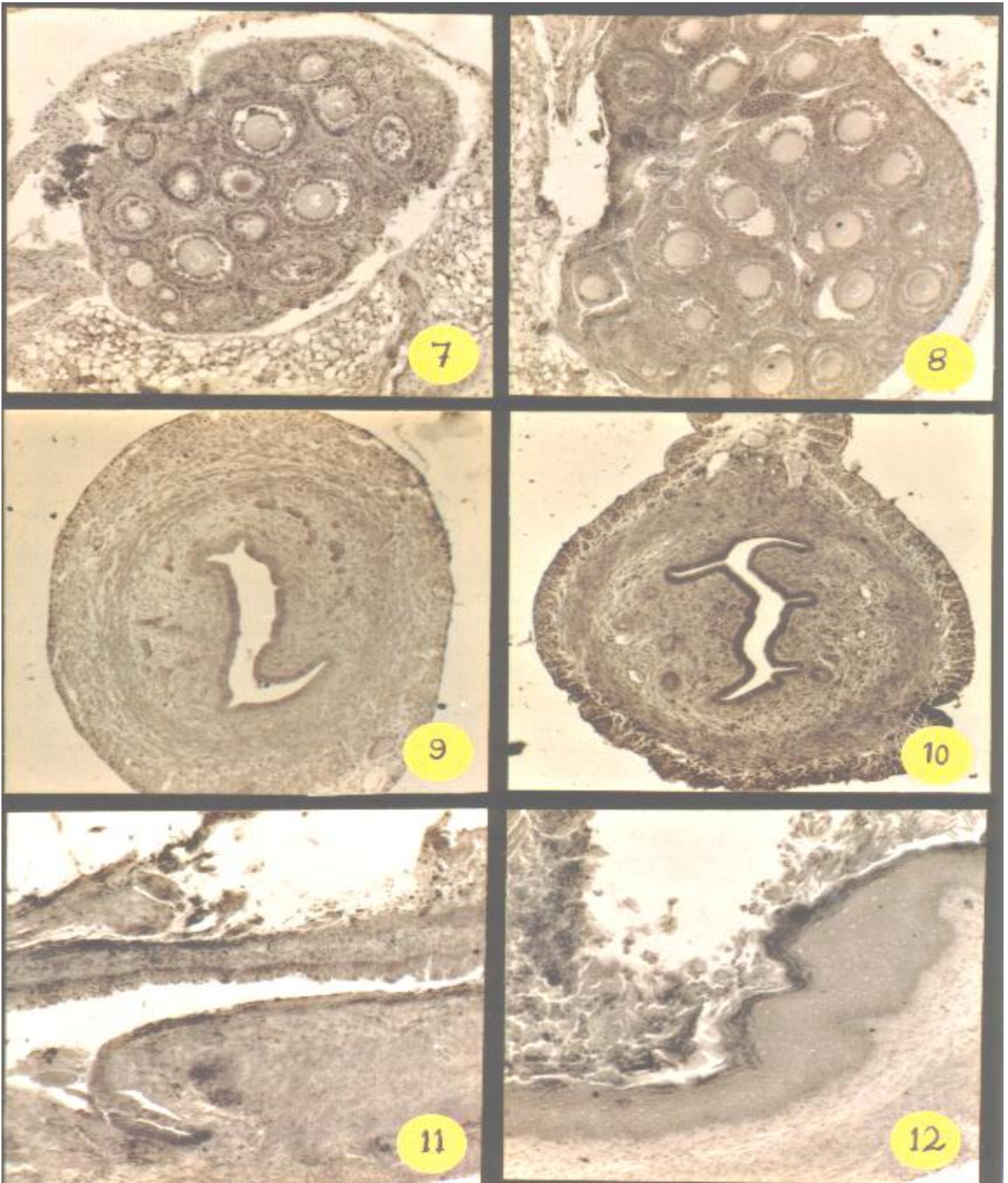
Fig. (22)Mice uterus treated with 1 mg/injection of o-p'-DDT showing increase glycogen content at the lining epithelium (P.A.S. stain X 100).

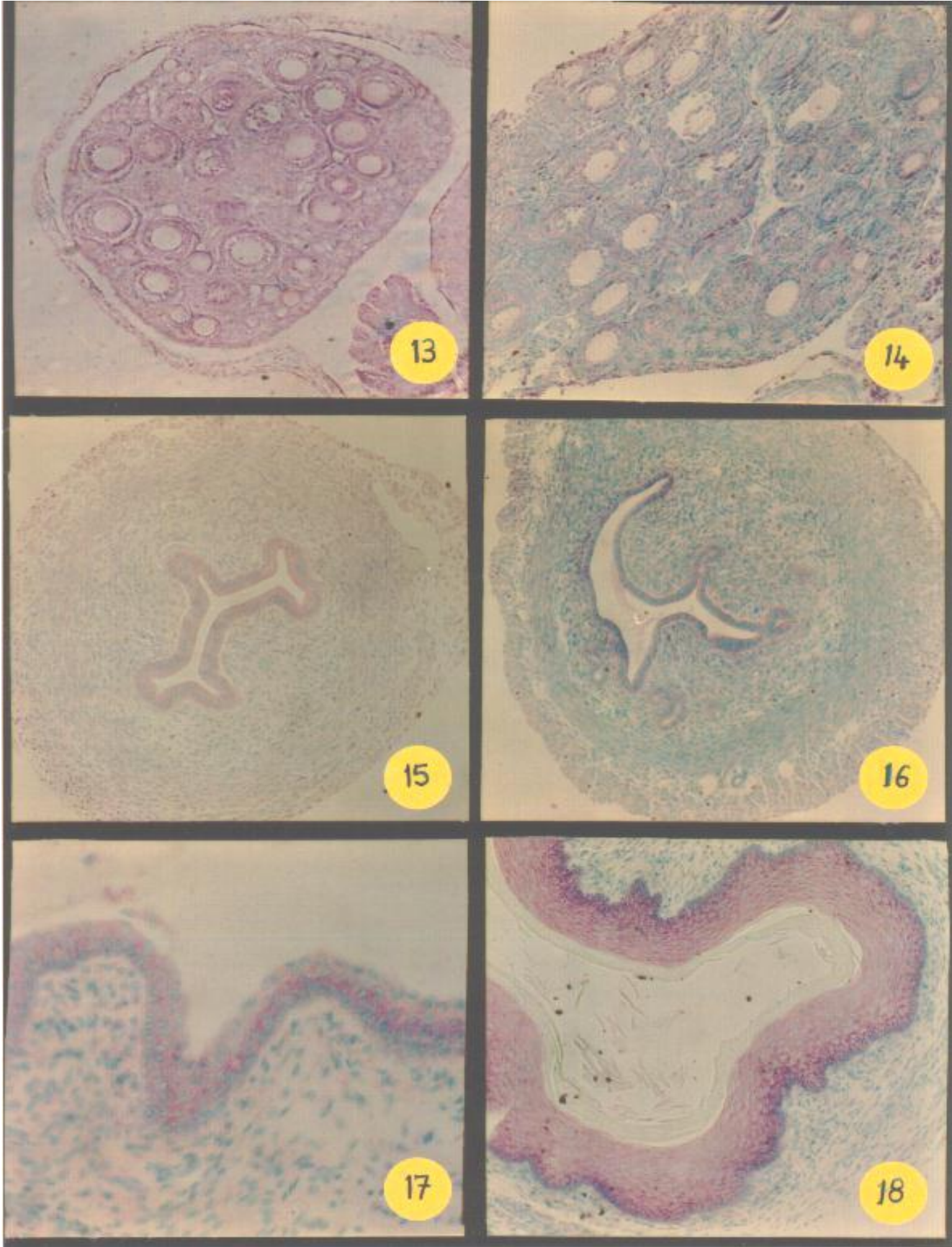
Fig. (23)Control mice vagina showing the distribution of glycogen (P.A.S. stain X 250).

Fig. (24)Mice vagina treated with 1 mg/injection of o-p'-DDT showing increase glycogen in the lining epithelium (P.A.S. stain X 400).

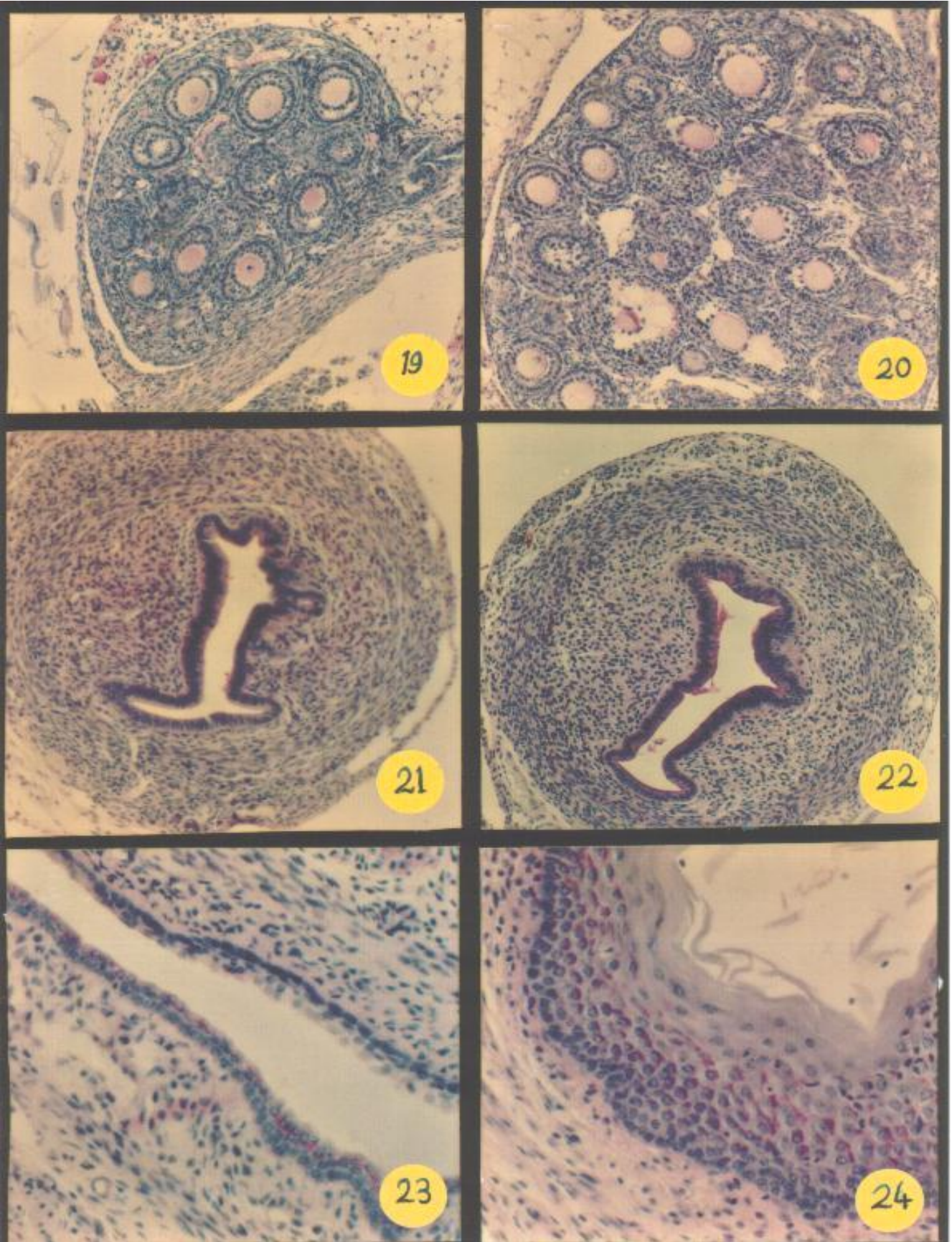


Estrogenic Effect of Orthopedic





Estrogenic Effect of Orthopedic



Discussion

In the environment, DDT accumulates gradually and persists for long times in the bodies of exposed species. Thus, the presence of small amounts of DDT in environment may not cause an immediate harm to animal life, but may instead induce an estrogenic hazard in which reproduction of animals is threatened. The undeveloped reproductive organs of mice serve as convenient target for studying the estrogenic activity of DDT. The epithelium lining of either the vagina or the uterus of the 12-day-old mouse similar to that of an ovariectomized adult female (*Iguchi et al.*, 1976, *Mori*, 1977) and was thin and undeveloped.

Previous studies indicated that there was a critical period in the development during which the undifferentiated hypothalamus is sensitive to the circulating gonadal hormones. In the mouse, this period was not ended until about 8 days after birth (*Turner and Bagnara*, 1976).

In this work, the results showed that, the neonatal administration of the different doses of o-p'-DDT leads to an increase in the number of the ovarian growing follicles as well as accelerated developmental changes in both the uterus and the vagina in a dose-dependent manner, with the higher doses producing maturation in the shorter time. These estrogenic effects of o-p'-DDT were in agreement with those reported by many investigators in different species (Welch et al., 1969; Heinrichs et al., 1971, Nigam et al., 1977 and Aldridge 1990).

Eroschenko and Mousa, (1979) stated that "kepone" as one of the estrogenic pesticides-induced changes in the reproductive tract of the female mouse; identical to those observed by the estrogen.

Huber, (1965) stated that kepone altered the ovarian structure and disturbed the female hormonal balance in the adult mice. The histochemical results obtained in this study showed an increase in the activity of the alkaline phosphatase enzyme, as well as in the content of RNA and glycogen in the different organs studied of female mice injected with o-p'-DDT. These results were coincided with those results obtained by Mousa et al., (1984), after using the kepone in the neonatal mouse.

Conney and Burns (1972), described an increased weight, water content, glycogen and RNA in uteri and oviducts of rats and chickens when injected with estrogen. Donald et al., (1965) reported that estrogen injection stimulated the production of both ribonucleo-proteins and alkaline phosphatase enzyme. Many reports stated that estrogenic pesticides administration increased the RNA content in the uteri and oviducts of rats, chicken and quail (Bitman et al., 1968, Levin et al., 1968 and Beeman 1982).

Cooke (1970) described an increase in the glycogen content of the oviduct of immature chicks and Japanese quail after administration of o-p'-DDT.

The mechanism of action of o-p'-DDT on the mammalian reproductive system is presently not understood. However, since o-p'-DDT induced an estrogenic response, it may act by interaction with estrogen receptors in the cells of the mouse reproductive tract as it has been demonstrated in quail (Turnes and Eliel 1978). Jefferies, (1967) postulated that DDT may affect the function of the pituitary gland or the hypothalamus.

It can be postulated from the for mentioned results that o-p'-DDT has a

definite estrogenic effect which leads to abnormalities in the ovaries and cells of both uterus and vagina of mouse and may interfere with ova or sperm transport as well as the process of implantation and pregnancy.

References :

- 1- Aldridge W.N. (1990) : An assessment of the toxicological properties of pyrethroids and their neurotoxicity. *CRC Crit. Rev. Toxicol.* 21, 80-104.
- 2- Beeman R.W. (1982) : Recent advances in mode of action of insecticide. *Ann. Rev. Ent.* 27:253-281.
- 3- Bitman J., Cecil H.C., Harris S.J. and Fries G.F. (1968) : Estrogenic activity of o-p'-DDT in mammalian uterus and avian oviduct. *Science*, 162:371-372.
- 4- Cockson A. and Morgan A. (1976) : DDT in babies' milk formula. *Bull. Envir. Contam. Toxicol.* 15:591-592.
- 5- Conney A.H. and Burns J.J.(1972) : Metabolic interactions among environmental chemicals and drugs. *Science* 178: 576-586.
- 6- Cooke A.S. (1970) : The effect of o-p'-DDT on Japanese quail, *Bull. Environ. Contam. Toxicol.* 5:152-157.
- 7- Culling C.F.A. (1974) : *Histological and histochemical techniques*, 3rd ed. Butterworths and Co., New York, London, P. 142.
- 8- Donald G.; Arthur T.; Wadi A. and Joseph T.V. (1965) : Histochemical observation on the endometrium. *J. Obstet. And Gynaecol.* Vol. 8 No. 1:22-38.
- 9- Drury R.A.B. and Walington, E.A.F. (1980) : *Carleton's Histological technique*. 4th edition Oxford University Press-London P.85-89.
- 10- Edwards, R.G. (1967) : Proc. 8th Int. Conf. of I.P.P.F., Santiago de Chile, Int. Plann. Parenth. Fedn., London, 381.
- 11- Eroschenko V.F. and Mousa M. (1979) : Neonatal administration of insecticide chlordecone and its effects on the development of the reproductive tracts in the female mouse. *Toxicol. Appl. Pharm - acol.* 49:151-159.
- 12- Filipe M.I. and Dowson I.M. (1968) : Qualitative and quantitative enzyme biochemistry of human endometrium and cervix in normal and pathological condition. *J. Path. Bact.* 95:243-259.
- 13- Gellert R.J., Heinrichs W.L. and Swedloff R.S. (1972) : DDT homologues : estrogen-like effects in vagina uterus and pituitary of the rat. *Endocrinol.* 91: 1095-1100.
- 14- Gellert R.J., Heinrichs W.L. and Swerdloff R.S. (1974) : Effects of neonatally administered DDT homologs on reproductive function in male and female rats. *Neuroendocrinology* 16:84-94.
- 15- Hall M. (1950) : Alkaline phosphatase in the human endometrium. *Am.J. Obstet. 9 Gynaecol.* 60:212.
- 16- Heinrichs W.L., Gellert R.J., Bakke J.L. and Lawrence N.L. (1971) : DDT administered to neonatal rats induced persistent estrus. *Science, N.Y.* 173:642-643.
- 17- Huber J.J. (1965) : Some physiological effects of the insecticide kepone in the laboratory mouse. *Toxicol. Appl. Pharmacol.* 7:516-524.
- 18- Iguchi T. (1976) : Occurrence of permanent changes in vaginal and

- uterine epithelia in mice treated neonatally with progestrine, estrogen and aromatizable or non-aromatizable androgens endocrinol. Toxicol. 13:401-405.
- 19- Jefferies D.J. (1967) : The delay in ovulation produced by p,p'-DDT and its possible significance in the field. *Ibis* 109:266-272.
- 20- Kupfer D. and Bulger W.H. (1976) : Studies on the mechanism of estrogenic actions of o,p'-DDT : interactions with the estrogen receptors. *Pesticide Biochem. And Physiol.* 6:561-570.
- 21- Laguens R. (1964) : Effect of estrogen upon the fine structure of the uterine smooth muscle cell of the rat. *J. Ultrastructure Res.* 10:576.
- 22- Levin W., Welch R.M. and Conney A.H. (1968) : Estrogenic action of DDT and its analogs. *Fed. Proc. Am. Soc. Exp. Biol.* 27:649.
- 23- Mori T. (1977) : Ultrastructure of the uterine epithelium of mice treated neonatally with estrogen. *Acta. Anat.* 99: 462-468.
- 24- Mousa M.A.; Hassan M.I.; Abdel-Aal M.E. and Khater M.O.(1984) : Histochemical study in the uterus and vagina of mice after neonatal administration of insecticide (Kepone). *Egypt. J. of Histology* 8(1) :104.
- 25- Nigam S.K.; Kashyab S.K.; Gupta R.C. and Karnik A.B. (1977): Effect of technical grade DDT on neonatal mice. *Indian J.Med. Res.* 65(4) :576-578.
- 26- Pearse A.G.E. (1968) : *Histochemistry theoretical and applied* pp. 150 Churchill, London.
- 27- Turner C.D. and Bagnora J.T. (1976) : *General endocrinology*, W.B. Saunders Philadelphia, Ch. 14.
- 28- Turner R.T. and Eliel L.P. (1978) : o-p'-DDT as an estrogen-An evaluation of its ability to compete with Hestracliol for nuclear estrogen receptor sites in the quail oviduct. *Bull. Environ. Contam. Toxicol.* 19(2):139-142.
- 29- Welch R.M., Levin W. and Conney A.H. (1969) : Estrogenic action of DDT and its analogs. *Toxicol. Appl. Pharmacol.* 14:358-367.
- 30- Wilson D.J., Locker D.J. Ritzen C.A, Watson J.T. and Schaffner W. (1973) : DDT concentrations in human milk. *Am. J. Dis. Child.* 125:814-817.
- 31- Wrenn T.R. Weyant J.R., Fries G.F. and Bitman J. (1971) : Effect of several dietary levels of o-p'-DDT on reproduction and lactation in the rat. *Bull. Envir. Contam. Toxicol.* 6:471-480.

التأثير الاستروجيني للمبيد الحشري (د.د.ت) على الجهاز التناسلي لأنثى الفأر الصغير رئيفه فتحى الغريب

يعتبر المبيد الحشري (د.د.ت) من أكثر المبيدات الحشرية انتشارا وشيوعا في العالم. ولقد وجد أن الـ د.د.ت له تأثير استروجيني على كثير من الثدييات والطيور.

والغرض من هذا البحث هو دراسة التغيرات المستولوجية والمستوكيميائية في الجهاز التناسلي لأنثى الفأر الصغير بعد حقنه بالمبيد الحشري الـ د.د.ت وعلاقة هذه التغيرات بتلك التي تحدث نتيجة الحقن بالاستروجين.

ولقد تم تقسيم الفئران المستخدمة الى خمس مجموعات حيث تم حقن ثلاثة منها لعشر جرعات من الـ د.د.ت بتركيز 0.25، 0.5، 1 ملليجرام لكل جرعة ومجموعة تم حقنها بعشر جرعات من الاستروجين 10 مكروجرام لكل جرعة والمجموعة الأخيرة حقنت بزيت السمسم فقط واعتبرت مجموعة ضابطة. ولقد أخذت العينات بعد يومين من آخر حقن حيث حضرت منها عينات شمعية وأخرى مثلجة وذلك لدراسة التغيرات المورفولوجية والمستوكيميائية في كل من مبيض ورحم ومهبل الفأر الصغير.

*زيادة عدد الحويصلات النامية بمبيض الفأر الأبيض وكذلك زيادة نشاط أنزيم الفوسفاتيز القلوي وكمية الحامض النووي الريبوزي والجليكوجية وذلك نتيجة الحقن بالـ د.د.ت.

*لوحظ ازدياد في نمو النسيج المبطن للرحم وظهور غدد رحمية جديدة وقد لوحظ أيضا ازدياد مصاحب في نشاط أنزيم الفوسفاتي القلوي وكمية الحامض النووي الريبوزي والجليكوجين في الحيوانات التي حقنت بالـ د.د.د.

*كما أدى استخدام الحقن بالـ د.د.ت إلى نمو خلايا الغشاء المبطن للمهبل مع تكوين طبقة حرشفية سطحية مصحوبا بازدياد في نشاط أنزيم الفوسفاتيز القلوي وكمية الحامض النووي الريبوزي مع زيادة واضحة في كمية الجليكوجين المترسبة في الخلايا.

وقد دلت النتائج على أن تأثير الحقن بالـ د.د.ت يماثل إلى حد كبير تأثير الحقن بالاستروجين من الناحية المورفولوجية والمستوكيميائية على أعضاء الجهاز التناسلي المختلفة للفأر الصغير.