

قسم الباثولوجيا
كلية الطب البيطري - جامعة أسيوط
رئيس القسم : أ د / حمدي سالم •

عدوى الاسبيروجيلس فبويجيس التي تنشأ نتيجة وجود
الحمام السليم مع الحمام المعدي تجريبيا بهذا الفطر
٢- التغيرات الباثولوجية في الجهاز التنفسي ودور هذا الجهاز
في العدوى بهذا الفطر

محمود عبدالظاهر

وجد أن التغيرات المرضية في الجهاز التنفسي تكون ثانوية لوجود الفطر وسمومه
في الدم وقد وجد أن التغيرات الميكروسكوبية ترجع الى تأثير الفطر على الأنسجة •
أما تكاثر الخلايا الليمفاوية فانه يرجع الى تفاعل الجهاز المناعي الدفاعي عن الجسم
ضد الفطر •

Dept. of Pathology,
Faculty of Vet. Med., Assiut University,
Head of Dept. Prof. Dr. H.A. Salem.

**CONTACT INFECTION WITH ASPERGILLOSIS OF PIGEONS
II. PATHOLOGY OF THE RESPIRATORY SYSTEM IN THIS DISEASE AND
ITS ROLE IN NATURAL INFECTION WITH ASPERGILLUS FUMIGATUS**
(With 4 Figs.)

By
A.Z. MAHMOUD
(Received at 28/9/1987)

SUMMARY

Micromorphological changes seen in the respiratory tract of pigeons with contact infection with Aspergillus fumigatus were secondary to fungemia and mycotoxemia. The micromorphological changes, such as chronic granulomatous lesions, were due to the reaction of the tissue against the presence of the fungus. Lymphoid cell proliferation was due to immune defense against the fungal infection. These observations indicate the importance of different routes of Aspergillus fumigatus infections in this species of birds.

INTRODUCTION

Aspergillosis is the most important fungal disease of birds. Infection occurs mainly via the respiratory tract; thus, the disease is known as brooder pneumonia JONES and HUNT (1983). Recently, it was found that the digestive route could play an important role in the pathogenesis of aspergillus in this species of birds ALI (1985). This work was designed to evaluate the role of the respiratory route in the pathogenesis of aspergillosis of pigeons.

MATERIAL and METHODS

Twenty-five pigeons 3-6 weeks of age were used in this study. These pigeons were clinically healthy and were free of parasites. These pigeons were reared with other pigeons which had been experimentally infected intracrop with Aspergillus fumigatus.

After 21 days all pigeons were killed and examined for gross lesions. Samples were taken from nasal cavity, larynx, trachea, lung, air sacs and heart. The samples were cultured on Sabouraud's agar. Pieces of the samples were fixed in 10% neutral buffered formalin and in Garnoy's solution. Sections were stained with hematoxylin-eosin (H&E) and periodic acid-Schiff (PAS) LILLIE (1965).

RESULTS

Mycological Studies:

After 21 days contact with infected birds Aspergillus fumigatus was isolated on Sabouraud's

A.Z. MAHMOUD

agar from the lung and air sacs of all test pigeons. No fungi were isolated from the nasal cavity, larynx; trachea or heart.

Macromorphological Studies:

Gross examination of the respiratory organs and heart of all experimental pigeons did not reveal detectable changes.

Micromorphological Studies:

The histopathological changes were observed only in the lung and air sacs. The nasal cavity, larynx and trachea did not have changes.

In the focal areas of exudative pneumonia with monocytic and lymphocytic infiltration, congestion was frequently observed. However, the multiple large focal areas of interstitial pneumonia sometimes accompanied with compensatory emphysema could be considered the most significant changes seen in the lung. In these focal areas of interstitial pneumonia, a characteristic granuloma developed. The granulomatous reaction began with the appearance of few giant cells which later increased in numbers and underwent necrotic changes. The necrotic areas were surrounded by epithelial granulation typical of aspergillus granulomas (Fig. 1). Focal areas of granulomatous inflammation were observed in the lung and consisted of epithelioid cells and large giant cells, whose cytoplasm contained fungal particles. The latter stained dark blue with H&E. In the focal areas of interstitial pneumonia, the main reacting cells were lymphoid and epithelioid septal cells. Few superimposed neutrophils were frequently seen.

The distributions of the pneumonic areas were always perivascular and peribronchial, i.e. around tertiary bronchi. The bronchial systems were completely free from any pathological changes. The blood vessels in the vicinity showed endothelial cell proliferation with accumulation of mononuclear cells in the lumen (Fig. 2). Perivascular lymphocytic cuffs were always seen in the lungs of all contact cases. The lymphoid follicles around the bronchi were hyperplastic but did not develop into typical aspergillus granuloma.

Microscopical examination of the air sacs revealed diffuse thickening of the air sacs with epithelial granulation and typical aspergillus granuloma (Fig. 3). The epithelioid granulation had abundant lymphoid cells and few superimposed neutrophil cells. Neither gross nor histopathological changes were seen in the heart.

periodic acid-Schiff Studies (PAS). PAS positive fungal mycelia were seen in the granuloma (Fig. 4). PAS positive mycelial particles were seen in the cytoplasm of giant cells in the lungs and air sacs.

DISCUSSION

Lesions of the respiratory system developed in pigeons with contact infections with Aspergillus fumigatus. The infections were not primary but were secondary to fungemia and probably mycotoxemia (infection occur through the digestive system due to consumption of contaminated feeds). The distribution of the lesions around the blood vessels and in the pulmonary tissues around the tertiary bronchi and the complete absence of the histopathological lesions from the bronchial system support this concept. Gross pathological changes could not be detected in this study. These results are in agreement with those of TAYLOR (1966) who recorded an outbreak of Aspergillus fumigatus in pigeons in which no gross pathological lesions were detected.

CONTACT INFECTION IN ASPERGILLOSIS PATHOLOGY OF THE RESPIRATORY SYSTEM

Lesions in the lungs of pigeons with contact infection of Aspergillus fumigatus were of two types. One type of lesion was due to the direct effect of the fungus and its toxins on the tissue and included typical granuloma formation, proliferation of septal cells of the lung with development of focal areas of interstitial pneumonia, and vascular lesions. The latter were represented by proliferative vasculitis and perivascular lymphocytic cuffing.

The second type of lesions were due to the immune defense mechanism of the body against the fungus infection. These lesions represented by widespread proliferation of lymphoid tissue, especially around the bronchi. ALI (1985) observed these two types lesions in pigeons experimentally infected with Aspergillus fumigatus. Similar lesions were also observed by NAFADY (1978) in chickens experimentally infected with Aspergillus fumigatus. Micromorphological changes were not observed in the upper respiratory tracts, i.e. nasal cavity larynx and trachea. These observations are contrary to the infection by inhalation. Proliferative vasculitis is good evidence of fungemia. Lesions of the air sacs were common in all experimental birds and were of chronic granulomatus nature. The lesions were due to localization of the fungus in these organs after the process of fungemia. PAS positive - mycelia were seen in the air sacs. Cardiac lesions were not observed in the experimental birds. Histopathological heart changes were detected in the cardiac muscle only after the fifth week of experimental aspergillosis ALI (1985). MITROIU, et al. (1962) reported lymphocytic and histocytic cellular infiltration in the cardiac muscle of chickens infected intravenously with Aspergillus fumigatus.

REFERENCES

- Ali, S.R. (1985): Histopathological and serum electrophoretic studies on experimental aspergillosis. Thesis M.V.Sc. Fac. of Vet. Med., Assiut Univ.
- Jones, T.C. and Hunt, R.D. (1983): Veterinary pathology. Fifth Edn. Philadelphia P. 667-669.
- Lillie, R.D. (1965): Histopathologic technic and practical histochemistry 3rd Edn. New York. McGraw. Hill.
- Mitroiu, P.; Jivoin, P. and Sirbu, Z. (1962): Pathogenicity of aspergillus fumigatus strains and the lesions in avian aspergillosis. *Lucr. Inst. Cerc. Vet. Bioprep. pasteur.* 1: 473-481.
- Nafady, A.A. (1978): Pathological studies on aspergillosis in poultry. Thesis M.V.Sc. Fac. of Vet. Med., Assiut University.
- Taylor, P.A. (1966): Mycotic pneumonia in pigeons, *Can. Vet. J.* 7: 11, 262-263.

Fig. (1)

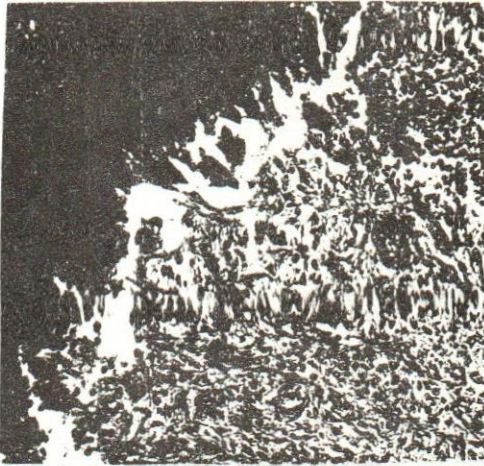


Fig. (3)


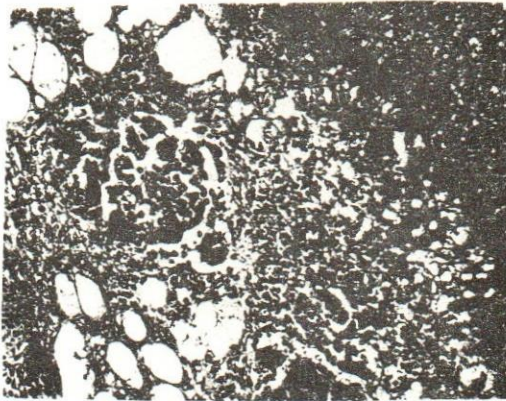
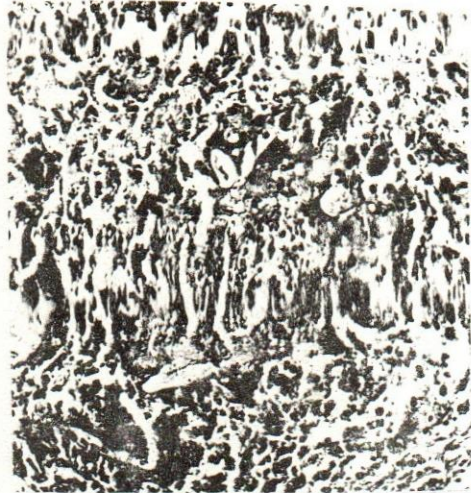


Fig. (2)

Fig. (4)

Fig. (1): Aspergillus granuloma in the lung H & E (16x).

Fig. (2): Blood vessels showed accumulation of mononuclear cells in the vicinity of granuloma. H & E (16x).

Fig. (3): Air sacs thickened by lymphoid cells and showed typical aspergillus granuloma. H & E (16x).

Fig. (4): PAS positive mycellia in the central Zone of pulmonary granuloma. PAS (16x).

