

قسم : التشريح والهيستولوجيا .
كلية : الطب البيطري - بمشتهر - بنها .
رئيس القسم : أ. د. / محمد حسين الشايب .

بعض الدراسات التشريحية على الجذع العضدي الدماغى

في الجاموس المصرى

محمد عطية

تم في هذا البحث دراسة منشأ ومسار وتفرعات الجذع العضدي الدماغى فى
الجاموس المصرى . هذا وقد نوقشت النتائج مع مثيلاتها فى الحيوانات الأخرى .

INTRODUCTION

In Egypt, the buffalo is one of the most important animals used for milk and meat production. Little was met with in the available literature concerning the anatomy of the vascular system of this animal in general and especially its brachiocephalic trunk. The present investigation was carried out to give a detailed description on the special anatomical features of the trunk in the buffalo.

MATERIAL and METHODS

This study was carried out on four adult buffaloes of both sexes and different ages and from different localities. These animals were recently dead and collected from local slaughter houses. They were fixed in 10% formalin solution and after 48 hours with gum copaloloid were embedded with subsequent cut of the trunk B.A.L. Vagwagwag through the common carotid artery. The nomenclature of the arteries used is that adopted by N.A.V. (1953).

RESULTS

The brachiocephalic trunk (B.C.T.) arose from the aortic arch during its course within the pericardium at the level of the cranial border of the fourth rib. It passes craniodorsally in the pericardial sac between the trachea dorsally and the oesophagus ventrally. It is crossed on both sides by the vagus nerves. In the first case, the brachiocephalic trunk terminated by dividing into the right subclavian artery and the right common carotid artery. In the second case, the right subclavian artery was a foot size and the common carotid artery was a foot size.

In other two cases, the trunk brachiocephalic divided the left common carotid artery then extended to the thoracic inlet where it gave off the right common carotid artery and continued as the right subclavian artery.

1- A. subclavia sinistra et dextra

The left subclavian artery (L.S.A.) originates from the left cranial part of the thoracic brachiocephalic trunk. In one case, it arose at the first intercostal

Dept. of Anatomy & Histology,
Fac. of Vet. Med., Moshtohor, Banha,
Head of Dept. Prof. Dr. M. El-Shaieb.

SOME ANATOMICAL STUDIES ON TRUNCUS BRACHIOCEPHALICUS OF EGYPTIAN BUFFALO (BOS BUBALIS L)

(With Two Figures)

By

M. ATTIA

(Received at 21/5/1986)

SUMMARY

The origin, course and distribution of the Truncus brachiocephalicus in the buffalo are described in details. The obtained results were compared and discussed with that of other ruminants especially cattle.

INTRODUCTION

In Egypt, the buffalo is one of the most important animals used for milk and meat production. Little was met with in the available literature concerning the anatomy of the vascular system of this animal in general and especially its brachiocephalic trunk. The present investigation was carried out to give a detailed description on the special anatomical features of this trunk in the buffalo.

MATERIAL and METHODS

This study was carried out on four adult buffaloes of both sexes and different ages and three fetuses. These animals were recently dead and collected from kalyobia farms. They were injected at first with 10% formaline solution and after 48 hours with gum milk-latex coloured with vulkanosol red of the firma BASF. Vudwigshafen through the common carotid artery. The nomenclature of the arteries used is that adopted by N.A.V. (1983).

RESULTS

The brachiocephalic trunk (1, 2/2) arises from the aortic arch during its course within the pericardium at the level of the cranial border of the fourth rib. It passes craniodorsally in the pericardiac mediastinum related to the trachea dorsally and Vena cava cranialis ventrally. It is crossed on both sides by the vagus nerve. In the five cases, the brachiocephalic trunk terminated by dividing into the right subclavian artery and bicarotid trunk. Its level of termination lies opposite to the first intercostal space in four cases and at the thoracic inlet in one specimen.

In other two cases, the truncus brachiocephalicus detached the left common carotid artery then extended to the thoracic inlet where it gave off the right common carotid artery and continued as the right subclavian artery.

1- A. subclavia sinistra et dextra:

The left subclavian artery (1/3) originates from the left dorsolateral aspect of the Truncus brachiocephalicus medial to the second rib. Only in one case, it arose at the first intercostal

space. It runs craniad parallel to its parent vessel and inclines ventrally to leave the thoracic inlet curving around the first rib to continue as A. axillaris sinistra (1/35). The right subclavian artery (2/4) arises opposite to first intercostal space in four dissected specimens and cranial to the thoracic inlet in the rest of the cases. In all cases, it leaves the thorax and continues as A. axillaris dextra (2/35).

Along their course, the left and right subclavian gives off Truncus costocervicalis, A. thoracica interna and A. cervicalis superficialis.

Truncus costocervicalis:

The left costocervical trunk (1/5) arises from the subclavian artery at the level of the first intercostal space. The right costocervical trunk (2/5) is given off the A. subclavia in five cases and Truncus brachiocephalicus in the rest two specimens. the level of origin presents medial to the first rib in four and cranial to the thoracic inlet in the rest cases.

The costocervical trunk courses craniodorsally crossing the esophageus on left side and trachea on the right side, then it leaves the thoracic inlet and continues its course between M. scalenus medius laterally and M. longus colli medially.

About 2 cm ventral to the caudal border of the transverse process of the last cervical vertebra, the costocervical trunk detaches A. cervicalis profunda and continues as A. vertebralis. Along its course, it gives off A. intercostalis suprema and A. scapularis dorsalis.

A. intercostalis suprema:

The left supreme intercostal artery (1/7) arises from the costocervical trunk about 1 cm from its origin and opposite to the first intercostal space. The A. intercostalis suprema dextra (2/7) originates with the A. scapularis dorsalis from Truncus costocervicalis by a stem vessel (2/6) in all dissected specimens. This stem vessel varies from 1 to 3 cm in length and lies medial to the first rib in four cases and cranial to the thoracic inlet in the rest specimens.

The A. intercostalis suprema runs caudodorsally on the lateral aspect of the esophageus on the left side and the trachea on the right side. Then it curves caudally to continue its course on M. longus colli where it terminates opposite to the third or fourth rib. It detaches the Aa. Intercostales dorsales I & II on the left side (1/8) and Aaintercostales dorsales 1-111 on the right side (2/8) in addition to their Rt. dorsales. (1, 2/8).

A. Scapularis dorsalis:

The left dorsal scapular artery (1/9) springs medial to the first rib. The right dorsal scapular artery (2/9) in three cases arose cranial to the thoracic inlet.

It runs craniodorsally on M. longus colli, leaves the thoracic inlet and ascends along the cranial border of the first rib. It continues its course deep to M. serratus ventralis cervicis where it ramifies in the cervical portion of Mm. rhomboideus and trapezius as well as the skin in the withers.

A. Cervicalis profunda:

The deep carvical artery (1, 2/10) passes dorsally between the transverse processes of the last cervical and first thoracic vertebrae covered laterally by Mm. intertransversir cervices. It detaches R. spinalis VIII 1, 2/11) and divides into a R. superficialis and R. transversus.

TRUNCUS BRACHIOCEPHALICUS OF EGYPTIAN BUFFALO

The superficial branch (1, 2/12) courses craniodorsally on the lateral aspect of *M. semispinalis capitis* and ramifies in the cervical portion of *M. rhomboideus* and *trapezius*.

The transverse branch (1, 2/13) passes dorsomedially deep to *M. semispinalis capitis* and ends in this muscle near to the caudal end of fifth cervical vertebra. It gives off twigs to *Mm. Splenius* and *longissimus capitis et atlantis*.

A. vertebralis

The vertebral artery (1, 2/14) forms the direct continuation of the costocervical after detaching the *A. cervicalis profunda*. It runs craniodorsally deep to the *M. scalenus medius* then ventral to the transverse process of the last cervical vertebra to gain the transverse foramen of the sixth cervical vertebra. It continues its course within the transverse canal of the cervical vertebrae. Along its course, the *A. vertebralis* gives off.

Rr. dorsales, The dorsal branches (1, 2/15) are strong and are given off *A. vertebralis* just before its entrance into the transverse foramen of the preceding vertebra. Each *R. dorsalis* extends craniodorsally crossing the lateral aspect of the caudal articular process of the preceding vertebra and ramifies in the dorsolateral muscles of the neck and skin covering. These branches compensate for the absence of *R. ascendens* of *A. cervicalis profunda*.

Rr. ventrales, Each of the ventral branches (1, 2/16) descends along the body of the corresponding cervical vertebra cranial to its transverse process and is distributed in the *Mm. intertransversarii cervicis* and *longus colli*.

Rr. spinales, They enter the intervertebral foramina to gain the vertebral canal to supply the spinal cord and its meninges.

A. thoracica interna, The internal thoracic artery (1, 2/7) is given off *A. subclavia medial* to the first rib on the left side and cranial to it on the right side. Only in one case, the right thoracic artery was given off *truncus brachiocephalicus*.

It passes caudoventrally to the second rib then runs caudally deep to *M. transversus thoracis* till the 7th costal cartilage. Here it detaches *A. musculophrenica* and continues its course as *A. epigastrica cranialis*.

Along its course, The internal thoracic artery gives off:

Rr. intercostales ventrales, Fine twigs to the mediastinum. In the young three cases, **Rr. thymici** are given off to the thymus, **R. Perforantes** and **A. pericardiophrenica**.

The perforating branches (1, 2/22) spring from the ventrolateral aspect of *A. thoracica interna*. The third perforating branch is given off with *R. intercostalis ventralis* by a stem vessel. The perforating branch passes through the corresponding interchondral space, detaches *R. sternalis* and ramifies in the pectoral muscles.

The pericardiophrenic artery (1, 2/23) arises from the ventromedial side of the parent vessel medial to the sixth costal cartilage. Only in one dissected case, the right pericardiophrenic artery was absent and their two terminal branches (*R. pericardiacus* and *R. phrenicus*) were given off opposite to the 4th and 5th costal cartilages respectively.

The pericardiophrenic artery passes craniomedially deep to *M. transversus thoracis* for about 3 cm and pierces it. Then it ascends on the caudolateral aspect of the pericardium for about 3 cm and divides into *R. pericardiacus* and *R. phrenicus*. The pericardiac branch ascends

on the pericardium till a level of 4 cm ventral to the coronary grooves where it divides into a cranial and caudal branch. The former anastomoses with that of the opposite side at the cranial border of the pericardium while the other terminates at the caudal border.

The phrenic branch extends caudad in the postcardiac mediastineum. It reaches the thoracic surface of the diaphragm and divides into two twigs which ramify after a short course.

A. musculophrenica.

The musculophrenic artery (1, 2/24) runs caudodorsally piercing the sternal part of the diaphragm at the level of the seventh interchondral space. It continues its course subperitoneally on the inner face of the costal arch between the interlocked digitations of the costal part of the diaphragm with M. transversus abdominis.

It terminates in the later muscle at the level of the 11th rib. During its course the A. musculophrenica detaches,

Rr. phrenici, these branches (1, 2/25) are 4-5 in number and supply the costal part of the diaphragm.

Rr. musculares: The muscular branches (1, 2/26) are 3-4 in number and descend to supply M. transversus abdominis.

Rr. intercostales ventrales: The ventral intercostal branches (1, 2/18) are segmental branches. The Rr. intercostales ventrales I-VI are given off A. thoracica interna while those from VII to X arise from the A. musculophrenica. They ascend subpleurally in the corresponding intercostal space.

The first ventral intercostal branch is a delicate twig arises from the ventral aspect of the parent vessel and descends in its intercostal space where it fades in the Mm. intercostales interni. Each of the other Rr. intercostales ventrales divides into R. postcostalis and R. precostalis.

The postcostal branch (1, 2/19) is, larger than the R. precostalis, and ascends subpleural along the caudal border of the corresponding rib where it anastomoses with the A. intercostalis dorsalis of the same space. This anastomosis is not seen in the first and second intercostal spaces on the left side in addition to the third one on the right side. The R. postcostalis sends the R. cutaneus lateralis and fine twigs to supply the Mm. intercostales and rectus thoracis. The R. cutaneus lateralis (1, 2/20) pierces the Mm. intercostales, serratus ventralis thoracis, pectoralis profunda and obliquus externus abdominis to distribute in the cutaneus trunci and skin in the ventral portion of the lateral thoracic wall.

The precostal branch (1, 2/21) passes caudodorsally to continue its course along the cranial border of next rib. It anastomoses with one of the collateral branches of A. intercostalis dorsalis of the same space.

A. epigastrica cranialis:

The cranial epigastric artery (1, 2/27) runs between 8th costal cartilage and xiphoid process to gain the dorsal surface of M. rectus abdominis where it continues caudally. An anastomosis is established between the A. epigastrica cranialis and A. epigastrica caudalis at the umbilical region. During its course, it gives.

A. epigastrica cranialis superficialis: This artery (1, 2/28) arises at a level with the caudal end of the xiphoid cartilage. It pierces the M. rectus abdominis and the ventral layer

TRUNCUS BRACHIOCEPHALICUS OF EGYPTIAN BUFFALO

of the rectus sheath. Then it runs caudad subcutaneously where it anastomoses with the A. epigastrica caudalis superficialis.

Rr. mediales: The medial branches (1, 2/29) are 5-6 in number. They are directed medially towards the linea alba where they ramify.

Rr. laterales: The lateral branches (1, 2/30) are 6-8 branches. they pass lateral on the dorsal surface of M. rectus abdominis and distribute in the external and internal oblique muscle of the abdomen. The last two dorsal intercostal arteries (1, 2/38) cross the costal arch, reach the M. rectus abdominis and anastomose with the lateral branches of the A. epigastrica cranialis.

A. cervicalis superficialis: The superficial cervical artery (1/31) is given off A. subclavia about 2-3 cm cranial to the thoracic inlet. only in one specimen it arose at a level medial to the first rib. It passes craniad between M. scalenus medius dorsally and external jugular vein ventrally, then it curves dorsally deep to the M. brachiocephalicus. At a level 3 cm. ventral to the ventral pole of the superficial cervical lymph node, the superficial cervical artery gives off **R. ascendens** and continues as **R. prescapularis**. The superficial cervical artery gives off:

Rr. musculares. They are 2-3 fine branches to Mm. scalenus medius and sternocephalicus.

R. deltoideus: The deltoid branch (1/32) arises at a distance 6 cm cranial to the first rib. Only in two dissected specimens, this branch was given off A. thoracica externa. The deltoid branch curves caudoventrally in the lateral pectoral groove in relation to the V. cephalica. It supplies the Mm. pectoralis descendens and brachiocephalicus.

R. ascendens: The ascending branch (1/33) is a small vessel extends cranially deep to M. brachiocephalicus till the level of the caudal end of the 5th cervical vertebra.

R. prescapularis

The prescapular branch (1034) runs dorsal between the superficial cervical lymphocenter cranially and M. subclavius caudally to terminate, in the M. trapezius cervicis. this branch gives off 3-4 glandular branches to the abovementioned lymphocenter, and 1-2 twigs to the M. subclavius.

Truncus bicaroticus

The bicarotid trunk (2/36) is seen in five cases. Its length varies from 2-5 cm. The trunk lies ventral to the trachea and divides into the right and left common carotid arteries (1, 2/37). In two cases, these arteries were given off Truncus brachiocephalicus.

DISCUSSION

The origin of the brachiocephalic trunk in the buffalo is similar to that of ox (SEIDLER, 1966), sheep (MUNTER, 1962), goat (OTTO, 1961) and camel (ATTIA, 1980)

The brachiocephalic trunk terminated by dividing into A. subclavia dextra and Truncus bicaroticus in five dissected cases as in swine and ruminants (KOCH, 1970, WILKEN & MUNSTER, 1981). However, in two specimens, the truncus bicaroticus did not seen and the two common carotid artery were given off Truncus brachiocephalicus a condition which is reported in the carnivora (GHOSHAL, 1975).

M. ATTIA

The A.subclavia sinistra in the present work arises at the medial border of the second rib resembles that of the sheep (MUNTER, 1962 and MAY, 1970) but in ox it springs at the first intercostal space. On the other hand, the A.subclavia dextra is given off at the first intercostal space in the buffalo similar to the camel (ATTIA, 1980) while in ox (SEIDLER, 1966) and sheep (MUNTER, 1962) it originates medial to the first rib.

According to WILKENS and MUNSTER (1981) and GHOSHAL (1975) in ruminants, the truncus costocervicalis arises from the subclavian artery as in the present study. However, the right costocervical trunk was given off Truncus brachiocephalicus in two dissected specimens a condition which reported in horse by BRADLEY 1922).

The left costocervical trunk springs at the first intercostal space as reported in ox by SEIDLER, (1966). The right costocervical trunk in the present observation arises medial to the first rib, SEIDLER (1966) in cattle affirmed its origin cranial to this rib as was observed in three dissected specimens.

The origin of the A.intercostalis suprema in the buffalo is in a line with that recorded by WILKENS and MUNSTER, (1981) in the ruminants.

The right supreme intercostal and dorsal scapular arteries originate by a stem vessel in all dissected cases a condition which was observed by SEIDLER (1966) only in one case of the cattle. However, MUNTER (1962) stated that in sheep the A. intercostalis suprema is given off A. scapularis dorsalis.

The A. intercostalis suprema sinistra is given off at the first intercostal space in the buffalo and the medial aspect of the first rib in cattle (SEIDLER, 1966).

According to GHOSHAL (1975) and WILKENS and MUNSTER (1981) in ruminants, the A.scapularis dorsalis in the buffalo is given off Truncus costocervicalis. It springs medial to the first rib in this study, SEIDLER (1966) in cattle beside WILKENS and MUNSTER (1981) in ruminants stated its origin cranial to this rib.

In agreement with GHOSHAL (1975) in ruminants the A. cervicalis profunda is given off Truncus costocervicalis. The R. superficialis and R. transversus of A. cervicalis profunda in the buffalo are also described by SEIDLER (1966) in cattle and by ATTIA (1980) in camel. The deep cervical artery distributes in the caudal cervical and withers region, in contrast to SEIDLER (1960) and WILKENS and MUNSTER (1981) in cattle stated that it supplies the cervical musculature from withers to nape. Similar observation as that of the buffalo is indicated by MUNTER (1962); MAY (1970) in sheep and ATTIA (1980) in camel. The origin and course of A.vertebralis in the present study agreed with that recorded in the other ruminants (WILKENS and MUNSTER, 1981), however, the Rr. dorsales of A.vertebralis in buffalo are stronger to compensate the short course of A. cervicalis profunda.

The origin of the A. thoracica interna in the buffalo is similar to that of the ruminants (WILKENS and MUNSTER, 1981).

In agreement with GLAGOLEV, (1969) in ruminants, the A. thoracica interna in buffalo gives off A musculophrenica and continues as A. epigastrica cranialis.

The A. pericardiacophrenica in the buffalo is distributes in the pericardium and diaphragm but MUNTER (1962) in sheep and SEIDLER (1966) in cattle described only R.phrenicus from A. thoracica interna. On the other hand, WILKENS and MUNSTER (1981) stated that this artery traced only up to the pericardium in domestic animals, it may reach the diaphragm or anastomose with A. phrenica before it reaches it.

TRUNCUS BRACHIOCEPHALICUS OF EGYPTIAN BUFFALO

The Rr. precostales and postcostales of Rr. intercostales ventrales in the buffalo are also described by OTTO (1961) in goat for the second to the sixth intercostal space and by ATTIA (1980) in camel from the second to seventh while MUNTER (1962) in sheep reported four cases in which a R. precostalis is given off A. thoracica interna for the cranial border of the 5th and 6th ribs.

The A. musculophrenica terminates at the level of 11th rib while in ruminants, this level lies at 10th rib (WILKENS and MUNSTER, 1981).

The R. laterales of A. epigastrica cranialis in the buffalo anastomose with the A.inter costalis dorsalis ventral to the costal arch, SEIDLER (1966) in cattle, WILKENS and MUNSTER (1981) in ruminants and ATTIA (1980) in camel affirmed this result. GHOSHAL (1975) considered these branches as Rr. intercostales ventrales and R. costoabdominalis ventralis.

The origin and distribution of A. epigastrica cranialis superficialis agreed with that described in ruminants (WILKENS and MUNSTER (1981)).

The origin, course and branches of A.cervicalis superficialis in the buffalo are similar to the described by GHOSHAL (1975) and WILKENS and MUNSTER, (1981) in ruminants.

REFERENCES

- Attia, M. (1980): Anatomical studies on the arterial blood supply of the trunk in the one humped camel (*Camelus dromedarius*). Thesis M.V.Sc. Assiut University Egypt.
- Bradley, O.CH. (1922): The topographical anatomy of the thorax and abdomen of the horse M. Green and son, Edinburgh.
- Ghoshal, N.G. (1975 b): Ruminant heart and arteries in. Sisson and Grossman, S. the anatomy of Domestic animals. Vol. I. 5th ed 960 - 1022. W.B. saunders comp. philadelphia London.
- Glagolev, V.E. (1969): Anatomy of the farm animals. Kolos. Moscow.
- Koch, T. (1970): Lehrbuch der Veterinar Anatomie B and III. VBE verlag Gustav fischer, Jena.
- May, N.D.S. (1970): The anatomy of the sheep 3rd ed Univ. Queensland press, st. Lucia Brisbane, Queensland.
- Munter, V. (1962): Arterien der korperwand des shafes Hannover, tierarzt-Hochsch., Diss-Med. Vet.
- Otto, E. (1961): Arterien der korperwand des shafes Hannover, tierarzt-Hochsch., Diss-Med. Vet.
- Seidler, D. (1966): Arterien und venen der korperwand des Rind. Hannover, tierarzt. Hochsch. Diss. Med. Vet.
- Wilkins and W. Munster (1981): The circulatory system, the skin and cutaneous organs of the Domestic mammals: In Nickel, schummer and seiferle, B. III Verlag P. parey, Berlin-Hamburg.

M. ATTIA

LEGENDS

Fig (1 & 2)

A- Costa I**C- Sternum**

- 1- Arcus aortae.
- 3- A. subclavia sinistra.
- 5- Truncus costocervicatis.
- 7- A. intercostalis suprema.
- 9- A. scapularis dorsalis.
- 11- R. spinalis of 10.
- 13- R. transversus.
- 15- R. dorsalis of 14.
- 17- A. thoracica interna.
- 19- Rr. postcostales.
- 21- Rr. precostalis.
- 23- A. pericardiocophrenicg.
- 25- rr. phrenici of 24.
- 27- A. epigastrica cranialis.
- 29- Rr. mediales of 27.
- 31- A. cervicalis superficialis.
- 33- R. ascendens.
- 35- A. axillaris.
- 37- A. carotis communis.

B- Costis XIII**D- Vertebra cervicalis VII**

- 2- Truncus brachiocephalicus.
- 4- A. subclavia dextra.
- 6- Stem vessel.
- 8- A. intercostalis dorsalis.
- 10- A. cervicalis profudus.
- 12- R. superficialis.
- 14- A. vertebralis.
- 16- R. ventrlis of 14.
- 18- Rr. intercostales ventralis.
- 20- Rr. cutanei laterales.
- 22- Rr. perforantes.
- 24- A. musculophrenica.
- 26- Rr. musculares of 24.
- 28- A. epigastrica cranialis superficialis.
- 30- Rr. laterales of 27.
- 32- R. deltoideus.
- 34- R. prescapularis.
- 36- Truncus bicaroticus.
- 38- Aa. intercostales dorsales of the aorta.

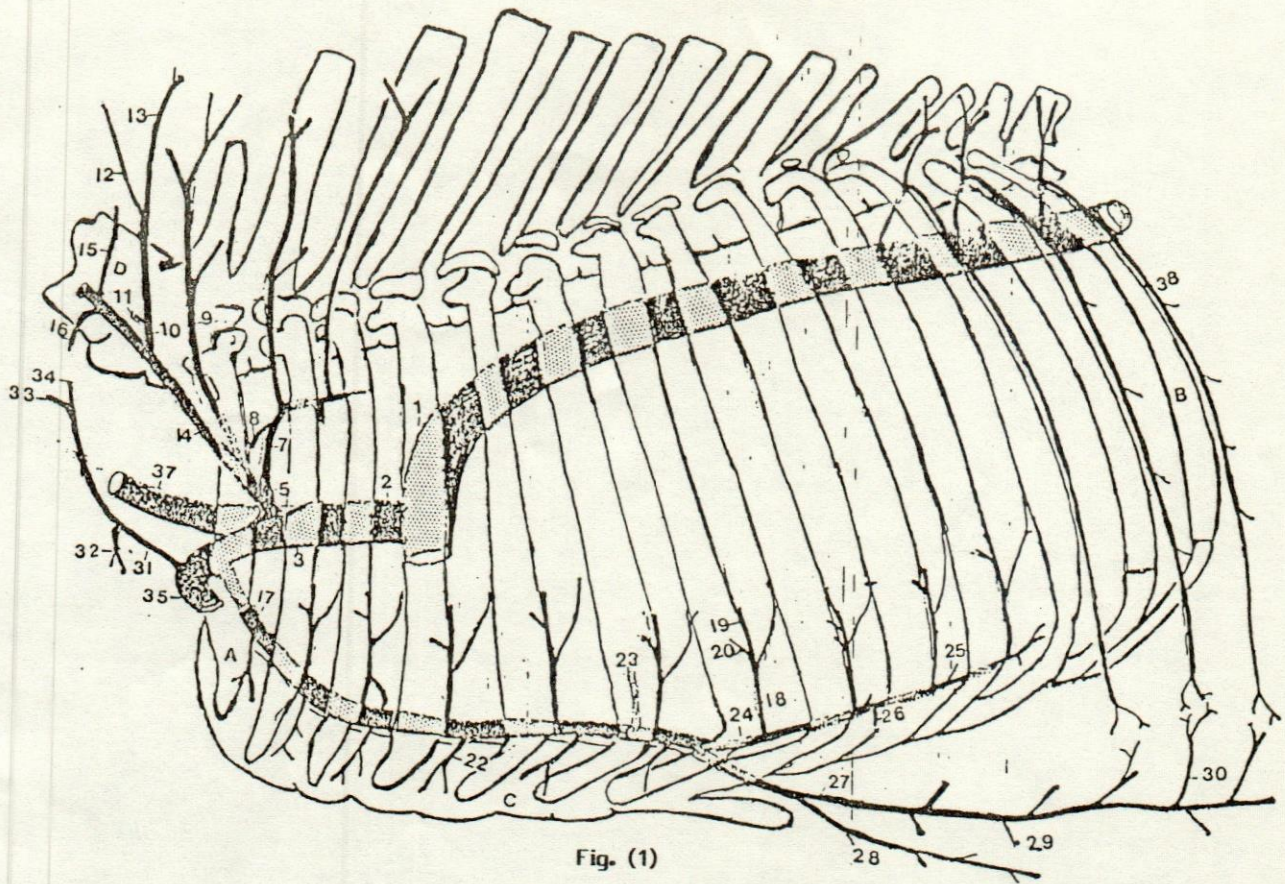


Fig. (1)

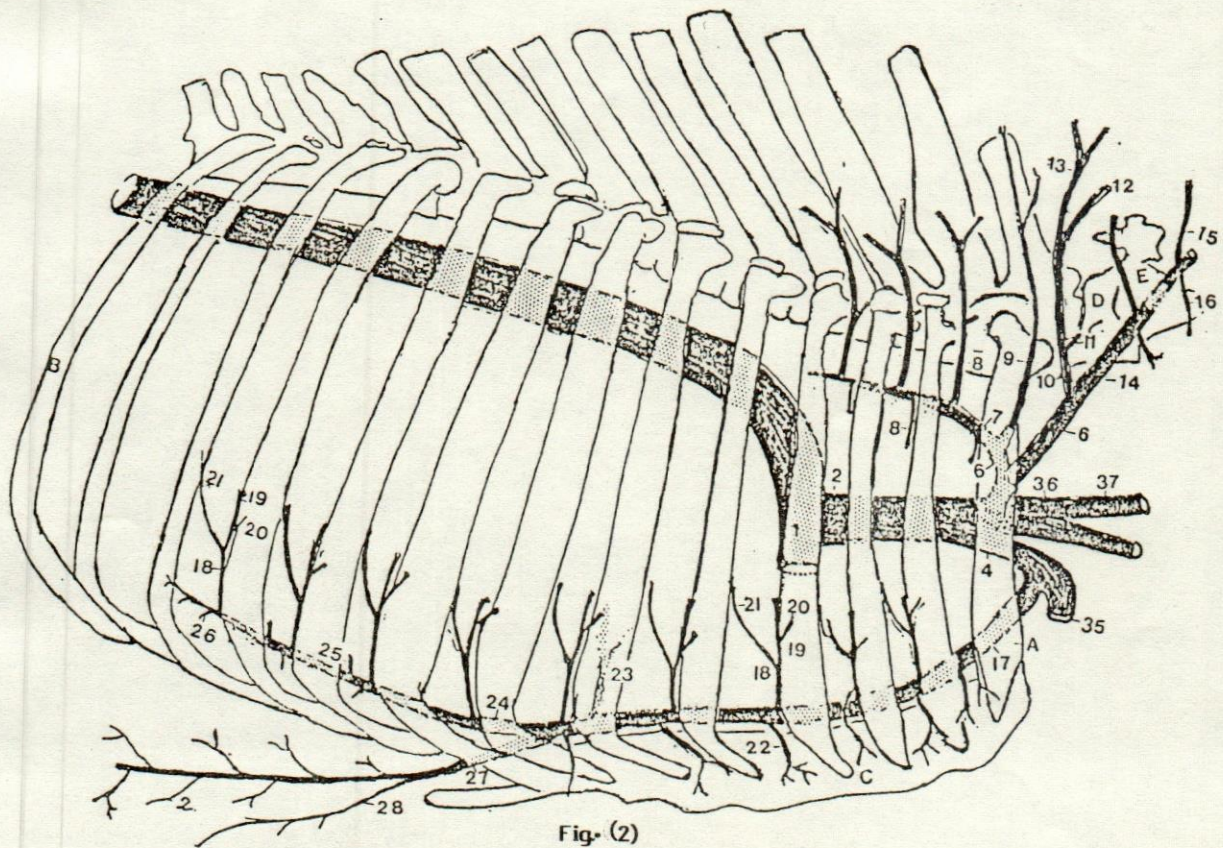


Fig. (2)