

قسم: التشريح والهستولوجيا.  
كلية: الطب البيطرى - جامعة الاسكندرية.  
رئيس القسم: أ.د. أنور محمد علي قاسم.

## دراسات طبوغرافية وتشريحية للأسنان والاشارة الى بعض اصاباتها الجراحية في الحمار والحصان

محمد سلامه ، مصطفى قاسم +

أجريت دراسة التشريح الطبوغرافى فى الأسنان على عدد عشرون جمجمة حمار من الجنسين تتراوح أعمارهم من ٥ - ٢٠ سنة ٠٠ وكذلك عدد عشرة جمجمة حصان ممن الجنسين تتراوح أعمارهم من ٥ - ٢٠ سنة. تمت الدراسة أطوال أسنان كل من الفكين العلوى والسفلى وكذلك دراسة العلاقة بين طول التاج والجذر بالنسبة الى تقدم العمر وتم أيضا دراسة العلاقة بين طول جذور أسنان الفك العلوى والجيوب الجار أنفية مع تقدم العمر.

وبالنسبة لبعض الأصابات الجراحية التي وجدت فى أسنان الحمير والخيول فقد تم دراسة عدد ٤٩ جمجمة وعلى ٩ حيوانات وتبين من الدراسة أن أكثر الأصابات انتشارا وتتطلب التدخل الجراحي مبكرا تفاديا من المضاعفات هى : تسوس الأسنان الحاده، زيادة طول الضرس الثانى فى الفك العلوى ، الترسبات الكلسية وكسور الأسنان ، الزيادة عن العدد الطبيعى فى الاسنان وأخيرا الزيادة فى حجم وطول السنه كما وجد بعض الأصابات الأقل خطورة مثل وجود مسافات متباينة بين الأسنان المجاوره فى الفك السفلى ونقص عدد الأسنان عن العدد الطبيعى .

+ : قسم الجراحة - كلية الطب البيطرى - جامعة الاسكندرية

Dept. of Anatomy, Histology & Embryology,  
Faculty of Vet. Med., Alex. University,  
Head of Dept. Prof. Dr. A.M. Kassem.

**TOPOGRAPHICAL ANATOMICAL STUDIES ON THE TEETH  
WITH SPECIAL REFERENCE TO SOME SURGICAL  
AFFECTIONS IN DONKEY AND HORSE**

(With 1 Table & 14 Figs.)

By

**A.E. AMIN and M.M. KASSEM**

(Received at 23/11/1986)

**SUMMARY**

The topographical anatomical studies of the teeth were carried out on 20 skulls of donkeys ranging in age between 5-20 years and 10 skulls of horses aging from 5-20 years. In 4 cases of donkeys and one case of horses a rudimentary upper 1P (wolf tooth), was found in upper jaw, which is short, narrow, smooth and lighter in colour. At age of 5-6 years in donkeys and horses we found that the cheek teeth have a long crown (hypodont type), the part of the crown embedded in the alveoli is known as the reserve crown. It was found that the lateral root of 4P and all roots of 1M are embedded in the inferior maxillary sinus, but in horses all roots of 4P and 1M are embedded in the inferior maxillary sinus. While the roots of 2M and 3M are embedded in the superior maxillary sinus in donkeys and horses.

Some dental affections were recorded from 49 skulls of donkeys and horses and also from 9 clinical cases. These affections were classified according to their incidence, dental caris, sharp enamel points, projection of 2P upper cheek teeth, dental tartar (calculus), diastasis dentium, fracture of the teeth, polydentia, exuberantia dentis, all these cases must be treated as early as possible to avoid more complications. Another recorded cases were diastasis dentium, stepformed table mouth and oligodontia.

**INTRODUCTION**

The anatomical studies on the teeth in the horse have adquate attention, Johna, Taylor, Oliver and BODY (1955); HABEL (1965); NICKEL, SCHUMMER and SEIFERLE (1973); CLAIR (1975) and BONE (1979). Nothing was found in the available literature about the topographical anatomical studies of the teeth in donkeys except a very brief idea about morphology and radiography given by BUNGER and HERTSCH (1981). In this respect the present investigation was carried out with the object of studying in detail the topographical anatomy of the teeth in donkeys and horses. On the other hand surgical affections of the teeth in horses have been recorded by many authors under the item of abnormalities of the development, irregular wear of the teeth and alterations in the substance of the teeth (FRANK, 1964; BERGE, 1966; OEHEME and PRIER, 1964 and O'CONNOR, 1980). In the available literature surgical affections of the teeth in donkeys have not been reported, except that discussed by MISK and HIFNY (1982) in south Egypt.

### **MATERIAL and METHODS**

The topographical anatomical studies of the teeth were carried out on 20 skulls of donkeys of age ranging between 5-20 years and 10 skulls of horses aging from 5-20 years, the dentition of these subjects was carried out on the lower incisor teeth after BONE (1979).

Removal of the teeth from the alveoli and opening the maxillary sinuses was performed by using a bone scissors.

The incidence of surgical affections of the teeth was recorded from 49 skulls, of 40 donkeys and 9 horses of both sexes and of different ages. Some of these dental affections were recorded from animals presented to our clinic suffering from oral affections (7 donkeys and 2 horses). Every case was thoroughly examined after tranquilization with combelen (1 ml/100 kg.b.wt.) injected intramuscularly.

### **RESULTS**

In the present study the length of the upper incisors was 5-6 cm in donkeys and 5.5-7 cm in horses, while the length of lower incisors 4-4.5 cm in donkeys and 5-6 cm in horses. They are increasing slightly in length from the lateral to the medial. The depth of the infundibulum 12-15 mm. in upper incisors and 6 mm. in lower incisors. The curvature of the upper incisor is generally marked than the lower incisors. The table of the incisors is oval transeversly at age of 5 years and it becomes rounded at 10 years, triangular at 15-17 years and finally nearly oval and constricted from middle at age of 20 years.

The canine teeth were well developed in male and rudimentary in female, its length is 4-5 cm in horse and 3-4 cm in donkey. The root was strongly curved caudally and the crown was short and cone shape. The canines were more close to the corner incisor (3 I) than to the (2P) while the upper canine being located at the junction of incisive and maxilla.

The upper cheek teeth in the donkey and horse are six in number (2P, 3P, 4P, 1M, 2M, 3M). In 4 cases of donkeys and one case of horses a rudimentary upper 1P (Wolf tooth) which is short, narrow, smooth and lighter in colour was found. This is normally present in young aged animals as a milk tooth up to 5 years, where it fall down. The wolf tooth persisted up to 8 years, (Fig. 1).

In the present investigation, the length of the upper cheek teeth is 5.5-7 cm in male donkey and 3.5-5.5 cm in female, while in the horse the length of the teeth is 8-10 cm in male and 6-7.5 cm in female. It was clear from this investigation that the longest tooth was 3P (7 cm) in donkey and 4P (10 cm) in horse.

At the age of 5-6 years in donkeys and horses we found that the cheek teeth have long crown (Hypodont type), the part of the crown embeded inthe alveoli is known as the reserve crown. In the age of 10-20 years, rapid elongation of the cheek teeth was observed and the reserve crown appeared, to compensate the excessive wear of the teeth (Fig. 2).

In this study it was found that the vestibular surface of the upper cheek teeth in the donkey has two longitudinal ridges surrounded by three grooves. While in the horse the vestibular surface has three longitudinal ridges which are seperated by two grooves. These ridges and grooves are prominent in 5 years old animals. It became shallow in old animals of the same

## TEETH, SURGICAL AFFECTIONS

species (15-20 years). On the opposite side the lingual surface of the upper cheek teeth has centrally placed a longitudinal ridge which is prominent in horses more than in donkeys and is accompanied on either side by two longitudinal grooves. It was found that the upper cheek tooth in donkeys was narrower than that of horses. The table of the upper cheek teeth is square except in 2P which is triangular in donkeys and horses. The 3M is also triangular in donkeys. Branches of root are not clear. The table of the upper cheek teeth is wide rostro-caudally and medio-laterally in donkeys and horses of 5 years old, while in advanced ages the table becomes narrower in two directions where it is more narrower in donkeys than in horses.

The roots of the upper cheek teeth are three in every tooth. They are more thicker in horses than in donkeys. The rostral root is the longest, the medial is the widest and the lateral one is the shortest, (Fig. 3 & 4).

In the present study it was found that the lateral roots of 4P and all roots of 1M are completely embedded in the inferior maxillary sinus in 5 years old donkeys. On the other hand in the horse at age 5 years the roots of the 4P and 1M of the upper cheek teeth are embedded in the inferior maxillary sinus. While the roots of 2M and 3M are embedded in the superior maxillary sinus in donkeys and horses. In advanced ages (10-20 years) the maxillary sinuses are increased in size, enlarged and extended to end at the level of rostral root of 4P in donkeys and horses, so that the roots of 4P, 1M and 2M are embedded in the inferior maxillary sinus. It was also found that, with increasing age, the roots of these teeth are separated from the maxillary sinuses by a thin plate of bone.

In the present work it was found that the lower cheek teeth are slightly longer than the upper cheek ones in donkeys and horses (6-7.5 cm) in male donkey, (3.5-5.5 cm) in female donkey and (8.5-10.5 cm) in male horse and (6.5-8 cm) in female horse. Wolf teeth in the lower jaw of examined donkeys and horses were not observed in present work.

The vestibular surface of the lower cheek teeth in donkeys and horses has a deep central groove and the lingual surface is marked by several small grooves. The table of the lower cheek teeth is rectangular in outline except 2P and 3M which have a triangular table. The table is narrow in rostro-caudal and medio-lateral directions in donkeys more than in horses. The roots of the lower cheek teeth in donkeys and horses at age of 5 years are very small, because the most embedded part of the teeth at this stage is a part of the crown known as reserved crown. It was also found that with increasing the age (over 5 years) the reserve crown becomes smaller to compensate for the wear.

It was noticed that in donkeys the embedded part of 3P and in horses the embedded part of 3P and 4P reach their maximum development at the age of 5 years, so that it produce bulge on the ventral border of the mandible. This bulged part disappear at 10 years old. The roots of 2P are directed ventrally in donkeys and rostrally in horses, while 3P in horse is directed vertically and in donkeys it is directed caudally, but 3P and 3M of the lower are directed caudally in both horses and donkeys. The apical foramen and pulp cavity are large in donkeys and horses (5 years), but in advanced age (10 years) they become smaller and in old age (20 years) they become visually obliterated in both horse and donkey.

Surgical affections of the teeth recorded from donkeys and horses in the present work are dental caris which mainly affect the upper cheek teeth on both sides, specially 2P, 3P, 1M and 2M. This affection is characterized by black discolouration of the centrally induced pathological hole at the crown (Fig. 5). In advanced cases it may reach the pulp cavity of the tooth and becomes filled with decomposed food materials and finally it causes sever pain during mastication.

The second common surgical affection is sharp enamel points which mainly affect donkeys and horses at any age more than 5 years in both sexes. The affection is localized at the lateral border of the upper cheek teeth and at the lingual border of the lower cheek ones. The sharpness of the teeth ranged from moderate to severe degree and causes different injuries of the mucous membrane of the mouth cavity. It was found that the sharp edges of the upper premolars and molars are more progressive than the lower ones, (Fig. 5).

The rostral projection of the 2P of the upper cheek tooth was covering the rostral half of the 2P of the lower jaw in horses and donkeys (Fig. 6). Some cases were accompanied by projection of the last molar (3M) of the lower cheek teeth caudal to the last upper molar.

Dental tartar (calculus) commonly affects the vestibular surface of the upper 2P, the lower incisors, the lingual surface as well as the labial surface on both upper and lower canines in donkeys and horses (Fig. 7). Biochemical analysis of dental calculi shows that it is composed of calcium phosphates, calcium carbonates and traces of chloride, but no magnesium salts could be detected (Table 1).

Diastasis dentium is more common at lower cheek teeth in donkeys and horses with variable width (Fig. 8). In only one case it was present at upper cheek teeth, where it was associated with polydentia situated at lingual surface of the upper jaw (Fig. 9).

Fracture of the teeth was diagnosed in 2 cases, one of them presented fracture of the crown without opening the pulp cavity in a central incisor of the upper jaw of a donkey, (Fig. 10). This case from its history was caused by accidental severe trauma. Another form of fissures was observed affecting the whole premolars and molars of the lower jaw, where only the enamel layer in donkeys is seen to be suffering (Fig. 11).

Stepformed table mouth had been recorded in the upper and lower cheek teeth in horses (Fig. 12), but it was found more severe in upper cheek teeth more than lower cheek ones in donkeys, (Fig. 5).

Polydentia was recorded in one donkey where the extra tooth was situated to one side (lingual) of the normal row of the upper cheek teeth. It was associated with diastasis dentium and alveolar periostitis, (Fig. 9).

Another case in a horse was affected with several teeth affections mainly, parrot mouth (Brachynathism), elongation of the first molar (1M) of the upper jaw (Exuberantia dentis) and lastly oligodontia in lower cheek teeth, (Fig. 13, 14).

## DISCUSSION

In the present investigation it was observed that the incisor teeth increase slightly in length from lateral to medial side in donkeys and horses, a finding similar to that mentioned by NICKEL, *et al.* (1973) in horses.

BUNGER and HERTSCH (1981) mentioned that the cups are 12-17 mm. deep in upper incisors and 6 mm. in lower incisors in horses, a result which is nearly similar to the present results in donkeys and horses.

In the present study in donkeys and horses we found the 1<sup>st</sup> upper premolar tooth (wolf tooth) in 4 cases of donkeys and one case of horse, the same results were discussed in horse

## TEETH, SURGICAL AFFECTIONS

by JOHNA, et al. (1955) and NICKEL, et al. (1973). Its persistence does sometimes cause inconvenience and annoyance to the animal necessitating its removal, usually by simple operation. On the other hand the wolf tooth is not present in the lower jaw in donkeys and horses, as recorded by JOHNA, et al. (1955), NICKEL, et al. (1973) and CLAIR (1975).

In donkeys and horses at age of 5-6 years we found that the cheek teeth have long crown (Hypodont type), the part of crown embedded in the alveoli known as reserve crown and the roots are not distinct, the same results have been obtained by JOHNA, et al. (1955) in horses.

In young donkeys (5 years) we found that the lateral root of 4P and roots of 1M are embedded in the inferior maxillary sinus. However JOHNA, et al. (1955) mentioned that in the horses the rest of the last four cheek teeth completely filled the maxillary sinus. Moreover in donkeys and horses (5 years) the roots of the 2M and 3M are embedded in the inferior maxillary sinus. It was found also that in donkeys and horses with increasing age (10-20 years) the maxillary sinus was enlarged and extended to end at the level of the rostral root of 4P which is similar to that mentioned in horses by JOHNA, et al. (1955).

In the same time with increasing age of the animal, the roots of the teeth are separated from maxillary sinuses by a thin plate of bone. Accordingly if dental caries, pulpitis and alveolar periostitis develops in these teeth, this barrier is broken down and the mucous membrane of the sinus becomes involved, and empyema develops. On the other hand the direction of the lower cheek teeth give an idea for the removal of the affected teeth in donkeys and horses.

From the present investigation it was found that the common surgical affections of the teeth in donkeys and horses are dental caries at upper cheek teeth more than the lower ones. This may be due to the presence of enamel folds on the masticatory surface of the tooth which act as predisposing factor, as mentioned by O'CONNOR (1980). On the other hand sharp enamel points which are widely prevalent in equines, localized at outer border of the upper cheek teeth and the inner border of the lower cheek ones may be due to more wear occurring at the contact masticatory surface of the teeth, where it is a well known fact that the width of the table of the upper cheek teeth is more than that of the lower one. This is in agreement with the results obtained by (MISK & HIFNY, 1982).

Projection of the cheek teeth are mainly restricted to the rostral half of the upper 2P (Fig. 6) and sometimes accompanied with the projection of the caudal part of the last molar of the lower jaw. This projection is usually acquired and may be a sequellae to a slight degree of parrot mouth of the same animal, MISK and HIFNY (1982) described the same projection in donkeys in upper Egypt.

Dental calculi were found at the vestibular surface of the upper 2P, labial surface of the lower incisors and were present at the whole circumference of the upper and lower canines in the form of a ring. This is in agreement with the results mentioned by OEHME & PRIER (1974).

Biochemical analysis revealed that dental calculi are composed of calcium carbonates, calcium phosphates and traces of chlorides as well as organic salts in donkeys and horses. On the contrary MISK and HIFNY (1982) stated that Magnesium salts were present in the composition of the dental tartar in donkeys. This may be attributed to variation in the constituents of food offered to the animals.

## AMIN and KASSEM

In the present study diastasis dentium was observed in the lower jaw in cases of oligodontia and in normal number teeth, where they were not accompanied by alveolar periostitis, while in the case of polydentia which was observed in the upper jaw was complicated by alveolar periostitis. This may be attributed to inability of the animal to get rid of the food materials embedded in the space by the tongue, which it is easy to do in the space of the lower jaw. In addition the presence of an extra tooth on the inner aspect of the normal jaw, produces severe pain during mastication where the animal is obliged not to masticate on the side where the extra tooth is present. As a result the remiment of the food materials persist for a longer time in the space, leading to alveolar periostitis of both neighbouring teeth.

Splintered fracture which was found in the central incisors of the upper jaw, affect partly the wall of the tooth and does not reach the pulp cavity. This fracture resulted from slight deviation of the left central incisor tooth towards the other neighbouring right central one. Another form of fissured fracture was found at the crown of the lower cheek teeth, may be attributed to variation inthe constituents of the teeth of the lower jaw.

Stepformed table mouth in the upper jaw as well as the lower jaw in donkeys and horses, may be acquired due to variation in the constituents of the teeth, absence or shortening of the opposite tooth (O'CONNOR, 1980).

Polydentia must be removed as early as possible, because its presistance causes many complications specially when it is accompanied by diastasis dentium. The common complications are alveolar periostitis, injuries of the oral mucous membrane and difficulty in mastication.

Several congenital affections were found in horses such as parrot mouth, oligodontia leading to other dental affections, elongation of the cheek tooth and projection of the 1st premolar of the upper jaw.

## REFERENCES

- Bunger, I. and Hertsch, B. (1981): Dentition of the donkey. Morphology and Radiology. Anatomia, Histologia Embryologia 10(1) 61-86.
- Clair, L.E.S. (1975): Equine digestive system, In sission and Grossmans. the anatomy of domestic animals Rev. by Getty 5th Ed. W.B. saunders. Company, Philadelphia, London, Toronto.
- Frank, E.R. (1964): Veterinary surgery, 7th Ed. Burgess publishing company, USA.
- Habel, R.S. (1965): Applied anatomy. A labarotomy guide for veterinary students. 5th Ed. Ithaca, New York. published by the authors.
- Jesse F. Bone (1979): Animal anatomy and pshiology. Reston publishing company.
- Johna, Tylor, Oliver and Boyd (1955): Regional and applied anatomy of the domestic animals. part one (Head & Neck). London. 39 A Welbeck street, W.I.
- Misk, N.A. and Hifny, A. (1982): Surgical affections of the teeth in donkeys of south Egypt. 14 Congress proceedings European society of veterinary surgery. Istanbul - Turkey 7-9 september, page 165-187.
- Nickel, Schummer and Seiferle (1973): The viscera of the domestic animals. Verlag paul parey, Berlin, Hambur.
- O'Connor, J.J. (1980): Dollar's veterinary surgery. 4th Ed. Bailliere, tindall, London.
- Oehme, F.W. and Prier, J.E. (1976): Large animal surgery. 4th Ed. The Williams and Wilkines company, Baltimore.

## TEETH, SURGICAL AFFECTIONS

Table (1)

Shows the amount of mineral salts present in the constituents of dental calculi in horses and donkeys

Ser.	Salt	Amount
1	Calcium phosphates	++++
2	Calcium carbonates	+++
3	Chlorides	+
4	Magnesium salts	-

## Legends to Illustrations

- Fig. (1):** Skull of 5 years old donkey showing the length of the teeth and size of the paranasal sinuses, as well as the wolf tooth in the upper jaw.
- Fig. (2):** Skull of 15-20 years old donkey that showing the length of the teeth and the size of the paranasal sinuses.
- Fig. (3):** Skull of the 10 years old donkey showing the length of teeth and the size of the paranasal sinuses.
- Fig. (4):** Skull of 10 years old horse showing the length of the teeth and the size of the paranasal sinuses.
- Fig. (5):** Caris dentium of the upper cheek teeth, stepformed table mouth and sharpe enamel points in a donkey.
- Fig. (6):** Exuberantia dentis of the 1M of the upper cheek teeth (elongation) as well as projection of 2P in the upper jaw in a horse.
- Fig. (7):** Dental calculus at vestibular surface of the lower incisors and canines in the form of (ring).
- Fig. (8):** Diastasis dentium between 1M and 2M of the lower cheek teeth (right side).
- Fig. (9):** Polydentia of the left upper cheek teeth where extra tooth is present in the inner aspect of the cheek teeth accompanied with diastasis dentium in a donkey.
- Fig. (10):** Splintered fracture of the upper central incisor (right one) with shortening of the left one as well as diastasis dentium.
- Fig. (11):** Fissures at enamel layer of the crown of the lower cheek teeth in a donkey.
- Fig. (12):** Stepformed table mouth of the upper cheek teeth in a horse (Wave mouth - Wave bite).
- Fig. (13):** Slight form of inferior Brachygnathism, note the overlapping of the upper incisors.
- Fig. (14):** Oligodontia in the lower cheek teeth at the right and the left side, with diastasis dentium.



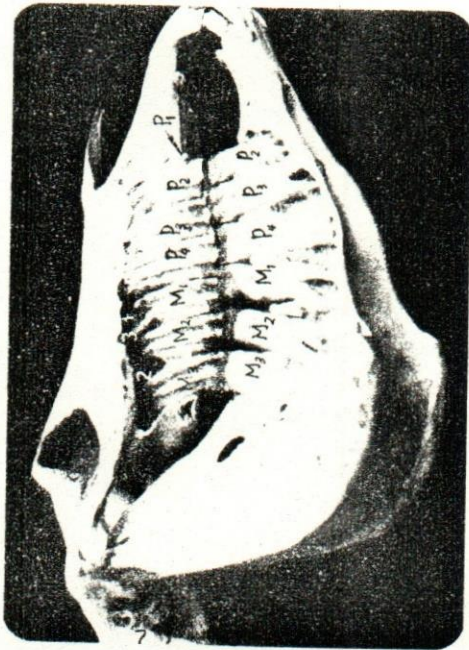


Fig. (1)  
Skull of five years old donkey showing the length of the teeth and the size of the paranasal sinuses, as well as the wolf tooth in the upper jaw.

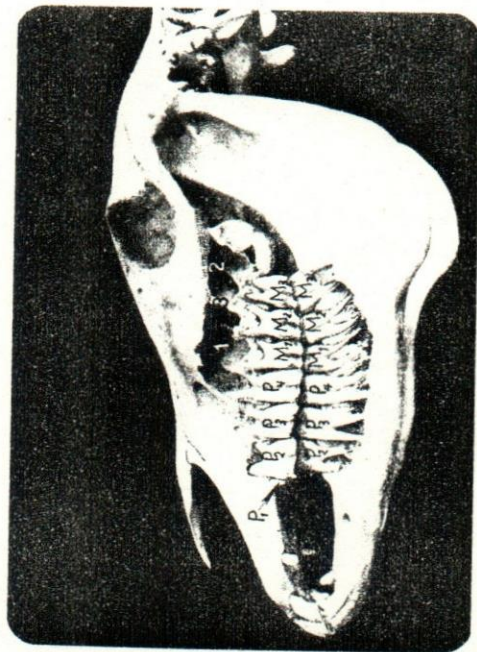


Fig. (2)  
Skull of 15-20 years old donkey that showing the length of the teeth and the size of the paranasal sinuses.

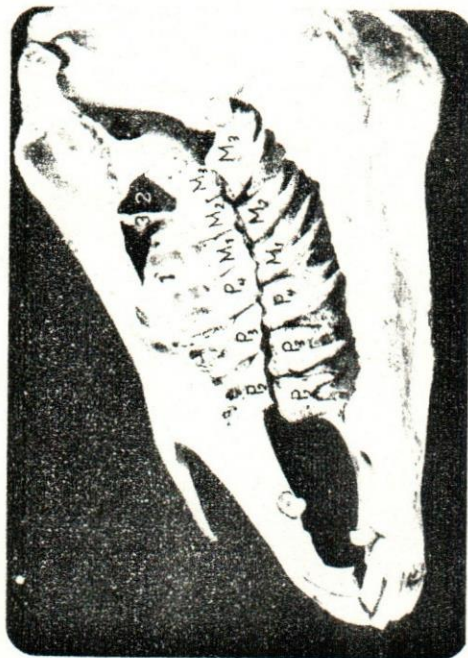

Fig. (3)  
Skull of ten years old donkey showing the length of the teeth and the size of the paranasal sinuses.

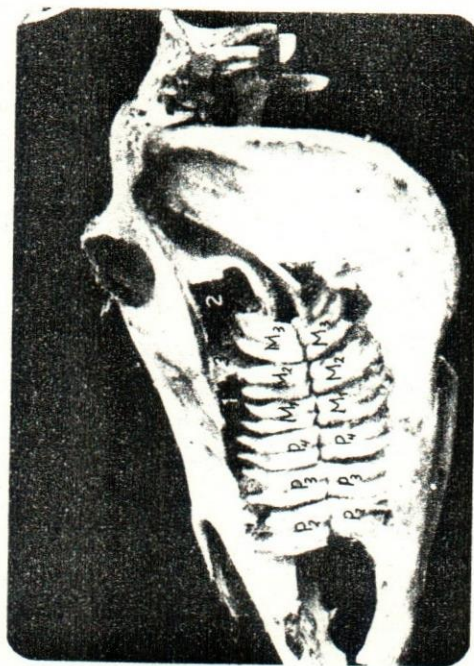


Fig. (4)  
Skull of ten years old horse showing the length of the teeth and the size of the paranasal sinuses.



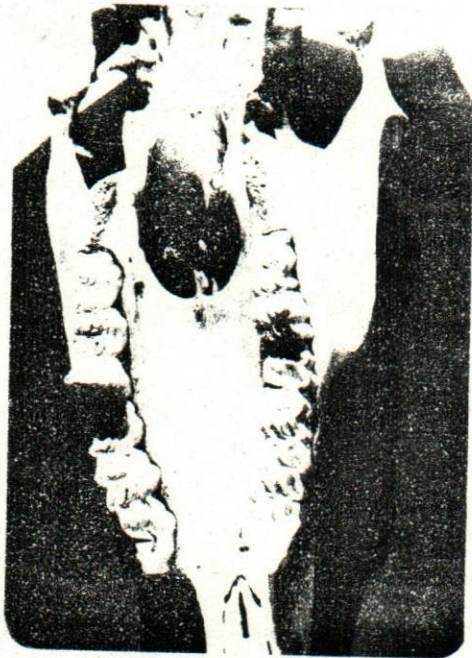


Fig. (5)  
Caris dentium of the upper cheek teeth and  
stepformed table mouth in a donkey.

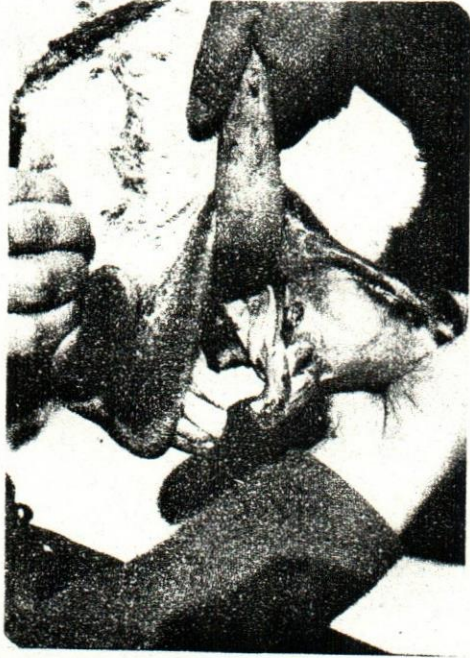

Fig. (7)  
Dental calculus at vestibular surface of the  
lower incisors and canines (Ring) in a donkey.

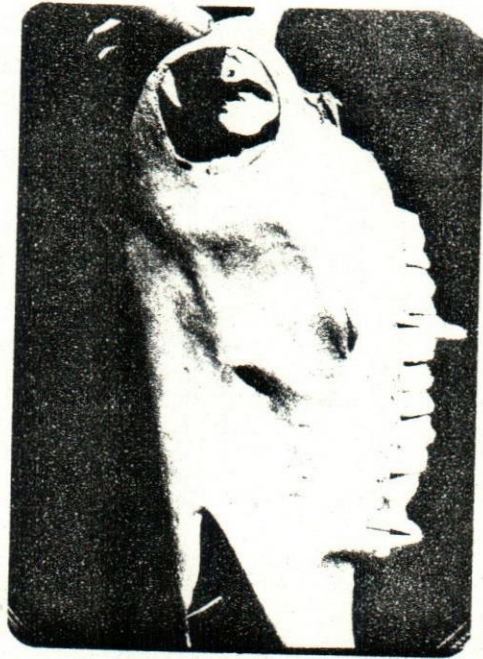

Fig. (6)  
Exuberantia dentis - elongation of 1M in upper cheek teeth in a horse.  
- and Projection of the 2P upper cheek tooth.

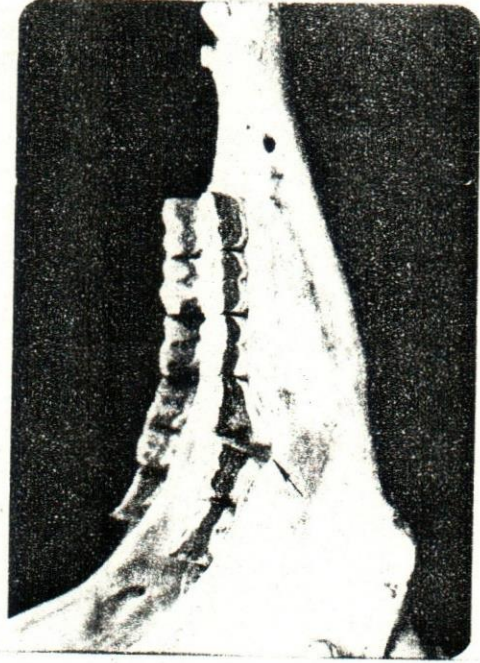


Fig. (8)  
Diastasis dentium between 1M and 2M of the  
lower cheek teeth (R.side) in a donkey.






Fig. (9)

Polydentia of the left upper cheek teeth where extra tooth present at the inner aspect of the cheek teeth with diastasis dentium in a donkey.

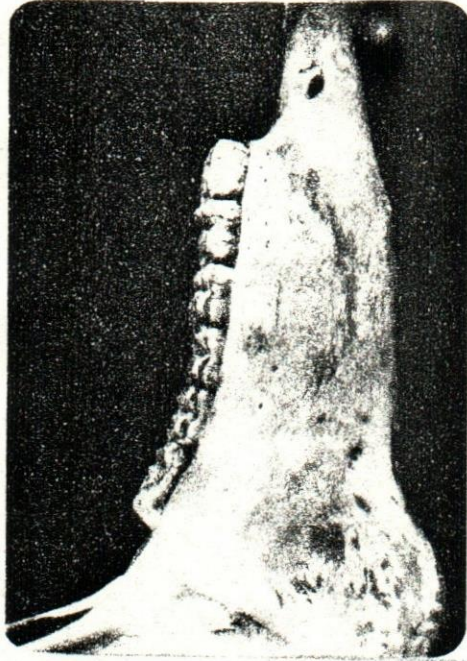


Fig. (11)

Fissures at enamel layer of the crown of the lower cheek teeth in a donkey.




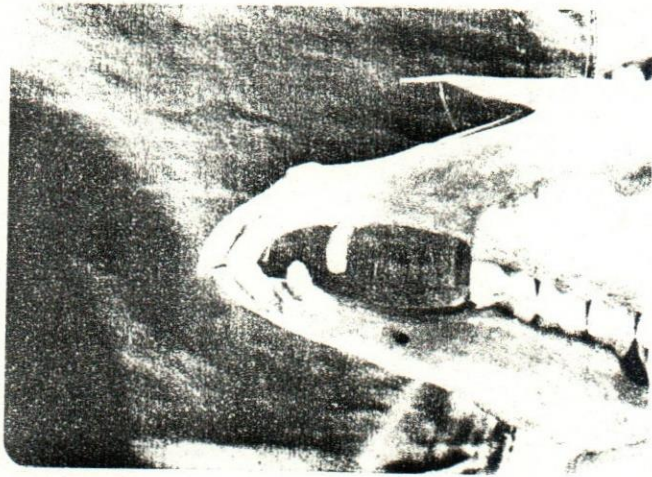
Fig. (10): Splintered fracture of the upper central incisor (Right) with shortening of the left one.

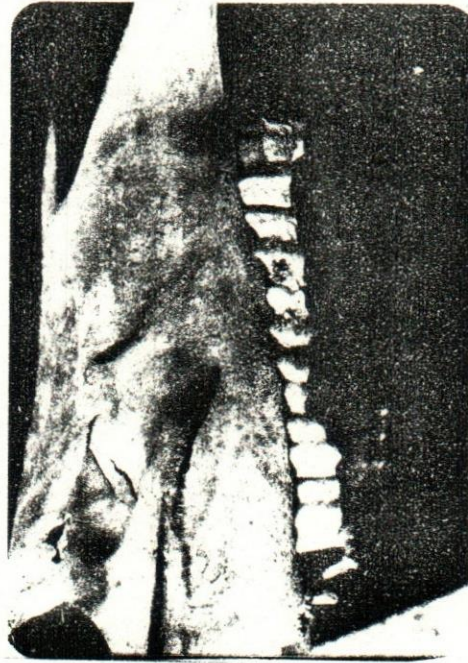

Fig. (12)

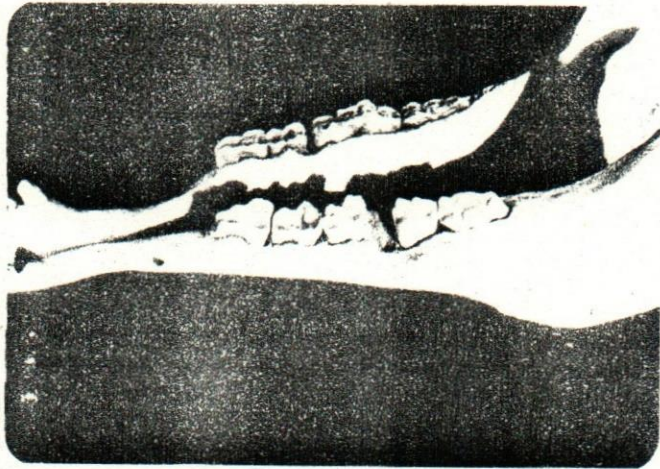
Stepped table mouth of the upper cheek teeth in a horse (Wave mouth - Wave bite).





*Fig. (13)*

*Brachygnathism inferior - note overlapping upper incisors in a horse.*



*Fig. (14)*

*Oligodontia in the lower cheek teeth at right and left sides with diastasis dentium.*