

Silymarin Protects the Histological Pattern of Rat Liver Against Radiation Toxicity

Samir A. Nassar^{*}, Omar I. Ghonemy^{**}, Sabry S. El-Serafy^{**},
Hamid M. Roushdy^{***} and Amr M. Abd-El-Hady^{*}

^{*} Dept. of Zoology, Faculty of Science, Zagazig University

^{**} Dept. of Zoology, Faculty of Science, Benha University

^{***} National Center for Radiation Research and Technology (NCRRT), Egypt

Abstract

Background: Silymarin, a flavonoid extract obtained from seeds of *silybum marianum*, is commonly used in the treatment of liver diseases of varying origins. It is of special medical importance for Egyptians due to the large incidence of liver diseases in Egypt. It is a complex of silybin, silydianin and silychristin. It is capable of protecting liver cells directly by stabilizing the membrane structures, including endoplasmic reticulum, by an effective decrease in membrane permeability and a change in their lipid content. The present study aimed to investigate, evaluate and confirm the radioprotective role of silymarin against liver disorder from the histological point of view.

Material and Methods: Forty, adult male albino rats have been used for this study and classified equally into 4 groups; normal rats, γ -irradiated (5Gy) rats, silymarin administrated and γ -irradiated rats, control rats (treated with silymarin only). Silymarin was administered by oral gavage, at a dose of 70mg/kg, one hour before irradiation. Liver sections were made from each group and stained with H&E.

Results: The histological examination of liver sections of γ -irradiated rats resulted in many pathological criteria such as hydropic degeneration, cytoplasmic vacuolation, pyknosis, karyolysis, nucleoli disappearance, necrosis, leucocytic infiltration and liver cell degeneration. Silymarin treatment prior to irradiation succeeded to minimize the deleterious effects of γ -irradiation in the hepatic tissue and support the liver to initiate a phase of recovery, regeneration and tissue healing.

Conclusion: These results suggest that the radioprotective role of silymarin for the hepatic tissue was confirmed. It helps the liver tissue to overcome the degenerative changes of γ -irradiation where the liver tissue gradually restored its normal histological pattern.

Keywords: Liver – rat – gamma irradiation – silymarin

Introduction

The radiation-induced hepatotoxicity has been recorded by several investigators. Adeib *et al.* (1988) recorded several changes following 500 rads whole body gamma irradiation of rats. These changes included multiple areas of disintegration in the membranes of the hepatic cells, congestion and dilatation of hepatic sinusoids. The central veins showed disruption of their intima. The branches of hepatic arteries and portal veins showed rupture of their intima and thickening of the tunica media associated with narrowing of their lumina. Whole body gamma irradiation of mice with fractionated doses at 6 Gy (twice a week over two weeks)

induced liver damage (EL-Sayed, 1995). Kafafy and Ashry (2001) reported that the liver of γ -irradiated rats revealed disturbed hepatic strands with degenerated hepatocytes and dilated blood sinusoids. Vacuolar to hydropic degeneration and many necrotic cells with pyknotic and even karyolytic nuclei were also seen. Also, whole-body gamma irradiation of rats resulted in lobular disarray in rat liver, loss of normal architecture of hepatic strands, cell vacuolation, degeneration and lymphocytic infiltration (Said *et al.*, 2002). There has been extensive research on radioprotective compounds during the past 50 years because of the relevance of these

Pharmaceutical action: It is highly valued for treatment of various skin diseases (Eczema, acne, impetigo, child's scabs, psoriasis) rheumatism, problems with breathing organs (normal cough and whooping cough), and for stronger urinating.

Remark: Mixed in equal parts with red clover this herb has better action in controlling skin diseases, and with rabbit orrache, for controlling whooping cough.

Preparing of tea: One soup spoon of dried and finely powdered herb over pour with a cup of boiling water, cover, and leave for twenty minutes. Drink two cups per day, sweetened with honey or with raspberry syrup.

SALLOW (TEUCRIUM MONTANUM)



Our highlanders are very much in love with this little herb, having an almost unlimited confidence in it. According to folk belief, the herb sallow told to the harvester: "Pick me, but don't destroy my roots, and I will rise the dead"

The pharmaceutical part of the herb: the young shoots with leaves are harvested, when in blossom, from June to July.

Habitat: The herb is to be found in sunny, bare stony places and pastures.

Pharmaceutical action: before everything this is a pharmaceutical for digestion organs (especially if there is little stomach acid), and also infected and rotten contents of digestive organs. Also, the herb is excellent for healing lungs (tuberculosis).

Remark: This herb has very similar action to the herb TEUCRIUM CHAMAEDRYS.

Preparing of tea: one soup spoon full of dried and finely powdered herb over pour with a cup of boiling water, cover, and let stay for 15 minutes. Drink three cups per day, unsweetened, before meals.

JUNIPER BERRY (JUNIPERUS COMMUNIS)



In places where this herb is to be found, its reputation is great.

Pharmaceutical parts of the herb: Ripe berries are harvested in the fall, dried in a cool and draughty place, with frequent overturning.

Habitat: The herb is to be found in higher, mountain places, in stony country.

Pharmaceutical substances: Etherical oils, up to 2.5%, 33% of invert sugar, 10% of resins, amara, juniperin, tannin, wax, gums, flavonoids, organic acids, etc.

Pharmaceutical action: Pharmaceutical action is mainly due to the ethereal oils, which oils have irritating/exciting and antibacterial action. The herb is also used as a diuretic (for better urinating), against common colds (in the form of a syrup, and inhalation), for a better metabolism, for indigestion problems, especially if there is not enough acid in the stomach. From without it is used (as an oil, or brandy) to control rheumatism and arthritis.

Remark: The juniper berry must be applied with some care. Do not use it longer than five weeks, because kidney inflammation may occur. The juniper berry is not to be recommended for pregnant women, because contractions of the uterus may occur.

Preparing of tea: one teaspoon of crushed berries over pour with a cup of boiling water, cover, and let stay for thirty minutes. Drink three cups per day.

Preparation of tincture: One part of juniper berries over pour with four parts of strong brandy, leave for six weeks, with frequent shaking. Filter over gauze. Drink three times per day one teaspoon, or use for massaging

compounds in military, clinical and industrial applications. Radiation protection might offer a tactical advantage on the battle field in the event of nuclear warfare. Radioprotectors could reduce the cancer risk to populations exposed to radiation directly or indirectly through industrial and military applications. They are required to reduce normal tissue injury during radiotherapy of cancer. Naturally occurring antioxidant compounds such as flavonoids and polyphenols offer protection against the deleterious effects of ionizing radiation because of their ability to scavenge free radicals (Uma *et al.*, 2000 and Nishimura *et al.*, 2003).

Silymarin is a mixture of polyphenolic flavonoids isolated from milk thistle (*Silybum marianum*). Several experimental studies have been done to evaluate whether silymarin can influence the course of radiation toxicity. Luper (1998) recorded a possible efficacy for the milk thistle (*Silybum marianum*) to play a main role in the treatment of toxic hepatitis, fatty liver, cirrhosis, viral hepatitis, ischemic injury, and radiation toxicity via its antioxidative, anti-lipidperoxidative, antifibrotic, anti-inflammatory, immunomodulating and liver regeneration effects. Silymarin administration has been shown an antifibrotic effect in human studies, whereas animal experiments suggested that this flavolignanes mixture may be beneficial in patients who have not developed cirrhosis yet (Stickel *et al.*, 2002). The radiation induced histological changes in rat liver cells were ameliorated by Silymarin after whole body γ -irradiation in a time and dose dependant manner (Abdel-Hamid, 2003). The administration of the flavonoid derivative troxerutin (175 mg/kg body weight) to tumor-bearing mice by intraperitoneal injection one hour prior to 4 Gy whole-body γ -irradiation significantly decreased the radiation-induced peroxidation of lipids in tissues such as liver and spleen, but there was no reduction of lipid peroxidation in tumor (Maurya *et al.*, 2004). Another group of authors examined the effects of antioxidants and other nutrients used during chemotherapy and/or radiation therapy. Many of their studies reported that antioxidants and nutrients produced higher response and increased survival rates when

administered during chemotherapy and/or radiotherapy (Simone *et al.*, 2007).

The present study was undertaken to scientifically investigate, assess and prove the radio protective effect of *Silymarin* against liver disorder from the histological point of view.

Material and Methods:

Animals:

Forty adult male albino rats weighing 150- 200g, were kept under standard conditions and were allowed free access to a standard diet and clean drinking water.

Irradiation:

Whole-body gamma-irradiation of animals, at an acute single dose level of 5 Gy and a dose rate of 1.3888 rad s⁻¹, was performed using Gamma cell-40 achieved by the National Center for Radiation Research and Technology (NCRRT), Atomic Energy Authority, Cairo.

Silymarin drug:

Silymarin produced by South-Egypt Drug Industries Company (SEDICO) was purchased. The experimental dose 70 mg / kg was dissolved in distilled water.

Experimental design:

Animals were categorized into the following groups each of 10 rats:

1. *Normal group:* Comprising 10 normal rats.
2. *Irradiated group:* Rats received a single dose of whole-body gamma rays (5 Gy).
3. *Silymarin treated and irradiated group:* Animals received a single oral dose (70 mg kg⁻¹) one hour before irradiation at 5 Gy.
4. *Control group:* Rats were administrated a single oral dose (70mg/ kg)of silymarin only at the same time with those of the previous group.

Rats were sacrificed, dissected and examined 1, 3, 5, 7 and 14 days post-irradiation or silymarin treatment. Normal and control rats were also examined in parallel at the same intervals. Pieces of livers from the normal, control and treated animals were removed, fixed in 10%

neutral formalin, dehydrated, cleared and finally embedded in paraffin wax. Liver sections of 3 μ thickness were cut and stained with haematoxylin and eosin according to the method of Bancroft and Gamble (2002) and examined under the light microscope. Two liver sections from each interval were examined and photographed seeking for any additional histopathological criteria which could be recorded.

Results

In comparison with the liver of normal animals (Figs. 1-2), the whole body gamma-irradiation, at the dose level 5 Gy resulted in many histopathological changes in the liver tissue. On the first day post-irradiation the liver tissue showed marked loss of uniformity and regularity of the liver lobules as a result of the hydropic degeneration. The hepatocytes appeared damaged with aggregation of their nuclei in some sort of hemorrhage infiltrated within liver sinusoids. Nuclei of the hepatocytes showed clear symptoms of pyknosis progressed to coagulative necrosis (Fig.3). The histological examination of another field of liver sections at the same interval post-irradiation revealed dilated blood vessels and bile ducts. The latter appeared surrounded with damaged and inflammatory leucocytes. The nuclei exhibited low stainability followed by karyolysis and disappearance of nucleoli (Fig.4). On day 3 post-irradiation, the hepatocytes showed mild hydropic degeneration with vacuolated cytoplasm. Hepatic cells appeared having pyknotic or disintegrated or intact nuclei. Dilated blood sinusoids were still recognized and appeared congested with haemorrhagic inclusions (Fig.5). Also karyolysed nuclei and leucocytic infiltration of inflammatory cells around blood vessels were obvious. Marked signs of fibrosis could be recorded around the damaged cells and central veins (Fig. 6). On day 5 post-irradiation degenerated hepatocytes with pyknotic and densely stained nuclei and haematomas or masses of blood were seen in the hepatic tissue. K pffer cells appeared elongated and slightly hypertrophied along the sides of the blood sinusoids (Fig.7). Some apoptotic cells appeared in the hepatic tissue indicating advanced degree of

degeneration. Some nuclei appeared with karyolysis. Widened extracellular spaces and blood sinusoids could be demonstrated. However some liver cells appeared with intact cell membranes and healthy nuclei and nucleoli (Fig.8). On day 7 post-irradiation haemorrhage and damaged liver cells were still evident inside the hepatic parenchyma. Bile ductules appeared with abnormal nuclei and surrounded with leucocytic inflammatory cells (Fig.9). However, the hepatic tissue showed some sort of regeneration where the nuclei of some cells restored their normal appearance and the cell membranes were intact. Other hepatocytes manifested a process of degeneration which proceeded to necrotic areas (Fig.10). After 14 days post-irradiation the parenchymal cells of liver tissue showed good signs of recovery where regeneration could be detected by mitotic activities within most of the cells. Other hepatocytes still having hydropic degeneration with karyopyknotic nuclei, thickened cell membranes and faintly stained cytoplasm. Marked inhibition of the leucocytic infiltration was evident (Fig. 11). At the same time, dilatation of blood vessels and hypertrophied K pffer cells were still prominent (Fig.12). Also, the regenerating cells in the examined liver section at this interval after irradiation were characterized by deeply-stained nuclei and richly-stained cytoplasmic granules.

Oral administration of silymarin (70 mg / kg) to rats prior to irradiation improves the histological pattern of the liver tissue. On the first day after silymarin administration and irradiation, some hepatocytes showed hydropic degeneration with vacuolated cytoplasm but at a degree much lesser than that of the irradiated non-treated rats. Haematomas or masses of blood were detected in the hepatic tissue. Blood vessels and sinusoids appeared dilated and congested with blood and damaged cells (Fig.13). In another field, the cells in the hepatic parenchyma appeared with intact walls and a number of these cells being binucleated. Their nuclei to some extent resembling those of the normal cells in both size and shape and the nucleoli were prominent and deeply stained (Fig.14). On the third day after silymarin administration and irradiation the blood vessels and

sinusoids inside the hepatic parenchyma were still dilated, but the K pffer cells appeared elongated with intact walls and increased in number along the walls of the blood sinusoids.

In addition , few number of vacuolated hepatocytes could be observed inside the liver tissue together with inflammatory leucocytic cells limited to the areas around the blood vessels (Fig. 15). In another section of liver tissue (Fig. 16), the hepatocyte membranes of hepatocytes appeared intact in most cells and they restored their cytoplasmic granulation. View number of the nuclei were faintly stained. The hepatic strands taking their normal pattern radiating from the central vein. The latter appeared nearly with normal lumen. The hepatic cells displayed distinct signs of recovery and tissue repair as compared with the tissues of rats which were subjected to irradiation only. On day 5 after silymarin administration and irradiation the hepatocytes showed vacuolated cytoplasm and enlarged nuclei. Few areas of necrosis were seen. The cell membranes between the adjacent cells appeared thickened in an abnormal shape and the nuclei and nucleoli were prominent and deeply-stained. The leucocytic infiltration of inflammatory cells was absent (Fig. 17). On day 7 after silymarin administration and irradiation, the nuclei of the hepatic cells restored their normal size and appearance where they were less stained as compared to those of the previous interval. Moreover, a considerable number of binucleated hepatocytes was seen to suggest the effort

of recovery or regeneration due to silymarin treatment. However, damaged cells with pyknotic nuclei were still present in the hepatic parenchyma (Fig. 18). On day 14 after silymarin administration and irradiation, the hepatocytes showed progressive signs of recovery and tissue healing. The majority of cell nuclei restored their normal pattern of chromatin distribution in the nucleoplasm with conspicuous nucleoli. The cytoplasmic granulation of most hepatic cells was also restored and the cells appeared with marked intact cell membranes. The hepatic strands arranged in a regular manner radiating from the central vein. Binucleated hepatic cells were more frequent in their incidence indicating a good proliferating activity (Fig. 19).

Histopathological examination of liver sections of control group (treated with silymarin only) didn't show any pathological changes. They showed normal cellular architecture with distinct hepatic cells and sinusoidal spaces (Fig. 20). The hepatic cell nuclei appeared normal without changes in their shape and size. The cell membranes were intact and binucleated cells were highly frequent inside the hepatic parenchyma

Explanation of Figures

Plates I, II, III, IV and V

Liver sections of normal, treated and control rats stained with Hx&E . original magnification of x1000 except fig.1 (x200).

PLATE I

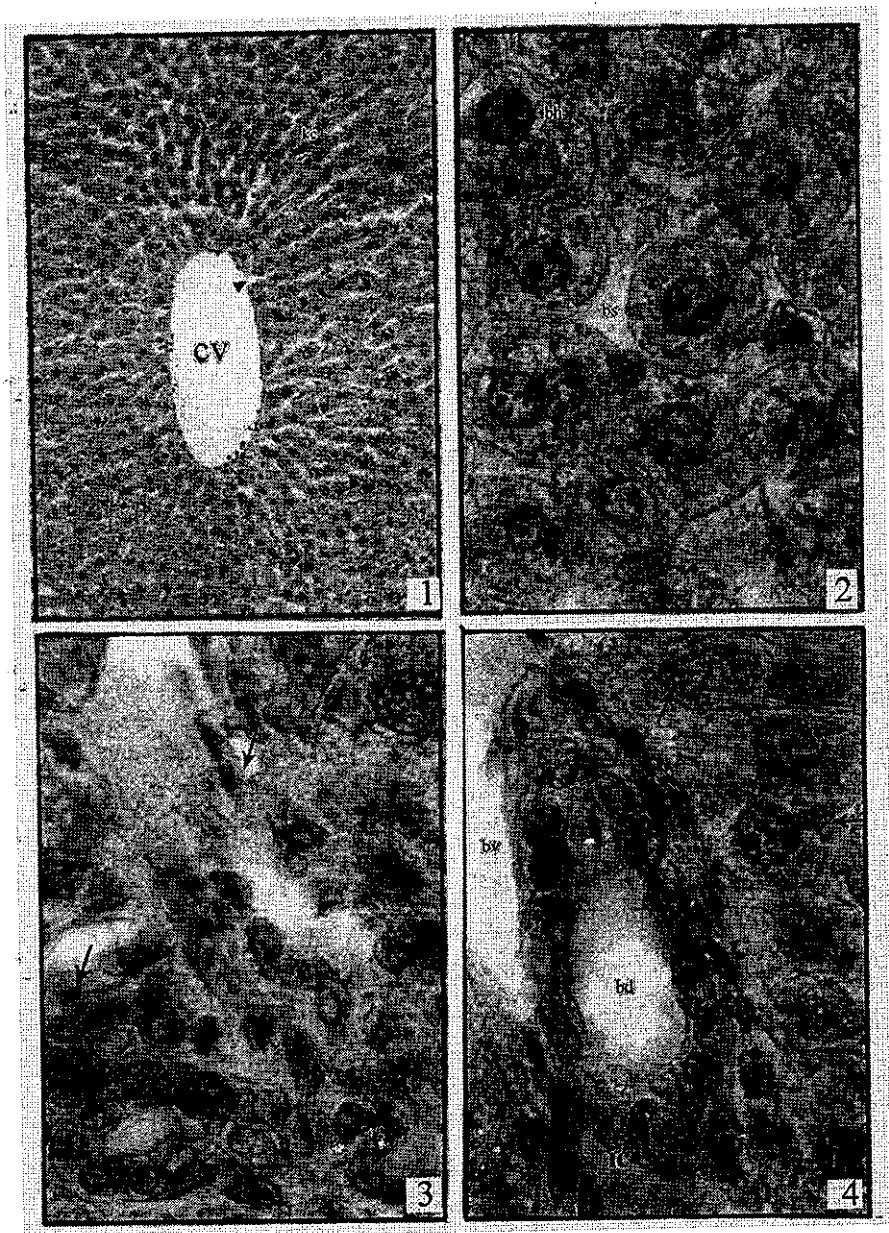
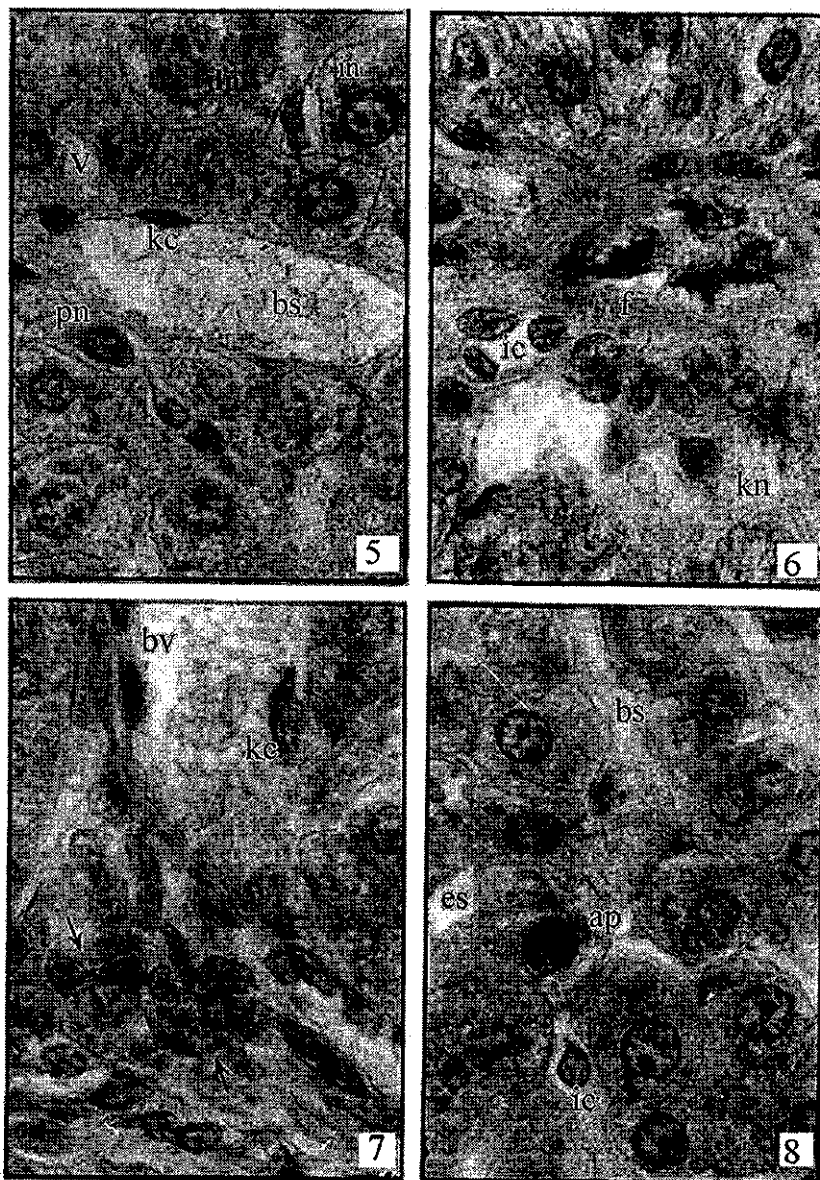


Plate (I)

- Fig.1:** Liver section of normal rat showing radially disposed hepatic strands around the central vein (cv) with fenestrated wall (arrow heads) and Kupffer cells (kc).
- Fig.2:** Liver section of normal rat showing a magnified part of the hepatic lobule illustrating binucleated hepatocytes (bh) with prominent nuclei and nucleoli, blood sinusoid (bs) and cytoplasmic granulation of hepatic cells.
- Figs. 3 and 4:** Liver sections of irradiated rats, one day post-irradiation, showing a marked loss of uniformity and coagulative necrosis (arrows) in the first field but Fig.4 showing faintly stained nuclei (arrows), dilated blood vessels (bv) bile duct (bd) and presence of inflammatory cells (ic).

PLATE II



Figs. 5 and 6: Liver sections of irradiated rats, three days post-irradiation, showing vacuolated cytoplasm (v), pyknotic nuclei (pn), disintegrated nuclei (dn), intact nuclei (in), Kupffer cells (k) and dilated blood sinusoids in the first field, but Fig. 6 showing fibrosis (f), inflammatory cells (ic) and karyolysed nuclei (kn).

Figs. 7 and 8: Liver sections of irradiated rats, five days post-irradiation, showing degenerated hepatocytes (arrows) and hypertrophied Kupffer cells (kc) in the first field but the second one reveals apoptosis (ap), karyolysis (arrowheads), inflammatory cells (ic), widened extracellular spaces (es) and blood sinusoids (bs).

PLATE III

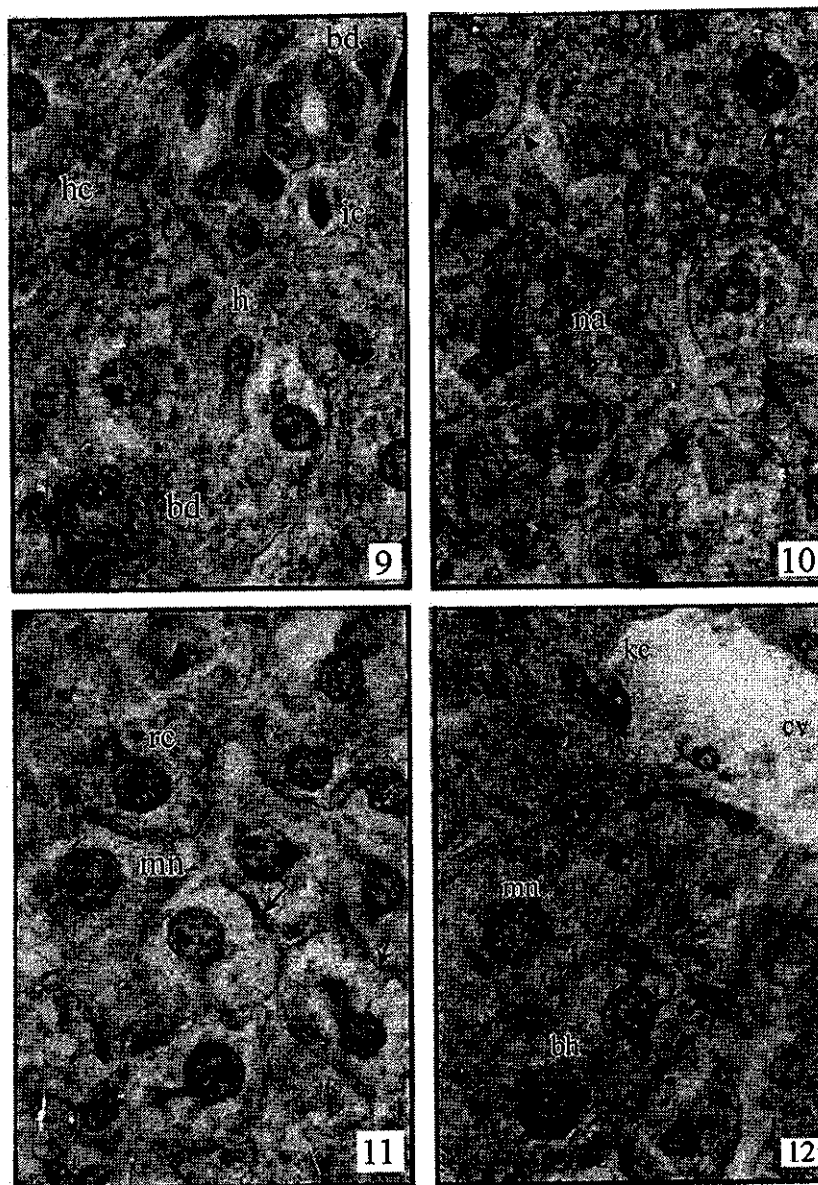


PLATE (III)

Figs. 9 and 10: Liver sections of irradiated rat, 7 days post-irradiation, showing damaged hepatocytes (hc), haemorrhage (h), bile ductules (bd), inflammatory cells (ic) in the first field while Fig.10 illustrates nearly normal hepatocytes (arrowheads) and necrotic areas (na).

Figs. 11 and 12: Liver sections of irradiated rats, 14 days post-irradiation. Fig. 11: showing regenerating cells (rc) with mitotic nuclei (mn) and cells undergoing hydropic degeneration (arrows) with thickened cell membranes. Fig. 12 showing binucleated hepatocytes (bh), dilated central vein (cv) and hypertrophied Kupffer cells (kc) and regular hepatic strands.

PLATE IV

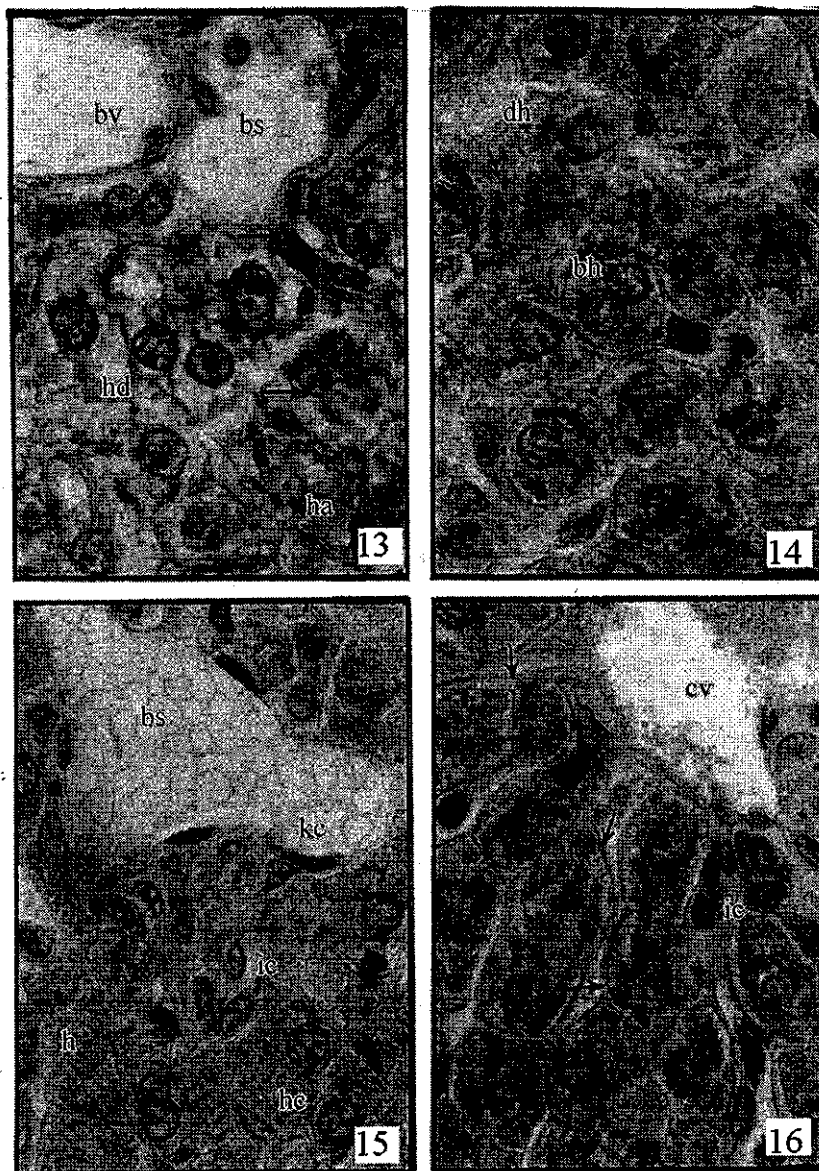


PLATE (IV)

Figs. 13 and 14: Liver sections of rat 1 day after silymarin treatment and irradiation. Fig. 13: showing haematomas (ha), dilated blood vessel (bv) and blood sinusoid (bs), damaged cells (arrows) and cells with hydropic degeneration (hd). Fig.14 reveals regular hepatic parenchyma, binucleated hepatocytes (bh), degenerated hepatocytes (dh).

Figs. 15 and 16: Liver sections of rat 3 days after silymarin treatment and irradiation. Fig. 15 illustrates dilated blood sinusoid (bs), hemorrhage (h), Kupffer cells (kc), and inflammatory cells (ic). Fig.16 showing regular hepatic strands, ill-defined nuclei (arrows) and central vein (cv).

PLATE V

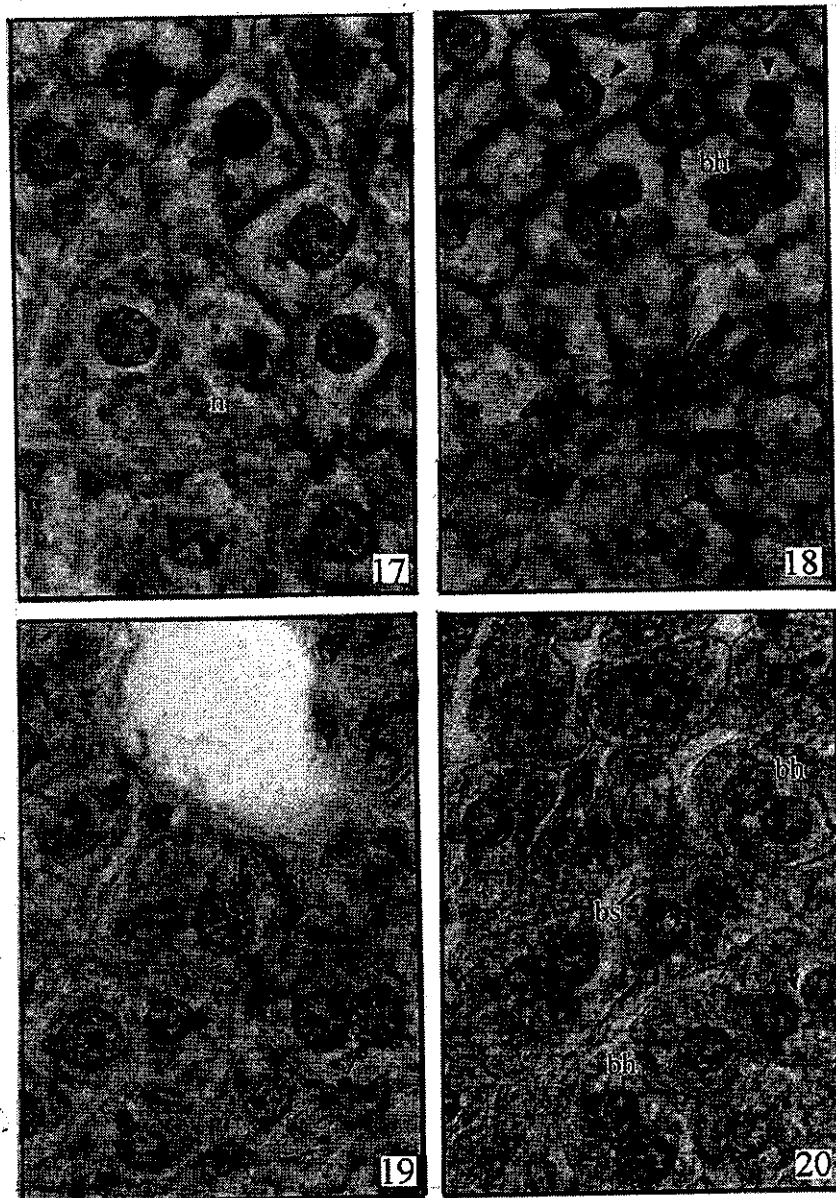


PLATE (V)

Fig. 17: Liver section of rat, 5 day after silymarin treatment and irradiation showing hepatocytes undergoing hydropic degeneration with thickened cell membranes, deeply-stained nuclei and necrosis (n).

Fig. 18: Liver section of rat 7 days after silymarin treatment and irradiation showing nearly normal nuclei (arrow heads), damaged cells with pyknotic nuclei (arrows).

Fig. 19: Liver section of rat 14 days after silymarin treatment and irradiation, showing nuclei with normal chromatin pattern, binucleated hepatocytes (arrow), cytoplasmic granulation, intact cell membranes and regular hepatic strands.

Fig. 20: Liver section of control rat treated with silymarin only, 3 days after silymarin treatment showing normal architecture of hepatocytes.

Discussion

Ionizing radiation is known to induce biochemical, histopathological, and physiological changes in humans and animals. The liver reacts to irradiation with a relative sensitivity due to its regenerative power.

Histological examination of liver sections reveals that the normal liver architecture was disturbed by whole body γ -irradiation of the experimental animals. Liver sections obtained from the irradiated rats many histopathological criteria could be recorded such as hydropic degeneration of cells, loss of regularity of liver strands, pyknosis, karyolysis, coagulative necrosis, widened-extracellular spaces, vasodilatation, haemorrhage, leucocytic infiltration, hypertrophied K upffer cells, fibrosis and apoptosis. The hepatotoxicity of the γ -irradiation has been reported to be due to the formation and release of free radicals especially the superoxid ions (e.g. H_2O_2) in the aqueous medium of the living cells which damage all the cellular structures and all vital molecules inside the cell (El-Bialy, 1980 and Roushdy *et al.*, 1982).

Silymarin administration prior to irradiation, in our study, helps to retain the normal architecture of the hepatic tissue. It minimizes the hydropic degeneration of cells which appeared with intact cell membranes on the first day after administration and irradiation since it acts to stabilize the cell membranes by decreasing the turnover rate of phospholipids and to scavenge the released free radicals. Such findings confirmed the data of Chaun *et al.* (1993) who recorded a cytoprotective effect of silymarin on rat liver injury. Also, our observations confirm and extend the reports of Racz *et al.* (1990) and Garrido *et al.* (1991) who recorded a strong antioxidant and free radical scavenging effect of silymarin. Our explanation seems to be reasonable and comes in agreement with previous data of Hakova *et al.* (1996) who recorded a stimulating effect of silymarin on the synthetic ribosomal RNA species through stimulation of polymerase I and ribosomal RNA transcription and by exerting a steroid-like regulatory action on DNA-transcription protecting the cell membrane from radical induced damage.

The application of silymarin according to this experimental design helped the liver of the treated animals to overcome the destructive effects of γ -irradiation, minimized the incidence of inflammatory leucocytes and increased the regenerative power of the liver in a progressive manner in accordance to the time elapsed after its administration. The liver exhibited good signs of recovery and tissue repair due to silymarin administration prior to irradiation. The hepatic parenchyma restored its regular organization gradually. The drug also increases the number of binucleated hepatocytes and helps the liver cells to restore their cytoplasmic granulation. This efficacy of silymarin may be attributed to its ability to stimulate protein synthesis and cell division in hepatocytes. The mechanism of silymarin effect includes not only stimulation of RNA-polymerase and following processes (stimulation of RNA synthesis, formation of ribosomes and proteosynthesis and stabilization of biological membranes) but also partial protection of cell genetic material (Kropacova *et al.*, 1998).

Yang *et al.* (2001) reported that flavonoids are the largest class of phenolics in the medicinal herbs used in the treatment of liver diseases. These flavonoids demonstrated far stronger antioxidant activity and contained significantly higher levels of phenolics. This antioxidant activity is responsible for the ability of the flavonoid to scavenge free radicals.

In case of the control rats which were treated with silymarin only, the present investigation didn't record any detectable changes in the general histology of liver. These observations support previous findings reported by Mahran and El-Saadany (2000) who couldn't demonstrate marked pathological changes in the hepatocytes of mice treated with silymarin for 30 days.

Although some investigators (Oneschuk and Younus, 2008) reported that it is advisable to approach the use of the natural health products during chemotherapy and radiation therapy with caution, it can be concluded from this investigation

that the treatment of rats with silymarin at adequate concentration and suitable time pre whole-body γ -irradiation succeeded in minimizing the variations occurred in the hepatic tissue at the histological level and confirmed its radioprotective role.

References

1. **Abdel-Hamid GR (2003):** Physiological and histological studies on the protective role of silymarin against the injury induced by subjection of rats to gamma radiation M.Sc: Thesis, Fac. Sci., Helwan Univ.
2. **Adieb N, Abd-El-Zaher K, El-Haggagy A and Wadie S (1988):** Histological study of the lung, heart, liver, pancreas and kidney of the albino rats after single dose whole body gamma irradiation. *Egypt. J. Histol.*, 11 (1): 79-85.
3. **Bancroft J D and Gamble M (2002):** Theory and Practice of Histological Techniques, 5th edition, Churchill, Livingstone, London.
4. **Chauv GW, Chamileau R.A.F.M, Bosch KS and Frederiks WM (1993):** Protective effect of silymarin on rat liver injury induced by ischaemia. *Virchows Archiv. B. Cell Pathol.*, 64: 259-263.
5. **El-Bialy MG (1980):** Use of imidazole as a chemical radiation protector to control radiation induced histochemical and histopathological changes in albino rat (*Rattus norvegicus*), M.Sc. Thesis. Fac. Sci. Cairo Univ.
6. **El-Sayed SM (1995):** Alteration in biological response of mice to γ -irradiation through certain therapeutic and environmental exposure., Ph.D. Thesis., Fac. Sci., Cairo Univ.
7. **Garrido A, Arancibia A, Compos R and Valenzuela A (1991):** Acetaminophen does not induce oxidative stress in isolated rat hepatocytes: its probable antioxidant effect is potentiated by flavonoid silybin. *Pharmacol. Toxicol.*, 69: 9-12.
8. **Hakova H, Misurova E and Kropacova K (1996):** The effect of silymarin on concentration and total content of nucleic acids in tissues of continuously irradiated rats. *Vet. Med. Czech.* 41 (4): 113-119.
9. **Kafafy YA and Ashry OM (2001):** Antioxidative potential of parsley on gamma irradiated rats. *Egypt. J. Rad. Sci., Applic.*, 14 (1): 25-42.
10. **Kropacova K, Misurova E and Hacova H (1998):** Protective and therapeutic effect of silymarin on the development of latent liver damage. *Radiat. Biol. Radioecol.*, 38(4): 411-415.
11. **Luper S (1998):** A review of plants used in the treatment of liver disease. *Altern. Med. Rev.*, 3(6): 410-412.
12. **Mahran HA and El-Saadany MM (2000):** The protective effect of silymarin against mice liver damage induced by amiodarone. *J. Egypt. Ger. Soc. Zool.*, 33 (c): 131-154.
13. **Maurya DK, Salvi VP and Krishan Nair CK (2004):** Radioprotection of normal tissues in tumor-bearing mice by troxerutin. *J. Rad. Res.*, 45: 221-228.
14. **Nishimura Y, Kim HS, Ikota N, Arima H, Bom HS, Kim YH, Watanabe Y, Yukawa M and Ozawa T (2003):** Radioprotective effect of chitosan in sub-lethally x-ray irradiated mice. *J. Radiat. Res.*, 44: 53-58.
15. **Oneschuk D and Younus J (2008):** Natural health products and cancer chemotherapy and radiation therapy. *Oncol. Rev.*, (1): 233-242.
16. **Racz K, Feher J, Csomos G, Vargal I, Kiss R and Glaz E (1990):** An antioxidant drug, silybinin, modulates steroid secretion in human pathological adrenocortical cells. *J. Endocrinol.*, 124: 341-345.
17. **Roushdy HM, Ashry MA and Mansour KM (1982):** Hepatic radiation protection by imidazole. *Isotope and Rad. Res.* 14(2): 86-92.
18. **Said UZ, Soliman SH and El-Tahawy NA (2002):** Possible protective and curative role of thiamine pyrophosphate against radiation induced biochemical and histological changes in male albino rats. *Egypt. J. Rad. Sci. Applic.*, 15(2): 17-29.
19. **Simone CBII, Simone NL, Simone V, and Simone CB (2007):** Antioxidants and other nutrients do not interfere with chemotherapy or radiation therapy and can decrease kill and increase survival. *Alternative Therapies*, 13: 22-28.
20. **Stickel F, Brinkhaus B, Krahmer N, Seitz HK, Hahn EG and Schuppan D (2002):** Antifibrotic properties of botanicals in chronic liver disease. *Hepatogastroenterology*, 49(46): 1102-1108.
21. **Uma DP, Ganasoundari A, Vrinda B, Srinivasan KK and Unikrihnan MK (2000):** Radiation protection by ocimum flavonoids orientin and vicenin: mechanism of action. *Radiat. Res.*, 154: 455-460.
22. **Yang CS, Landou JM, Huang MT, Newmark HL (2001):** Inhibition of carcinogenesis by dietary polyphenolic compounds. *Annu. Rev. Nutrition*, 21: 381-406.

عقار السيليمارين يحمي المظهر الهستولوجي لكبد الجرذان من سمية الإشعاع

سمير نصار* - عمر غنيمي** - صبرى الصيرفي** - حامد رشدى*** وعمرو عبد الهادى*

* من قسم علم الحيوان - كلية العلوم - جامعة الزقازيق، ** قسم علم الحيوان - كلية العلوم - جامعة بنها،
*** والمركز القومى لبحوث وتكنولوجيا الإشعاع (NCRRT) - مصر

لعقار السليمارين أهمية طبية خاصة في حياة الإنسان المصري نظراً لانتشار أمراض الكبد في القطر المصري حيث يستخدم هذا العقار غالباً في علاج العديد من أمراض الكبد. ويصنف ضمن عائلة الفلافونويدز (flavonoids) ويتكون من ثلاثة أشباه هي: السيليبين (silybin) والسيليديانين (silydianin) والسيليكريستين (silychristin) وقد أثبتت الدراسات السابقة أن هذا العقار قادر على حماية الخلايا الكبدية بشكل مباشر عن طريق المساعدة على استقرار الأغلفة الحيوية لهذه الخلايا وتغيير المحتوى الدهني لها.

ويهدف هذا البحث إلى الدراسة وإلقاء المزيد من الضوء على الدور الوقائي للسليمارين من حدوث بعض التغيرات الهستوباثولوجية في خلايا كبد الجرذان المشععة وذلك عند إعطائه لحيوانات التجارب عن طريق الفم قبل عملية التشعيع بساعة واحدة ولقد استخدمت في هذه الدراسة ذكور الجرذان البالغة وتم تقسيمها إلى أربع مجموعات كما يلي: مجموعة جرذان طبيعية، مجموعة جرذان مشععة بالجرعة 5 جراى، مجموعة جرذان تم إعطاؤها عقار السليمارين (70 مجم / كجم من وزن الجسم) ثم تشعيعها أيضاً بالجرعة 5 جراى، مجموعة جرذان ضابطة (تم إعطاؤها عقار السليمارين فقط) ولم تشعع. تم ذبح جميع الجرذان للمجموعات الأربع في فترات زمنية واحدة وهي اليوم الأول والثالث والخامس والسابع ثم اليوم الرابع عشر بعد التشعيع وتم أخذ عينات الكبد وتثبيتها في 10% فورمالين ثم تقطيعها وصباغتها بصبغة الهيماتوكسين والأيوسين وفحصها بالميكروسكوب الضوئي وتم تسجيل النتائج الآتية :

أظهر الفحص الهستولوجي لخلايا الكبد في الجرذان المشععة بأشعة جاما تغيرات باثولوجية واضحة منها ظهور الفجوات السيتوبلازمية ثم بكنزة النواة وتحللها واختفاء النويات وتهدم النسيج الكبدي وظهور النكزة في مناطق عديدة منه. وتزايد غزو النسيج الكبدي بالخلايا البيضاء الدالة على الالتهاب وغيرها. وفي دراستنا الحالية أظهر عقار السليمارين دوراً واقياً لخلايا الكبد (في الجرذان المشععة) من تأثير الإشعاع حيث ساعد النسيج الكبدي في التغلب على التأثيرات الهدمية للإشعاع ورفع من قدرته على التجدد والاستشفاء وإعادة البناء فظهرت الخلايا الكبدية مرتبة في أشرطة خلوية قطرية داخل الفصوص الكبدية وذات جدر خلوية سليمة وأنوية ونويات واضحة. ثم استعادت الخلايا الكبدية بشكل تدريجي مظهرها الهستولوجي ووضعها النسيجي الطبيعيين مع تزايد ظهور الخلايا الكبدية ذات النواتين الدالة على ازدياد نشاط التجدد والانقسام في النسيج الكبدي مع العلاج بالسليمارين. من النتائج السابقة خلصنا إلى تأكيد الدور الوقائي لعقار السليمارين للمظهر الهستولوجي لخلايا كبد الجرذان المشععة بأشعة جاما.