

قسم التشريح والهستولوجيا  
كلية الطب البيطري - جامعة أسيوط  
رئيس القسم : أ.د/ حلمي محمد بدوي •

## الكيس الليمفاوي والقناه الصدريه في الحمار

محمد علم الدين ، علي عبدالقادر ، كمال هاشم

أجري هذا البحث على أربعة وعشرين حمارا بغرض دراسة الكيس الليمفاوي والجزوع الليمفاوية التي تصب فيه وكذلك تواصله في التجويف الصدري ممثلا في القناه الصدرية •  
وقد أمكن في هذا البحث حقن القناه الصدرية بواسطة مادة اللاتكس الملونه - وعند التشريح وتتبع هذه المادة وجد أنها تصل للكيس الليمفاوي وكذلك الجزوع الليمفاوية التي تصب فيه مباشرة والجزوع الليمفاوية الاصغر وخاصة الجزوع اللفائقيه والتي يصل فيها الحقن حتى بداية تكوينها كتجميع لأوعية صادرة من العقد الليمفاوية - أما الجزوع الأخرى مثل الجزوع القولونية والكبدية والمعدية فقد كان يتوقف الحقن عند بعض النقاط وأممكن استكمال الحقن من بعد هذه النقاط حتى وصلنا بهذه الجزوع الى بداية تكوينها من العقد الليمفاوية المقابلة •

وبالاضافة لهذا تم حقن بعض العينات بالطرق التقليدية وباستعمال مادة الايفانس الأزرق لتسجيل تفاصيل أكثر بخصوص تكوين هذه الجزوع أو لتسجيل الأوعية الصادرة لبعض العقد الليمفاوية التي تصب مباشرة في هذه الجزوع •

وأخيرا تم تشريح ووصف هذه الجزوع ومقارنتها بمشيلاتها في الحيوانات الأخرى •  
وتسجيل أوجه الشبه والاختلاف والتي كانت تشبه في كثير من الأحيان تلك الموجودة في الحصان •

Dept. of Anatomy and Histology,  
Fac. of Vet. Med., Assiut University,  
Head of Dept. Prof. Dr. H. Badawi.

**THE CISTERNA CHYLI AND THE THORACIC DUCT IN DONKEY  
( EQUUS ASINUS )  
(With 4 Figures)**

By  
**M.A. ALAM EL-DIN; A.A. MANSOUR and K.E.H. ABDALLA**  
(Received at 5/3/1987)

**SUMMARY**

This study was carried out on 24 donkeys. The trials for injection of the lymph trunks by using coloured gum milk latex gave a satisfactory results.

The cisterna chyli in donkey is rounded in shape and situated opposite to the first lumbar vertebra. The visceral trunk which is not formed in horse is recorded in donkey. The celiac trunk is formed by the joining of the hepatic and gastric trunks and the intestinal trunk is formed by the joining of the jejunal and colic trunks. However, in horse, the celiac and intestinal trunks are formed by the confluence of the efferent vessels of the celiac and cranial mesenteric lymph nodes respectively. The thoracic duct was recorded in one third of cases on the left dorsal aspect of the aorta. The other variations of the duct in donkey were found to resemble those in horse.

**INTRODUCTION**

The available literature lack data on the anatomy of the lymphetic system in donkey in spite of the great importance of this animal in the farms. Only Ali *et al.* (1984) described the lymphocenters of the thoracic cavity in donkey but the aim of the present work is to investigate the large lymph trunks.

**MATERIAL and METHODS**

The present work was carried out on 24 donkeys. Nineteen of them were anaesthetized by chloroform, bled and the thoracic cavity had been opened and the thoracic duct was injected by the coloured gum milk latex. It must be noted that injection of the lymph trunks by using latex should be gently performed to avoid their rupture because their wall are very thin and weak.

In another two examined donkeys and after opening of the thoracic cavity, the thoracic duct was found congested with coagulated lymph, mixed with regurgiated blood from the venous side. These two specimens were described without injection.

The later three donkeys were anesthetized and injected by 1% solution of Evan's blue in a dose of 0.5 ml. in different seats (subcut., subperitoneum and subpleura). The animals were bled and the thoracic and abdominal cavity were opened and the injection was continued in the subserosa of the viscera which gave a good results. Moreover, these three cases were also injected through the thoracic duct by the gum milk latex because the cisterna chyli and the large trunks were found usually free from Evan's blue.



The nomenclature used, is that adopted by Nomina Anatomic Veterinaria (1983).

## RESULTS

### A) *Cisterna chyli*

The cisterna chyli in donkey (Fig. 1/1) is more or less rounded in shape. It is situated on the right dorsal aspect of the abdominal aorta in contact to the body of the first lumbar vertebra and is embedded between the tendons of the crura of the diaphragm dorsally and between right kidney and the caudal vena cava ventrally. It lies just caudal to the right renal artery and extends caudally till the level of the cranial aspect of the second lumbar vertebra and it measures 0.3 - 0.7 cm in thickness, and 1.5 - 2 in cm diameter. The cisterna chyli receives the trunci lumbales, Truncus visceralis, and efferent vessels of the renal and lumbar aortic lymph nodes and continues cranially as the ductus thoracicus.

#### Trunci Lumbales :

The lumbar trunks (Fig. 1/2) are represented by 1 - 3 lymph vessels passing on the right and ventral aspect of the caudal vena cava and the left aspect of the abdominal aorta. These trunks are formed mainly by the efferent vessels of the medial iliac lymph nodes. They measure about 7 - 11.5 cm in length and 0.3 - 0.7 cm in diameter. Along their course the lumbar trunks drain the lumbar aortic lymph nodes and in 8 examined cases the lumbar trunks were found to receive efferent vessels from the caudal mesenteric lymph nodes. Moreover in 4 examined cases one of these trunks was found to terminate in the intestinal trunk.

#### Truncus visceralis :

The visceral trunk (Fig. 1/3) is a very short lymph vessel measuring 0.5 - 1.2 cm in length and 0.3 - 0.6 in cm diameter and is recorded in 17 examined cases. It is formed by the union of celiac and intestinal trunks and passes upward between the caudal vena cava and the aorta to terminate into the ventral part of the cisterna chyli, however in 5 cases of the examined donkeys the visceral trunk, terminated into the thoracic duct (Fig. 2 a).

#### Truncus intestinalis :

The intestinal trunk (Fig. 1/4) is formed by junction of the jejunal and colic trunks just caudal to the cranial mesenteric artery, it measures 4 - 7 cm length and 0.2 - 0.4 cm diameter. Along its course it receives efferent vessels of the cranial mesenteric lymph nodes. In 17 examined cases the intestinal trunk terminates by joining the celiac trunk to form the visceral trunk, while in another 7 cases the intestinal trunk was found to terminate separately into the cisterna chyli (Fig. 2 b). On the other hand, in 50% of the examined cases the intestinal trunk receive the efferent vessels from the caudal mesenteric lymph nodes, these vessels accompany the ventral aspect of the caudal vena cava and measures about 5.5 cm in length.

The jejunal trunks (Fig. 15) are 8-13 in number which ranging between 2-6 cm in length and each of them is formed by the efferent vessels of 2 - 5 adjacent lymph nodes. The jejunal trunks join the colic one to form the intestinal trunk however some of them terminate in the cranial mesenteric lymph node.



## THE CIST. CHYLI AND THE T.D. IN DONKEY

The colic trunk (Fig. 1/6) is formed by the connection of 4 large vessels which drain the colic and cecal lymph nodes in addition to some vessels from the caudal mesenteric lymph node, these vessels measure 3 - 5 cm in length and accompany the colic branch, right colic and cecal arteries. The colic trunk joins the jejunal trunks, caudal to the cranial mesenteric artery, to form the intestinal trunk.

### Truncus celiacus :

The celiac trunk (Fig. 1/7) is formed by the connection of the hepatic and gastric trunks. It is about 3 - 6 cm in length and is found dorsal to the right adrenal gland. It receives the efferent vessels of the celiac lymph node and joins the intestinal trunk to form the visceral trunk, however in 6 out of 24 examined cases it was found that the celiac trunk open independently into the cisterna chyli (Fig. 2 b). Moreover, in another three cases it was observed that the celiac trunk opens into the thoracic duct (Fig. 2 c).

The hepatic trunk (Fig. 1/8) is formed by the efferent vessels of hepatic lymph nodes, it passes caudodorsally in the substance of pancreas accompanying the dorsal aspect of the portal vein. It receives the efferent vessels of the pancreaticoduodenales lymph nodes and terminates by joining the gastric trunk to form the celiac trunk.

The gastric trunks (Fig. 1/9) are formed by the efferents of the gastric lymph nodes and accompany the parietal and visceral branches of the left gastric artery.

During dissection it was found that the cisterna chyli, the associated large trunks and even the smaller ones such as the jejunal trunks were injected. The other smaller trunks (hepatic, gastric and colic) were usually found incompletely injected. Therefore, the injection was repeated beyond the point of obstruction until it reach the beginning of these trunks as a confluence of the efferent vessels of the corresponding lymph nodes.

## B) Ductus thoracicus

The thoracic duct in donkey (Fig. 1/10, 3/1) is the cranial continuation of the cisterna chyli. It passes on the right dorsal aspect of the aorta, ventral to the vena azygos until the level of 6th thoracic vertebra where it inclines ventrally crossing the left aspect of the esophagus and trachea to gain the dorsal aspect of the brachiocephalic trunk and in turn the left subclavian artery. Then after the thoracic duct accompany the bicarotid trunk and the left vagus nerve and later on it inclines ventrally and become ampullated to open into the cranial vena cava 0.1 - 2.5 cm cranial to the first rib, just medial to the medial scalenus muscle. In half of the examined cases that portion of the thoracic duct, from the 6th thoracic till its termination, bifurcates and rejoins again. In two examined cases this bifurcation and rejoining was twice occurred. The thoracic duct measures about 65.5 - 78.5 cm in length and 0.6 - 1.1 cm in diameter. Along its course it drains the intercostal, thoracic aortic, middle mediastinal, cranial mediastinal, left tracheobroncheal and the inconstant costocervical lymph nodes. Moreover it receive lymph vessels from the lumbar and tendinous parts of the diaphragm.

The course, position and termination of the thoracic duct shows a great variety among the examined donkeys. In most of the examined cases it lies on the right dorsal aspect of the aorta while in 8 cases it was found to be located on the left dorsal aspect of the aorta from the level of the 16th thoracic vertebra till the 6th thoracic vertebra and then continued its course as mentioned before. In another 3 cases the thoracic duct was found to be divided into two large lymph vessels (Fig. 4 c), at the level of the 17 thoracic vertebra, one of them on the right and the other on left dorsal aspect of the throacic aorta. The two vessels



M.A. ALAM EL-DIN, *et al.*

continued cranially till the level of the 7<sup>th</sup> thoracic vertebra where the right vessel terminates into the left one. The two vessels were connected by two cross anastomoses dorsal to the aorta and opposite to the 16<sup>th</sup> and the 14<sup>th</sup> thoracic vertebra in one of the examined cases (Fig. 4 d).

In 3 examined cases the thoracic duct was found to be divided into two branches which opened separately (Fig. 4 e) into the cranial vena cava 1 - 2 cm apart from each other. Moreover in 4 cases the thoracic duct was found to terminate into the left external jugular vein (Fig. 4 f).

In one examined case the thoracic duct divided into right and left branches, opposite to the 18<sup>th</sup> thoracic vertebra, which encircle the costoabdominal and the last two pairs of the dorsal intercostal arteries (Fig. 4 g), thereafter the two vessels connect to form one vessel which completed its course on the right dorsal aspect of the aorta.

### DISCUSSION

The cisterna chyli in donkey is rounded in shape, lies opposite to the first lumbar vertebra and extends caudally to the level of the cranial extremity of the 2<sup>nd</sup> one where it receives the lumbar trunks. It extends cranially embedded between the two crura of the diaphragm as the thoracic duct. This description resembles the most dilated portion of the spindle-shaped cisterna chyli of horse which extends from the 2<sup>nd</sup> lumbar to the last thoracic vertebra as described by VOLLMERHAUS (1981).

In donkey the celiac and intestinal trunks join together to form the visceral trunk which is also formed in carnivores, pig and ruminant as reported by VOLLMERHAUS (1981). The same author added that in horse the two trunks open separately into the cisterna chyli without forming the visceral trunk. The formation of the celiac and intestinal trunks in donkey resembles that described in bovine by SAAR and GETTY (1975). They mentioned that in horse, these trunks are formed as the confluence of the efferent vessels of the celiac and cranial mesenteric lymph nodes respectively. The termination of the celiac and visceral trunks into the thoracic duct which is found in exceptional cases of the examined donkeys was not recorded in horse by SAAR and GETTY (1975) and VOLLMERHAUS (1981).

In donkey the lumbar trunks are formed mainly by the efferents of the medial iliac lymph nodes. This comes in agreement with that described in dog and small ruminant by VOLLMERHAUS (1981). Whereas in horse the author mentioned that the lumbar trunks are formed by the efferent vessels of the aortic lumbar lymph nodes. Moreover the same trunk receives the efferents of the caudal mesenteric lymph nodes which was recorded in the present work in some examined donkeys.

SAAR and GETTY (1975) mentioned that the thoracic duct in horse and bovine divides in many cases into two branches which lie on the right and left side of the dorsal face of the aorta and they usually unite over the base of the heart, moreover they are connected by cross branches. Similar findings were recorded in the present work.

In horse (VOLLMERHAUS, 1981) and in camel (ALAM EL-DIN, 1984) the thoracic duct cranial to the level of the 4<sup>th</sup> intercostal space divides and reunites and before its termination it becomes ampullated, similar to that described in the present work.

The termination of the thoracic duct in donkey, in the cranial vena cava or the left external jugular vein resembles that described in horse and bovine by SAAR and GETTY (1975), in cat by WALKER (1970) in goat by TANUDIMADJA and GHOSHAL (1973) and in dog by BAUM (1918).



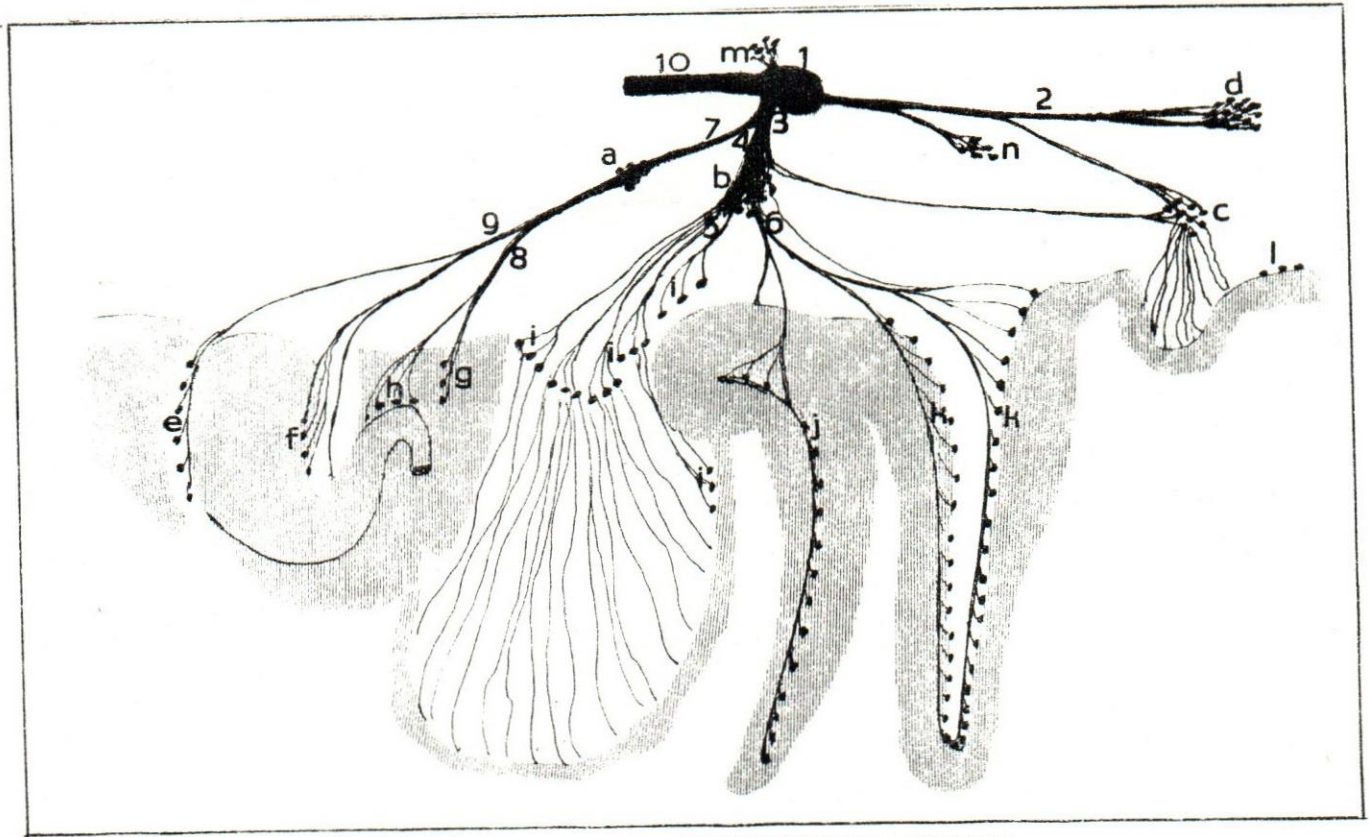
### THE CIST. CHYLI AND THE T.D. IN DONKEY

The bifurcation of the duct at its termination which was observed in some examined donkeys is reported in horse by SAAR and GETTY (1975) and in cat by MIOTTI (1965).

The thoracic duct in donkey drain some of the intercostal, thoracic aortic and cranial mediastinal lymph nodes as mentioned by ALI *et al.* (1984). In the present study it also drain the middle mediastinal, the costocervical, when present, and the caudal deep cervical lymph nodes as well as the lymph vessels from the crura and the tendinous part of the diaphragm.

### REFERENCES

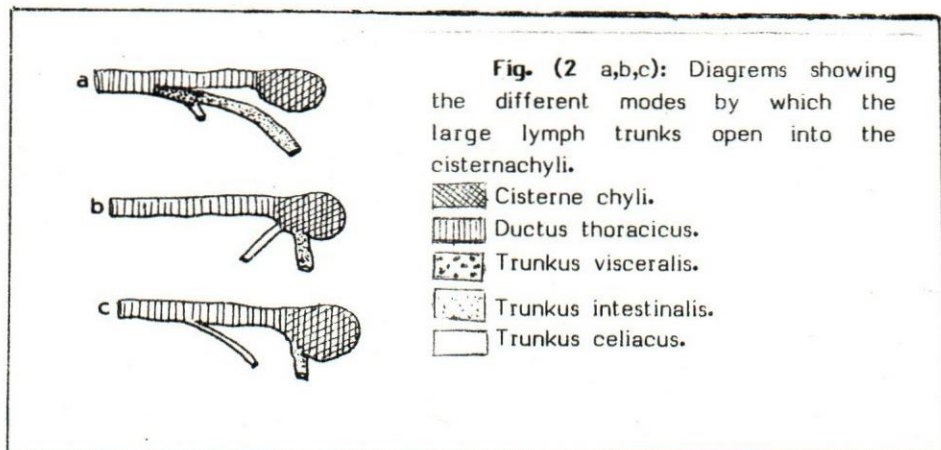
- Alam, El-Din, M.A. (1984): Some anatomical studies on the lymphatic system of one humped camel (*Camelus dromedarius*). Thesis Fac. Vet. Med. Assiut University.
- Ali, A.M.A.; A.S. Saber; A.A. Mansour and I.A. Ibrahim (1984): Lymphocenters of the thoracic limb and thoracic cavity of donkey (*Equus Asinus*) First scientific Congress. Faculty of Vet. Med. Assiut University.
- Baum, H. (1981): Cited by Miller, M.E. (1964): *Anatomy of the dog*. W.B. Saunders Company Philadelphia London.
- Miotti, R. (1965): Cited by: Rudolf, H. and M.W. Stromberg (1976): *Anatomy of the laboratory Rat*. The Williams and Wilkins Company, Baltimore.
- Nomina Anatomica Veterinaria (1983): Third edition. Published by the international committee on Veterinary Gross Anatomical Nomenclature under the financial responsibility of the World Association of Veterinary Anatomists Ithaca, New York.
- Saar, I. & R. Getty (1975): *Equine lymphatic system in Sisson & Grossman's, The anatomy of the domestic animals Vol. I*. Rev. by R. Getty. Saunders Company, Philadelphia, London, Toronto.
- Tanudimadja, K. and N.G. Ghoshal (1973): The lymph nodes and lymph vessels of the thoracic wall of the goat (*Capre hircus*). *Iowa State J. Res.* 47: 229-243.
- Vollmerhaus, B. (1981): *Lymphatic system in Nickel, Schumer and Seiferles. The anatomy of the domestic animals. Vol. II, the circulatory system, the skin and the cutaneous organs of the domestic mammals*. Verlag Paul Parey, Berlin. Hamburg.
- Walker, W.F. (1970): *Vertebrate Dissection*. W.B. Saunders Company. Philadelphia. London. Toronto.








**Fig. (1):** Schema of the large trunks in donkey:

1) Cisterna chyli. 2) Trunci lumbales. 3) Truncus visceralis. 4) Trunci intestinales. 5) Trunci jejunales. 6) Trunci colicae. 7) Truncus celiacus. 8) Truncus hepaticus. 9) Trunci gastricae. 10) Ductus thoracicus:

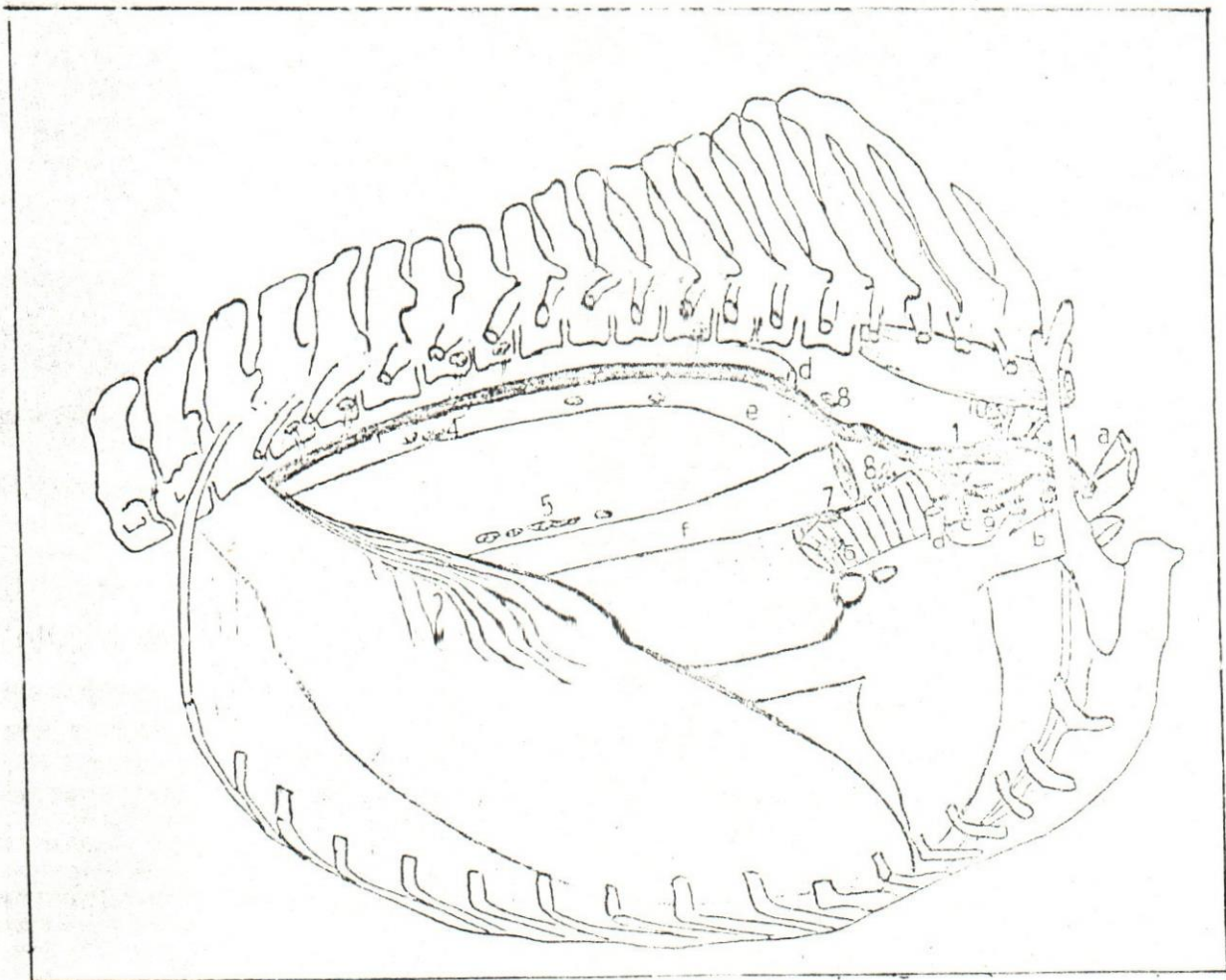
a) Lymphonodi celiaci. b) Lymphonodi mesentrici craniales. c) Lymphonodi mesentrici caudales. d) Lymphonodi iliace mediales. e) Lymphonodi lienales. f) Lymphonodi gastrici. g) Lymphonodi hepaticae. h) Lymphonodi pancreaticodudenaes. i) Lymphonodi jejunales. j) Lymphonodi cecales. k) Lymphonodi colicae. l) Lymphonodi renales. m) Lymphonodi anorectales. n) Lymphonodi aortici lumbales.



**Fig. (2 a,b,c):** Diagrams showing the different modes by which the large lymph trunks open into the cisternachyli.

 Cisterna chyli.  
 Ductus thoracicus.  
 Truncus visceralis.  
 Truncus intestinalis.  
 Truncus celiacus.










**Fig. (3):** A diagram of the thoracic cavity of donkey showing the thoracic duct. Right side:

- 1) Ductus thoracicus.
- 2) Lymph vessels of the diaphragm.
- 3) Lnn. intercostales
- 4) Lnn. thoracici aortici.
- 5) Lnn. mediastinales caudales.
- 6) Lnn. tracheobronchiales dextri.
- 7) Lnn. tracheobronchiales medii.
- 8) Lnn. mediastinales medii.
- 9) Lnn. mediastinales craniales.
- 10) Lnn. costocervicales.
- 11) Lnn. cervicales profundae.

- a) V. jugularis externus sinistra.
- b) V. cava craniales.
- c) Trunkus brachiocephalicus.
- d) V. azygos dextra.
- e) Aorta.
- f) Esophagus.
- g) Diaphragm.
- h) V. cava caudales.
- i) Heart.
- j) First rib.

**Fig. (4, a-g):** Diagrams showing the variations of the thoracic duct in donkey:

-  Cisterne chyli.
-  Ductus thoracicus.
-  Vena cava cranialis.
-  Vena jugularis externus sinistre.
-  A. Costo abdominalis and the last two pairs of the Aa intercostales dorsales.

