

معهد بحوث صحة الحيوان - أسيوط  
مدير المعهد : دكتور/ سمير ناشد

دراسة بكتريولوجية وباثولوجية لحالات عدوى نادرة  
بما يشبه بالسل الكاذب في الجمال

سمير ناشد ، محمود عبدالظاهر \*

تم تشخيص عشرة حالات للعدوى بالسل الكاذب في الجمال وكانت الاصابات موجودة بالغدد الليمفاوية الواقعة أمام الفخذ وكان منظر الاصابات بالعين المجردة يشبه السلي حد كبير اصابات السل • أما الدراسة الميكروسكوبية فقد أثبتت أن الاصابات هي عبارة عن عملية نكرزة في أنسجة الغدد الليمفاوية مع وجود خلايا التهابية مثل الخلايا الليمفاوية والأكولة ولكن لوحظ عدم وجود الخلايا العملاقة المتعددة الأنوية • وقد عزل ميكروب يشابه ميكروب السل الكاذب من ستة حالات • أما العدوى التجريبية لخنازير غينيا لم تؤد السلي أي حالات مرضية •

**MICROBIOLOGICAL AND HISTOPATHOLOGICAL  
STUDIES FOR RARE CASES OF CORYNEBACTERIUM  
INFECTION IN CAMEL**  
(With 7 Figures)

By  
**S.M. NASHED and A.Z. MAHMOUD\***  
(Received at 1/12/1986)

**SUMMARY**

Ten cases of corynebacterium infection had been diagnosed in camel. Lesions were observed in the perifemoral lymph nodes. Grossly, the lesions were closely resembling those of tuberculosis. The spherical onion like concentrically laminated mass characteristic for caseous lymphadenitis in sheep were not observed in the affected lymph nodes of camel. Microscopically the lesions were characterized by necrosis of caseous, liquefactive or coagulative type, lymphoid and epithelioid cells reaction. Giant cells were not observed. An organism resembling corynebacterium ovis was isolated from the lesions of six affected lymph nodes. Experimentally inoculated guinea-pigs showed no signs of illness.

**INTRODUCTION**

There are a number of diseases among animals associated with Corynebacterium pseudotuberculosis infection; chiefly among these are caseous lymphadenitis in sheep, ulcerative lymphangitis in horse and cattle and oedematous skin disease in buffaloes (SOLIMAN, 1963). This organism was first isolated and described by PREISZ and GUINARD (1891) from renal abscesses in sheep. The infection has attracted considerable attention of veterinary bacteriologists because of the economic importance of ovine caseous lymphadenitis especially in raising countries like Australia. The main purpose of this study was the isolation of a diphtheroid resembling similar corynebacterium ovis organism from lymph node of camels as well as histopathological studies of infected lymph nodes of camel and organs of experimental animals.

**MATERIAL and METHOD**

The perifemoral lymph nodes from 10 camels had been sent from Banny Adi abattoir during the period of oct. 1984 to oct. 1985 to the Animal Health Research laboratory for examination for T.B. Direct smears from the lymph nodes were made and stained with Ziehl Neelsen and Grams. The smears were taken from necrotic areas in the lymph nodes particularly those at the edge of lesion. An emulsion of caseated material was inoculated S/C in two guinea-pigs and kept under observation for 4 weeks.

Nutrient broth was inoculated from the lesions and incubated at 37°C for 48 hours. Cultures were made on 10% sheep blood agar plates from necrotic areas as well as from inoculated broth. 0.2 ml broth culture after 48 hours incubation at 37°C, was inoculated S/C in two guinea-pigs for each sample.

The isolated colonies were subjected to morphological examination as well as to biochemical studies according to CRUICKSHANK *et al.* (1976). All the affected lymph nodes were carefully examined grossly. Samples from different parts of the affected lymph nodes of camels were taken for histopathological examination.

The two guinea-pigs inoculated with emulsion of lymph nodes of camels were killed 4 weeks post-injection. The guinea-pigs were dissected and samples were taken from different organs including liver, spleen, intestine, lung, heart, regional lymph nodes and brain. The other two guinea-pigs inoculated with bacterial culture were sacrificed after 4 weeks and treated similarly. These samples and those from the affected lymph nodes of camels were processed for histopathological studies.

## RESULTS

### Bacteriological Studies

Direct smears performed from all of the lymph nodes of camel showed no acid-fast organism. The Gram stained smears of 6 out of the 10 lymph nodes of camels showed Gram-positive pleomorphic beaded coccobacilli arranged in Chinese lettering. The other 4 smears of lymph nodes did not show such appearance and its culture was negative on blood agar.

Colonies of culture of 6 lymph node on blood agar were 1-2 mm in diameter, whitish in colour opaque and friable surrounded by a small zone of beta haemolysis in case of some strains. Colonies when touched by the platinum loop moved readily and were broken up into pieces. Smears from these colonies showed similar characters. Subculture of these colonies on 10% serum broth showed fine to coarse granular deposit extending on the side of the tube with clear supernatant fluid. The six strains fermented, glucose, fructose galactose, maltose, dextrose with acid only while lactose, sucrose and dulcitol were not attacked. Litmus milk showed acid and clot after 48 hours then it was digested. Indol, methyl red and Voges-Proskauer were negative, urea test was weakly positive. No utilization of Koser's citrate.

All these results agreed with those of Corynebacterium ovis.

### Pathological Studies

Grossly the affected lymph nodes were extremely enlarged and hard in consistence. Cut section sometimes had a gritty sound. In cross section the entire node contained multiple focal areas of caseous necrosis. The caseous material was friable and yellowish gray in colour. Occasionally, the center of these lesions were calcified and contained lumps. Gross examination of other caseous lymph nodes revealed no detectable changes. Post mortem examination of guinea-pigs experimentally infected with the isolated diphtheroid revealed no changes.

**Micromorphological studies showed that the lesion of the affected lymph nodes could be classified into two distinct types :**

The first type of lesions consisted of focal areas of caseous necrosis. These areas were multiple and had different sizes (Fig. 1). Sometimes they communicate together to form band of necrotic tissue which occupy a considerable area of the lymph node. These areas of necrosis always involved the lymph follicles of the cortical area, but sometimes they extended to involve the medulla. The caseous necrotic areas always showed calcification, usually in the central zone. The necrotic areas were surrounded from outside by reactive zone (Fig. 2). The reaction around the necrotic area consists of proliferation of epithelioid and lymphoid cells but giant cells were not seen. These cellular reactions were surrounded from outside by zone of intense hyperemia. In a few instances the reacting cells were surrounded from outside by mild fibrous C.T. proliferation. Fibrous C.T. proliferation was sometimes seen extensively in the subcapsular zone of the lymph node. Calcification was sometimes seen in these areas of proliferating C.T. The blood vessels of the subcapsular area were blocked by large organized thrombus which was sometimes reorganized (Fig. 3) or showing calcification.

### CORYNEBACTERIUM IN CAMEL

A masses of bacterial clumps were sometimes seen within the blood vessels of the subcapsular and paracortical areas.

The second type of lesions begin with coagulative necrosis of some of the lymphoid cells, usually in the center of lymph follicles and sometimes at the periphery of them (Fig.4). These areas of coagulative necrosis as it increased in size were expanded to involve large areas of the lymph follicles and a process of liquefactive necrosis began in the center and extended to involve the areas of coagulative necrosis (Fig. 5). This process resulted in a large central areas of liquefactive necrosis which was surrounded from outside by a zone of lymphoid and epithelioid cells (2-3 rows of cells). This zone of Lymphoid cells usually suffered from early coagulative necrotic changes (Fig. 6) The whole lesions were sharply demarcated from the surrounding tissues, but always present in the center of the lymphoid follicles and never seen in the medulla. These lesions were numerous in number and variable in sizes. Somtimes these lesions were surrounded by a mild fibroblastic proliferation (Fig. 7). No changes were observed in the organs of guinea-pigs inoculated either with the Camel's lymph nodes or with diptheroid culture. The diptheroid organism could not be recovered from the inoculated animals.

### DISCUSSION AND CONCLUSION

Local literature on Corynebacterium ovis infection in camel is rather scanty as most of the work is restricted to bacteriological routine diagnosis of the disease in sheep. CARPANO (1932) reported the disease in camel. Also CARNE (1939) stated that, there were reports in the literature of the occurrence of natural infection by Corynebacterium ovis in ox, goat, camel, wild deer, pig and fowls. In this study 6 isolates of a morphologically and biochemically diptheroid resembling Corynebacterium ovis had been isolated from prefermoral lymph nodes of 10 camels. On the other hand, these isolates differed from other diptheroids which may be isolated from other domestic animal as Corynebacterium equi (Woolcock et al., 1980). Grossly, the lesions were closely resembling those of tuberculosis. The characteristic lamination (onion shape appearance) of the lymph node pathognomonic for this disease in sheep (JUBB and KENNEDY, 1985), was not observed in the lymph nodes of camel. Microscopically the lesions were of two types. The first type consisted of multiple focal areas of caseous necrosis. These necrotic areas were surrounded by lymphoid and epithelioid cell reaction and zone of prominent congestion, giant cells were not seen. Calcification was commonly observed in the central zone of the necrotic areas, the second type of lesions consisted of multiple focal area of liquefactive necrosis which was surrounded from outside by a zone of lymphoid and epithelioid cells. Not infrequently the latter showed coagulative necrosis. Such lesions were observed only in the lung of sheep affected with caseous lymphadinitis (JONES and HUNT, 1983). Lesions of the blood vessels in the subcortical areas were prominent and consisted of thrombosis, organization of thrombus and its calcification. While some of the blood vessels showed clumps of bacteria. These facts point out to the possibility of hematogenous infection of the lymph nodes. Tuberculous infection of the lymph glands of camel was not only excluded on the results of the pathological findings but also on those of bacteriological investigation. The latter included negative smears as well as negative animal inoculations. The isolated diptheroid differed from the classical Corynebacterium ovis as regards being non-pathogenic to guinea pigs since it did not produce pyogenic or toxigenic action. This result is in partial agreement with the studies of SOLIMAN et al. (1963)

From this study, it can appear that camels are susceptible to lymph gland infection by an organism very similar to Corynebacterium ovis.

Lymph glands lesions in camels showing the above appearance should not exclusively considered to be tuberculous and simple bacteriological examination for our diptheroid should be taken in consideration.

NASHED and MAHMOUD

**REFERENCES**

- Carne, M. (1939): A bacteriological studies of 134 strains of corynebacterium ovis J. Path. Bact. 49, 313.
- Carpano, N. (1932): Bull. Zez. Iteil. Sci. Int. Microbiol. 4, 108.
- Cruickshank, R.; T.P. Duid and R.H.R. Swain (1970): Medical Microbiology 12th Ed., E.S. Livingstone Limited. Ediuburgh, London.
- Jones, T.C. and R.D. Hunt (1983): Vet. Pathology. Fifth Ed. Lea Febiger. Philadelphia.
- Jubb, K.V. and P.C.K. Kenedy (1983): Pathology of Domestic animal. Third. Ed. Vol. Z.Academic press, New York, Sanfrancisco London.
- Preisiz, H. and Guinard, L. (1891): Cited from Soliman et al. (1963) Med. Vet. 16, 563.
- Soliman, K.N.; Agamy, F.I. and Sayour, E.M. (1963): Bactriological study of twenty five strains of corynebacterium pseudotuberculosis (C. Ovis). Proceedings of the 4th Arab Annual Veterinary congress on the 20th to 26th April 99-107.
- Woolcock, J.B., Mutinger; M.D. and Farmer, A.M.T. (1980): Epidemiology of Corynebacterium equi in horses. Res, Vet. Sci. 28, 87.



Fig. (1): Lymph node showing caseous necrosis. H & E (16 X).

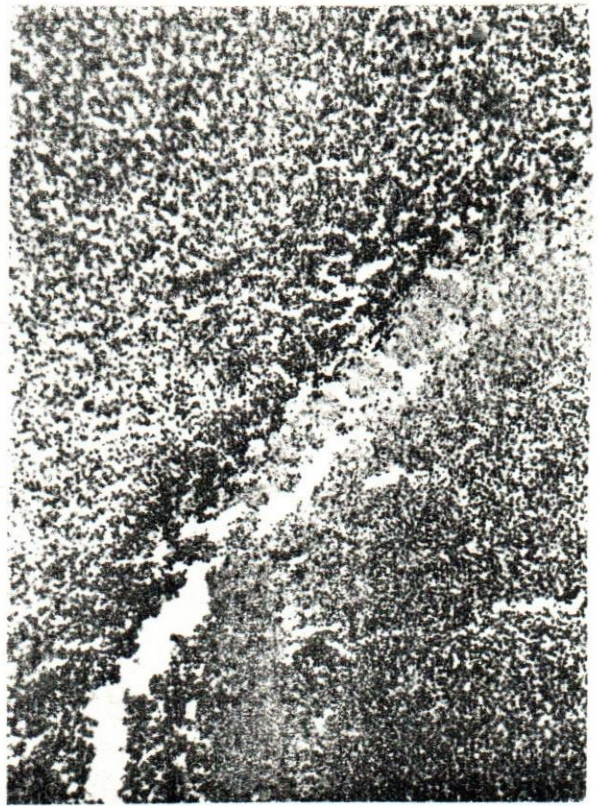


Fig. (2): A Zone of cellular reaction around the necrotic areas. H & E (16 X)

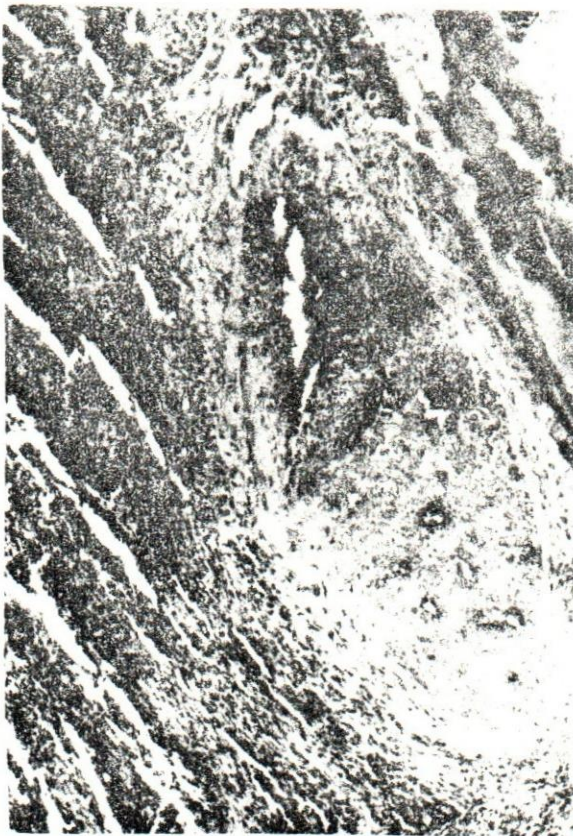

Fig. (3): Blood vessels in the subcortical area in the lymph showing thrombus with recanalization. H&E (16 X)

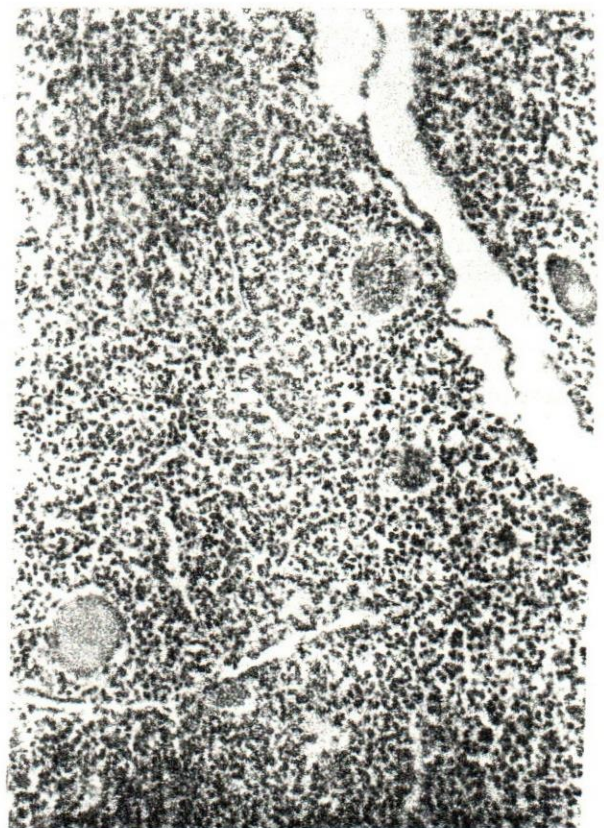

Fig. (4): Minute focal areas of coagulative necrosis in the lymph node. H&E (16 X)

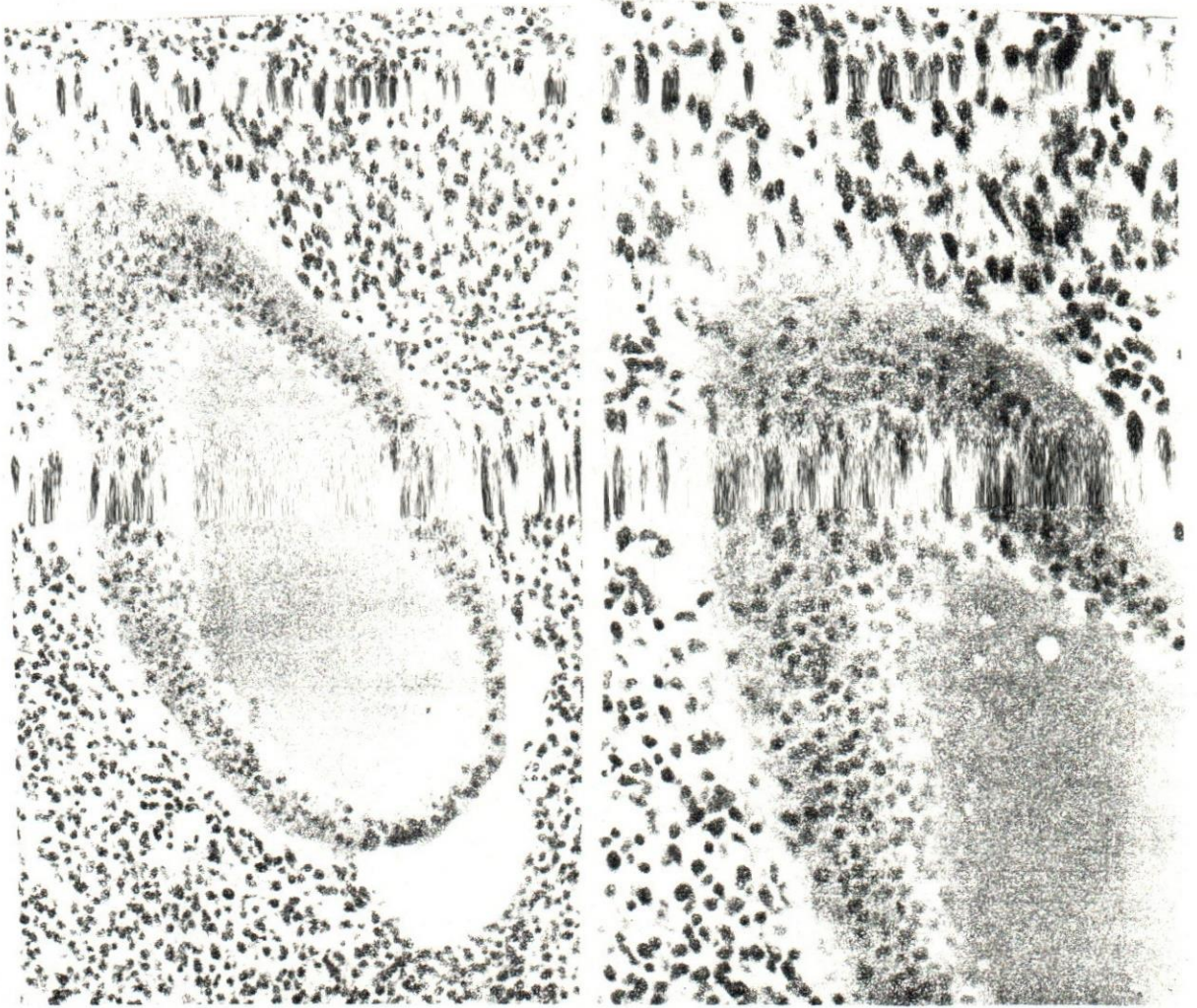


Fig. (5): Area of liquefactive necrosis.  
H & E (25 X ).

Fig. (6): Area of liquefactive necrosis sur-  
rounded by zone of coagulative  
necrosis H & E (40 X ).

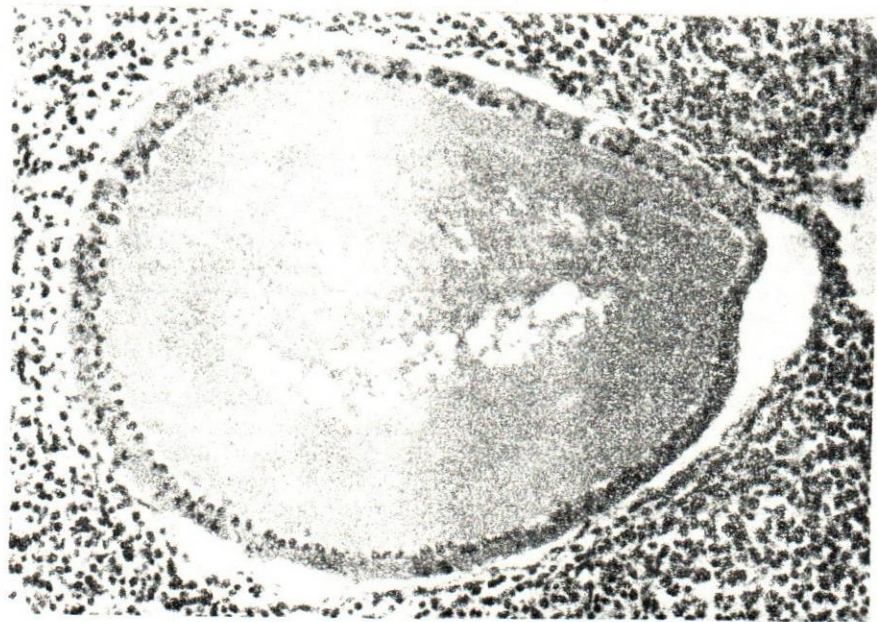


Fig. (7): The necrotic area sometimes was surrounded by fibroblastic proliferation.  
H & E (16 X )