

## Protective Effect of Vitamin "A" Against Skin Injury Caused by Exposure to Electromagnetic Field Histological and Histochemical Studies

Mona A. Salem

Histology Dep., Faculty of Medicine for Girls, Al- Azhar University

### Abstract

**Introduction and Aim of work:** Electromagnetic fields (EMFs) are major environmental danger to our population. They are all around us. Human beings are exposed daily to a variety of radiations which are not recognized. EM radiation from extremely low frequency, radio frequency, emissions, television sets, mobile phone systems, mobile computers, and microwave are harmful to all living organisms. Retinoids are powerful modulators of cell proliferation, differentiation, apoptosis and a mainstay therapy for a wide range of dermatologic diseases.

The aim of this work is to investigate the effects of long term exposure to low-frequency EMF emitted from a colored TV as a house hold set in every day use for prolonged periods of time on the skin of albino rats and the possible protective role of vitamin A.

**Material and Methods:** Twenty adult male albino rats were used in the present study. They were divided into 4 equal groups, control group, the second group (given vitamin A daily for 2 months), the third group exposed to electromagnetic field emitted from colored TV set for 6 hours daily for 2 months. The fourth group was exposed to EMF as the third group and given vitamin A.

**Results** of the present study showed that, exposure to EMF for long period produced thinning of all layers of skin. Hairs were short fine and easily detached, and accepted a yellow color. Apoptosis was observed in the nuclei of the keratinocyte more than that of the control group. Some hair follicles were damaged and replaced with horn-containing cysts. Sebaceous glands were atrophied. Collagen fibers of the dermis appeared thick and disorganized. Most adipocytes in the lower dermis and hypodermis disappeared. The proliferating cell nuclear antigen (PCNA) was reduced compared to control. The mean number of PCNA positive cells in the epidermis and the mean area percent of PCNA positive nuclei were less than that of control.

Giving vitamin A with EMF exposure, reduced most of the changes produced by exposure to EMF, the epidermis and dermis restored their nearly normal thickness. Hairs also restored their normal appearance and thickness. Hair follicles and sebaceous glands regenerate. The collagen fibers restored their nearly normal thickness and arrangement. The mean number and mean area percent of PCNA positive nuclei of the epidermis were increased in comparison to control.

**In conclusion:** long term exposure to EMF induced apoptosis of the cells of the epidermis and dermis, damage of hair follicles and sebaceous glands, also disorganization of collagen fibers. These changes were effectively reduced by vitamin A administration.

**Key words:** Electromagnetic Field- skin- Vitamin "A"

### Introduction

Life on earth is evolved in a sea of weak natural EMFs that ranged in frequency from a few cycles per second (Hz) to the extremely short wavelengths and high energies of cosmic rays. Natural EMFs had been evolved from solar radiation. Also EMFs are found

around any object that has an electric charge. In recent years, there has been a massive introduction of equipments that emit EMFs in an enormous range of frequencies and intensities, and living organisms have not had the opportunity to adapt to such environment.

EMFs from man-made devices and systems are far above the levels of natural radiation. (Adey, 1981).

EMFs exist in the home and workplace as a result of all types of electrical equipments and building wiring as well nearby power lines. Home electrical appliances often provide the highest magnetic field levels with electric blankets being among the largest sources. Electric hair dryers, curling irons, vacuum cleaners, and electric irons (Delpizzo, 1990), mobile phone systems, handsets and mobile computers (Hallberg and Johansson 2004), microwave ovens, video display terminals, and personal radio communication systems are all associated with EMFs that are above natural backgrounds. Occupational exposures cover an enormous range that include heaters and sealers; electric welders; TV servicing; electric power distribution systems; and radio (Adey, 1990a).

Chronic exposure to EMF in the range of 50-60 Hz was found to be associated with health hazards as eye diseases, immunosuppression, hypertension, cardiac conduction defects and ECG abnormalities, endocrinal and hormonal abnormalities, reproductive and teratogenic effects, dermatological risks, obstetric complications and increase risk of tumors (Stevens *et al.*, 1992 and Tenforde, 1992), loss of appetite, irritability, discomfort, fatigue, fainting and difficulty in concentrating (Hallberg & Johansson 2004). Numerous reports suggest that there is a relationship between the increased incidence of cancer particularly leukemia and lymphoma, childhood malignant diseases, female breast cancer, pancreatic, lung and brain malignancies and the exposure to EMFs (Savitz *et al.*, 1988; Zakland *et al.*, 1991; Michelozzi *et al.*, 2002 and Eid & Al-Dossary, 2007). Developmental abnormalities have also been reported from exposure to environmental EMFs, spontaneous abortion fetal deaths and teratogenic abnormalities were also noted (Forlen *et al.*, 1987 and Milham 1985).

Skin is an external organ in continuous interaction with environmental influences as EM irradiation which can lead to skin disease

under certain conditions and in certain individuals (Koike *et al.*, 2005).

It was reported that colored TV sets emit harmful levels of ultraviolet, infrared and microwaves from picture tube in addition to very low EM radiations from high voltage circuit. UV radiation is a form of EM radiation that is capable of damaging cells in different ways (Hallberg and Johansson 2004). UV radiation is the most important physical carcinogen in the environment, and the skin is its main target. In this tissue, UV radiation induces photochemical changes (break molecular bonds in cells to produce ionization that may lead to acute effects such as erythema or chronic effects that include premature skin aging and skin tumors (Sesto *et al.*, 2002). UV irradiation exposure results in the formation of wrinkles, degradation of matrix molecules, development of elastosis (Sano *et al.*, 2005) and increased risk of epithelial skin cancer (Chang *et al.*, 2002).

Vitamin A (retinol), is an essential human nutrient, it plays an important role in cellular differentiation, regulation of epidermal cell growth and normal cell maintenance. It is also a powerful modulator of cell proliferation, differentiation, and apoptosis of keratinocytes and is widely used for the management of skin diseases and for prevention of nonmelanoma skin cancer in predisposed patients with defects of DNA repair. (Kraemer *et al.*, 1988; Lotan, 1996; Altucci and Gronemeyer, 2001 and Soprano *et al.*, 2004).

As EM waves are all around us nearly all the time, so the aim of this study is a trial to investigate the effects of long term exposure to low-frequency EM waves emitted from a colored TV set as a household appliance in every day use for prolonged periods of time on the skin of albino rats and the possible protective role of vitamin A.

## Material and Methods

Twenty adult male albino rats 170- 180 g were used in this study. They were fed on rat chew and freely supplied with water. They were divided into 4 equal groups, the first group was used as normal control, the second

group was given vitamin A (A-Viton, capsule, 50000 I.U. vitamin A Kahira Pharm. & Chem. Ind. Co. Cairo-Egypt) orally at a dose of 900 IU equivalent to the human dose 50000 IU daily for 2 months. The third group was exposed to EM waves emitted from the picture tube 30 cm in front of 14 inches colored TV set 6 hours daily for 2 months. The fourth group was exposed to EM waves as the third group and given vitamin A at the same time as the second group. At the end of the experiment, the animals were anaesthetized by ether inhalation. A small part of skin 1 cm. x 1cm was excised from the skin of the middle of their back after hair shaving. The specimens were fixed in 10% neutral buffered formalin, dehydrated in ascending grades of ethanol, cleared in benzene and embedded in paraffin wax. 5 um thick serial sections were cut and alternative slides were stained with H&E, Masson's trichrome stains (Bancroft & Stevens 1996) and PCNA immuno-stain (Celis *et al.*, 1986).

#### Measurement of the epidermal and dermal thickness:

The thickness of the epidermis from the epidermo-dermal junction to the distal edge of the stratum granulosum was measured in five randomly selected regions from each H&E stained section. The thickness of the dermis from the epidermo-dermal junction to the end of the dermal layer was also measured in the same sections. Pictures were taken using an Olymplus Camedia C-5060 digital camera fitted on the microscope. Pictures of a slide micrometer were also taken, with the same magnification used for the specimens. Image analysis was done on an IBM compatible computer. The image analysis software used was "Image Tool for Windows version 3". The software was first calibrated for the magnification of the image. The thickness of both epidermis and dermis were measured by drawing a line on the image. The software calculates and displays the length of the drawn line.


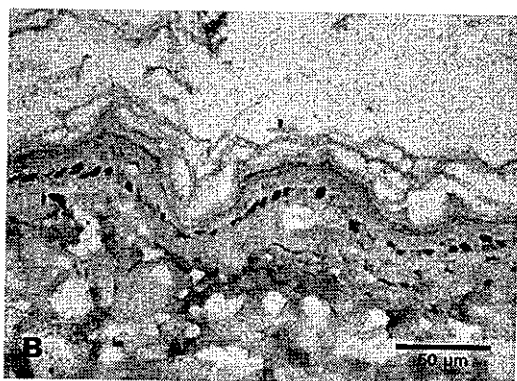
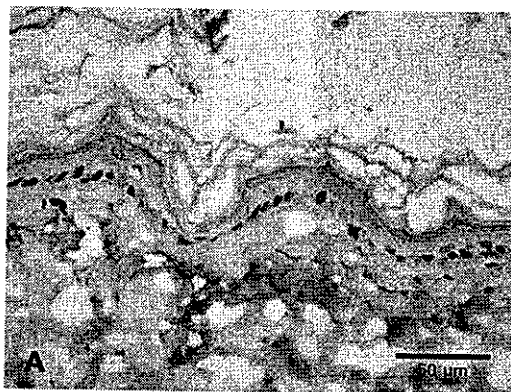
Statistical analysis of the data was performed by analysis of variance. Individual means comparisons were identified by Duncan's Multiple Range Test (SAS, SAS Institute, Cary, NC). Statistical significance was set at  $p < 0.05$ .

#### Immunohistochemical detection of the proliferating cell nuclear antigen (PCNA):

The monoclonal antibody, PC 10 detect the proliferating cell nuclear antigen (PCNA), an auxiliary protein to DNA polymerase-delta necessary for DNA replication. was used. Immunostaining was performed using formalin fixed, paraffin-embedded tissue sections, on poly-L-lysine coated slides. Sections were dewaxed, rehydrated, and brought to phosphate buffered solution (PBS). Endogenous peroxidase activity was blocked by incubation for 7 minute in 3% H<sub>2</sub>O<sub>2</sub>. Monoclonal antibody against PCNA (PC10) (Dakopatts, Glostrup, Denmark) diluted 1 in 200 in PBS was incubated overnight. Normal mouse serum was substituted for primary antibody as a negative control. The sections were then treated for 30 minutes with a biotin-labelled second layer antibody and avidin-biotin-peroxidase complex (Dakopatts, Glostrup, Denmark) was added. Sections were developed with diaminobenzidine for 10 minutes, and counterstained with haematoxylin.

PCNA positive cells in the epidermis were counted in 5 high power images (X400) for each group, using the manual tag feature of the software. The total number of tagged items was counted. For measuring the area% of PCNA immunopositivity in the epidermis, the software was first calibrated for the magnification of the image. The image was then colored to select only the brown colour of immunopositivity which is then masked by a red binary colour. Any immunopositivity detected by the software outside the epidermis was excluded. Then the area% of the red binary color relative to the area of the whole image was calculated (Hall *et al.*, 1990).

Statistical analysis of the data was performed (Armitage and Berry, 1994).



**Image analysis of PCNA immuno-stained skin section**

- A) Original image (PCNA immunostaining, x400).
- B) Same image with the brown colour of PCNA +ve nuclei masked by a red binary colour. Total area of the image = 55391.14  $\mu\text{m}^2$ . Area% = 0.825683%.
- C) Same image with positive nuclei tagged and numbered in red. Count = 25.

**Results**

Skin sections of both control and vitamin A- given groups showed the normal skin structure which was composed of epidermis and an underlying dermis (fig.1). The top thin epidermal cellular layer with an overlying layer of loose keratin was seen, the individual epidermal cell layers were difficult to discern by the low power. By high power examination a single basal keratinocyte layer cuboidal, or low columnar, containing basophilic cytoplasm and large nucleus were located along the basement membrane. Stratum spinosum, the thickest layer, composed of polyhydral to flat cells, and granular cells. Stratum corneum composed of

several layers of flattened, keratin-containing dead cells. A wavy basement membrane separated the epidermal from the thick dermal layers (fig. 2). This epidermo-dermal junction was marked by downward folds of the epidermis (rete ridges). The dermal layer was divided into: a superficial fine loose papillary dermis just beneath the epidermis which contained fine collagen and a thicker, coarse deeper reticular dermis which contained large compact collagen fibers. The cellular components of the dermis were mainly fibroblasts. Also the skin appendages as hair follicles and sebaceous glands could be easily detected within the dermis. The hypodermis

was present beneath the reticular dermis and formed of fat cells (figs 1 & 3). The mean epidermal thickness for group 1 was  $59.2761 \pm 7.8542$  and for group 2 was  $62.4852 \pm 5.7639$ . The mean dermal thickness for group 1 was  $633.3558 \pm 12.2396$  and for group 2 was  $684.9753 \pm 10.1683$  (table 1, histograms 1 & 2).

Immunostaining of skin sections of group 1 and 2 revealed a positive reaction for the proliferating cell nuclear antigen (PCNA) in the nuclei of the epidermis of skin. A positive reaction was expressed as a relatively dark brown color in the nucleus (fig 4). The mean number of PCNA positive cells in the epidermis was  $18.8 \pm 2.945$  for group 1 and  $20.60000 \pm 3.047359$  for group 2. The mean area percent of PCNA positive nuclei was  $0.4135 \pm 0.10845$  for group 1 and  $0.5379 \pm 0.215236$  (table 2, histograms 3 & 4).

By naked eye it was observed that hairs of the animals of the 3<sup>rd</sup> group exposed to EM irradiation emitted from a colored TV were short fine and easily detached, and its color changed to yellow.

Histological examination of H&E stained sections of skin of this group, showed thinning of the epidermis. The keratin layer covering epidermis was markedly reduced in thickness and disappeared completely on many sites (fig. 5). Epidermal keratinocyte layer was markedly reduced in thickness, and its cells were separated. Apoptosis was observed in the nuclei of the keratinocytes more than the control group, which was identified by cell shrinkage, nuclear condensation or fragmentation (fig. 6). The thickness of the dermis and the hypodermis was also reduced. Some hair follicles were

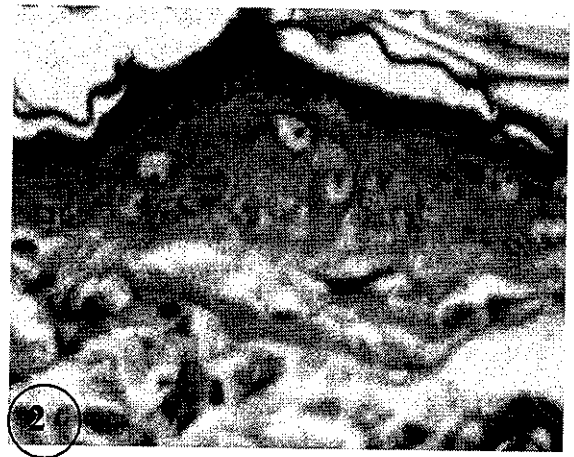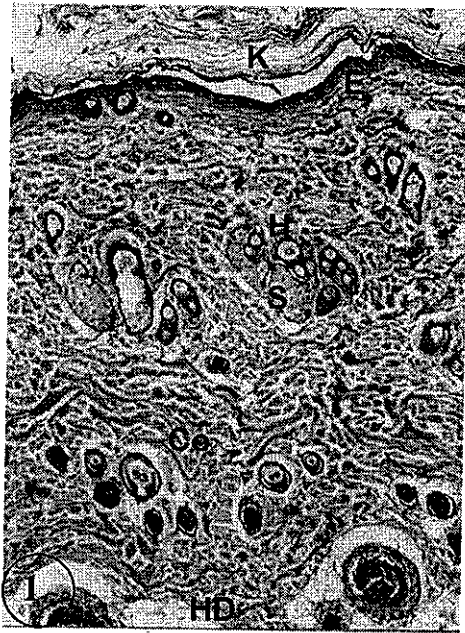
damaged and replaced with horn-containing cysts. Sebaceous glands were atrophied with inflammatory infiltrate in the papillary dermis. Most adipocytes in the lower dermis and hypodermis disappeared (fig. 5).

Collagen fibers appeared thickened, compacted and disorganized with accumulation of collagen bundles in lower dermis (fig. 7). The mean epidermal thickness was  $30.2524 \pm 3.4641$  and the mean dermal thickness was  $465.7731 \pm 20.4218$  (table 1, histograms 1 & 2).

In the 3<sup>rd</sup> group PCNA reaction was reduced compared to control (fig 8). The mean number of PCNA positive cells in the epidermis and the mean area percent of PCNA positive were reduced. The mean number of PCNA positive cells in the epidermis was  $10.82 \pm 1.923$  and the mean area percent of PCNA positive nuclei was  $0.2535 \pm 0.1316$  (Table 2, histograms 3 & 4).

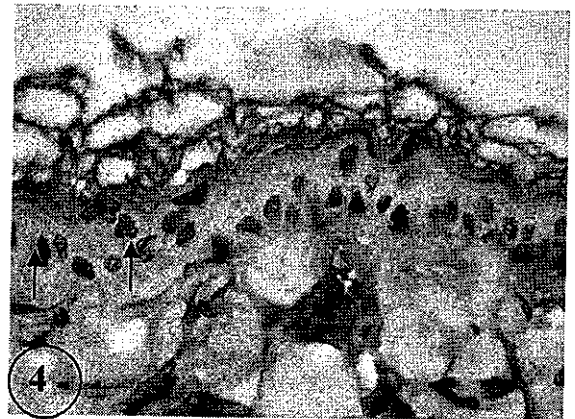
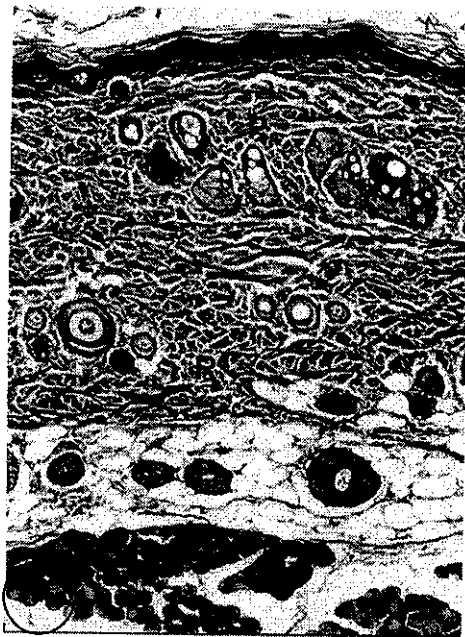
Giving vitamin A with EMF exposure reduced most of the changes produced by exposure to EMF, the epidermis and dermis restored their normal thickness. The keratin layer restored its normal thickness and the hairs also restored their normal color and appearance. The hair follicles and sebaceous glands began to regenerate (figs. 9 & 10). The collagen fibers restored their normal thickness and arrangement (fig. 11). The mean epidermal thickness was  $65.2538 \pm 2.3583$  and the mean dermal thickness was  $691.6276 \pm 16.7254$  (table 1, histograms 1 & 2).

PCNA positive cells increased in the number (fig. 12). The mean number of PCNA positive cells in the epidermis was  $22.2 \pm 1.923$  and the mean area percent of PCNA positive nuclei was  $0.6135 \pm 0.1316$  (Table 2, histograms 3 & 4).



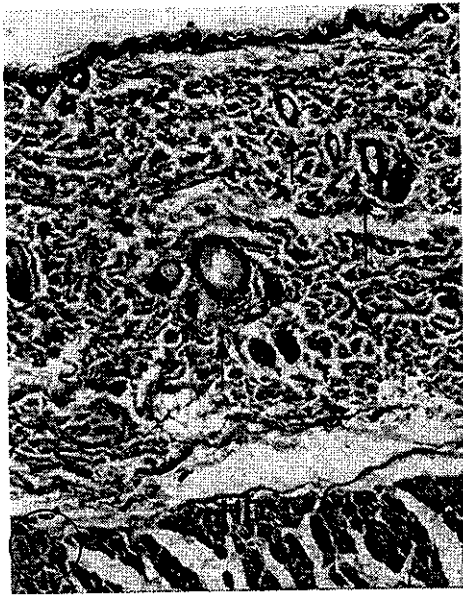
**Fig.(1):** Showing the three layers of the skin epidermis (E) covered by keratin scales (K), dermis containing interlacing collagen fibers (Co), hair follicles (H), sebaceous glands(S), and hypodermis (HD) containing fat cells. (Control, H&EX100).

**Fig(2):** Showing a higher magnification of a part of the epidermis to demonstrate clearly the keratinocytes. (Control, H&E X 1000).



**Fig.(3):** Showing fine green collagen fibers of papillary dermis (P) and coarse fibers of reticular dermis(R). (Control, Masson's trichromeX100).

**Fig. (4):** Showing normal PCNA immunolabelling in the nuclei of keratinocytes (↑). (Control, Avidin-biotin peroxidase complex stain with Mayer's haematoxylin counter stain X 1000).



Fig(5): Showing decreased epidermal and dermal thickness, damaged hair follicles with atrophied sebaceous glands (↑) and markedly reduced hypodermal layer (HD) with absence of adipocytes. (EMF exposed group H&E X100).

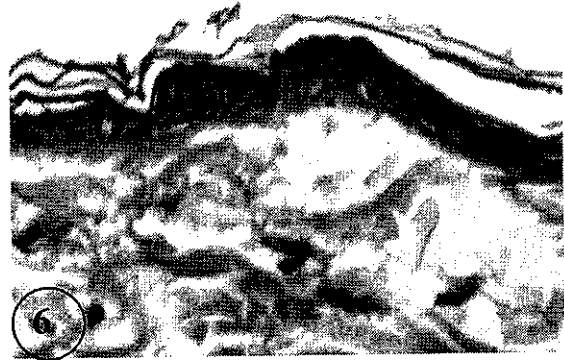

Fig.(6) :Showing apoptosis in most nuclei of the keratinocyte. (EMF exposed group, H&E X1000).

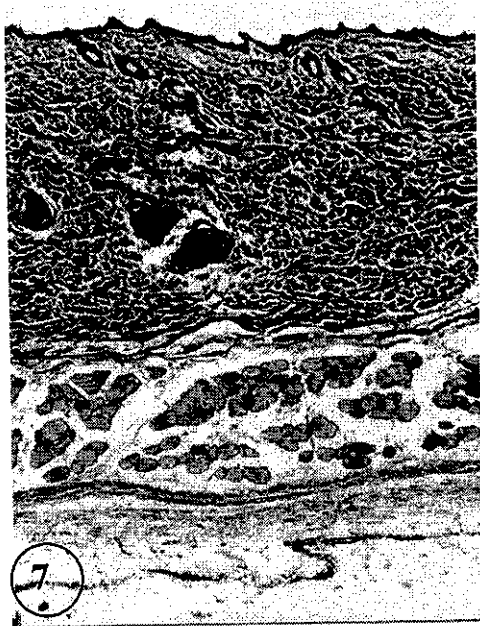

Fig.(7): Showing thickened and disorganized collagen fibers. (EMF exposed group Masson's trichromeX100).

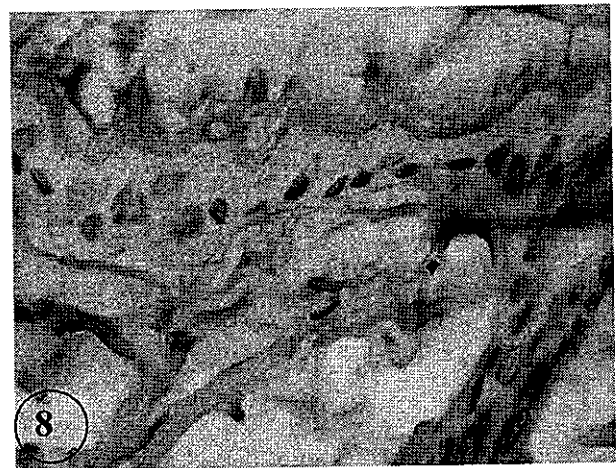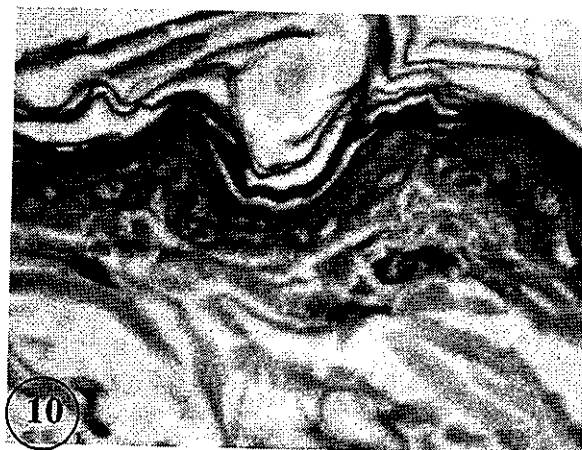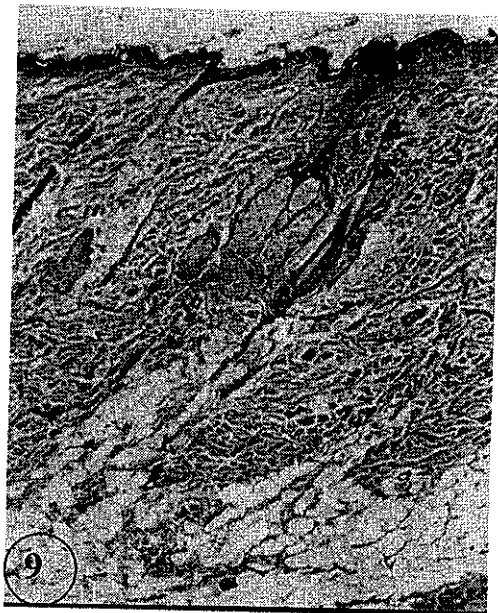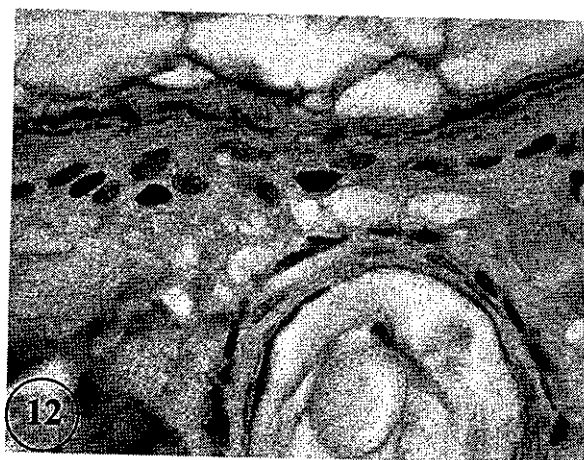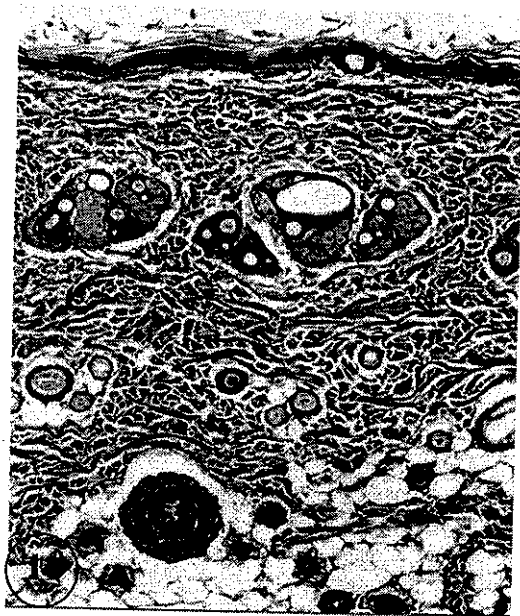


Fig.( 8): Showing reduced immunolabelling with PCNA in the epidermal layer. (EMF exposed group, Avidin-biotin peroxidase complex stain with Mayer's haematoxylin counter stain X1000).



**Fig.(9):** Showing apparently normal skin layers, regenerating sebaceous glands. Fat cells in the hypodermis reappear. (EMF+ vitamin A group, H&E X100).

**Fig.(10):** Showing more or less normal keratinocytes. (EMF+ vitamin A group, H&E X1000).



**Fig.(11):** Showing nearly normal collagen fibers. (EMF+ vitamin A group Masson's trichrome X100).

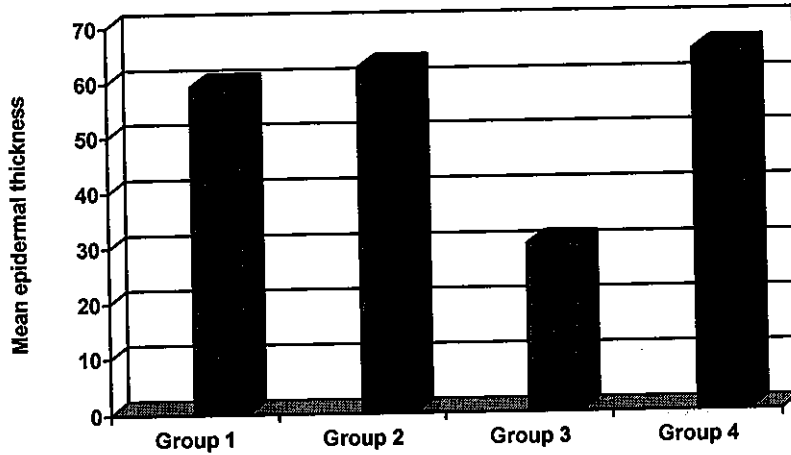
**Fig.(12):** Immunolocalization of PCNA in the epidermis following TV exposure and vitamin A treatment. Note the increase of PCNA reaction in the nuclei of epidermal cells. (EMF+ vitamin A group Avidin-biotin peroxidase complex stain with Mayer's haematoxylin counter stain X 1000)



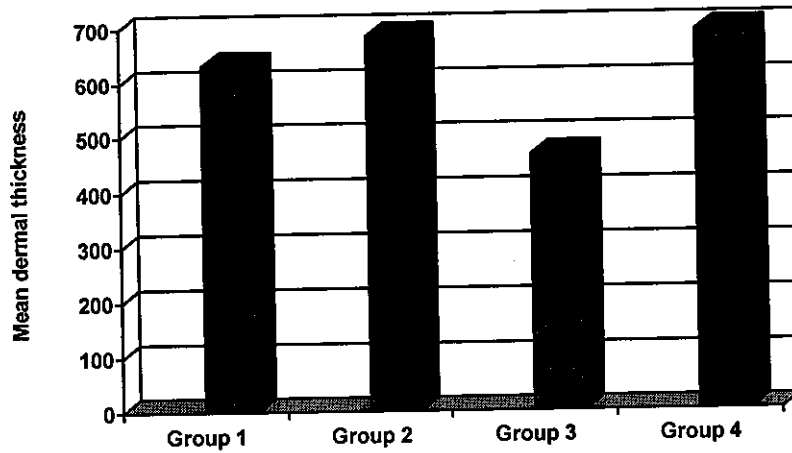
**Protective Effect of Vitamin "A" Against Skin Injury.....**

**Table (1): showing mean epidermal and dermal thickness.**

	No.	Mean epidermal thickness	SD	No.	Mean dermal thickness	SD
Group 1	5	59.2761	7.8542	5	633.3558	12.2396
Group 2	5	62.4852	5.7639	5	684.9753	10.1683
Group 3	5	30.2524	3.4641	5	465.7734	20.4218
Group 4	5	65.2538	2.3583	5	691.6276	16.7254



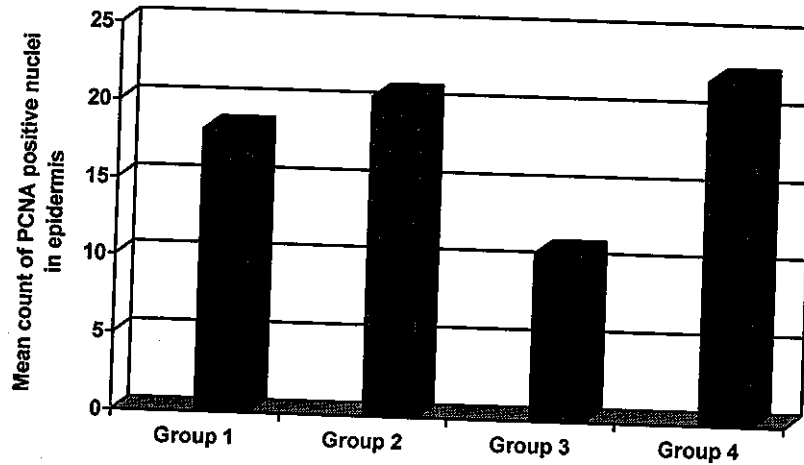
**Histogram (1): showing mean epidermal thickness**



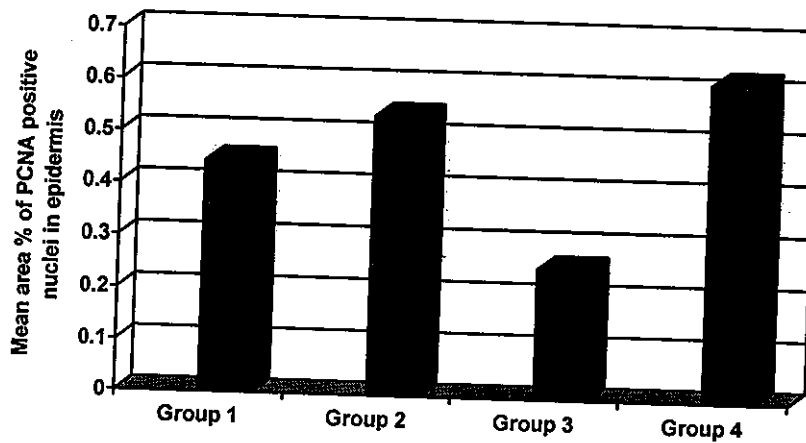
**Histogram (2): showing mean dermal thickness.**

Table (2): showing the mean area% and mean count of PCNA positive cells in the epidermis

	No.	Mean area%	S.D.	No.	Mean count	S.D.
Group 1	5	0.444758	0.108453	5	18.20000	2.949576
Group 2	5	0.5379	0.215236	5	20.60000	3.047359
Group 3	5	0.253574	0.131623	5	10.80000	1.923538
Group 4	5	0.613541	0.091637	5	22.20000	1.788854



Histogram (3): Mean count of PCNA positive nuclei in the epidermis of the studied groups.



Histogram (4): Mean area% of PCNA positive nuclei in the epidermis of the studied groups

## Discussion

Normal human skin is covered with stratified epithelium composed mostly of keratinocyte cells, which undergo a continuous process of proliferation, differentiation, and apoptosis. Within the epidermis, keratinocytes are not a homogeneous population, but they differ in proliferative capacity and state of differentiation. Keratinocytes are constantly exposed to the damaging and carcinogenic effects of UV radiation (Fuchs, 1990).

In this study, long time exposure to EMF reduced the thickness of all skin layers, hairs were short, fine and easily detached, and their color changed to yellow. Apoptosis was observed in the nuclei of the keratinocytes more than the control group. The hair follicles were damaged and replaced with horn-containing cysts. Sebaceous glands were atrophied.

In agreement with our results Ishida-Yamamoto *et al.*(1999); Kulms *et al.*(2002) and Chaturvedi *et al.*(2005) proved in their studies that, apoptosis in keratinocytes is required for epidermal turnover, stratum corneum formation, and removal of ultraviolet-damaged premalignant cells. Also they added that, keratinocytes exposed to UV light undergo cell death but basal and differentiated keratinocytes differ in their response to this insult and that UV-induced apoptotic cells which they call ("sunburn cells") appeared within 12 hours and are predominately located in the suprabasal, differentiated keratinocyte compartment of keratinocytes. So keratinocyte apoptosis represents an important response to the environmental injury caused by UV radiation.

Ziegler *et al.* (1994) and de Gruijl (2000) proved that apoptosis of keratinocytes that have sustained UV-induced DNA damage represents a key protective mechanism against squamous cell carcinoma by removing premalignant cells that have acquired mutations. They also proved that UV rays induce damage to keratinocytes through three mechanisms: direct DNA damage, death receptor activation, and reactive oxygen species formation. Also

Kulms *et al.* (2002) added that, the primary mediator responsible for removing UV-induced DNA damage of keratinocytes in skin is believed to be p53 which activates downstream genes and subsequently induces cell-cycle arrest in the G1-S phase to repair DNA mutations. They added that, if the cells have excessive unrepaired DNA damage, a process that leads to fragmentation of the DNA is initiated and apoptotic sunburn cells are formed. In this way, apoptosis is considered to act as a crucial mechanism for the elimination of keratinocytes damaged by UV irradiation. Easterly (1981) and Adey(1990b) proved that EMFs caused alteration of mitotic processes and dysfunction of cell membranes of keratinocytes that led to apoptosis.

The observed reduced thickness of skin layers may be due to the increased apoptosis of keratinocytes. Also the degeneration of collagen fibers of the dermis and adipocytes of the hypodermis caused reduction of the thickness of the dermis and hypodermis.

The exact mechanisms of hair falling and destruction of skin appendages are not known. Most probably hair follicle damage and necrosis of skin appendages led to brittle easily removable hair.

In the present results, adipocytes in the lower dermis and hypodermis disappeared. Hiroaki *et al.* (1999) supported this finding in their experiment and noticed that UV rays penetrated into the lower dermis and caused photodamage there. Also UV irradiation resulted in the disappearance of adipocytes in the lower dermis and subsequently fibroblasts migrate into the resultant spaces and proliferate and the adipose tissue changes into fibrous tissue.

Results of the present study, showed that collagen fibers in the dermis were thickened and disorganized. Varani *et al.* (1994) in their study explained that collagen synthesis is low in UV exposed skin. Also Fisher *et al* (1977), observed in their study that collagenase increased in UV irradiated skin. While Varani *et al.* (2001) observed that, UV irradiation caused necrosis of

fibroblast cells and collagen contraction and fragmentation. These changes inhibited fibroblast functions, cell growth and type I procollagen production. In addition Lin & Grinnell (1993) study showed that UV irradiation caused fibroblast shape change from elongated to round and caused degradation of collagen fibers. Also they proved that, the optimal fibroblast function depend on maintenance of the elongated cell shape. Failure to replace damaged collagen with newly synthesized collagen contributes to the progressive degenerative changes that occur in the connective tissue of UV exposed skin (Griffiths *et al.*, 1993).

In the present study, EMF exposure was associated with a decrease in the number of proliferating cell nuclear antigen and the mean area percent of PCNA positive nuclei in the epidermis. This finding may be attributed to the increased apoptosis observed in this group.

On giving vitamin A with EMF exposure, the epidermis and dermis restored their nearly normal thickness. The hair follicles and sebaceous glands began to regenerate. The collagen fibers restored their normal thickness and arrangement. PCNA reaction was more or less around the normal levels.

These findings are in agreement with the studies of Mrass *et al.* (2004) who stated that, vitamin A treatment sensitizes keratinocytes to apoptosis induced by UV radiation. This proapoptotic effect is accompanied by induction of the tumor suppressor protein p53 and the induction of proapoptotic caspases. They also added that chronic UV irradiation induces fibrosis in the lower dermis which was effectively prevented by vitamin A.

Fisher *et al.* (2002) explained in their studies that, retinoic acid induced the production of type I and type III procollagen gene expression in the skin. They added that retinoic acid also induced transforming growth factor  $\beta$  (TGF- $\beta$ ) which induced the production of type I and III procollagen and other components of the dermal extracellular matrix.

## References

1. Adey WR (1981): Tissue interactions with nonionizing electromagnetic fields. *Physiol. Rev.*, 81: 435-514.
2. Adey WR (1990a): Joint actions of environmental nonionizing electromagnetic fields and chemical pollution in cancer promotion. *Environmental Health Perspectives*, 86: 297-305.
3. Adey WR (1990b): Electromagnetic Fields, Cell Membrane Amplification, and Cancer Promotion. In *Extremely Low Frequency Electromagnetic Fields: the question of cancer*. Wilson BW, Stevens RG, Anderson LE, eds. Columbus, OH: Battelle Press, London, New York, p 211-249.
4. Altucci L, and Gronemeyer H (2001): The promise of retinoids to fight against cancer. *Nat. Rev. Cancer*, 1:181-193.
5. Armitage P, and Berry G (1994): *Statistical Methods in Medical Research*, 3<sup>rd</sup> ed. Blackwell Scientific Publications, London. p 40.
6. Bancroft J D and Stevens A (1996): *Theory and Practice of Histological Techniques*, 4<sup>th</sup> ed. Churchill Livingstone, Edinburgh, London. pp. 100-104.
7. Celis J E, Adsen P, Nielson S, and Celis A (1986): Nuclear patterns of cyclin (PCNA) antigen distribution subdivide S-phase in cultured cells-some applications of PCNA antibodies. *Leuk. Res.*, 10:237-249.
8. Chang J H, Seo J Y, Lee M K, Eun H C, Lee J H, Kang S, Fisher G J, and Voorhees J. J. (2002) : Ultraviolet modulation of human macrophage metalloelastase in human skin in vivo. *J. Invest. Dermatol.*, 119: 507-512.
9. Chaturvedi V, Sitailo L A, Qin J Z, Bdner B, Denning M F, Curry Y, Zhang W, Brash D, and Nickoloff B J (2005): *Oncogene*, 24: 5299-5312
10. de Gruijl F R (2000): Photocarcinogenesis: UVA vs UVB. *Methods Enzymol.*, 319: 359-366
11. Delpizzo V (1990): A model to assess personal exposure to ELF magnetic fields from common household sources. *Bioelectro-magnetics*, 11:139-47.
12. Easterly CE (1981): Cancer link to magnetic field exposure: a hypothesis. *Am. J. Epidemiol.*, 114:169-74.
13. Eid, F and Al-Dossary AA (2007): Ultrastructural, histological and

- histochemical study of the effect of electromagnetic field on the kidney cortex of pregnant rats and their fetuses. *The Egyptian Journal of Hospital Medicine*, 28:306-326.
14. -Fisher GJ, Wang Z-Q, Datta SC, and Varani J (1977): Pathophysiology of premature skin aging induced by ultraviolet light. *N. Engl. J. Med.*, 337: 1419-1426.
  15. -Fisher GJ, Kang S, Varani J, Bata-Csrogo Z and Voorhees J (2002): Mechanisms of photoaging and chronological skin aging. *Arch. Dermatol.*, 138:1462-1570.
  16. Frolen H, Svedenstal, B M, and Bierke B (1987): Repetition of a study of the effect of pulsed magnetic fields on the development of fetuses in mice. Final Report to Swedish National Institute of Radiation Protection, Project 346, 386.
  17. Fuchs, E. (1990): Epidermal differentiation: the bare essentials. *J. Cell Biol.*, 111: 2807-2814
  18. Griffiths CEM, Russman G, and Hamilton TA (1993): Restoration of collagen formation in photoaged human skin by tretinoin (retinoic acid) *N. Engl. J. Med.*, 329:530-329543.
  19. Hall PA, Levison DA, Woods AL, Yu CC, Kellock DB, Watkins JA, Bames DM, Gillett CE, Camplejohn R, Dover R, Waseem NH, and Lane DP (1990): Proliferating cell nuclear antigen (PCNA) immunolocalization in paraffin sections: an index of cell proliferation with evidence of deregulated expression in some neoplasms. *J. Pathol.*, 162:285-262.
  20. Hallberg O, and Johansson O (2004): Malignant melanoma of the skin- not a sunshine story. *Med. Sci. Monit.*, 10(7): 336- 340.
  21. Hiroaki M, Ichiro K, Hidenao T, Toshihiko T, and Toshio I (1999): Alterations of hairless mouse skin exposed to chronic UV irradiation and its prevention by hydrocortison. *Photochemistry and Photobiology*, Web site : [http:// findarticles.com/p/ articles/mi\\_qa3931/is\\_199901/ai\\_n8837933](http://findarticles.com/p/articles/mi_qa3931/is_199901/ai_n8837933)
  22. Ishida-Yamamoto A, Tanaka H, Nakane H, Takahashi H, Hashimoto Y, and Iizuka H (1999): Programmed cell death in normal epidermis and lorcin keratoderma. multiple functions of roclaggrin in keratinization. *J. Invest. Dermatol. Symp. Proc.*, 4:145-149.
  23. Koike M, Ninomiya Y, and Koike A, (2005): Characterization of ATF3 induction after ionizing radiation in human skin cells. *J. Radiat. Res.*, 46(4): 379- 385.
  24. Kraemer KH, DiGiovanna JJ, Moshell AN, Tarone RE, and Peck GL. (1988): Prevention of skin cancer in xeroderma pigmentosum with the use of oral isotretinoin. *N. Engl. J. Med.*, 318:1633-1637.
  25. Kulms D, Zeise E, Poppelmann B, and Schwarz T (2002): DNA damage, death receptor activation and reactive oxygen species contribute to ultraviolet radiation-induced apoptosis in an essential and independent way. *Oncogene*, 21:5844-5851.
  26. -Lin Y-C, and Grinnell F (1993): Decreased level of POGV-stimulated receptor autophosphorylation by fibroblasts in mechanically relaxed collagen matrices. *J. Cell Biol.*, 122: 663-672.
  27. Lotan R (1996): Retinoids in cancer chemoprevention. *FASEB J.*, 10:1031-1039.
  28. Michelozzi P, Capon A, and Kirchmayer U (2002): Adult and childhood leukaemia near a high power radio station, *Am. J. Epidemiol.*, 155: 1096- 1103.
  29. Milham S (1985): Mortality in workers exposed to electromagnetic fields. *Environ. Health Perspect.*, 62: 297-300.
  30. Mrass P, Rendl M, Mildner M, Gruber F, Lengauer B, Ballaun C, Eckhart L, and Tschachler F (2004): Retinoic acid increases the expression of p53 and proapoptotic caspases and sensitizes keratinocytes to apoptosis: a possible explanation for tumor preventive action of retinoids. *Cancer Research*, 64: 6542-6548.
  31. Murphy G, A R, Wulf H C, Kulms D, and Schwarz T (2001): The molecular determinants of sunburn cell formation. *Exp. Dermatol.*, 10: 155-160.
  32. Repacholi MH (1997): Radiofrequency field exposure and cancer: what do the laboratory studies suggest? *Environmental Health Perspectives*, 105(6): 1565- 1568.
  33. Sano T, Kume T, Fujimura T, Kawada H, Moriwaki S, and Takema Y, (2005): Ultraviolet B light stimulates interleukin-20 expression by human epithelial keratinocytes. *Arch. Dermatol. Res.*, 296: 359-365.
  34. Savitz D A, Wachtel H, Barnes F A, John E M, and Tvdrick J G (1988): Case-control study of childhood cancer and exposure to

- 60-Hertz magnetic fields. *Am. J. Epidemiol.*, 128: 21-38.
35. **Sesto A, Navarro M, Burslem F and Jorcano JL, (2002):** Analysis of the ultraviolet B response in primary human keratinocytes using oligonucleotide microarrays. *PNAS*, 99(5): 2965- 2970.
36. **Soprano DR, Qin P, and Soprano KJ (2004):** Retinoic acid receptors and cancers. *Annu. Rev. Nutr.*, 24: 201-221.
37. **Stevens RS, Scott D, and Thomas DB (1992):** Electric power, pineal function, and the risk of breast cancer. *FASEB*, 6:853-860.
38. **-Tenforde TS. (1992):** Biological interactions and potential health effects of extremely-low-frequency magnetic fields from power lines and other common sources. *Ann. Rev. Public Health.*, 13:173-196.
39. **Varani J, Prone P, and Griffiths CEM (1994):** All-trans retinoic acid (RA) stimulates events in organ cultured human skin that underlie repair. *J. Clin. Invest.*, 94: 1747- 1753.
40. **-Varani J, Spearman D, and Prone P (2001):** Inhibition of type I procollagen synthesis by damaged collagen in photoaged skin and by collagenase-degraded collagen in vitro. *Am. J. Pathol.*, 158:931-942.
41. **-Zakland Z, Fizycznych I, and Medycyny P L (1991):** Extremely low frequency electromagnetic fields in human environment and the risk of cancer in the light of epidemiological studies based on the literature. *Med. Pr.*, 42(5):373-80.
42. **Ziegler A, Jonason A. S, Leffell D J, Simon J A, Sharma H W, Kimmelman J, Remington L, Jacks T, and Brash D E (1994):** Sunburn and p53 in the onset of skin cancer. *Nature*, 372: 773-776.

التأثير الوقائي لفيتامين أ ضد الأضرار التي تصيب الجلد بسبب التعرض للموجات الكهرومغناطيسية

دراسة هستولوجية و هستوكيميائية

منى عبد الرحمن سالم

قسم الهستولوجي كلية طب البنات جامعة الأزهر

تعتبر المجالات الكهرومغناطيسية من أهم الأخطار البيئية الرئيسية على صحة البشر وسائر الكائنات الحية. وهذه الموجات تحيط بنا في كل مكان حولنا. وتنبعث هذه الإشعاعات الكهرومغناطيسية من الراديو والميكروويف وخطوط الضغط العالي والتليفون المحمول ومحطات التقوية الخاصة به وأجهزة التليفزيون والعديد من الأجهزة الأخرى. يعتبر فيتامين أ منظم لتجديد الخلايا وتميزها كما ينظم عملية الموت المبرمج للخلايا ويعتبر أيضا علاج لمجموعة واسعة من الأمراض الجلدية.

والهدف من هذا البحث هو دراسة التأثير الوقائي لهذا الفيتامين ضد الأخطار المترتبة على المدى الطويل للتعرض للموجات الكهرومغناطيسية ذات الترددات المنخفضة المنبعثة من جهاز التلفزيون الملون كواحد من الأجهزة المنزلية التي تستخدم لفترات طويلة من الوقت يوميا على جلد الجرذ الأبيض وخاصة أن العديد من الرجال والنساء والأطفال صغار السن يجلسون لساعات طويلة أمام أجهزة التليفزيون.

واستخدم في هذه الدراسة عشرون جرذ أبيض ذكور ناضجة. تم تقسيمها إلى 4 مجموعات متساوية، المجموعة الأولى الضابطة، والمجموعة الثانية أعطيت فيتامين أ يوميا لمدة شهرين، أما المجموعة الثالثة فقد تعرضت للموجات الكهرومغناطيسية المنبعثة من جهاز التلفزيون الملون لمدة 6 ساعات يوميا لمدة شهرين أما المجموعة الرابعة فقد أعطيت فيتامين أ وتعرضت للموجات الكهرومغناطيسية يوميا لمدة شهرين كما في المجموعة الثالثة.

وقد أظهرت نتائج هذه الدراسة أن التعرض للموجات الكهرومغناطيسية لفترة طويلة نتج عنه نقص سمك جميع طبقات الجلد. وأوضح الفحص الظاهري أن الشعر أصبح قصير واكتسب اللون الأصفر كما كان سهل السقوط.

ولوحظ أيضا أن أنوية خلايا البشرة كانت بها تغيرات قد تؤدي إلى موت الخلايا أكثر من المجموعة الضابطة أما الألياف الكولاجينية في طبقة الأدمة فكانت غير منتظمة ومضغوطة مع تحطم بعض بصيلات الشعر التي تحولت إلى حويصلات كيراتينية كما اختفت الخلايا الدهنية الموجودة تحت الجلد. ولوحظ أيضا انخفاض متوسط مضادات النواة للخلايا المتكاثرية و أيضا مساحة الأنوية الإيجابية في خلايا البشرة مقارنة بالمجموعة الضابطة. ومع إعطاء فيتامين أ والتعرض للموجات الكهرومغناطيسية لوحظ اختفاء معظم التغيرات التي نتجت عن التعرض للموجات الكهرومغناطيسية حيث استعادت طبقة البشرة والأدمة سمكها الطبيعي تقريبا. كما استعاد الشعر لونه الطبيعي وسمكه وكثافته. كما ظهرت بصيلات الشعر والغدد الدهنية تستعيد طبيعتها. واستعادت الألياف الكولاجينية شكلها الطبيعي. كما زاد متوسط مضادات النواة للخلايا المتكاثرية و أيضا مساحة الأنوية الإيجابية في البشرة بالمقارنة بالمجموعة الضابطة وينتج من هذا البحث أن المعاملة بفيتامين أ أثناء التعرض لفترات طويلة للموجات الكهرومغناطيسية المنبعثة من جهاز التلفزيون الملون يحد من الآثار الضارة لهذه الموجات ولهذا أوصى بضرورة تناول فيتامين أ للجميع خاصة الأطفال حيث يجلسون أمام شاشات التلفزيون لساعات طويلة.