

قسم : الجراحة والولادة •

كلية : الطب البيطري - جامعة الاسكندرية •

رئيس القسم : أ.د. محمد بهجت عبدالرحيم نصير •

نقل قناة الغدة اللعابية النكفية جراحيا

في الكلب مع الاشارة الى استكشاف مسارها التشريحي

مصطفى قاسم ، محمد أمين

أجريت عملية نقل قناة الغدة النكفية جراحيا على خمسة عشر كلبا بثلاث طرق مختلفة لتثبيت حلمة القناة اللعابية في ملتحمة العين •

اتضح من البحث أن أنسب وأسهل وأحسن طريقة هو تثبيت الحلمة في الجانب الوحشي السفلي من ملتحمة العين بعد رفع القناة اللعابية من الأنسجة المحيطة بها وذلك من الجانب الخارجي من الخد • ولتحديد مسار القناة اللعابية يفضل ادخال قسطرة رفيعة من خلال فتحة القناة اللعابية الموجودة في الجانب الداخلي من الخد أمام الضرس الرابع العلوي •

وهذه الطريقة جعلت العين في رطوبة دائمة لامدادها بالسائل اللعابي المستمر الذي يشبه الدموع من تكوينه دون مضاعفات ويفضل اجراءها لعلاج جفاف قرنية وملتحمة العين •

Dept. of Surgery & Theriogenology,
Fac. of Vet. Med., Asexandria Univ.,
Head of Dept. Prof. Dr. M. Bahgat Noseir.

**PAROTID DUCT TRANSPOSITION IN A DOG
WITH SPECIAL REFERENCE TO ITS SURGICAL EXPOSURE**
(With 3 Figures and One Table)

By
M.M. KASSEM and M.E. AMIN
(Received at 20/6/1987)

SUMMARY

The present work concluded that the most suitable seat for fixation of the parotid papilla, was the lateral conjunctival fornix. Ample space was present for fixation of the papilla and the applied stitches are far away from the cornea. The ventral conjunctival fornix was also suitable for fixation of parotid papilla. The fixation of the parotid duct to the upper conjunctival fornix was a difficult procedure, needs more subcutaneous dissection and end with twisting and obstruction of the transported parotid duct in dogs.

INTRODUCTION

Parotid duct transposition was first used in Human beings in 1950 by Filatov, who reported successful cases in Asia as well as other parts of the world. The operation of the parotid duct transposition was first reported in experimental dogs in 1959 in Japan. Different techniques for parotid duct transposition have been reported, (GLEN and LAWSON, 1971; MAGRANE, 1971; GELATT, 1981 and BEDFORD, 1984).

The surgical anatomy of the parotid duct of the dog has been discussed by HABEL (1973) and BERG (1974). The course of the parotid duct in the anaesthetized dog has also been demonstrated by sialography (CHRISTOPH, 1956; HARVEY, 1969 and BELL, 1978). McCARTHY (1978) was the only author who reported the possibility of palpating the parotid duct in a living Greyhound.

The aim of the present study is to compare and evaluate the various techniques for transposition of the parotid duct to the conjunctival fornix of the eye.

MATERIAL and METHODS

In the present work six adult dogs of both sexes, were used at the department of anatomy for palpation and detection of the parotid duct. Animals were tape muzzled and tranquilized with Combelen 0.05 ml/Kg.b.wt. before palpation. Dissections using routine technique were made on the facial regions of the aforementioned dogs after they had been formalized, in order to measure the length of the parotid duct and the distance :

- 1- From the parotid gland to the middle of the lower conjunctival fornix.
- 2- From the parotid gland to the lateral canthus of the eye.
- 3- From the parotid gland to the middle of the upper conjunctival fornix.

On the other hand 15 adult dogs of both sexes weighting 15-25 kg. were subjected to experimental parotid duct transposition to the conjunctival fornix with different techniques of fixation for the parotid duct papilla at the conjunctival fornix.

KASSEM and AMIN

Each animal was thoroughly examined for the efficiency of its parotid gland and for duct abnormalities or obstructions. The papilla of parotid duct is immediately present adjacent to the caudal aspect of the upper P4 cheek tooth (carnassial). Parotid gland function can be stimulated by few drops of 1% atropine sulphate solution applied to the tongue of the animal.

Pre-operative technique was performed after securing and tranquilization of each animal with Combelen in a dose of 0.05 mg/Kg,b.w.t. intramuscularly. This was followed by I.V. administration of thiopental sod. (Nesdonal)* until the main reflexes were abolished.

Catheterization of the parotid duct :

The oral mucous membrane was washed with normal saline solution. A special catheter (epidural catheter**) was introduced through the orifice of the parotid duct. This was facilitated by drawing the buccal mucous membrane by means of non-toothed ordinary forceps (Fig. A). The parotid papilla was adjacent to the carnassial tooth of the upper jaw. Careful introduction of the catheter was performed until it reached the parotid gland. The catheter was fixed to buccal mucous membrane with an artery forceps. The parotid duct can now be easily palpated from lateral aspect of the cheek.

Surgical procedure :

The lateral aspect of the cheek was prepared for aseptic operation as usual. A skin incision was made along the course of parotid duct beginning from its origin at parotid gland toward the parotid papilla. The incision passed through the subcutaneous tissues and superficial facial muscles. The parotid duct is carefully dissected from the masseter muscle and retracted by a silk thread No. 2 passed around it. The thread is also used to elevate the duct from the area of dissection by the aid of an assistant. The duct is dissected caudally to the angle of the mandible rostral to the parotid papilla.

Separation of the parotid duct from the masseter muscle is continued rostrally, one must avoid the facial vein and the dorsal or ventral branches of the buccal nerve. The parotid duct usually continues for about 0.5 to 1 cm submucosally before terminating in the papilla. An incision around the parotid papilla is made through the buccal mucosa, from inside the cheek, freeing the papilla from the rest of the oral mucous membrane (Fig. B). The opening of the buccal mucosa into the mouth is then closed with simple interrupted sutures using chromic catgut (2/0).

The palpebral fissure is widely separated by eyelid dilator. The parotid papilla is fixed to the conjunctival fornix in three situations :

- 1- Lower conjunctival fornix.
- 2- Ventrolateral conjunctival Fornix (Fig. C).
- 3- Upper conjunctival Fornix.

A flossa needle was inserted into conjunctival fornix at one of the aforementioned positions and was pushed subcutaneously with great care until it reached the level of the parotid gland. The parotid papilla was fixed to the opening of the flossa needle and then withdrawn to the conjunctival sac. The parotid papilla was sutured into conjunctival fornix

* : Nesdonal (Thiopental sodium) - Specia - Paris.

** : Epidural catheter (Braun mel surgen Ag. West Germany).

PAROTID DUCT TRANSPOSITION

with four simple interrupted sutures using atraumatic needle with 4/0 chromic catgut placed at 12, 3, 6 and 9 O'clock. The epidural catheter was withdrawn and the facial skin wound was closed in a routine manner (Fig. D).

Post-operative care :

The eye of the same side of operation is carefully flushed with cleaning solution in the morning following surgery. It is probably advisable during the first few days post-operation to divide the food intake into several small meals, as this will ensure the flow of parotid secretion. A drop of 1% ophthalmic atropine solution applied to the tongue to ensure and measure the patency of the transported duct as well as to remove the debris from it, or its papilla, associated with the trauma of surgery and cannulation. Skin stitches were removed 10 days after operation.

RESULTS

In the present work, it was possible to feel the massetric part of the parotid duct after tranquillization of dogs. The parotid duct lie on the lateral surface of the ventral third of the masseter muscle, it can be palpated by ball of the thumb. The duct can be moved in ventro-dorsal direction using light to moderate pressure exerted against the skin surface. In addition the buccal part of the duct could be felt by placing the tip of the index finger in the caudal part of the buccal vestibule of the appropriate side and passed laterally against the buccal mucosa immediatly rostral to the prominent rostral border of the masseter muscle simultaneously and the ball of the thumb placed on the buccal skin surface overlying the tip of the index, with a rostro-ventral movement. The parotid duct can be differentiated from the dorsal buccal nerve after dissection, by its thickness and hardness, while the nerve appears to more flattened, less prominent and situated dorsally.

In this study, it was cleared that the length of the parotid duct is longer than the distance from the parotid gland to the middle of the lower conjunctival fornix and the distance from that gland to the lateral canthus of the eye, but it is shorter than the distance from the parotid gland to the middle of the upper conjunctival fornix, (Table 1).

Most of the operated animals suffered from facial oedema for a few days following operation. This oedema subsided one week after surgery. In few cases, mucoid discharge was observed in the eye for about one or two days post operation, but this discharge disappeared after local and systemic application of antibiotics. Healing of the facial wound took place by first intention without any complications.

TECHNIQUE (1) :

In this technique the parotid papilla was implanted into the middle of the lower conjunctival fornix (Fig. 1). It was found that the parotid secretion increased in the eye during mastication of the food or after application of 1% atropine sulphate solution on the dorsum of the tongue, in operated animal.

TECHNIQUE (2) :

In this method the parotid papilla was fixed into the ventrolateral conjunctival fornix (Fig. 2). It is the shortest way for parotid duct transposition, and it proved to be safe for less subcutaneous distruction, and minimal corneal irritation. In addition this method, kept the effeciency of the duct for transportation of the parotid secretion to the eye for continuous lubrication of the corneal surface. The function of the duct was not interrupted for six months.

TECHNIQUE (3):

In this technique the parotid papilla was implanted into the middle of the upper conjunctival fornix, (Fig.3). It was cleared that this method is not satisfactory, because it produced more subcutaneous distruption and massive oedema for long time. The function of the duct continued normally about 3 days, but the salivary secretion did not lubricate the corneal epithelium in a proper way. Obstruction of the transplanted duct took place after a short period ranging from 5-7 days.

DISCUSSION

Parotid duct transposition is indicted in cases of lacrimal gland insufficiency resulting in keratoconjunctivitis sicca. There is a close similarity between lacrimal and parotid secretions thus providing the conjunctival and corneal surfaces with a constant source of the corneal tear like film (BEDFORD, 1984; MAGRANE, 1971 and PHILLIS, 1976).

In the present work, transposition of the parotid duct in the dog, from the lateral aspect of the cheek with fixation of the parotid papilla at the ventrolateral conjunctival fornix proved to be the more suitable and safe method, because the portion of the duct dissected free was found to be long enough to reach the lateral canthus of the eye without stretching or twisting. These results are in agreement with that obtained by GLEN and LAWSON (1971). In addition this technique provides less subcutaneous distruption and minimal corneal irritation. It is advisable to use this method for the treatment of keratoconjunctivitis following failure to obtain cure after 4-6 weeks trial of medical therapy (GELATT, 1973).

Fixation of the parotid papilla to the lower conjunctival fornix was also suitable, but trauma to the cornea may result by the suture knots used for fixation of the papilla, Moreover fixation of the parotid papilla to the upper conjunctival fornix resulted in obstruction of the duct due to its twisting and overstretching.

Determination of the course of the parotid duct before surgical operation in living dogs was somewhat difficult by digital palpation. It can be easily identified by introducing a fine catheter through the parotid papilla located 1.5-2 cm proximal to the alveolar border of the caudal half of the carnassial (P4) tooth. Although HOFFMANN (1951) stated that the papilla can be pushed away from its original site in the living dog, this produce a further difficulty in locating it, yet the parotid papilla was easily reached, where a catheter was freely introduced slowly in the present work.

REFERENCES

- Bedford, P.G.C. (1984): Atlas of canine surgical techniques. 1st Ed. British Small Animal Veterinary Association, Oxford, London Edinburgh.
- Bell, D.A. (1978): A grass seed in the parotid duct of a dog. *Vet. Rec.*, 102, 340.
- Berg, R. (1974): *Angewandte und topographische Anatomie der haustiere* Gustav Fisher, Jena.
- Christoph, H.J. (1956): Zur Erkrankung der speicheldrüsen und deren Ausführungsgänge beim Hund. *Berl. Munch Tierarztl. Wschr.*, 69, 227-231.
- Gelatt, K.N. (1973): Keratoconjunctivitis sicca in a dog. *VM/SAC*, July, 767.
- Gelatt, K.N. (1981): *Textbook of Veterinary Ophthalmology*. Published in Great Britain by Balliere Tindell, London printed in USA.
- Glen, J.B. and Lawson, D.D. (1971): A modified technique of parotid duct transposition for the treatment of keratoconjunctivitis sicca in the dog. *Vet. Rec.*, Vol. 88, 210.
- Habel, R.E. (1973): *Applied Veterinary Anatomy*. Robert E Habel, Thaca, N.Y.
- Harvey, C.E. (1969): Sialography in the dog. *Journal of Am. Vet. Radiol. Soc.*, 10, 18-27.

PAROTID DUCT TRANSPOSITION

- Hoffmann, G. (1951): Zur topographie der parotisgangmundung beim Hund. *Mh. Vet. Med.* 16, 320.
- Magrane, W.G. (1971): *Canine Ophthalmology* 2nd Ed. Lea & Febiger, Philadelphia, USA.
- McCarthy, P.H. (1978): The Anatomy of the parotid duct (ductus parotideus) of the Greyhound as appreciated by the sense of touch. *Zbl. Vet. Med. C. Anat. Histol. Embryol.*, 1, 311-319.
- Phillis, J.W. (1976): *Veterinary Physiology*. Bristol Wright-Scientechica.

Table (1)

Measurement the length of the parotid duct, the distance from parotid gland and the middle of the lower conjunctival fornix, lateral canthus and the middle of the upper conjunctival fornix

Sex	No.	Length of the parotid duct	Lower	Distance from the parotid gland to		
				C. Fornix Lateral	C. Upper	C. Fornix
Femal	1	9.0	8.6	8.8	9.3	Cm
	2	8.5	8.0	8.0	8.9	Cm
	3	7.5	6.9	7.1	8.0	Cm
Male	4	10.0	9.4	9.6	10.4	Cm
	5	9.7	9.0	9.2	10.2	Cm
	6	9.3	8.8	9.0	9.9	Cm

LEGENDS

- Fig. A. :** Cannulation of the parotid duct with polyethylene epidural catheter. Showing the position of parotid papilla in the relation to the 4th upper cheek tooth (cranial).
- Fig. B. :** The parotid duct has been dissected from underlying masseter muscle. Its papilla (arrow) has been excised from the mouth).
- Fig. C. :** The papilla has been sutured into the ventrolateral conjunctival fornix.
- Fig. D. :** The facial wound 10 days post operation.
- Fig. E. :** Dissection the lateral aspect of the cheek in a dog:
- (1) Dorsal buccal nerve.
 - (2) Parotid salivary gland.
 - (1') Parotid duct (Masseteric part).
 - (2') Parotid duct (Buccal part).
 - (3) Ventral buccal nerve.
 - (4) Facial vein.
 - (5) Maxillary labial artery.

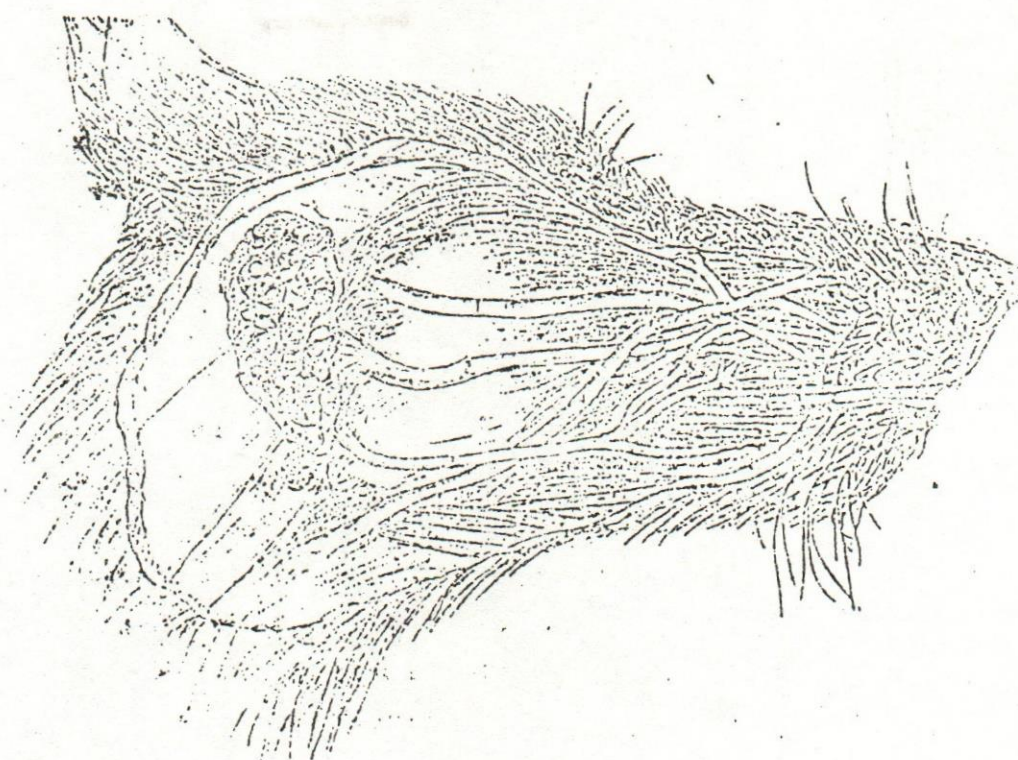


Fig. (E)

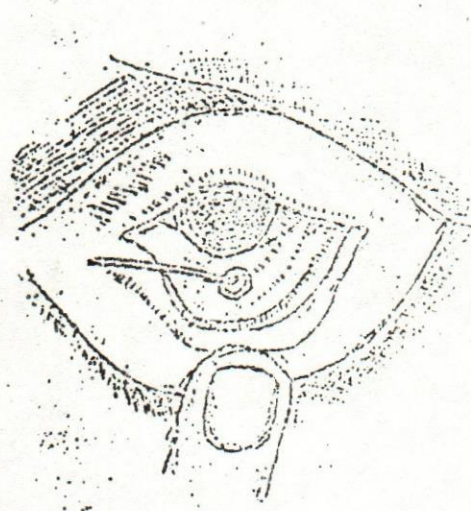


Fig. (1)

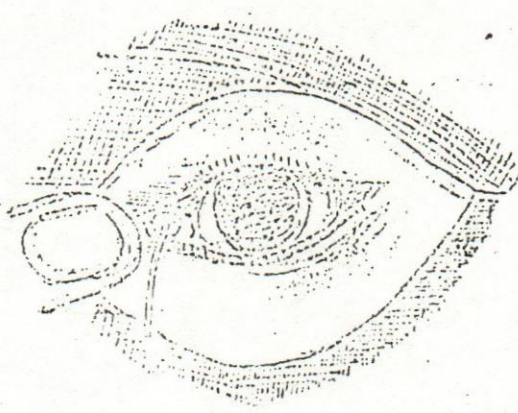


Fig. (2)

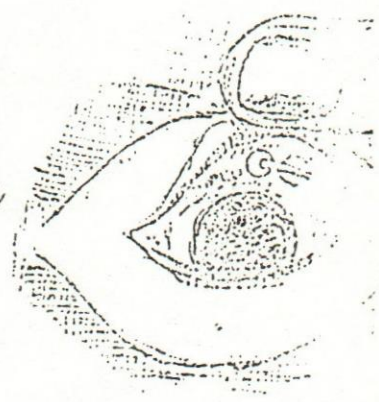


Fig. (3)

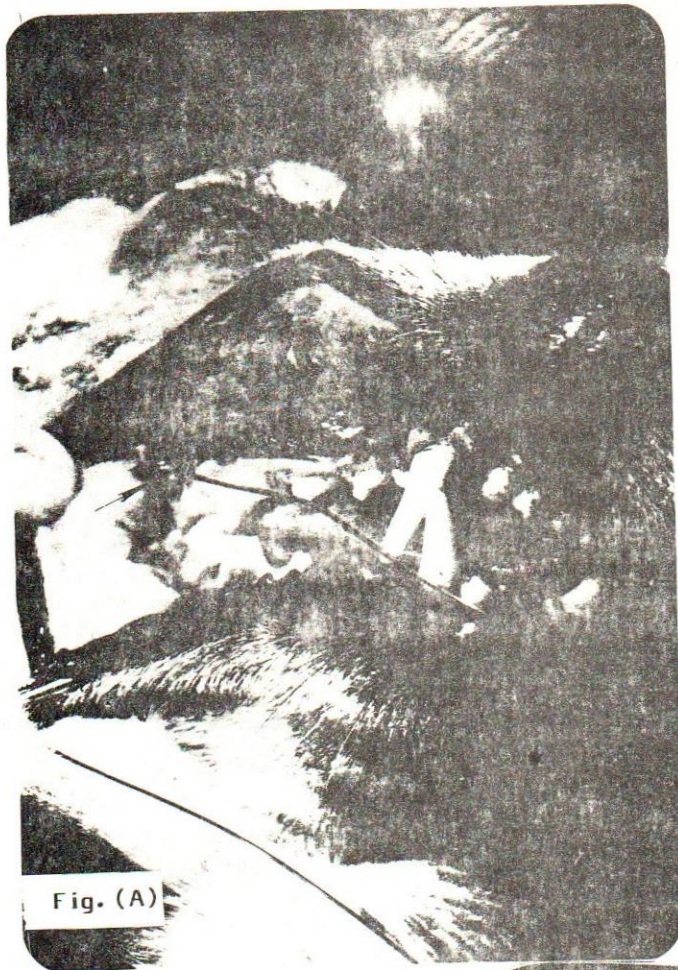

Fig. (A): Cannulation of the paroti duct with polyethylene epidural catheter. Showing the position of parotid papilla in the relation to the 4th upper cheek tooth (craniasial).

Fig. (B): The parotid duct has been disected from underlying masseter muscle. its papilla (arrow) has been excised from the mouth.




Fig. (B)




Fig. (C)

Fig. (C): The papilla has been sutured into the ventrolateral conjunctival fornix.

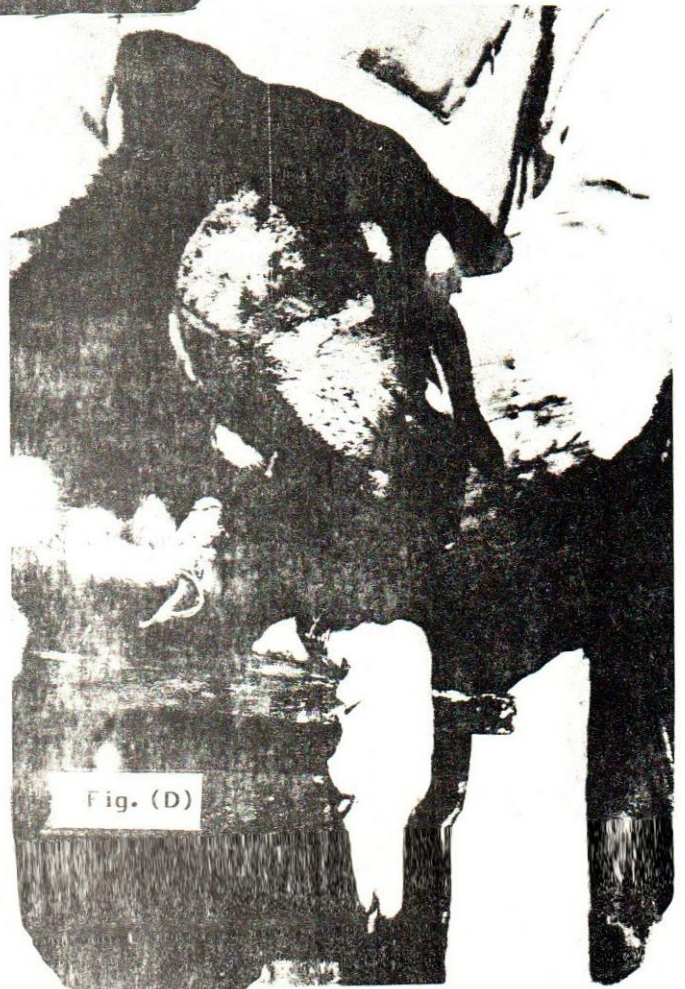

Fig. (D)

Fig. (D): The facial wound 10 days post operation.