

قسم : التوليد والتلقيح الصناعي .
كلية : الطب البيطرى - جامعة الفاتح - طرابلس - ليبيا .
رئيس القسم : أ. د. / ممدوح عثمان .

سخطة مزدوجة في الضأن البرقي الليبي

ممدوح عثمان ، فؤاد عثمان

أجرى البحث على حالتين من الأجنة المشوهة من الضأن البرقي (السلالة الليبية المحلية) .

لقد كانت الحالة الأولى عبارة عن توأمين مقترنين متشابهين من ناحية الشكل والحجم ورأس واحدة ، وأوضحت الدراسة أن هذين الجنين كانا متحدين بداية من القصي الى الحبل السرى .

الحالة الثانية كانت عبارة عن سخطة ذات عمود فقرى منحنى مع وجود ازدواجية في عدد الأرجل وفتحة الشرج والأعضاء التناسلية الخارجية .

تم وصف الأعضاء الداخلية ومناقشة النتائج مع ما أتى الحصول عليه من مراجع في هذا المجال .

مكتبة جامعة القاهرة
القاهرة - مصر

رقم الكتاب: 1000

تاريخ النشر: 1980

كتاب: تاريخ مصر القديمة
(مجلد 1)

المؤلف: محمد مصطفى
الناشر: دار المعارف

عدد الصفحات: 300
عدد النسخ: 1000

حالة الكتاب: جيد
رقم التسجيل: 1000

Dept. of Obstetrics,
Faculty of Vet. Med., Alfateh University, Tripoli, Libya,
Head of Dept. Prof. Dr. A.M. Osman.

OVINE DOUBLE MONSTERS IN LIBYAN BARQI BREED (With 3 Figs.)

By
A.M. OSMAN and F.A. OSMAN
(Received at 1/2/1985)

SUMMARY

Two cases of double monsters from Barky (Libyan native breed) were studied.

The first monster appeared as a conjoined twin fetuses with single head and of nearly similar shape and size. The two foeti were joined ventrally from the manubrium sterni to the umbilical cord. The second monster appeared as a single foetus with curved vertebral column and double sets of fore limbs, hind limbs and two recti and double sets of external genitalia.

The monsters were photographed, radiographed and dissected. The observations are discussed in light of the available literature.

INTRODUCTION

Embryopathy as a modern term for diseases of the conceptus (ARTHUR; NOAKES and PEARSON, 1981) received the attention of many investigators in different animal species. ROBERTS (1971) cited that extensive non-genetic anomalies of the conceptus is called monster.

Double monsters were reported in swine (GREEN and MORGAN, 1958; HALNAN, 1970; SELBY; HOPPS & EDMOND, 1971 and HUSTON, SCHONWEISS and LEIPOLD, 1978) and in bovine (HANCOCK, 1954; ARTHUR, 1956 and LEIPOLD and DENNIS, 1980). The work published by DENNIS (1974 & 1980) denoted that conjoined twins or double monsters were not recorded in sheep.

The anatomy of two cases of ungainly shape double monsters was described in details as they differed more particularly from other cases recorded in other species.

MATERIAL and METHODS

Two cases of double monsters were brought to the clinic of the faculty from a local Barqi breed sheep farm. The owner said that both cases were delivered dead and without difficulty. Similar monsters have not been observed by the owner previously in his herd as well as in other neighbour herds. The anatomical descriptions of both cases were performed as usual. The second case was previously eviscerated by the owner. The two cases were photographed before dissection.

RESULTS

Case 1: (Fig. 1 & 2):

The monster appeared as a conjoined twin fetuses with single head and of nearly similar shape and size. They weighted 5 kg. and the crown rump length was 32 cm while the total length was 44 cm. The contour of the conjoined chest was 39 cm while that for each abdomen behind the umbilicus was 22 cm.

The two foeti were joined ventrally from the manubrium sterni to the umbilical cord which is common and has double set of blood vessels.

The apparently normal head has a normal face and two additional fused auricles (without external acoustic meatus) between the normal ears. Double set of forelimbs and hindlimbs were present. The forelimbs were somewhat displaced as a result of the duplication. After dissection, the foramen magnum was double, each with two occipital condyles. Thereafter, there were two vertebral columns directed laterally and caudally at the level of the thoracic region, where they were curved towards each other.

The duplicated thoracic cavity was large in size, rectangular in form and bounded by two vertebral columns, two sterni and two set of ribs. It was divided longitudinally with a membranous septum into right and left equal compartments. The cavity was limited caudally with an unusually shaped diaphragm. The numbers of vertebrae, sternae and ribs were normal for each fetus. Posterior to the level of the umbilicus, the two foeti were completely separated and appeared normal from morphological appearance.

Internally, the head region has a cleft palate and a longitudinally grooved tongue. There was a single larynx lead to a wide V-shaped tracheal groove that ends blindly after a short distance missing the tracheal cartilages.

Each compartment of the conjoined chest has a separately under-developed lung in which the cranial lobes were absent and the caudal lobes were suppressed. There were true and false hearts in the left and right compartments respectively. The true heart was relatively large and of normal morphological appearance. The false heart was represented only by complete pericardial sac but without cardiac tissue. The foramen ovale of the true heart was larger than normal.

The large blood vessels were in the form of double set connected with the true heart and appears normal in the abdominal region of both foeti.

The initial part of the oesophagus appeared as two tubes on the sides of the tracheal groove. At the caudal third of the neck they united to pass as a single tube through the thorax, piercing the diaphragm to open in a large atrium ruminis.

The reticulum and omasum were single, large and located at the right and left sides of the conjoined part of the abdomen respectively. The rumen expanded laterally in the form of a right and left large chambers with a single large abomasum in between. The latter has two pyloric canals, each of them lead to the corresponding duodenum. The remainder parts of the intestine were doubled and each one was normally arranged in its corresponding foetus without apparent abnormality.

There were two livers (large and small) located at the right side of the conjoined part of the abdominal cavity. The large one was irregularly quadrilateral in form with strongly convex diaphragmatic surface and two renal impressions (right and left). The small liver was flattened, more triangular and without renal impression. The gall bladder was normal in each liver.

OVINE DOUBLE MONSTERS

The urogenital organs were duplicated and appeared normal with regard to their position, size and morphological appearance. Both foeti were females with normally opened vagina in one foetus and closed one in the other.

Case 2: (Fig. 3):

In this case, the monster appeared as a single foetus with curved vertebral column and double sets of fore limbs, hind limbs and two recti and double sets of external genitalia. The crownrump length was 24.5 cm, the total length was 38 cm. The thoracic contour was 29 cm and the weight without the viscera was 3 kg. The forelimbs were malplaced although the thoracic cavity was single and appeared normal. Caudally, the apparently normal vertebral column was overlapped at the level of the abdominal region by the additional hind quarters which were markedly malplaced in position. The umbilical cord was common and has double sets of blood vessels. Cranial to the umbilicus the abdomen was duplicated and has abnormal shape and strange muscular arrangement. Caudal to the umbilical region the two foeti were separated. The external genitalia on the right side were represented by two empty scrotal sacs with small phallus in the prepuce. On the left side there were underdeveloped scrotal outgrowth while the phallus could not be recognized.

The additional hind quarters missed the tail caudally. The tail of the highly curved abnormally shaped sacrum was hidden underneath the skin of the dorso-lateral aspect of the thigh. It was discovered by palpation and dissection. The viscera were not available as mentioned.

DISCUSSION

The multiple duplications and anomalies of the described two monsters differ from those of the Siamese twinning described in swine with GREEN and MORGAN (1958) in which the monsters have double unequal heads.

McFEE; MURPHREE and REYNOLDS (1965) could define a period between 22nd and 25th days of gestation when the sheep embryo is susceptible to radiation-induced deformities of the front legs. Moreover, ARTHUR, *et al.* (1982) reported the embryonic period in sheep, between 14-35 days, is the period of great susceptibility to teratogens. The present described two cases of conjoined twins might be exposed to any teratogenic causes that induced such abnormalities, during the critical embryonic period. Different teratogenic agents include nutritional deficiency, endocrine disturbance, radiation, chemicals and others were reported by ROBERT (1971).

REFERENCES

- Arthur, G.H. (1956): Conjoined and identical twins, *Vet. Rec.* 68, 389.
 Arthur, G.H.; Noakes, D.E. and Person, H. (1982): *Veterinary Reproduction and Obstetrics*. 5th Ed. Bailliere, Tindall, London p. 85.
 Dennis, S.M. (1974): A survey of congenital defects of sheep. *Vet. Rec.* 95, 488.
 Dennis, S.M. (1980): Congenital and inherited defects in sheep. In: *Current therapy in theriogenology*. Morrow, D.A. Ed. W.B. Saunders Co., Philadelphia, London, Toronto.
 Green, F.R. and Morgan, J.T. (1958): The anatomy of a double Pig. *Vet. Rec.* 70, 704.
 Halnan, C.R.E. (1970): A cephalothoracophagus pig. *J. Anat.* 106, 204.

- Hancock, J. (1954): Monozygotic twins in cattle. In: *Advances in Genetics* 6, 141, Academic Press Inc. N.Y.C.
- Huston, G.S.; Schonweiss, E. & Leipold, H.W. (1978): Congenital defects in pig. *Vet. Bull.*, 48, 8.
- Leipold, H.W. and Dennis, S.M. (1980): Congenital defects affecting bovine reproduction. In: *Current therapy in theriogenology*. Morrow, D.A. Ed., W.B. Saunders Co., Philadelphia, London, Toronto, p. 924.
- Roberts, S.J. (1971): *Veterinary Obstetrics and genital diseases*. 2nd Ed. Edward Brothers, Inc. Michigan.
- Selby, L.A.; Hopps, H.C. & Edmond, L.D. (1971): Comparative aspects of congenital malformations in man and swine. *J. Am. Vet. Med. Ass.* 159, 1485.
- McFee, Q.F.; Murphree, R.L. and Reynolds, R.L. (1965): Skeletal Defects in prenatally irradiated sheep, cattle and swine. *J. An. Sci.*, 24, 4, 1131.

LEGENDS OF FIGURES

- Fig. (1):** Frontal view of the conjoined twins showing the line of junction, single head and double number of limbs.
- Fig. (2):** Dorso-ventral radiograph of the conjoined twins showing single head, double vertebral columns and double sets of limbs.
- Fig. (3):** Oblique lateral view of a monster showing the single foetus with curved vertebral columns and double sets of limbs.




Fig. (1)






Fig. (2)

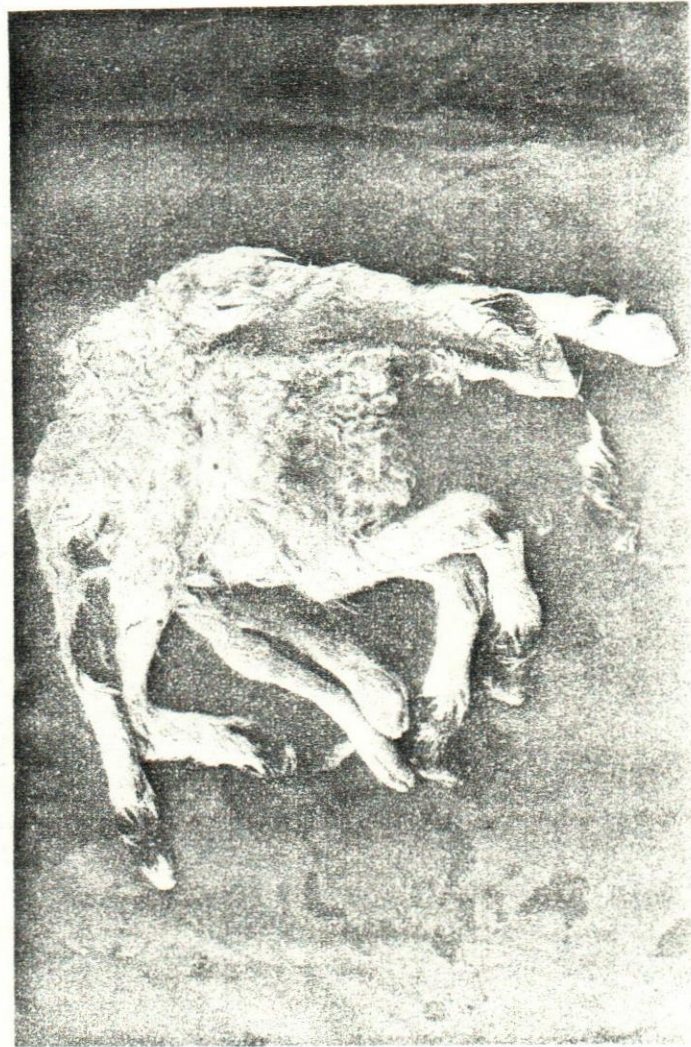

Fig. (3)