

## Endoscopic Adenoidectomy (EA) By Different Approaches

Mohammed M. I. EL-Beltagy, Ali Abd Allah Abdel Rhman  
and Mohamed M. El-Sawy  
ENT Department, Faculty of Medicine  
El-Azhar University

### Abstract

**Objective:** to assess the advantage of using the endoscopic approaches in performing adenoidectomy over the traditional adenoidectomy by using a curette.

**Design:** a prospective study analysis of outcomes for patients who underwent endoscopic adenoidectomy.

**Patient & Methods:** 300 patients underwent endoscopic adenoidectomy (transoral or transnasal) were available to take part in this prospective study between January 2003 and December 2005. All patients were subjected to complete ENT, routine blood work up, X-ray to the nasopharynx and tympanometry. Nasopharyngeal CT scan and/or transnasal endoscopy was done in suspicious cases. Follow up of these patients was done for 2 years by the means of X-ray of the nasopharynx or endoscopic examination.

**Results:** from the 300 cases, 120 patients in this study (40 %) were revision cases. Transoral endoscopic adenoidectomy was done in 255 patients (85 %). Transnasal endoscopic adenoidectomy was done in 43 patients (14 %). Combined transoral and transnasal endoscopic approaches was done in 2 patients (<1%) for cases with submucous cleft palate. Postoperative complications in this study were rare. Postoperative bleeding occurred in 2 cases (<1%), recurrent adenoid occurred in 6 cases (2%) in the 2 years follow up.

**Conclusion:** the authors recommend the endoscopic adenoidectomy approaches over the traditional adenoidectomy as it offers better visualization, less complications and less incidence of adenoid recurrence.

### Introduction

Adenoidectomy continues to be one of the most commonly performed operations in children in the 20<sup>th</sup> century. Adenoids are often removed alone or in conjunction with tonsillectomy and/or with placement of pressure equalization tubes (Clemens *et al.*, 1998).

Adenoidectomy is a safe and straightforward surgical procedure with clear indications. It is commonly performed to treat snoring, nasal obstruction, obstructive sleep apnea, recurrent otitis media, otitis media with effusion, sinusitis and adenotonsillar hypertrophy (Cowan and Hibbert, 1997).

Traditional method for removing the adenoid by using adenoid curettes, especially in patients with large adenoids; can be inadequate. Shaving large adenoid by curettage can be dicey as it is done blindly. In addition, after assuming successful curette adenoidectomy, many

children continue to be symptomatic. The presence of residual or recurrent adenoid should be determined in such cases. Allergy or immunodeficiency may also need to be ruled out. Removal of the tubal tonsils, also known as the tonsilla tubaria, eustachian tonsils, or Gerlach tonsils, is not consistently performed during curette adenoidectomy. Their potential impact may not be appreciated until symptoms persist or recur after adenoid removal (Emerick and Cunningham, 2006).

Therefore, this research is devised to determine the advantage of the endoscopic approach, by different approaches, in performing adenoidectomy.

### Patients & Methods

Three hundred patients underwent endoscopic adenoidectomy were available to take part in this prospective study

between January 2003 and December 2005. All patients were subjected to complete ENT, routine blood work up, conventional soft tissue X-ray to the nasopharynx and tympanometry. Nasopharyngeal CT scan and/or transnasal endoscopy was done in suspicious cases (figure 1). Follow up of these patients was done for 2 years by the means of X-ray of the nasopharynx or endoscopic examination.

#### **Operative technique**

For endoscopic adenoidectomy approaches (transoral and transnasal endoscopic approaches), the operative instruments include 70° (figure 2 A), 30° rigid endoscope, straight and up-biting angled forceps, adenoid curettage, angled suction diathermy, angled suction for maxillary sinus, Boyle-Davis mouth gag and plastic suction catheter.

**Transoral endoscopic approach:** the patient is placed in a supine position with the neck fully extended. After oro-endotracheal intubating, Boyle-Davis mouth gag is applied to keep the mouth open. The soft palate is palpated for the presence of a submucosal cleft. The posterior and lateral nasopharyngeal walls are palpated for pulsation (figure 2 B). On mild traction of the catheters, nasopharynx can be easily seen without the liability of tearing of the palatal mucosa. The surgeon is usually stands on the patient's head. The visualization of the nasopharynx is done by using 1) a plastic suction catheter passed through each nostril and retrieved through the mouth and 2) a 70° endoscope. Then, adenoidectomy is done by using adenoid curettage and the remnant parts removed by angled forceps (figure 2 and 3).

**Transnasal endoscopic approach:** it is usually done in selected cases (choanal adenoid and tubal tonsils) (Figure 4). The

surgeon stands on the right side of the patient and a 30° rigid endoscope is used to evaluate the nasopharynx. Then, cotton pledgets with a mixture of 4% lidocaine and 1:100,000 epinephrine is placed in the nasal cavities to shrink the nasal mucosa. After that, a transnasal adenoidectomy is done and the adenoid tissue removed under direct vision with straight and up-biting forceps.

During the EA, the patient's Eustachian tube orifice was always identified to avoid its damage during the procedure.

In case of submucosal cleft palate, the authors performed an upper 1/2 "partial" adenoidectomy by combined transoral and transnasal endoscopic adenoidectomy approaches.

Once the adenoids had been removed, hemostasis achieved by angled suction diathermy and the nasopharyngeal pack.

#### **Results**

- Three hundred endoscopic adenoidectomy was reviewed by the authors. Patient's mean age was about 6 years (range from 1 year to 20 years old), both male and female numbers were nearly equal.
- 120 patients in this study (40%) were revision cases.
- Transoral endoscopic adenoidectomy was done in 255 patients (85 %).
- Transnasal endoscopic adenoidectomy was done in 43 patients (14 %).
- Combined transoral and transnasal endoscopic approaches was done in 2 patients (<1%) for cases with submucous cleft palate.
- Postoperative complications in this study were rare. Postoperative bleeding occurred in 2 cases (<1%), recurrent adenoid occurred in 6 cases (2%) in the 2 years follow up.

## Endoscopic Adenoidectomy (EA) By Different Approaches

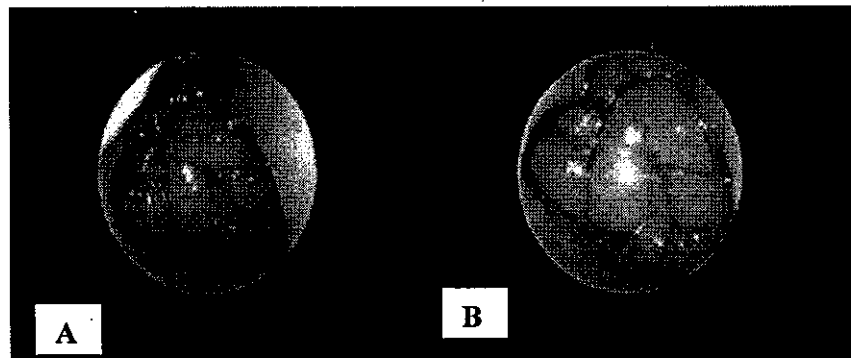


Figure (1): A, B shows large adenoid by preoperative transnasal endoscopic examination.

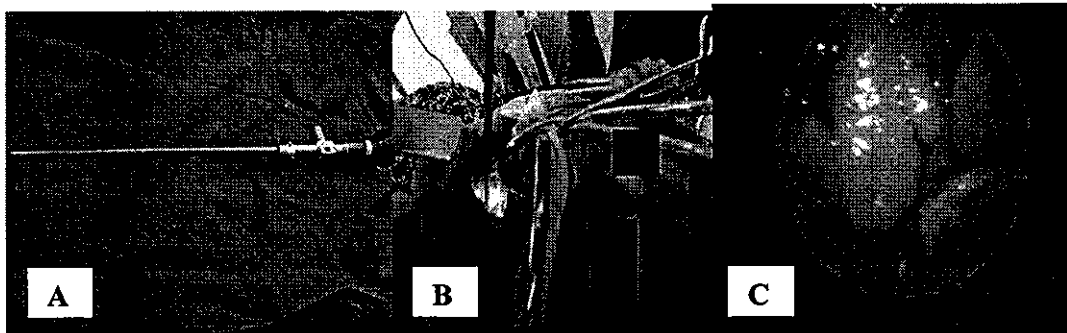


Figure (2): A: 70° rigid endoscope, B: The position of the patients, and C: Transoral endoscopic view.

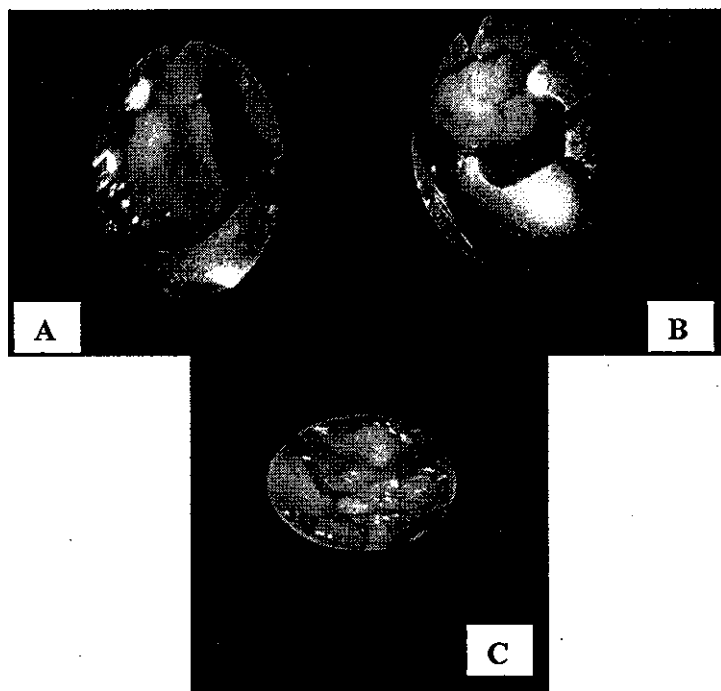


Figure (3): A: Removal of adenoid by adenoid curettage, B: removal of adenoid remnant by angled forceps, and C: After complete adenoidectomy, the choanae appears.




Figure (4): A & B: preoperative CT scans showing nasopharyngeal mass plugging in the choanae (choanal adenoid).

## Discussion

Adenoidectomy for the management of adenoid hypertrophy is a safe and effective procedure in treatment of nasal obstruction. Various techniques and different instruments had been utilized throughout the history of the procedure.

Traditional curettage is a well-known operation for the management of adenoid hypertrophy. However, many surgeons find it a blind procedure; with various postoperative complications include bleeding and recurrence. Cannon *et al.* (1999) have found that after conventional adenoidectomy, there is always residual tissue in the posterior superior choanae of the nose and nasopharynx. Therefore, surgeons recommended more sophisticated techniques to increase the efficiency in dissection and hemostasis (Steven, 1990 and Hartley *et al.*, 1998).

The authors found that endoscopic adenoidectomy is superior to the traditional curettage and nasopharyngeal mirror. The usage of endoscopic approach leads to: 1) complete removal of adenoid tissue even from the choanae/nasal cavity; 2) precise hemostasis under direct visualization; and 3) avoidance of damage to normal structures, ie, vomer and torus tubarius 4) easy access for removal of tubal and choanal adenoid.

On the other hand, the only drawback of the EA is the time consuming. However, in reviewing studies compare the traditional adenoidectomy to the endoscopic approaches regarding the time of the procedure, weight of the adenoid tissue harvested, and blood loss. Studies showed that, although

the EA takes longer time, the blood loss is less and the adenoid tissue removed is more (Cannon *et al.*, 1999).

In this study, the authors found that, the transoral endoscopic adenoidectomy take less time than transnasal endoscopic adenoidectomy. However, transnasal endoscopic adenoidectomy is utilized in more difficult and challenging cases as in choanal and tubal adenoid.

Finally, endoscopic adenoidectomy is technically feasible and can be easily learned. In addition, its tools are readily available in most of the ENT centers and do not require any expensive equipment.

## Conclusion

The authors recommend the endoscopic adenoidectomy approaches over the traditional adenoidectomy as it offers better visualization, less complications and less incidence of adenoid recurrence.

## References

1. Clemens J, McMurray J and Willging JP (1998): Electrocautery versus curette adenoidectomy: Comparison of postoperative results. *Int J Pediatric Otorhinolaryngol*, 43: 115-122
2. Cowan DL and Hibbert J (1997): Tonsils and adenoids. In: Kerr AG, Gleeson M, eds. *Scott Brown's Otolaryngology, Pediatric Otolaryngology*, Vol. 6, 6th ed. Oxford: Butterworth Heinemann, Ch. 18, pp. 1-16.
3. Emerick KS and Cunningham MJ (2006): Tubal tonsil hypertrophy, a cause

## Endoscopic Adenoidectomy (EA) By Different Approaches

- of recurrent symptoms after adenoidectomy. Arch Otolaryngol Head Neck Surg, 132: 153-156.
4. **Hartley BE, Papsin BC and Albert DM (1998):** Suction diathermy adenoidectomy. Clin Otolaryngol, 23: 308-309.
  5. **Steven MH (1990):** Laser surgery of tonsils, adenoids, and pharynx. Otolaryngol Clin North Am, 23: 43-7.
  6. **Cannon CR, Replogle WH and Schenk MP (1999):** Endoscopic-assisted adenoidectomy. Otolaryngology- Head and Neck Surgery, 121: 740-744.

## استئصال اللحمية خلف الأنف بواسطة المنظار

### عن طريق الفم أو الأنف أو الفم و الأنف

محمد محمد البلتاجى - على عبد الله عبد الرحمن - محمد محمود الصاوى

قسم الأذن و الأنف و الحنجرة

كلية الطب - جامعة الأزهر

الهدف من الدراسة: تقييم استخدام المنظار لأجراء عملية استئصال اللحمية خلف الأنف مقابل الاستئصال التقليدى بواسطة الكحت.

تصميم الدراسة: دراسة تتبعية لنتائج استئصال اللحمية خلف الأنف بالمنظار فى بعض المرضى محل الدراسة.

المرضى والطرق : أجريت الدراسة على 300 مريض تم استئصال اللحمية خلف الأنف عندهم بالمنظار (عن طريق الفم أو الأنف) فى الفترة ما بين يناير 2003 وديسمبر 2005 وقد خضع كل المرضى للفحص الاكلينيكي الشامل للأنف والأذن والحنجرة وأبحاث الدم المعتادة وكذلك الأشعة العادية للبلعوم الأنفى و ضغط الأذن. وفى بعض الحالات أجرى فحص بالمنظار عن طريق الانف وفحص بالأشعة المقطعية للبلعوم الأنفى. وتم متابعة الحالات لمدة عامين عن طريق عمل أشعة عادية للبلعوم الأنفى أو الفحص بالمنظار.

النتائج : 40% من حالات الدراسة سبق إجراء عملية استئصال اللحمية خلف الأنف لها ، وأجرى المنظار عن طريق الفم فى 85% من الحالات ، وعن طريق الأنف فى 14% ، وعن طريق الفم والأنف فى حوالى 1% من الحالات (شق سقف الحلق تحت الغشاء المخاطى). ولم تتجاوز حالات النزف بعد العملية 1% وعودة اللحمية خلال عامى المتابعة 2%.

التوصيات: وقد أوصى الباحثون باستئصال اللحمية خلف الأنف عن طريق المنظار بدلاً من الاستئصال الجراحى التقليدى حيث أنه يوفر رؤية أوضح ومضاعفات أقل كما أنه أقل عرضة لرجوع اللحمية مرة أخرى.