

قسم: الباثولوجيا .  
كلية: الطب البيطرى - جامعة أسيوط .  
رئيس القسم: أ.د. / محمد ابراهيم الشرى .

التغيرات الهستولوجية والهستوكيميائية في الكبد  
بعد تعرض الجسم الكلبي لأشعة اكس

مختار طه ، صلاح الدين يوسف

درس التأثير الحاد لتعرض الجسم الكلبي لأشعة اكس في كبد الأرانب البلدية  
البالغة هستوباثولوجيا وهستوكيميائيا . وضحت شرائح الكبد المصبوغ  
بالهيماتوكسولين والايوسين تغيرات كبدية باثولوجية في نسيج الكبد . هستوكيميائيا  
لوحظ زيادة أنزيم الفسفاتيز الحامضي ونقص في انزيم الفسفاتيز القاعدى .

Handwritten text at the top of the page, possibly a header or title.

Handwritten text in the middle section of the page.

Handwritten text in the lower middle section of the page.

Large block of handwritten text at the bottom of the page, possibly a main body or conclusion.

Dept. of Pathology,  
Fac. of Vet. Med., Assiut University,  
Head of Dept. Prof. Dr. M.I. El-Sherry.

## **HISTOLOGICAL AND ENZYME-HISTOCHEMICAL ALTERATIONS IN THE LIVER INDUCED BY TOTAL BODY X-IRRADIATION**

(With 6 Figures)

By

**M.M. TAHA and M.S. YOUSSEF**

(Received at 1/4/1986)

### **SUMMARY**

The acute effect of total body X-irradiation on the liver was studied histopathologically and histochemically in adult male Baladi rabbits.

In haematoxylin and eosin stained sections, the irradiated liver showed hepatopathic changes of the parenchyma. Histochemically, an increase in acid and decrease in alkaline phosphatase enzymes had been detected.

### **INTRODUCTION**

The liver was considered previously as a radio-resistant organ (RUBIN and CASARRETT, 1968). However, various animal and human studies have shown that it can be easily affected by a moderate dose of X-irradiation (JONES and HUNT, 1983).

The induced hepatic alterations were mainly through the direct effect of irradiation damage or due to the indirect toxic effects of the whole body irradiation (WALTER and MILLER, 1969). Experimental studies are needed to elucidate these changes and their pathogenetic mechanisms.

### **MATERIAL and METHODS**

The experiment was carried out on 12 adult male Baladi rabbits 3 used as control. Prior to irradiation, all the animals were premedicated by intramuscular injections of Promacid (Chlorpromazine HCl) in a dose of 5 mg./Kg. B.W. and 0.5 mg. 1% atropine sulphate. General anaesthesia was induced after 10 minutes by the slow intravenous injection of Thiopental in the ear vein in a dose of about 50 mg./Kg. B.W. (SOMA, 1971 and LUMB and JONES, 1973).

The dose of irradiation was adjusted by X-ray apparatus to obtain the sublethal dose; 810 Rads, for rabbits (BERDJIS, 1971). For fulfilling this requirement, the dose rate was 9 R/minute; the K.V. was 200; the filter used composed of 10 cu and 1.0 AL; the filament current was 5 M.A. and the exposure time was 1.5 hours.

The irradiated animals were classified into 3 groups, 3 rabbits each, then were sacrificed 1, 5 and 7 days respectively. The non-irradiated control rabbits were sacrificed in the same manner.

For histopathological examination of the liver, specimens were taken, fixed in neutral buffered formalin and Carnoy's fixative, processed and stained by haematoxylin and eosin stain for light microscopy.

For enzyme histochemical studies, fresh tissue samples were sectioned by freezing cryocut and stained for alkaline phosphatase activity (GOMORI, 1952) and acid phosphatase activity (GOMORI, 1941).

## TAHA and YOUSSEF

The first publication in this experiment was histo-enzymatic alterations of the testis after acute irradiation correlated to its hormonal function by TAHA *et al.* (1985).

**RESULTS****Gross and histopathological findings :**

The irradiated liver was slightly enlarged and dark red in colour. The most early and prominent finding 1 and 5 days post-irradiation was the vascular congestion. The central veins, hepatic sinusoids and portal blood vessels appeared dilated and filled with packed erythrocytes. In some cases, the hepatic parenchyma showed centrilobular degenerative changes. The hepatocytes were swollen and had a granular cytoplasm. However, some cells revealed cytoplasmic vacuolation. In other cases, nuclear necrobiosis could be seen. These nuclear changes were mainly pyknosis together with karyolysis of some nuclei (Fig. 1).

After one week, the portal triads appeared oedematous and infiltrated with lymphoid cells. The hepatic sinusoids were severely hyperaemic and revealed multiple immature leucocytic infiltrates (Fig. 2). In addition, some vessels showed endothelial damage and subsequent red thrombus formation.

**Enzyme histochemical findings :****Alkaline phosphatase :**

In the control animals, the alkaline phosphatase activity appeared in form of blackish granules (++) drawing the vascular endothelium and bile canaliculi (Fig. 3). The cytoplasmic reaction of the liver cells was (+), while the nuclei of liver cells were negative.

The liver examined 1, 5 and 7 days post-irradiation showed no alteration in the localization of the alkaline phosphatase activity. However, the intensity of the reaction was increased (+++) in the bile canaliculi (Fig. 4). The cytoplasmic reaction of the liver cells disappeared.

**Acid phosphatase :**

The reaction in the control animals was mainly localized in hepatic cell nuclei and was represented by dark brownish granules (++) while, the cytoplasm showed only sporadic positive (+) granules (Fig. 5).

In the irradiated livers, the intensity of the reaction was significantly increased both in the nuclei and cytoplasm (+++) (Fig. 6).

**DISCUSSION**

In the present work, the acute effect of total body X-irradiation on the rabbit's liver was manifested by vascular changes as well as hepatocellular changes.

The vascular lesions of the liver were the earliest changes observed as a result of the whole body irradiation. These lesions included severe congestion and oedema of the portal triads. Endothelial damage with the resulting thrombus formation were also found in some blood vessels. Similar findings were reported in the irradiated liver of the experimental animals (OGATA *et al.* 1963 and REED and COX, 1966) as well as human being (FELLOWS *et al.*, 1968 and WARTON *et al.*, 1973). OGATA *et al.* (1963) attributed these changes to the direct effect of irradiation on the liver.

## TOTAL BODY X-IRRADIATION

The hepatocellular changes were mainly granular proteinous dystrophy and to a lesser extent vacuolar degeneration. Moreover, nuclear necrobiosis was observed in some cases. Similar changes of the irradiated liver had been observed by many authors (PHOLE & BUNTING, 1932 and SCOTT, 1962). These previous hepatic changes were regarded as the first cellular reaction to the direct toxic injurious effect of the ionizing irradiation (BRAS and MCLEAN, 1953) or as an indirect result of the vascular disturbances produced by irradiation (OMALLEY *et al.*, 1963). In our opinion, both the direct and indirect effects of irradiation played a role in the induction of the hepatopathological alterations.

The lymphoid cell infiltrates found in the portal tracts were regarded as a primary inflammatory cellular response to the ionizing irradiation. This was in accordance with JACKSON *et al.* (1977) who reported the early presence of lymphocytes, monocytes and polymorphonuclear leucocytes. However, the polymorphonuclear cells and monocytes could not be detected in our data. The presence of immature leucocytes in the hepatic sinusoids was regarded as an extramedullary haematopoiesis due to the suppressive effect of total body X-irradiation on the bone marrow. BLOOM (1948) and COTCHIN and FRACIS (1967) reported a haematopoietic activity in the liver as a result of loss of leucocytes, erythrocytes and thrombocytes from the circulation and failure of the bone marrow to produce an adequate number of these cells.

Histochemically, acid phosphatase activity was increased in the irradiated liver. As it is known, acid phosphatase enzyme is a hydrolytic, catabolic and reductive enzyme, so, the increased cytoplasmic and nuclear reactions could be correlated to the induced degenerative and necrobiotic changes after irradiation. This was in accordance with the findings of WILLSON and STOWELL (1953) and ONO and OKADA (1974).

Alkaline phosphatase is anabolic enzyme and is linked with the protein biosynthesis of the cell (MUKERJEE and GOLFEDER, 1974). In our results, alkaline phosphatase activity was totally absent in the degenerated liver cells. However, it was increased in bile canaliculi. This increase could be related to the physiological hyperactivity of bile secretion. The increased bile metabolism could be a result of increased haemolysis of the congested blood or as a direct effect of X-irradiation on erythrocytes or both. Contradictory results were recorded by WITCOFSKI *et al.* (1972) and WARTON *et al.* (1973) who reported increased alkaline phosphatase activity in the irradiated liver cells and considered this increase to the regenerative capacity of the liver.

It could be concluded that total body X-irradiation induced vascular and cellular changes in the liver. The vascular lesions was a direct effect of irradiation on the vasculature. The hepatic cells suffered from combined direct cytotoxic effect of X-ray as well as the indirect effect produced by vascular disturbances. The histochemical indices reflected these hepatocellular alterations as was indicated by the increased acid phosphatase and absence of alkaline phosphatase activity.

## REFERENCES

- Bloom, W. (1948): Histopathology of Irradiation. Book Company, Inc., London.  
 Bras, G. and Mclean, E. (1953): Toxic factors in veno-occlusive disease in foetal and infant liver function and structure. Ann. N.Y. Acad. Sci. III: 392 - 398.  
 Berdjis, C.C. (1971): Pathology Of Irradiation. The Williams and Wilkins Company, Baltimore, USA.  
 Cotchin, E.I. and Fracis, J.C. (1967): Pathology Of The Liver Of Rats And Mice. Blacknell Scientific Publication, Oxford and Edinburgh, First edition.

## TAHA and YOUSSEF

- Fellows, K.F.; Vawter, G.F. and Tefft, M. (1968): Hepatic effects following abdominal irradiation in children, detection by Au 198 Scan and Confirmation by histologic examination. *Am. J. of Roentg. Lo 3* : 427 - 431.
- Gomori, G. (1941): In *Theory And Practice Of Histologic Techniques* (1977). By: Bancroft, J.D. and Stevens, A.S. Foreward By: Dawson, I.M.P. Churchill Livingstone Edinburgh London and New York.
- Gomori, G. (1952): In *Theory And Practice Of Histologic Techniques* (1977). By: Bancroft, J.D. and Stevens, A.S. Foreward By: Dawson, I.M.P. Churchill Livingstone Edinburgh London and New York.
- Jarkson, R.L.; Christensen, G.M. and Hebard, D.W. (1977): In vivo repair of radiating injury leading to interphase cell death in rat liver. *Radiation Research* 69 : 339 - 347.
- Jones, T.C. and Hunt, R.D. (1983): *Veterinary Pathology, Fifth Edition*, Lea & Febiger. Philadelphia.
- Lumb, W.V. and Jones, E.W. (1973): *Veterinary Anaesthesia*. Febiger. Philadelphia.
- Mukerjee, H. and Goldfeder (1974): Protein biosynthesis in the liver of X-irradiated mice. *Int. J. Radiat. Biol.* 25 (5): 445 - 454.
- Ogata, K.; Hizawa, K.; Yoshida, M.; Kitamuro, T.; Akagi, G.; Kagawa, K. and Fulrado, F. (1963): Hepatic injury following irradiation, a morphologic study. *Tokushima J. Exp. Med.* 9 : 240 - 251.
- Omalley, B.; Dangio, G.J. and Vawter, G.F. (1963): Late effects of Roentgen therapy given in infancy. *Amer. J. Roentg.* 89 : 1067 - 1074.
- Ono, T. and Okada, A. (1974): Estimation in vivo of DNA strand breaks and their rejoining in thymus and liver of mouse. *Int. J. Radiol.* 25 (3): 291 - 301.
- Phole, E.A. and Bunting, C.H. (1932): Studies of the effect of Roentgen rays on the liver. *Acta Radiol.* 13 : 117 - 124.
- Reed, G.B. and Cox, A.J. (1966): The human liver after radiation injury. *Am. J. Path.* 48 : 597.
- Robin, P. and Casarrett, G.W. (1968): *Clinical Radiation Pathology* Saunders Co. Vol. 2.
- Scott, R.B. (1962): Hepatic veno-occlusive syndrome in an American adult rats. *Gastroenterology* 42 : 631 - 636.
- Soma, L.R. (1971): *Textbook of Veterinary Anaesthesia*. The Williams & Wilkins Company, Baltimore, USA.
- Taha, M.M.; Bayoumi, A.H.; Mostafa, A.M. and Youssef, H.A. (1985): Histo-enzymatic alterations of the testis after acute irradiation correlated to its hormonal function. *Assiut Medice Journal* 9 (3): 558 - 566.
- Willson, M.E. and Stowell, R.E. (1953): Cytological changes following Roentgen irradiation of the liver in mice. *J. Nat. Cancer Inst.* 13 : 1123 - 1138.

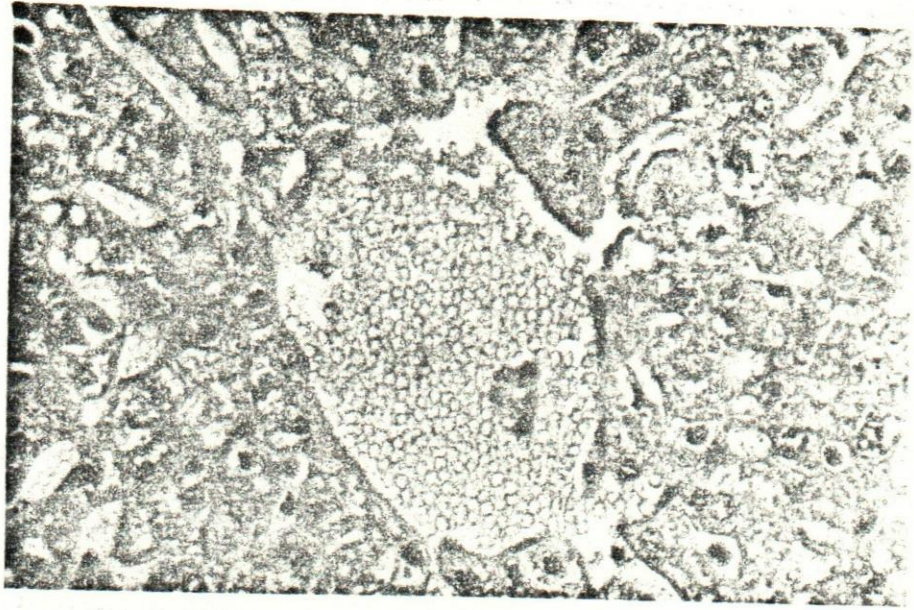


Fig. (1)

Liver 1 day post-irradiation showing congestion and  
necrotic changes of the hepatocytes.  
( H. E., X 400 )

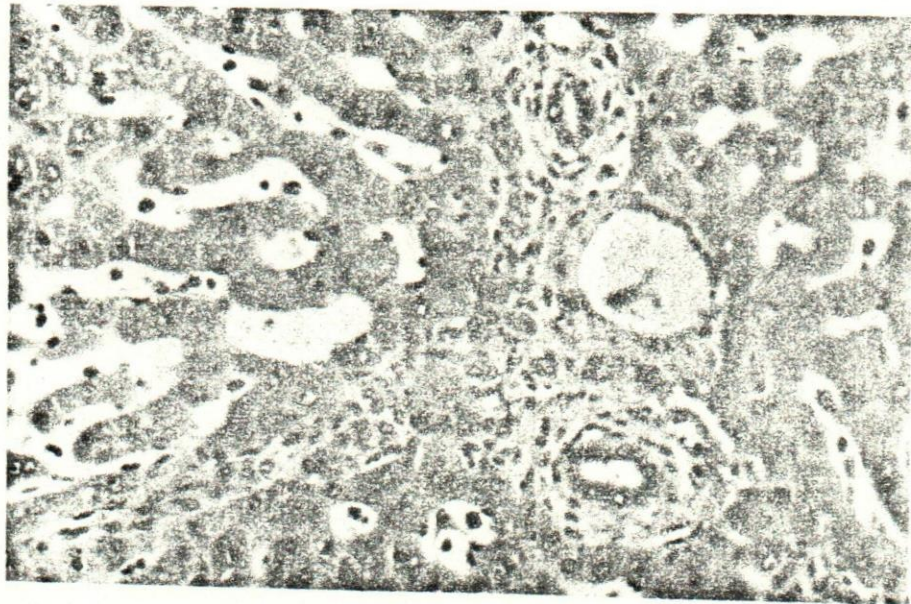

Fig. (2)

Liver 1 week post-irradiation showing edema, lymphoid  
cell infiltrate in the portal area and immature leucocytes  
in the sinusoids.  
( H. E., X 250 )





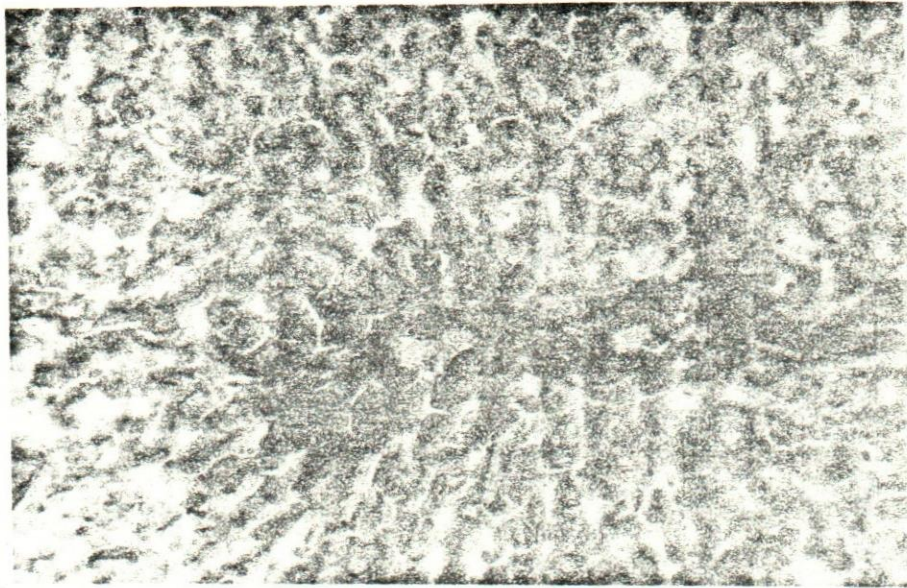


Fig. (3)

Control alkaline phosphatase enzyme in non-irradiated liver.  
( X 160, Gomori method ).

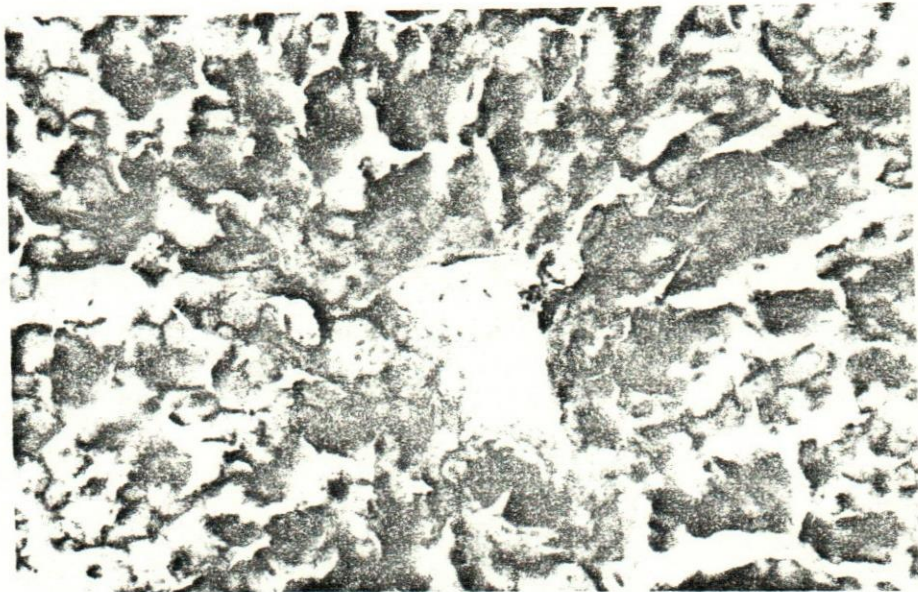

Fig. (4)

Irradiated liver showing increased alkaline phosphatase  
reaction (+++) in the bile canaliculi.  
( X 250, Gomori method ).



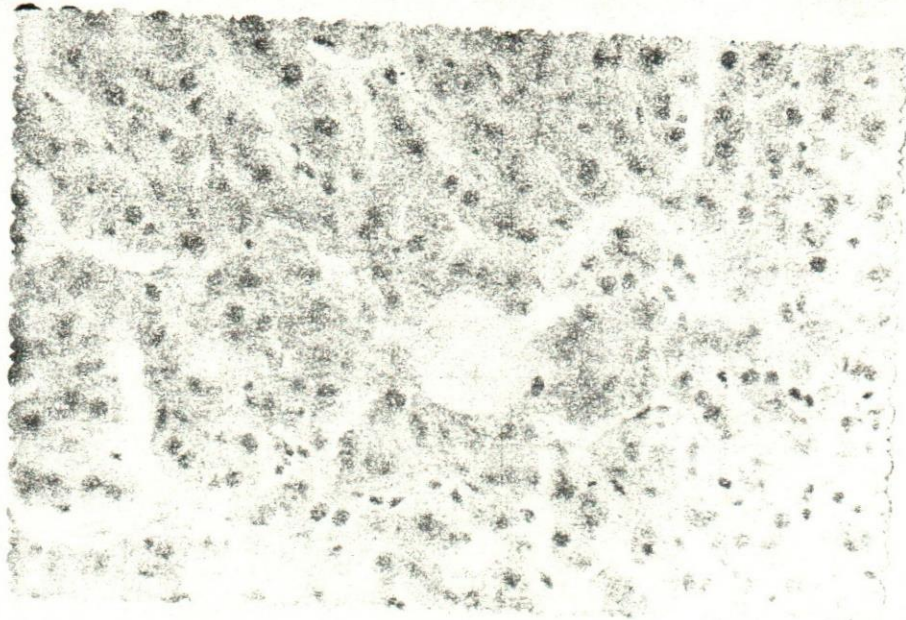


Fig. (5)

Control acid phosphatase enzyme in non-irradiated liver.  
( X 250, Gomori method ).

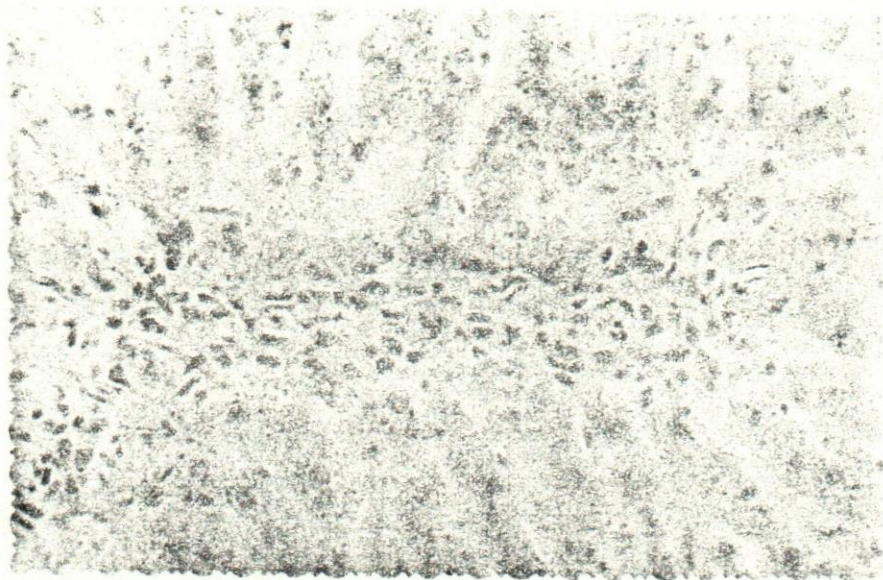


Fig. (6)

Irradiated liver showing increased acid phosphatase  
cytoplasmic and nuclear reaction (+++).  
( X 250, Gomori method ).

