

## Impact of adenoidectomy alone or with ventilation tube for treatment of secretory otitis media in children

Tawfik Abdelaty Elkholy<sup>1</sup> MD, Fatma Mohammed Abd El-gaber<sup>1</sup> MD,  
Dalia Mesbah Mohamed Al-Agamy<sup>2</sup> MD, Marwa Elhady<sup>3</sup> MD.

### \* Corresponding Author:

Fatma Mohammed Abd El-gaber

[fatmamohamed30@hotmail.com](mailto:fatmamohamed30@hotmail.com)

Received for publication July 17,

2021; Accepted August 22, 2021;

Published online August 22, 2021.

**Copyright** The Authors published by Al-Azhar University, Faculty of Medicine, Cairo, Egypt. Users have the right to read, download, copy, distribute, print, search, or link to the full texts of articles under the following conditions: Creative Commons Attribution-Share Alike 4.0 International Public License (CC BY-SA 4.0)..

**doi:** 10.21608/aimj.2021.86770.1529.

<sup>1</sup>Otorhinolaryngology Department, Faculty of Medicine (for Girls), Al-Azhar University, Cairo, Egypt.

<sup>2</sup>Regional center of mycology and biotechnology, Faculty of science (for Girls), Al-Azhar University, Cairo, Egypt.

<sup>3</sup>Pediatric Department, Faculty of Medicine (for Girls), Al-Azhar University, Cairo, Egypt.

### ABSTRACT

**Background:** Adenoid surface in patients suffering from secretory otitis media is usually associated with bacterial biofilm. Adenoidectomy is thought to be effective in treatment of cases associated with secretory otitis media.

**Aim of the study:** To Evaluate the role of adenoidectomy alone or in combination with ventilation tube insertion in improving the outcome of OM with effusion associated with adenoid hypertrophy.

**Patients and Methods:** This study included 40 children with recurrent or persistent secretory OM despite proper medical treatment for 3-6 months. They were divided into 2 equal groups. Group A treated by adenoidectomy with ventilation tube insertion and the group B was treated by adenoidectomy alone. These patients were evaluated preoperatively by plain X-ray nasopharynx lateral view and audiological assessment, adenoid specimen was taken for scanning by electron microscope for adenoid surface biofilm detection and grading. Postoperatively, we followed up the patients for 1 year to assess improvement and post-operative complications.

**Results:** At the 1st follow up visit, Group A had higher rate of improvement than those who had adenoidectomy alone. Long term follow up (1 year) show significant higher rate of complications in those who were treated by adenoidectomy with ventilation tube 5 cases in comparison to only 2 cases of in Group B. There was no significant association between adenoid size and biofilm formation. Adenoid size and biofilm extension grade had no significant relation to postoperative outcome.

**Conclusion:** Removal of adenoid was associated with relieve of OME with significant higher rate of complications in those undergoing adenoidectomy with ventilation tube insertion.

**Keywords:** adenoidectomy; ventilation tube; otitis media; children.

**Disclosure:** The authors have no financial interest to declare in relation to the content of this article. The Article Processing Charge was paid for by the authors.

**Research Support:** RCT approval numbers: NCT04656067 and PACTR202101794541918

**Authorship:** All authors have a substantial contribution to the article.

### INTRODUCTION

Secretory otitis media is a condition characterized by accumulation of non-purulent mucoid or serous fluid in the middle ear in absence of signs of acute infection. Secretory otitis media is considered chronic when effusion persists for 3 or more months that detected either clinically or by tympanometry<sup>1</sup>. Persistent secretory otitis media is a common health problem in pediatric age group that adversely affects hearing due to fluid pressure on the tympanic membrane that limits its vibratory movement in response to sound waves. Sensorineural hearing loss is also reported to be a sequel of persistent OM with effusion. Hearing defect, further impairs the learning ability and quality of life of such children<sup>2</sup>. Other complications include tinnitus, sense of ear

fullness and vestibular dysfunction causing excessive clumsiness, awkwardness and recurrent falling. Furthermore, unresolved middle ear effusion provides a media for bacterial proliferation.<sup>3</sup>

There is emerging evidence that infection from nasopharynx pathogen has a key role in persistence of secretory OM. In children the short length and horizontal position of Eustachian tube predispose them for spread of nasopharyngeal pathogen into the cavity of the middle ear. Despite advances in medical treatment, bacterial resistance to antimicrobial medication represents a great barrier against resolution of secretory OM.<sup>4</sup>

Bacterial biofilm is complex surface attached to microbial communities that linked by self-produced polymer matrix encapsulate the bacterial forming microcolony that can survive and resist high

concentration of antibiotics. Formation of bacterial biofilm making it difficult to treat the underlying infection leading to increased risk of persistent/recurrent infection. Removal of the colonized tissue is the only effective method to eradicate biofilm associated infection.<sup>5</sup>

Poor Eustachian tube ventilation caused by mechanical obstruction by enlarged adenoid is one of the underlying mechanisms for persistent OM<sup>6</sup>. Drainage of effusion through myringotomy with ventilation tube insertion represents rapid effective treatment. Adenoidectomy is another option for treatment especially for those with enlarged adenoid<sup>7</sup>. However, surgical intervention did not always provide satisfactory results. Surgery has many complications that making surgical decision is challenging with the need for proper judgment of benefits to hazards. Myringotomy with tympanostomy tubes insertion related complications including purulent otorrhea, residual perforation, tympanic membrane atrophy, tympanosclerosis, and early extrusion of the tube leading to effusion re-accumulation<sup>8</sup>. The objective of this work was to study the effect of bacterial biofilm on chronicity of secretory OM and study the efficacy of adenoidectomy alone for treatment of chronic secretory otitis media.

## PATIENTS AND METHODS

This prospective interventional analytic study was conducted on 40 children with persistent or recurrent OM despite proper medical treatment for 3-6 months. They were selected from Otorhinolaryngology and pediatric outpatient clinics, during the period from September 2108 to March 2020. The study was approved by the Research Ethics Committee of faculty of Medicine- Al Azhar University. Parents of all included children were informed about the study, and written consents were obtained from them.

Inclusion criteria were children with secretory otitis media and adenoid hypertrophy aged 5 to 15 years old of both sexes. Children with naso-facial malformation, cleft palate, allergic rhinitis, history of adenoid operation, previous tube insertion, any other ear problem and patients who respond properly to medical treatment were excluded from the study.

Included children were randomly divided into two groups based on the consecutive number of enrollments those with odd number were included into group A while those of even number were included in group B:

Group A: Included 20 children who underwent adenoidectomy operation with ventilation tube insertion.

Group B: Included 20 children who underwent adenoidectomy operation only without ventilation tube insertion.

### History and examination

All patients were subjected to detailed history taking and thoroughly clinical examination was done with special emphasis on ENT examination.

### Otorhinolaryngological assessment

All children were evaluated preoperatively by plain X-ray nasopharynx lateral view to confirm the adenoid hypertrophy and to measure the adenoid-nasopharyngeal ratio according to Fujioka et al. [9].

Audiological assessment was performed preoperative for all included children using pure tone audiometry and tympanometry.

Intraoperative nasopharynx examination was done using flexible nasal endoscopy to determine the grade of adenoid hypertrophy (small, medium and large). The ratio of adenoid tissue to choanal opening was stated as a percentage. Patients were graded based on the degree of obstruction into three grades. Grade 1: <50% of choanal space was occupied by the adenoid tissue, Grade 2: 50–75% choanal obstruction and Grade 3: >75% choanal obstruction [10]. The physician who performed the endoscopic examination was blinded to the clinical and radiographic findings.

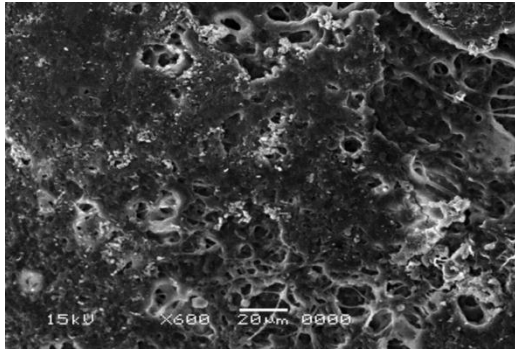
Postoperatively, we followed up the patients for 1 year (after 2 weeks, 6 months and 12 months) to assess improvement of the symptoms, audiology and for detection of any complications.

### Biofilm detection

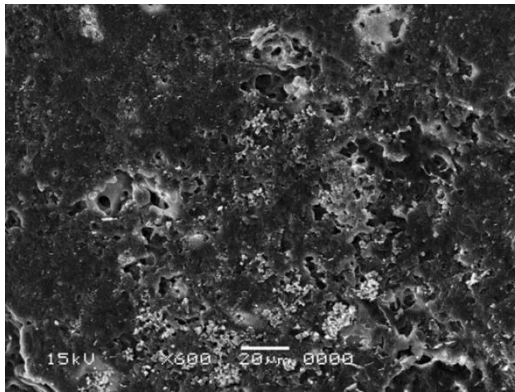
Adenoid specimen was taken (for scanning electron microscope for adenoid surface biofilm detection and grading).

The fresh different size of specimens was immediately fixed in 2.5% glutaraldehyde for 24 hours, washed in phosphate buffer (pH 7.4), post fixed in 1% osmium tetroxide in phosphate buffer (pH 7.4), and dehydrated in increasing concentrations of alcohol. After dehydration, the specimens underwent the critical drying point process and were mounted on metal stubs with double-sided adhesive tape. Then the samples were sputtered with a 15-nm-thick layer of gold in a sputter apparatus (SPI MODULE). The images were taken with the JEOL SEM 5500LV (JEOL Ltd, Tokyo, Japan).

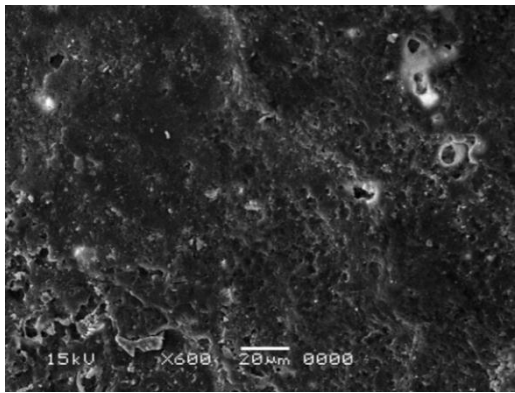
To examine the areas of interest on the surface of an adenoid tissue specimen, we took sample SEM images with a voltage of 15 kV and within a magnification 600 times. We determined the biofilms as the areas where multilayered remnants of tissue and microorganisms exist. With respect to the average biofilm extension, grade 1 (Figure 1), grade 2 (Figure 2), grade 3 (Figure 3), and grade 4 (Figure 4) biofilm formations were determined when less than 25%, 25% to 49%, 50% through 75% and more than 75% of sample surfaces were involved, respectively.



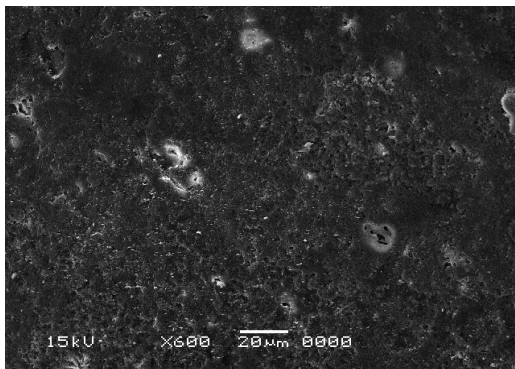
**Fig1:**SEM image showing microbial biofilm less than 25%



**Fig.2:** SEM image showing microbial biofilm 25% to 49%



**Fig.3:**SEM image showing microbial biofilm 50% through 75%



**Fig.4:** SEM image showing microbial biofilm more than 75%

### Statistical analysis

Data analysis was done using statistical package for social science (SPSS Inc., Chicago, Illinois, USA) version 22. Numerical data were expressed as mean and standard deviation (mean  $\pm$  SD) and non-numerical data were expressed as number and percentage. Comparison between groups was done using independent student t-test for numerical data and chi square test for non-numerical data. The level of significance was set as P-value  $<0.05$ .

### RESULTS

The current study included 40 children with persistent OM with effusion. Their age ranged between 5 to 8 years old. They were 18 males and 22 females. Twenty of them were treated by adenoidectomy alone while the remaining twenty were treated by adenoidectomy with ventilation tube insertion. There was no significant difference between the 2 groups as regard age, sex, adenoid size and biofilm extension as shown in table 1.

At the 1<sup>st</sup> follow up visit (2 weeks after operation), children with adenoidectomy and ventilation tube insertion had higher rate of improvement than those who had adenoidectomy alone (90% vs 70%). Long term follows up for 1 year show significant higher rate of complications in those who were treated by adenoidectomy with ventilation tube 5 cases in comparison to only 2 cases of in those who were treated by adenoidectomy alone as shown in table 2.

Neither of adenoid size nor biofilm extension grade had significant relation to postoperative outcome as shown in table 3.

Adenoid size did not have significant association with biofilm formation or postoperative outcome among our studied children as shown in table 4.

Clinical data	adenoidectomy with ventilation tube insertion n=20	adenoidectomy alone n=20	Independent student t test/ chi square test	
			t/X <sup>2</sup>	P-value
Age (year)	6,4±0.3 1,090	6.140±1.165	0.839	0.407
Sex (n, %)				
Male	8 (40%)	10 (50%)	0.404	0.525
female	12 (60%)	10 (50%)		
Adenoid enlargement			3.394	0.183
Mild	5 (25%)	5 (25%)		
Moderate sever	11 (55%) 4 (20%)	6 (30%) 9 (45%)		
Biofilm extension			0.577	0.902
Grade 1 (< 25%)	2 (10%)	3 (15%)		
Grade 2 (25%-49%)	5 (25%)	5 (25%)		
Grade 3 (50%-75%)	8 (40%)	6 (30%)		
Grade 4 >75%	5 (25%)	6 (30%)		

**Table 1:** Comparison of clinical data of the studied groups

Clinical data	adenoidectomy with ventilation tube insertion n=20	adenoidectomy alone n=20	Independent student t test/ chi square test	
			t/X <sup>2</sup>	p-value
Follow up at 2 weeks Resolved OM Unresolved OM	18 (90%) 2 (10%)	14 (70%) 6 (30%)	2.500	0.114
Follow up at 6 month Resolved OM Complicated	15 (75%) 5 (25%)	20 (100%) 0 (0%)	5.714	0.017*
Follow up at 12 month Complicated Uncomplicated	5 (25%) 15 (75%)	2 (10%) 18 (90%)	1.558	0.212

\*significant . OM: otitis media

Complication in group A 5 cases were early extrusion 1cases, recurrent OM 2 cases, 1otorrhea, 2 residual perforation (one case may presented by more than one complication)

Complications in group B were recurrent OM 2 cases

**Table 2:** medical course during follow up of the studied children

Clinical data	Uncomplicated cases n=33	Complicated cases n=7	Independent student t test/ chi square test	
			t/X <sup>2</sup>	p-value
Age (year)	5.857±0.899	6.333±1.164	- 1.203	0.255
Sex (n, %)				
Male	14 (42.4%)	4 (57.2%)	0.505	0.477
Female	19 (57.6%)	3 (42.8%)		
Adenoid enlargement				
Mild	6 (18.2%)	4 (57.1%)	4.760	0.093
Moderate	15 (45.4%)	2 (28.6%)		
Severe	12 (36.4%)	1 (14.3%)		
Biofilm extension				
Grade 1	4 (12.1%)	1 (14.3%)	1.743	0.627
Grade 2	7 (21.2%)	3 (42.8%)		
Grade 3	12 (36.4%)	2 (28.6%)		
Grade 4	10 (30.3%)	1 (14.3%)		

**Table 3:** Comparison of clinical data, adenoid size and bacterial biofilm between complicated and uncomplicated children

	Adenoid enlargement			Chi square test	
	Mild (n=10)	Moderate (n=17)	Severe (n=13)	X <sup>2</sup>	p-value
<b>Biofilm extension</b>					
Grade 1	1 (10%)	3 (17.6%)	1 (7.7%)	8.5 23	0.202
Grade 2	5 (50%)	2 (11.8%)	3 (23.1%)		
Grade 3	3 (30%)	8 (47.1%)	3 (23.1%)		
Grade 4	1 (10%)	4 (23.5%)	6 (46.1%)		
<b>Outcome</b>					
Resolved OM		15	12	5.3 08	0.257
Recurrent OM	6 (60%)	(88.2%)	(92.3%)		
Other complications	2 (20%)	1 (5.8%)	1 (7.7%)		
	2 (20%)	1 (5.8%)	0 (0%)		

OM: otitis media

**Table 4:** The relation between adenoid size and bacterial biofilm formation among studied children (n=40)

**DISCUSSION**

In addition to adenoid induced mechanical Eustachian tube dysfunction, adenoid bacterial colonization and biofilm formation may contribute to persistent secretory otitis media <sup>11</sup>. In cases that failed medical treatment for 3 months, surgical intervention is the most effective treatment option. There is controversy regarding the best surgical intervention technique. <sup>12</sup>

In the current study we evaluated the long-term outcome after the two common surgeries for treatment of secretory otitis media in children (either adenoidectomy combined with insertion of ventilation tubes or a

adenoidectomy alone). Despite initial higher rate of improvement among those who underwent adenoidectomy with ventilation tube insertion in comparison to those who underwent adenoidectomy alone (90% vs. 70%) but long term follows up showed better outcome in those who underwent adenoidectomy alone with significant higher resolution rate (100% vs 75%) at 6 months follow up and lower rate of complication (10% vs 25%) at 1 year follow up.

In agreement with our findings, Damoiseaux and Rovers [13] concluded that ventilation tube insertion seem to have only a short- term benefit in subjects with secretory otitis media as it allows rapid release of middle ear retained fluid. Mikals and Brigger <sup>14</sup> systematic review and meta-analysis demonstrated that failure rate was higher in children treated by tympanostomy tube placement (31.8%) in comparison to those who were treated by adenoidectomy (17.2%). Boonacker et al <sup>15</sup> showed that children underwent adenoidectomy had higher clinical improvement with failure rate of 16% at 12 months follow up. Hao et al <sup>16</sup> reported that adenoidectomy with ventilation tube insertion is more effective with shorter duration of effusion cure and lower rate of recurrence than ventilation tubes alone in treating children with secretory otitis media (19.77% vs 6.12%).

Adenoidectomy has been emerged as an effective surgical intervention for those with persistent/recurrent secretory otitis media. Resolution of symptoms after adenoid removal is not only attributed to removal of enlarged hypertrophied adenoid tissue and relieve of mechanical obstruction leading to better aeration and drainage of retained fluid in middle ear and improve Eustachian tube function but also removal of the colonized bacterial biofilm at adenoid tissue that act as source for recurrent resistant infection <sup>17</sup>. Xu et al <sup>18</sup> demonstrated that pathogenic microorganisms isolated from the middle ear effusion were similar to that isolated from adenoid tissues of children with secretory otitis media. Furthermore, infection from adenoid tissue can be transmitted through ascending pathway to middle ear cavity causing effusion. <sup>19</sup>

Among our included children all of them showed bacterial biofilm formation isolated from adenoid tissue. There was no significant association between adenoid size and biofilm formation. In agreement with our findings, Saafan et al<sup>20</sup> reported that biofilm formation in 74 % of adenoid specimen from children with chronic OM with effusion in comparison to 42% from adenoid of children who had hypertrophied adenoid without middle ear effusion with no significant relation between adenoid size and biofilm formation. A lower prevalence of bacterial biofilm in adenoid tissue was reported by Kania et al<sup>21</sup> who found 63.5% bacterial biofilm in adenoid of children with chronic secretory otitis media.

This high prevalence of bacterial biofilm among our studied children could explain the high-resolution rate among our studied children with only 4 cases of recurrence of OM (90%) after removal of adenoid regardless of the insertion of ventilation tube. Furthermore, adenoidectomy with or without ventilation tube insertion was effective for decreasing the recurrence of OM with effusion regardless of the size of adenoid suggesting that the ineffectiveness of antibiotic medications in those children may be caused by nasopharyngeal biofilm forming bacteria. The distribution of biofilm producing bacteria in the nasopharynx plays an important role in the development of recurrent OM with effusion in children with higher risk in those who had bacterial biofilm isolated from adenoid tissue located near the ostium of Eustachian tube suggesting that colonized adenoids act as a reservoir for bacteria<sup>22</sup>. Evidence showed that formation of bacterial biofilm is associated with increased antibiotic resistance and enhance the bacterial survival leading to recurrent or persistent OM<sup>23</sup>.

Follow up of our studied children showed higher rate of complications in those who underwent ventilation tube insertion while recurrence of OM was similar between both groups. Complications included early extrusion, otorrhea and residual perforation. In accordance with our findings, Saki et al [24] found high rate of complications among children treated by ventilation tube insertion in the form of transient otorrhea (12.5%), delayed otorrhea (8.2%), tympanic membrane atrophy (27.8%) tympano-sclerosis (37.9%), and persistent perforation (2.4%). Vahedian et al<sup>25</sup> reported that complications related to ventilation tube insertion were otorrhea (2%), tympanosclerosis (12.2%), atrophy (6.8%), residual perforation (1.5%), and recurrent OM (3.9%).

The small number of included children represent a major limitation of the current study however the long follow up for one year increase the strength of the study findings.

### CONCLUSION

Bacterial biofilm is a key element in persistence of adenoid chronic mucosal inflammation and may act as a reservoir for infection in children with recurrent/persistent OM with significant improvement after removal of the infectious source in the nasopharynx irrespective of the adenoid size

which just acts as a mechanical factor for obstruction of the Eustachian tube. Regardless the surgical intervention method, removal of adenoid was associated with relieve of OM with significant higher rate of complications in those undergo adenoidectomy with ventilation tube insertion. Our findings add evidence that adenoidectomy alone without tube insertion is sufficient to achieve improvement in patients with secretory otitis media. Hence, we can avoid exposing children to tympanotomy and tube insertion long term complications.

### REFERENCES

- 1- Vanneste P, Page C. Otitis media with effusion in children: Pathophysiology, diagnosis, and treatment. A review. *J Otol.* 2019;14(2):33-9.
- 2- Emmett SD, Kokesh J, Kaylie D. Chronic Ear Disease. *Med Clin North Am.* 2018 Nov;102(6):1063-79
- 3- Kolkaila EA, Emara AA, Gabr TA. Vestibular evaluation in children with otitis media with effusion. *J Laryngol Otol.* 2015 Apr;129(4):326-36.
- 4- Korona-Glowniak I, Wisniewska A, Juda M, Kielbik K, Niedzielska G, Malm A. Bacterial aetiology of chronic otitis media with effusion in children - risk factors. *J Otolaryngol Head Neck Surg.* 2020;49(1):24.
- 5- Muhammad MH, Idris AL, Fan X, Guo Y, Yu Y, Jin X, Qiu J, Guan X, Huang T. Beyond Risk: Bacterial Biofilms and Their Regulating Approaches. *Front Microbiol.* 2020 May 21;11:928.
- 6- Nemade SV, Shinde KJ, Rangankar VP, Bhole P. Evaluation and significance of Eustachian tube angles and pretympnic diameter in HRCT temporal bone of patients with chronic otitis media. *World J Otorhinolaryngol Head Neck Surg.* 2018 Dec;4(4):240-5.
- 7- Ahmed A, Kolo E, Aluko A, Abdullahi H, Ajiya A, Bello-Muhammad N, Raji H, Tsigah-Ahmed F. Diagnosis and management of otitis media with effusion in a tertiary hospital in Kano: a best practice implementation project. *JBID Database System Rev Implement Rep.* 2018 Oct;16(10):2050-63.
- 8- Djordjević V, Bukurov B, Arsović N, Ješić S, Milovanović J, Nešić V. Long term complications of ventilation tube insertion in children with otitis media with effusion. *Vojnosanit Pregl.* 2015 Jan;72(1):40-3.
- 9- Fujioka M, Young LW, Girdany BR. Radiographic evaluation of adenoidal size in children: adenoidal-nasopharyngeal ratio. *AJR Am J Roentgenol.* 1979 Sep;133(3):401-4.
- 10- Yaseen ET, Khammas A, & Anbaky FA. Adenoid enlargement assessment by plain X-ray & Nasoendoscopy. *Iraqi journal of community medicine.* 2012; 25:88-91.
- 11- Johnston J, Hoggard M, Biswas K, Astudillo-García C, Radcliff FJ, Mahadevan M, Douglas RG. Pathogen reservoir hypothesis investigated by analyses of the adenotonsillar and middle ear

- microbiota. *Int J Pediatr Otorhinolaryngol.* 2019 Mar;118:103-9.
- 12- Yousaf M, Inayatullah, Khan F. Medical versus surgical management of otitis media with effusion in children. *J Ayub Med Coll Abbottabad.* 2012 Jan-Mar;24(1):83-5.
- 13- Damoiseaux RA, Rovers MM. AOM in children. *BMJ Clinical Evidence* 2011;pii:0301.
- 14- Mikals SJ, Brigger MT. Adenoidectomy as an adjuvant to primary tympanostomy tube placement: a systematic review and meta-analysis. *JAMA Otolaryngol Head Neck Surg.* 2014 Feb;140(2):95-101.
- 15- Boonacker CW, Rovers MM, Browning GG, Hoes AW, Schilder AG, Burton MJ. Adenoidectomy with or without grommets for children with otitis media: an individual patient data meta-analysis. *Health Technol Assess.* 2014 Jan;18(5):1-118.
- 16- Hao J, Chen M, Liu B, Yang Y, Liu W, Ma N, Han Y, Liu Q, Ni X, Zhang J. Compare two surgical interventions for otitis media with effusion in young children. *Eur Arch Otorhinolaryngol.* 2019 Aug;276(8):2125-31.
- 17- van den Aardweg MT, Schilder AG, Herkert E, Boonacker CW, Rovers MM. Adenoidectomy for otitis media in children. *Cochrane Database Syst Rev.* 2010 Jan 20;(1):CD007810.
- 18- Xu J, Dai W, Liang Q, Ren D. The microbiomes of adenoid and middle ear in children with otitis media with effusion and hypertrophy from a tertiary hospital in China. *Int J Pediatr Otorhinolaryngol.* 2020 Jul;134:110058.
- 19- Buzatto GP, Tamashiro E, Proenca-Modena JL, Saturno TH, Prates MC, Gagliardi TB, Carezzi LR, Massuda ET, Hyppolito MA, Valera FC, Arruda E, Anselmo-Lima WT. The pathogens profile in children with otitis media with effusion and adenoid hypertrophy. *PLoS One.* 2017 Feb 23;12(2):e0171049.
- 20- Saafan ME, Ibrahim WS, Tomoum MO. Role of adenoid biofilm in chronic otitis media with effusion in children. *Eur Arch Otorhinolaryngol.* 2013 Sep;270(9):2417-25.
- 21- Kania R, Vironneau P, Dang H, Bercot B, Cambau E, Verillaud B, Camous D, Lamers G, Herman P, Vicaud E, Tessier N, Van Den Abbeele T. Bacterial biofilm in adenoids of children with chronic otitis media. Part I: a case control study of prevalence of biofilms in adenoids, risk factors and middle ear biofilms. *Acta Otolaryngol.* 2019 Apr;139(4):345-50.
- 22- Torretta S, Drago L, Marchisio P, Gaffuri M, Clemente IA, Pignataro L. Topographic distribution of biofilm-producing bacteria in adenoid subsites of children with chronic or recurrent middle ear infections. *Ann Otol Rhinol Laryngol.* 2013 Feb;122(2):109-13.
- 23- Yan J, Bassler BL. Surviving as a Community: Antibiotic Tolerance and Persistence in Bacterial Biofilms. *Cell Host Microbe.* 2019 Jul 10;26(1):15-21.
- 24- Saki N, Nikakhlagh S, Salehe F, Darabifard A. Incidence of Complications Developed after the Insertion of Ventilation Tube in Children under 6 years old in 2008-2009. *Iran J Otorhinolaryngol.* 2012 Winter;24(66):15-8.
- 25- Vahedian M, Salimi A, Garkaz O, Abdi S T , Donyadideh S , et al. A Study of Surgical Complications of Ventilation Tube Insertion in Children in Central Iran, *J Compr Ped.*2020; 11(3):e102108.