قســــــم : التشريح والهستولوجى - كلية الطب البيطرى - جامعة أسيوط .
رئيس القســم : أ . د / عبد الله حفنى طــه .

منبع وتوزيع الأعصاب المحركة للعين فى الجمل وحيد السنام

رشــاد فتح الباب ، عبد الله حفنى ، أحمــد قنــاوى ، محمد المحـــــرزى

تم فى هذا البحث دراسة العصب محرك العين وهو ثالث الأعصاب المخية ويخرج عن طريق الثقب الحجابى حيث ينقسم الى :

١ - الفرع الظهرى الذى يغذى العضلة المستقيمة الظهرية لمقلة العين والرافعة الجفنية العلويـــــــة

٢ - الفرع البطنى وهو اكبر الفرعين ويعطى الياف حركية للعقدة الهدبية كما يعطى فروعا للعضـــــلات المستقيمة البطنية والانسيه وينتهى فى العضلة المنحرفة السفلى .

كما تم دراسة العصب البكرى وهو رابع الاعصاب المخية وأصغرها ويخترق الخيمة المخيخية ليترك القحاف عن طريق الثقب الحجابى ليغذى العضلة المنحرفة العلوية لمقلة العـــين .

كذلك تم دراسة العصب السعد وهو سادس الاعصاب المخية ويخترق الام الجافية مع العصب محرك العين والعصب العينى ليصل الحجاج عن طريق الثقب الحجابى حيث يغذى العضلة المستقيمة الوحشية ومسترجعة العـــــين .

Dept. of Anatomy and Histoloty,
Faculty of Vet. Med., Assiut University,
Head of Dept. Dr. A. Hifny.

THE MOTOR NERVES OF THE EYE, ORIGIN AND DISTRIBUTION IN THE ONE HUMPED CAMEL (Camelus dromedarius)

(With One Figure)

By

M.R. FATH-ELBAB, A. HIFNY, A.K. AHMED and M. EL-M. ABDEL-MONEIM

(Received at 16/11/1981)

SUMMARY

The origin, course and distribution of the oculomotor, trochlear and abducent nerves were described in details. The quadriangular ciliary ganglion was also completely described. The present results were discussed with the available leteratures of other domestic animals.

INTRODUCTION

The anatomical features of the cerebral nerves suppling the ocular muscles are completely described in domestic animals other than camel. PRINCE et al. (1960), GODINHO and GETTY (1971, 1975) and SEIFRLE (1975) gave a detailed describtion of the motor nerves of the eye, however, the lack of such knolwdge in the one humped camel necessitates carring on this investigation.

MATERIAL and METHODS

The present study was carried on 10 heads of adult camels (Camelus dromedarius) of both sexes and different ages. The specimens were collected from Cairo slaughter hause. The heads were injected by 10% formalin solution and preserved for 24 hours before dissection was carried on. The nomenclature used is that adopted by NOMINA ANATOMICA VETERINARIA (1973).

RESULTS

N. Oculomotorius:

The oculomotor nerve (1/1,2) orginates by about five roots from the lateral border of the Fossa intercururalis. It passes in a rostrodorsal direction with lateral inclination to pierce the deep surface of the dura mater cerebri at a level with the infundibulum of the pitutary gland and appears on the dorsal surface of the cavernous sinus and rete merabile epidurale rostromedial to the trochlear nerve. The oculomotor nerve passes through foramen orbitorotundum venteral to the trochlear nerve and medial to the ophthalmic and maxillary nerves. Just rostral to the Foramen orbitorotundum, the oculomotor nerve divides into a dorsal smaller and a ventral larger branch.

The dorsal branch of the oculomoter nerve (1/2) passes in a rostral direction ventral to the trochlear nerve and disappears under M. rectus dorsalis where it divides into 3-4 branches which enter and supply the substance of this muscle. From these branches originate one or two twigs which traverse M. rectus dorsalis to terminate in M. levator palpebrae superioris.

The ventral branch of the oculomotor (1/1) passes in a rostral direction medial to the nasociliary nerve till it reaches the apex of the muscle cone where it enters between the origin of Mm. rectus dorsalis and rectus lateralis, accompanied dorsally by long ciliary nerve. The ciliary ganglion is situated on the ventral branch of the oculomoter nerve as it passes between the above mentioned muscles from one side and the ventro-lateral aspect of the optic nerve on the other one. The ventral branch of the oculomotor nerve gives off 2-3 small twigs to the M. rectus ventralis at the level of and rostral to the ciliary ganglion continues medial to the ganglion in a rostroventral direction where it joins the communicating branch of the maxillary nerve, the venteral branch of the oculomotor nerve continues its course venteral to the belly of the M. rectus ventralis from its caudal end to its rostral one and then ventral to the Corpus adiposum intraperiorbita reach the caudal border of the M. obliquus ventralis in which it terminates

by dividing into 3-4 small branches.

Ganglion Ciliare:

The ciliary ganglion is a quadriangular structure situated between the distal fourth of Mm. rectus lateralis and rectus ventralis in relation to the lateroventral aspect of the optic nerve. The ciliary ganglion receives twigs from the ventral branch of the oculomotor nerve after giving a branch to M. rectus medialis, in addition, it receives Ramus communicans cum ganglion ciliare of the nasociliary nerve which enters the ganglion through its caudodorsal angle. From its rostrodorsal angle the ciliary ganglion gives off the short ciliary nerves which divide into two groups one on the medial and other on the lateral side of the optic nerve.

N. Trochlearis:

The trochlear nerve (Fig. 1/7) is originated from the dorsal wall of the mesencephalon and descends within the dural fold of the tentorium cerebelli and pierces it just rostral to the pons and appears on the ventral surface of the dura mater cerebri in a point between the oculomotor nerve medially and the trigeminal nerve laterally.

About 1.5-2 cm. from its origin the trochlear nerve comes in relation with the dorsolateral aspect of the oculomotor nerve, leaves the Foramen orbitorotudum dorsal to the oculomotor nerve then continues dorsal to the dorsal branch of the latter till the apex of the muscle cone where it passes within the periorbita, crossing the dorsal surface of the M. rectus dorsalis where it detaches fine twigs to this muscle. The trochlear nerve enters the caudodorsal border of the initial part of M. obliquus dorsalis after giving off a fine twig to the same muscle.

N. abducens :

The abducent nerve (Fig. 1/8) originates from the Corpus trapezoidum and passes in a rostral direction ventral to the pons where it pierces the Dura mater encephali and continues ventral to the dural sheath of the semilunar ganglion and the initial part of the trigeminal nerve. The abducent nerve continues along the ventral aspect of the maxillary nerve for about 1.5 cm. then along the ventromedial border of the later nerve passing within the cavernus sinus and the Rete merabile epidurale rostrale. At the Foramen orbitorotundum, the abducent nerve lies ventral to the medial branch of the ophthalmic nerve and medial to the maxillary nerve It leaves the before mentioned foramen and continues ventral to the medial branch of the ophthalmic nerve, on reaching the apex of the ocular muscle cone it crosses the nasociliary nerve laterally and passes between the Mm. rectus dorsalis and rectus lateralis lateral to the before mentioned nerve. The abducent nerve continues for a short distance between the M. rectus lateralis and the lateral aspect of the M. retractor oculi where it terminates by dividing into three muscular branches one for each muscle nearly at the level of its caudal third.

DISCUSSION

Similar to that of camel, in other domestic animals (GODINHO and GETTY 1975) the oculomotor nerve is divided into dorsal and ventral branches. The dorsal branch supplies Mm rectus dorsalis and levator palpebrae superioris. The ventral branch supplies Mm. rectus ventralis, rectus medialis and obliquus ventralis, in addition, the ciliary ganglion is situated on this branch.

According to GODINHO and GETTY (1975) the trochlear nerve in horse and pig arises from the rostral cerebral peduncle just caudal to the caudal colleculus while in bovines, ovines and dogs, the nerve emerges at the rostral medullary velum as stated also by SEIFERLE (1975).

The trochlear nerve reaches the orbit through the foramen orbitorotundum in camel as: in swines, bovines and ovines (GODINHO and GETTY 1975).

The branch given from N. trochlearis to M. rectus lateralis in the camel is not stated by GODINHO and GETTY (1975) and SETFERIE (1975).

The abducent nerve arises in camel at the level of corpus trapezoidum as stated by SEIFRLE (1975) in all animals and by GODINHO and GETTY (1975) in bovines and ovines.

According to GODINHO and GETTY (1975), the abducent nerve in the dog and pig innervates the dorsal and ventral protions of M. retractor bulbi, while the same nerve in ruminants and horse is distributed in the whole muscle in addition to M. rectus lateralis.

DIRECTIONS TO THE CONTRIBUTERS

The journal is published to cover subjects in veterinary and allied sciences.

Correspondance and manuscripts should be sent to the Secretary of the Editorial Board, Faculty of Veterinary Medicine, Assiut University, Assiut, Egypt.

Three manuscripts must be submitted (an original & 2 coupies) either Arabic or English. The articles must be accumpanied by a letter from the place in which the articles have been completed. All manuscripts must be signed by all investigators sharing in the article. The article should not exceed 10 pages including tables and figures. The text must be typewritten on one side of quarts paper measuring 21 X 29.7 cm with a left and right margin of 4 cm and double spacing. Each english manuscript must be accompanied by an arabic summary. Summaries must not exceed in length 20 lines of typescript or, in the case of short communication 10 lines. A line comprieses 60 type characters. At the head of the manuscript in addition to the full name of the author, there must appear the official designation of the place where the work was carried out and the head of that place. Addresses of the other contributors must be metnioned at the end of the first page. Name of authors in the text must be in capital letters. Each orginal article must be as a general rule devided into: SUMMARY, INTRODUCTION, AIMS AND OBJECTS, MATERIAL AND METHODS, RESULTS, DISCUSSION, REFERENCES and ARABIC SUMMARY.

The number of illustration and tables must be stated at the paper just below the title of the article.

The number of tables, charts and plates should be strictly restricted as the cost of publication is high. A limited number of plates illustrating the articles are normally paid for by the journal, but the authors may, however be required to share in paying the entire costs of plates or charts if they are far too many for a single article. Coloured plated will not be reproduced, except under exceptional circumstances or when the auther is willing to bear the entire cost.

The list of references should be in alphabetical order of the authors. Each reference should consists of the following: Author, Authers (Surname and Initials of Christian names,) Years of publication, Title of the article, Name of the periodic, Number and page number (first, last). Books or the non-serial publications which are quoted in the references must be cited as follows: Authors or Authors name, Year of publication, Title of book, Publisher, and Place of Publication. Articles not yet publiched must be denoted by the expression in press.

Articles are considered for publication on the understanding that they have neither been published before nor are being considered for publication elsewhere.

A copy of the proof will be sent to the first auther and it should be returened without delay (two weeks maximum) fully corrected. Any change in the matter is not permissible at that stage.

The Journal will supply 25 reprints free of charge, further reprints can be purchased. Orders for reprints must reach the secretary of the editorial board not latter than the time of printing the article.

REFERENCES

Godinho, H.P. and Getty, R. (1971): The branches of the ophthalmic and maxillary nerves to the orbit of the goat, sheep and ox. Arquivos da Escola de veterinaria (Belo Horizonte, Brail) 23, 229-241.

Godinho, H.P. and Getty, R. (1975): Crnial nerves in Getty: Sisson and Grossman's the anatomy of the domestic Animals. 5th ed. W.B. saundere company philadelphia London. Toronto.

Nomina Anatomica Veterinaria: Publ. by the Int. Committee on Vet. Anat. Nomenclature of the World Ass. Vet. Anat. 2nd ed., Wien (1973).

Prince, J.H., C.D. Diesem; I. Egltis, and Ruskell G.L. (1960): Anatomy and Histology of the eye and orbit in domestic animals: Charles C. Thomas Publisher. Springfield, Illinois.

Seiferle, E. (1975): Gehirnnerven in: R. Nickel, A. Schummer and E. Seifrle, Lehrbuch der Anatomie der Haustiere, Bd. IV, Verlag Paul Parey, Berlin and Hamburg.

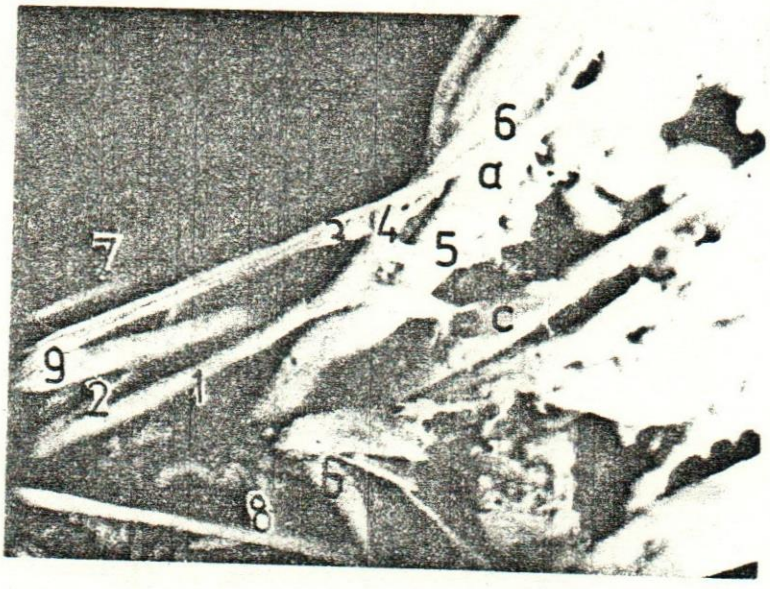

Fig. (1): Motor nerves of the eye of Camel.

a) N. opticus, b) rectus lateralis,
c) rectus ventralis

1) R. ventralis of N. oculomotorius, 2) R. dorsalis,
3) R. communicans cum ganglio ciliaris, 4) Ganglio ciliaris,
5) Nn. ciliares breves, 6) N. ciliaris longus,
7) N. trochlearis, 8) N. abducens,
9) N. nasociliaris.