

- قسم التشريح
- كلية الطب البيطري - جامعة أسيوط.
- رئيس القسم : دكتور/ عبد الله حفنى

مسار وتوزيع الشريان الصدرى الداخلى في البغل

عبد الله حفنى ، أحمد تناوى ، اسماعيل عبد العزيز

ينشأ الشريان الصدرى الداخلى من الشريان تحت الترقوى مقابل منتصف الحيز الضلعي الأول يعطى الشريان الصدرى الداخلى فروعاً ثابتة وفروعاً بين ضلعيه بطنيه وكذلك الشريان التامورى الحجابى ثم ينقسم مقابل الحافه الخلفيه للغضروف الضلعي الثامن أو السادس الى الشريان العضلى الحجابى والشرسوفى الأمامى . هذا وقد وجد أن الفروع بين ضلعيه البطنيه التي تخرج من الشريان الصدرى الداخلى تتحدد مع نهايات الشرايين بين الضلعية الظهرية والتي تنشأ من الأبهـر الصدرى .

Dept. of Anatomy and Histology,
Faculty of Vet. Med., Assiut University,
Head of Dept. Dr. A. Hifny.

**COURSE AND DISTRIBUTION OF A. THORACICA INTERNA
IN MULE (*Equus hinus*)
(With One Fig.)**

By
A. HIFNY, A.K. AHMED and I.A. IBRAHIM
(Received at 16/11/1981)

SUMMARY

The origin, course and distribution of the internal thoracic artery in mule (*Equus hinus*) were completely described.

The branches and termination of the internal thoracic artery in mule resemble those found in most domestic animals, however, the differences between this animal and other domestic animals were discussed.

INTRODUCTION

The available literature about the anatomy of the vascular system of the mule is meagre. The aim of this study is to describe the arterial blood supply of the ventral wall of the thorax. The obtained results were completely discussed with that of other domestic animals.

MATERIAL and METHODS

This study was carried out on 10 adult healthy mules, 7 males and females. The animals were bled, injected through the common carotid artery with 10% formalin solution, then with gum milk (Latex) after about one week. The Nomenclature used is that adopted by NOMINA ANATOMICA VETERINARIA (1973).

RESULTS

The internal thoracic artery (1/1) is given off the ventral aspect of the subclavian artery at the level of the 1st intercostal space. It courses gently in a ventrocaudal direction under the parietal pleura. At the level of the 2nd rib, it continues its course caudally under cover of *M. transversus thoracis* to terminate at a level with the caudal border of the eighth costal cartilage by dividing into *A. musculophrenica* and *A. epigastrica cranialis*.

Along its course, the internal thoracic artery detaches *Rr. intercostales ventrales II-V*, *Rr. perforantes I-VII* and *A. pericardiophrenica*, in addition to *Rr. sternales*.

Rr. intercostales ventrales II-V:

Each ventral intercostal branch (1/2) arises at the corresponding interchondral space, and ascends between *Mm. intercostales interni* and *transversus thoracis*. On reaching the level of the costochondral junction, it divides into *R. precostalis* and *R. postcostalis*.

A. HIFNY et al.

The precostal branch (1/3) ascends along the cranial border of the following rib and unites with one of the collateral branches of the dorsal intercostal arteries. It detaches small twigs to Mm. intercostales, serratus ventralis thoracis, pleura and ribs.

The postcostal branch (1/4) which is larger than the precostal one, ascends subpleurally along the caudal border of the corresponding rib to join the corresponding dorsal intercostal artery. It sends fine twigs to supply Mm. intercostales, rectus thoracis and serratus ventralis thoracis, pleura, and ribs.

Rr. perforantes I-VII:

The segmental perforating branches (1/5) are given off at the level of the corresponding interchondral space. These branches vascularize M. transversus thoracis and emerge through the corresponding interchondral spaces to supply the pectoral muscles, cranial part of M. rectus abdominis, sternum and skin of the sternal region.

A. pericardiophrenica:

The pericardiophrenic artery (1/6) is a very small vessel which arises opposite to the 6th intercostal space. It ascends in the caudal mediastinum on the left side, and in the plica venae cavae on the right side accompanying the corresponding phrenic nerve to supply the diaphragm. Moreover, it gives collateral branches to the pericardium and pleura.

A. musculophrenica:

The musculophrenic artery (1/7) is one of the two terminal branches of the internal thoracic artery and arises at a level with the caudal border of the eighth costal cartilage. It courses in a caudodorsal direction along the costal part of the diaphragm where it terminates by forming an arch with the cranial branch of A. intercostales dorsales XIII.

During its course, the musculophrenic artery detaches Rr. intercostales ventrales VI-XII, Rr. phrenicae and Rr. musculares for M. transversus abdominis.

Rr. intercostales ventrales VI-XII:

These ventral intercostal branches (1/8) arise segmentally from the musculophrenic artery, at the corresponding interchondral spaces. They ascend between the intercostal muscles, then subpleurally along the caudal border of the corresponding rib to join the dorsal intercostal arteries. They supply the intercostal muscles and pleura. In addition, they give off Rr. cutanei laterales VII-XII which pierce the external oblique abdominal muscle and terminate in M. cutaneous trunci, the fascia and skin of the lateral thoracic wall.

Rr. phrenicae:

Four to six phrenic branches (1/9) are given from the dorsal aspect of the musculophrenic artery at irregular intervals. These branches pass dorsally in the costal part of the diaphragm and terminate before reaching its tendinous center.

A. epigastrica cranialis:

The cranial epigastric artery (1/10) forms the direct continuation of the parent vessel at the level of the caudal border of the 8th costal cartilage. It passes caudalwards between

A. THORACICA INTERNA IN MULE

the 9th costal cartilage and xiphoid process to gain the dorsal aspect of M. rectus abdominis. It continues within the substance of this muscle and terminates by anastomosing with A. epigastrica caudalis at the umbilical region. It detaches regular segmental Rr. mediales and laterales for M. transversus abdominis.

DISCUSSION

The origin and mode of division of A. thoracica interna in *Equus hinnus* resembles that reported by WILKENS and MUNSTER (1976) and SIMOENS *et al.* (1979) in horse, dog, pig and cattle and in camel by ATTIA (1980).

The division of the ventral intercostal branches into a pre- and postcostal branches was also described by OPTIZ (1961) from the 3rd to the 8th intercostal space in cat, by MORTHEEN (1939) and MILLER *et al.* (1964) from the 2nd to the 8th intercostal spaces in dog and by OTTO (1961) from the 2nd to the 6th intercostal spaces in goat and ATTIA (1980) from the 2nd to the 6th intercostal spaces in camel.

The origin of the pericardiophrenic artery is similar to that stated by WILKENS and MUNSTER (1976) and SIMOENS *et al.* (1979) in most domestic animals, while in camel the pericardiophrenic artery arises by a stem vessel with the superficial cranial epigastric artery as stated by ATTIA (1980).

The musculophrenic artery in *Equus hinnus* possesses a similar origin to that of horse as stated by BRADLEY (1949), GHOSHAL (1975) and WILKENS and MUNSTER (1976); in cat by OPTIZ (1961) and CROUCH (1969); in dog by MARTHEM (1939), BRADLEY and GRAHAM (1959) and MILLER *et al.* (1964) and in cattle by RAGHAVAN (1964).

The ventral intercostal branches of the musculophrenic artery are similar to those in horse (BRADLEY, 1947); in cat (OPTIZ, 1961 and CROUCH, 1969); in dog (MARTHEM, 1939); in pig (KAHLER, 1960 and GHOSHAL, 1975) and in cattle (SEIDLER, 1966).

According to WILKENS and MUNSTER (1976) the segmental medial and lateral branches of the cranial epigastric artery in pig and ruminants anastomose with branches from A. musculophrenica. These anastomoses are not found in *Equus hinnus*.

REFERENCES

- Attia, M.M. (1980): Anatomical studies on the arterial blood supply of the trunk in the one humped camel (*Camelus dromedarius*). Thesis M.V.Sc., Assiut Univ.
- Bradley, O. (1974): The Topographical Anatomy of the thorax and abdomen of the horse. W. Green and Son, Limited, Edinburgh.
- Bradley, O. and Graham (1959): Topographical Anatomy of the dog Edinburgh and London, Oliver and Boyd.
- Crouch, J.E. (1969): Text-Atlas of cat Anatomy. Lea and Febiger, Philadelphia.
- Ghoshal, N.G. (1975): Heart and arteries in SISSON and GROSSMAN. The Anatomy of the Domestic Animals. Rev. by R. GETTY; 5th Edition, Ed. I, II.
- Kahler, W. (1960): Arterien der Körperwand des Schweines. Hannover, Tierarwt-Hochsch., Diss. Med. Vet.

A. HIFNY, et al.

- Marthen, G. (1939): *Über die Arterien der Körperwand des Hundes.* Hannover. Tierarwtl' Hochsch. Diss. Med. Vet.
- Miller, M.E., G.G. Christensen and H. Evans (1964): *Anatomy of the dog.* W.B. Saunders Comp. Philadelphia - London.
- Optiw, M. (1961): *Arterien der Körperwand der Katze.* Hannover, Tierarzt HOCHSCH. Diss. Med. Vet.
- Otto, E. (1961): *Arterien der Körperwand der Ziege.* Hannover, Tierarzt. Hochsch' Diss. Med. Vet.
- Raghavan, D. (1964): *Anatomy of Ox.* Indian Council of Agricultural Research. New Delhi.
- Seidler, D. (1966): *Arterien und Venen der Körperwand des Rindes.* Hannover, Tierarzt. Hochsch' Diss. Med. Vet.
- Simoens, P., H.R. DE Vos and H. Lauwers (1979): *Illustrated Anatomical Nomenclature of the heart and the arteries of the head and neck in the domestic Mammals.* Communication of Faculty of Veterinary Medicine, State University Ghent, 1-2, 1-100.
- Wilkens, H. and W. Munster (1976): *Arterien und venen;* In R. NICKEL, A. SCHUMMER und E. SEIFERLE, *Lehrbuch der Anatomie der Haustiere B. III.* Verlag P. Parey, Berlin-Hamburg.

LEGENDS

Fig. (1): Diagram showing the course and distribution of A. thoracica interna in mule. (Left side).

- A. first rib,
 - B. sternum,
 - C. humerus,
 - D. ulna,
-
- 1. A. thoracica interna,
 - 2. Rt. intercostales ventrales,
 - 3. R. precostalis,
 - 4. R. postcostalis,
 - 5. Rt. perforantes,
 - 6. A. pericardiacophrenica,
 - 7. A. musculophrenica,
 - 7. Rt. musculates,
 - 8. Rt. phrenicae,
 - 9. Rt. phrenicae,
 - 10. A. epigastrica cranialis.

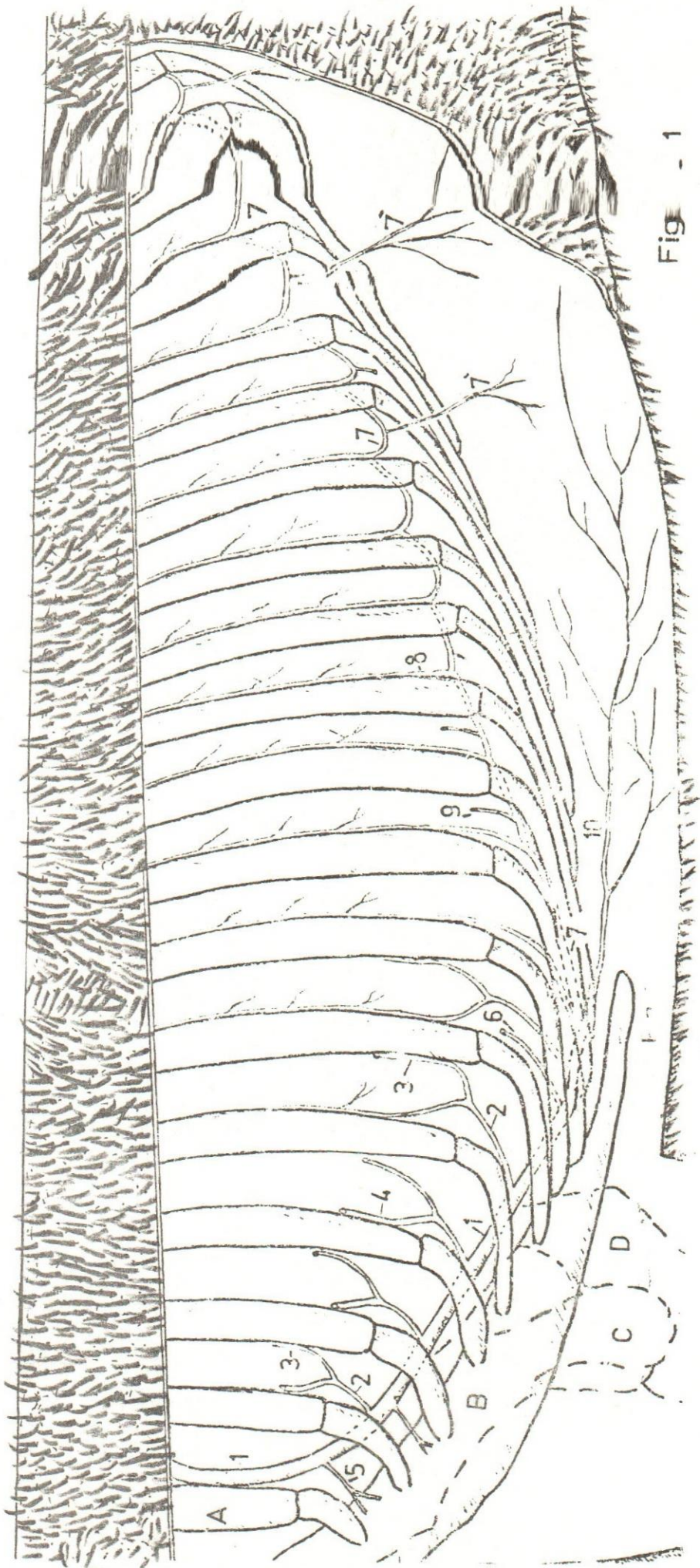


Fig - 1