

Role of Magnetic Resonance Imaging in Ebstein's Anomaly

Eman Ibrahim^a, Yasser Abdelhady^a, Ibrahim Helmy^b, Medhat Refaat^a, Mary Mahrous^b

^a Department of Radiology,
Faculty of Medicine Benha
University, Egypt.

^b Department of Radiology,
national heart institute, Giza,
Egypt.

Correspondence to: Eman
Ibrahim, Department of
Radiology, Faculty of Medicine
Benha University, Egypt.

Email:

emanelbalky889@gmail.com

Received: 21 September 2019

Accepted: 25 August 2021

Abstract:

Background: Background: Ebstein's anomaly is an uncommon clinical syndrome accounting for approximately 0.5% of congenital heart disease (CHD) patients. It is defined as a congenital displacement of the posterior and septal leaflets of the tricuspid valve towards the right ventricular apex which results in atrialization of a part of the right ventricle. **Aim and objectives:** Review the pathological spectrum of Ebstein's Anomaly in adults, illustrate by MR the morphologic aspects of EA. Discuss MR Findings of right ventricular overload including right ventricular dimension, paradoxical ventricular septal motion. Emphasize the role of MR in the assessment of ventricular and valvular function. Demonstrate the use of delayed contrast-enhanced MR to rule out segments of myocardial dysplasia, Subjects and Methods: The present study involved twenty patients who were previously diagnosed for assessment and treatment of Ebstein's anomaly. The clinical records and surgical details of all identified patients were examined, and Participants were selected from the outpatients in National Heart Institute, Giza, Egypt. Results: results of the study revealed that Ebstein's anomaly severely affecting tricuspid regurge since 75% of patients (15 of 20) were affected while only one patient (5%) suffered of mild regurge and four patients (20%) suffered of moderate regurge, Conclusion: The diagnosis of Ebstein's anomaly is usually based on echo findings; however, cardiac magnetic resonance imaging(CMR) can add useful information enabling a detailed visualization of cardiac abnormality, as well as a method of accurate physiological evaluation. CMR, in conjunction with echocardiography, offers a comprehensive non-invasive evaluation either for surgical management or ongoing follow-up of these patients.

Keywords: Ebstein's Anomaly, Congenital Heart Disease, Magnetic Resonance Imaging.

Introduction

Ebstein's anomaly is an uncommon clinical syndrome accounting for approximately 0.5% of congenital heart disease (CHD) patients. It is defined as a congenital displacement of the posterior and septal leaflets of the tricuspid valve towards the right ventricular apex which results in atrialization of a part of the right ventricle. It is almost always associated with tricuspid insufficiency. (1)

It can also be associated by other anomalies like atrial septal defect (ASD), isolated severe tricuspid regurgitation, L-transposition of great vessels, bicuspid or atretic aortic valves, pulmonary atresia or hypoplastic pulmonary artery, subaortic stenosis, coarctation, mitral valve prolapse, accessory mitral valve tissue or muscle bands of the left ventricle, ventricular septal defects, and pulmonary stenosis. (1)

Etiology:

1. Unknown
2. Maternal Lithium ingestion

Symptoms: Mild forms of Ebstein's anomaly may not cause symptoms until later in adulthood. If signs and symptoms are present, they may include:

Fetus: Hydrops.

Neonates: Severe cyanosis & circulatory collapse.

Infant:

- Shortness of breath, especially with exertion
- Fatigue
- Heart palpitations or abnormal heart rhythms (arrhythmias)
- A bluish discoloration of the lips and skin caused by low oxygen (cyanosis).

Adult: Mild symptoms or no symptoms

• **Pathological Anatomy:**

In the normal heart, the tricuspid valve has 3 leaflets: anterior, posterior, and septal. Ebstein's anomaly is a malformation of the tricuspid valve and right ventricle characterized by (1) adherence of the septal and posterior leaflets to the underlying myocardium (failure of delamination, namely splitting of the tissue by detachment of the inner layer during embryologic development); (2) downward (apical) displacement of the functional annulus (septal > posterior > anterior); (3) dilation of the "atrialized" portion of the right ventricle, with various degrees of hypertrophy and thinning of the wall; (4) redundancy, fenestrations, and tethering of the anterior leaflet; and (5) dilation of the right atrioventricular junction (true tricuspid annulus). (1, 6)

The apical displacement of the hinge point of the valve in Ebstein's anomaly from the atrioventricular ring is shown downwards. The point of maximal displacement is at the commissure between the posterior and septal leaflets of the tricuspid valve. In normal human hearts, the downward displacement of the septal and posterior leaflets in relation to the anterior mitral valve leaflet is $<8 \text{ mm/m}^2$ body surface area. The spectrum of the malformation in Ebstein's anomaly may range from only minimal displacement of the septal and posterior leaflets to an imperforate membrane or muscular shelf between the inlet and trabecular zones of the right ventricle.(1)

The anterior leaflet is generally redundant and may contain several fenestrations. Its chordae tendineae are generally short and poorly formed. Moreover, the anterior leaflet of the tricuspid valve may be severely deformed, so that the only mobile leaflet tissue is displaced into the right ventricular outflow tract, where it may cause obstruction or form a large sail-like intracavitary curtain. (1,2)

Patients and Methods

Participants were selected from the outpatients attending National Heart Institute, Giza, Egypt from June 2017 to June 2019. All cases were subjected to clinical examination to investigate the

presence of previous or recent hepatic, renal disorders and diabetes mellitus, which might affect the parameters to be investigated.

A prospective study involved twenty patients who were previously diagnosed **for assessment** and treatment of Ebstein's anomaly of the tricuspid valve.

An informed consent obtained from patients newly diagnosed with Ebstein's anomaly before inclusion in the study.

The study is subjected by the ethics committee of the national heart institute.

The clinical records, ECG, Holter monitor, chest x-rays, and echocardiograms, resting oxygen saturation and surgical details of all identified patients were examined.

ECHO: The most recent echocardiogram was reviewed to record the presence of any atrial septal defect (ASD), degree of tricuspid valve displacement (displacement of septal leaflet from the atrioventricular junction), severity of tricuspid regurgitation (assessed by color Doppler), right atrial size, right ventricular systolic pressure (as assessed from tricuspid regurgitation assuming an estimated right atrial pressure of 10mmHg) and presence of right ventricular outflow tract obstruction (Doppler pressure gradient $>20\text{mmHg}$). The RA size was graded on

the basis of the maximal end diastolic RA diameter from 4 chamber apical echocardiographic views into 4 grades:

1) Being normal [40mm]; 2) mild enlargement [40-50mm]; 3) moderate enlargement [50-60mm]; and 4) severe enlargement [>60 mm]. Left-sided echocardiogram measurements included LV function (grade 1 = normal, 2 = mild dysfunction, 3 = moderate dysfunction, 4 = severe dysfunction) and the degree of mitral regurgitation (grade 1 = none or trivial, 2 = mild, 3 = moderate, 4 = severe). The presence of any left ventricular outflow tract obstruction was also noted.(1)

Diagnosis of Ebstein's Anomaly

Chest Radiograph: The cardiac silhouette reflects the severity of EA. Cardiothoracic ratio was traditionally used to determine the timing of intervention in EA; with a ratio of >0.6 as a threshold for referral. However, earlier intervention to prevent progression of RV dysfunction is now recommended.(3)

Transthoracic Echocardiography: The diagnosis of EA is established by the characteristic tethering of the septal and inferior leaflets with shift of the functional TV orifice away from the anatomic atrioventricular groove.

Apical displacement of septal leaflet hinge point provides a quantitative

echocardiographic marker for EA. Displacement is assessed by measuring the distance separating the septal tricuspid and mitral hinge points (Figure 2G) and indexing this to the body surface area (BSA).(1)

A displacement index of > 8 mm/m² supports the diagnosis of EA and can be used to differentiate it from other right heart disorders.9, 10 TV annular dilation and a leaflet coaptation gap can be seen by two-dimensional (2D) TTE in most patients with clinically significant EA.

TV leaflet tethering is also readily identified by 2D TTE (Figure 2).8 both anterior and septal leaflets are generally assessed from the apical 4-chamber view. The inferior (or posterior) leaflet is best seen from an RV inflow view (parasternal long-axis view with angulation toward the "normal" TV position) or in the subcostal long-axis view of the atrioventricular junction (Figure 5C). The parasternal short axis view is used to demonstrate the entire RV from inflow to outflow.

Vena contracta dimensions can be difficult to measure accurately with multiple regurgitation jets. Also, the typically triangular or oblong regurgitant orifice, and unusual angles of regurgitation complicate these measurements. Proximal isovelocity surface area is generally not performed for the same reasons. (1,6)

Color Doppler is used to confirm that the apparent 2D regurgitant orifice is indeed associated with TR and that the coaptation gap accurately represents the area of regurgitation. In those with less obvious gaps between the leaflets, color Doppler at the identified functional orifice is used to further outline the width of the jet(s). The area of the combined jets are “virtually summed” to approximate a vena contracta width, allowing semi-quantitative (“eyeball”) grading of the valve’s dysfunction. The apical four-chamber view may not contain the functional orifice and often does not demonstrate the regurgitant jet optimally. Regurgitant jets may be directed inferiorly, as the effective orifice is frequently oriented more toward the RV outflow tract. In this situation, subcostal sagittal and parasternal short axis views may profile the jet best. Three dimensional (3D) TTE may aid in anatomic TV and RV delineation.(1)

Transesophageal Echocardiography:

TEE is primarily used for intra-operative assessment, and rarely in those with limited acoustic windows. The mid-esophageal 4-chamber and transgastric sagittal views can show the apical displacement of functional TV annulus in a manner similar to that described for TTE.
(5)

The 4-chamber view also allows assessment of anterior and septal leaflet attachments to the myocardium. Mid-esophageal oblique view at 30-60 degrees, (equivalent of parasternal short axis view) can show the anterior rotation of the functional TV orifice into the RV outflow tract.

ASDs and PFOs can also be assessed in this view, as well as in the bicaval or 4-chamber view.

The transgastric sagittal RV inflow view is the best view to visualize the inferior TV leaflet. The deep transgastric 4-chamber view is difficult to obtain in patients with EA due to lateral displacement of apex by the dilated RV.

3D TEE has the advantage of visualizing TV in enface view from RA and RV perspectives, allowing better understanding of leaflet morphology and mobility. A full volume dataset acquisition with breath-hold is usually needed to capture all TV apparatus.(4)

Cross-sectional imaging: CMR imaging and computed tomography (CT) are complementary non-invasive imaging techniques in EA patients with limited acoustic windows, and when quantification of RV size and function are clinically necessary.(5)

Cardiac Magnetic Resonance Imaging: CMR offers better quantification of RV

size and function in Ebstein's anomaly, which are challenging to accurately quantitate by echocardiography because of the poor acoustic window. Size and function of the left and RV are assessed by obtaining a stack of steady-state free precession cine cardiac images in planes axial to the body or in short-axis (figure 3A & 3D) to the heart. End-diastolic and end-systolic areas are traced in each slice with zero gap that are stacked together to generate volumes of the ventricles in end-systole and end-diastole, allowing calculation of ejection fraction.(6)

The aRV is included in the RV volume measurements and axial stack is preferable

for analysis of the RV as it is easier to delineate atrioventricular junction and attachments of abnormal tricuspid valve in this orientation, making it a more reproducible method. However, other institutions perform volumetric analysis on the short axis stack which has the advantage of being able to obtain volume data for both the ventricles simultaneously. Inclusion or exclusion of aRV is also variable among institutions. Standard practice has been to include aRV in the RV volumes and EF as this gives more insight into the postoperative RV function when the aRV has been incorporated into the functional RV.(1)

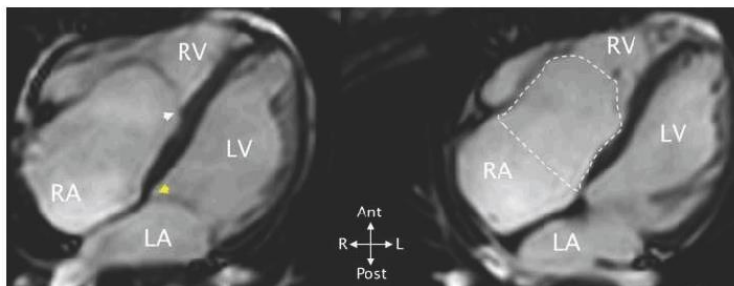


Fig:1 Demonstrate the atrialized portion by 4chamber view in CMR.

TR quantification can be performed by velocity mapping (phase contrast imaging) by setting up a plane perpendicular to the TR jet. Higher encoding velocity (VENC) in the order of 2-3 m/s is usually used to prevent aliasing. A TR jet cross-section of $\geq 6 \times 6$ mm is considered severe regurgitation in adults. (7)

Flow quantification across atrioventricular valves is generally quite challenging. This is especially true for TR quantification in EA where the regurgitant jet(s) may be multiple and have unusual directions. Moreover, the direction of jet may change in different phases of systole with annular motion of TV. (7)

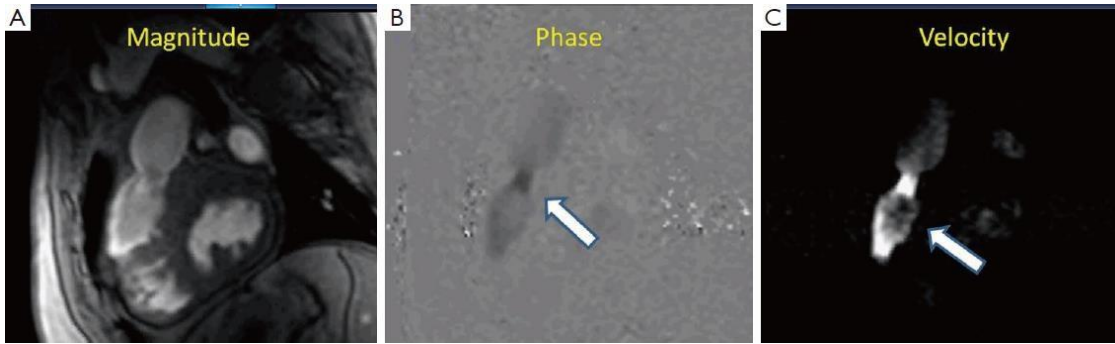


Fig 2. Valvular regurgitation across the RV outflow tract. (A) Magnitude images do not conclusively demonstrate flow disturbances across the valve; (B) the phase images (white arrow) show a hypo intense region just after the valves close, reflecting to a phase

All of these may lead to inaccuracies and lack of reproducibility between studies. Some of these limitations can be overcome by using advanced techniques, such as 4D phase contrast CMR imaging. Alternative method for TR quantification is to combine velocity mapping and cine imaging quantification;

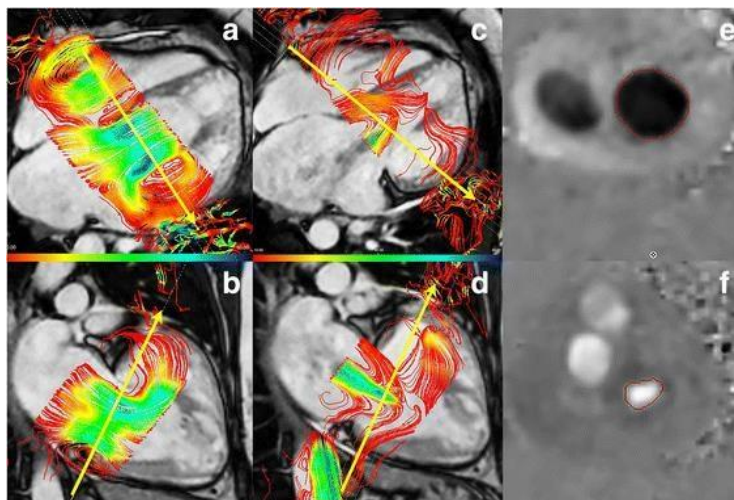


Fig 3 Example of 4D flowCMR analysis. In a-d the annular plane is reconstructed perpendicular to the flow direction, in figure e + f the flow contours are drawn in the reconstructed through-plane flow slice

the TV regurgitate volume is calculated by subtracting forward stroke volume, as measured by velocity mapping of pulmonary artery, from total RV stroke volume measured on the cine images. Regurgitant fraction can then be calculated by dividing this regurgitant volume by RV stroke volume from the cine images. (7) Atrial level shunt is best seen by

echocardiography but may also be visualized on CMR cine images of atria in the short axis orientation. Measuring the difference between aortic and pulmonary blood flow by velocity mapping can calculate the net shunt across the atrial septum at rest. Contrast is typically not needed in CMR imaging of EA, however if used, it can be valuable in identifying

inter-atrial shunt. Left-sided lesions, such as non-compaction cardiomyopathy and others can be better assessed by CMR as well. (7)

Statistical methods

Results:

Anthropometric results for gender revealed 45% of patients were males and 55% were females with equivocal percentage (fig 4). Most patients were suffering of type B tricuspid valve degree of displacement (55%), while type A and C together constituted only 45% of total patients (fig.5). Results revealed no significant effect of Ebstein's anomaly regarding right ventricular function since affecting only 55% of patients with fair function. Fair ranges from (32% to 46%) and good (range 40% to 64%) (fig.6). Ebstein's in anomaly severely affecting tricuspid regurge since 75% of patients (15 of 20) were affected while only one patient (5%) suffered of mild regurge and four patients (20 suffered

Data management and statistical analysis were done using SPSS vs. (IBM, Armonk, New York, United states). Numerical data was summarized as means and standard deviations. Categorical data was summarized as numbers and percentages.

of moderate regurge (fig.7). Ebstein's in anomaly didn't highly affected right to left shunt since only 7 patients were found to be positive (35%) while 13 patients (65%) were found to be negative for shunt (fig.8). Regional wall motion abnormality were not found affected by Ebstein's anomaly since only 8 patients (40%) had abnormality of their regional wall motion but 12 patients (60%) were not affected (fig.9). left ventricular function is not severely affected at all since only one patient (5%) of twenty patients were affected while the function good in all other patients. Fair ranges from (32% to 46%) and good (range 40% to 64%) (fig.10). There were only 2 cases (10 %) out of 20 patients found with LGE (fig. 12).

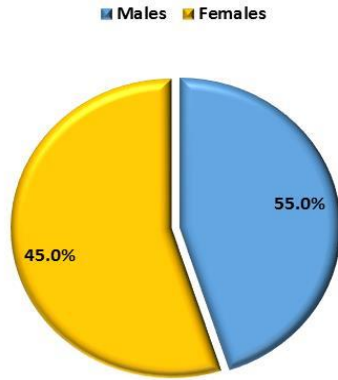


Figure (4) Demographic characteristics in the whole study population

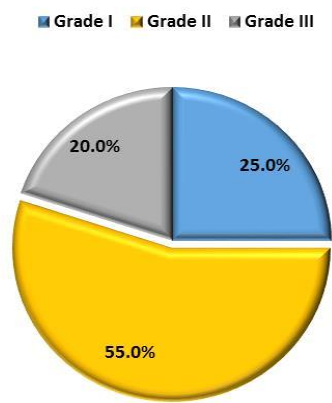


Figure (5) Tricuspid valve degree of displacement

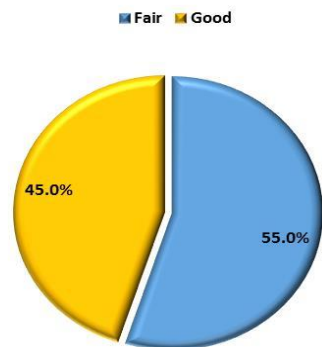


Figure (6): Right ventricular function in the whole study population

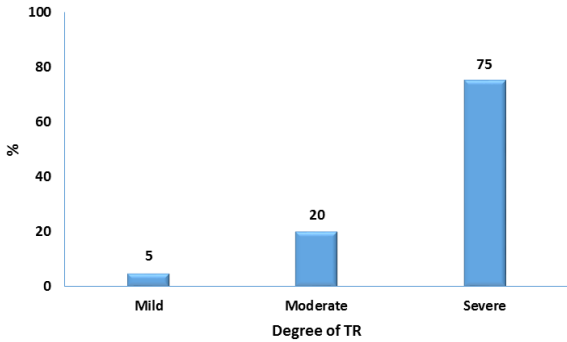


Figure (7): Degree of tricuspid regurgitation in the whole study population

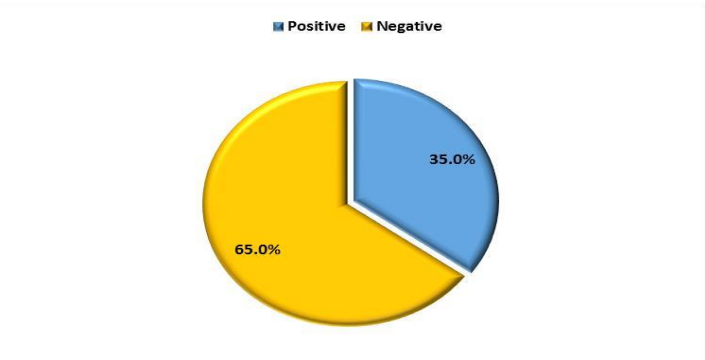


Figure (8): Right to left shunt in the whole study population

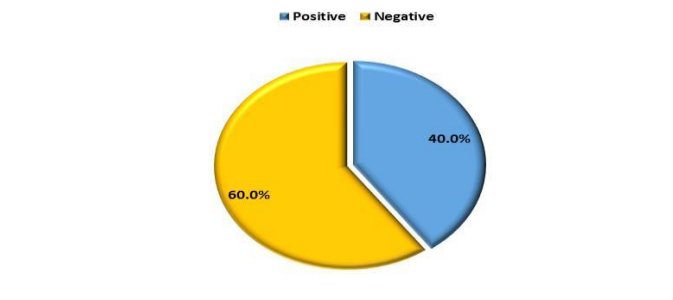


Figure (9): Regional wall motion abnormality in the wall study population

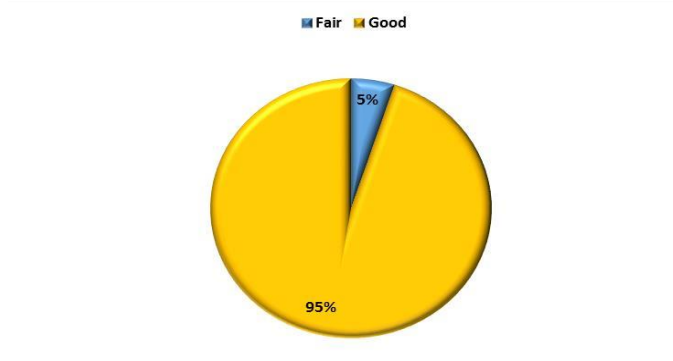


Figure (10): Left ventricular function in the whole study population

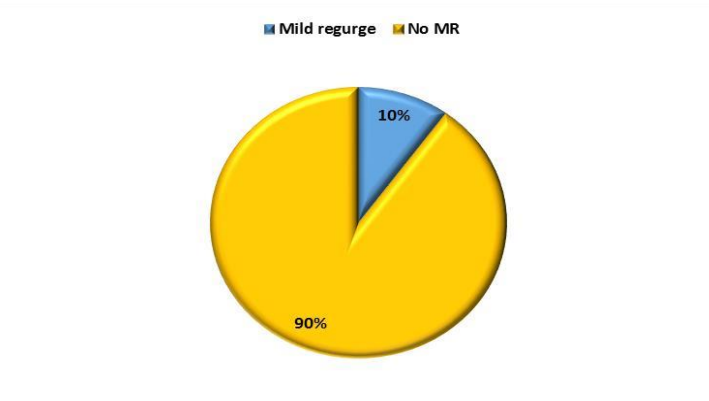


Figure (11): Mitral regurgitation in the whole study population

Table (1) pulmonary stenosis in the whole study population

Pulmonary stenosis	n (%)
Yes	0 (0.0)
No	20 (100.0)

There was no pulmonary stenosis due to Ebstein’s anomaly since there is no cases were demonstrated in this study.

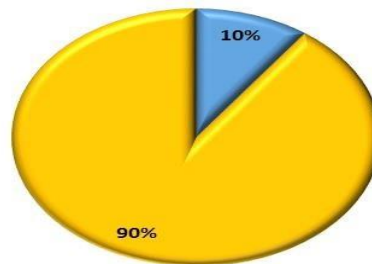


Figure (12): Late gadolinium enhancement in the whole study population

Table (2) Degree of displacement in tricuspid valve according to gender

	Males (n = 9)		Females (n = 11)		P value
	N	%	N	%	
Tricuspid valve degree of <u>displacement</u>					
Type A	4	44.4	1	9.1	0.281
Type B	4	44.4	7	63.6	
Type C	1	11.1	3	27.3	

Fisher's exact test was used for Ebstein anomaly affecting Tricuspid valve degree of displacement within the same gender and were found to be non significant (p = 0.28) either in males or females.

Table (3) Right ventricular function according to gender

Functional RV	Males (n = 9)		Females (n = 11)		P value
	N	%	N	%	
Fair	3	33.3	8	72.7	0.095
Good	6	66.7	3	27.3	

Fisher's exact test was used were calculated regarding right ventricular function according to gender. Although right ventricle was found small in size but its function was not significantly affected.

Table (4) Degree of tricuspid regurge according to gender

Degree of TR	Males (n = 9)		Females (n = 11)		P value
	N	%	N	%	
Mild	0	0.0	1	9.1	0.026
Moderate	4	44.4	0	0.0	
Severe	5	55.6	10	90.9	

Fisher's exact test was used to calculate the degree of tricuspid regurge according to gender. Results were significant ($p=0.026$) denoting effect of Ebstein's Anomaly on the tricuspid regurge.

Table (5) Right to left shunt according to gender

Right to left shunt	Males (n = 9)		Females (n = 11)		P value
	N	%	N	%	
	2	22.2	5	45.5	0.374

Fisher's exact test was used

Table (6) Regional wall motion abnormality according to gender

Regional wall motion abnormality	Males (n = 9)		Females (n = 11)		P value
	N	%	N	%	
	1	11.1	7	63.6	0.028

Females were significantly affected by Ebstein's anomaly more than males ($p=0.028$) using Fisher's exact test since 63% of females had regional wall motion abnormality but only 11% of males were affected.

Table (7) Left ventricular function according to gender

LV function	Males (n = 9)		Females (n = 11)		P value
	N	%	N	%	
Fair	0	0.0	1	9.1	1.0
Good	9	100.0	10	90.9	

Fisher's exact test was used

Table (8) Mitral regurg according to gender

Mitral Regurge	Males (n = 9)		Females (n = 11)		P value
	N	%	N	%	
Mild	1	11.1	1	9.1	1.0
No MR	8	88.9	10	90.9	

Fisher's exact test was used

Table (9) Left to right shunt according to gender

Left to right shunt	Males (n = 9)		Females (n = 11)		P value
	N	%	N	%	
Positive	2	22.2	2	18.2	1.0

Discussion

CMR allows detailed visualization of the pathological anatomy in patients with Ebstein’s anomaly. It is of great value when echocardiography image quality is inadequate due to a poor acoustic window. CMR also provides a method of accurate physiological assessment of already proven superiority to echocardiography: It is a technique for precise volumetric analysis of ventricular function and intracardiac blood flow, without any geometric assumptions. CMR delayed contrast enhancement image is a potential tool to

recognize areas of right ventricle dysplasia.(1)

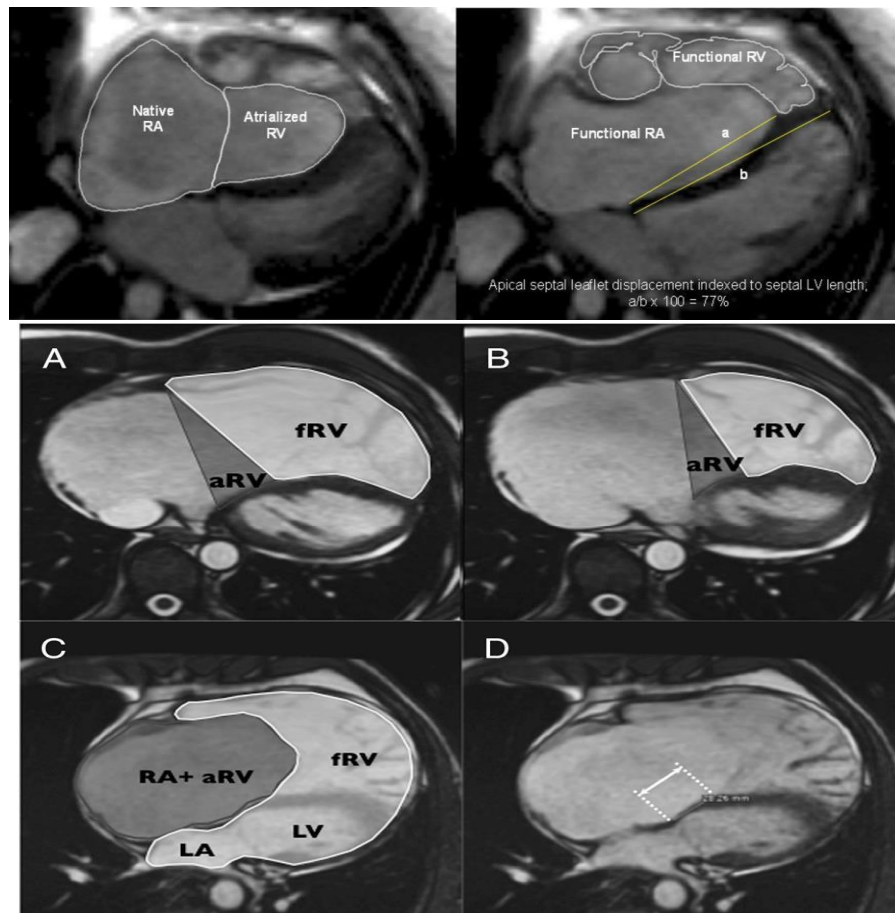
RV and LV functional analysis : In our study, 49% (range 32% to 46%) and 50% (range 40% to 64%) for the functional RV ejection fraction

CMR offers better quantification of RV function, which is challenging to accurately quantitate by echocardiography. Size and function of the left and RV are assessed by obtaining a stack of steady-state free precession cine cardiac images in planes axial to the body or in short-axis

(figure 3A & 3D) to the heart. End-diastolic and end-systolic areas are traced in each slice that is stacked together to generate volumes of the ventricles in end-systole and end-diastole, allowing calculation of ejection fraction. The aRV is included in the RV volume measurements and axial stack is preferable for analysis of the RV as it is easier to delineate atrioventricular junction and attachments of abnormal tricuspid valve in this orientation, making it a more reproducible method. However, other institutions perform volumetric analysis on the short axis stack which has the advantage of being able to obtain volume data for both the ventricles simultaneously. Inclusion or

exclusion of aRV is also variable among institutions. But in this study, practice has been to include aRV in the RV volumes and EF as this gives more insight into the postoperative RV function when the aRV has been incorporated into the functional RV. (1).

In our study, more than half of the patients (55%) RV ejection fraction ranged between 32% to 46% and in the remaining 45% of patients, ejection fraction ranged between 40% to 64%, which was comparable to other studies(7) 49% (range 32% to 46%) and 50% (range 40% to 64%) for the functional RV ejection fraction.



LV EF and percent LV length change were reduced in Ebstein's patients compared to normal. Fractional change in area and shortening of both short axes were uniformly depressed in Ebstein's relative to normal as one out of 20 patients was severely affected while the rest of patients was found out decreased to normal but in normal ranges.**(8)**

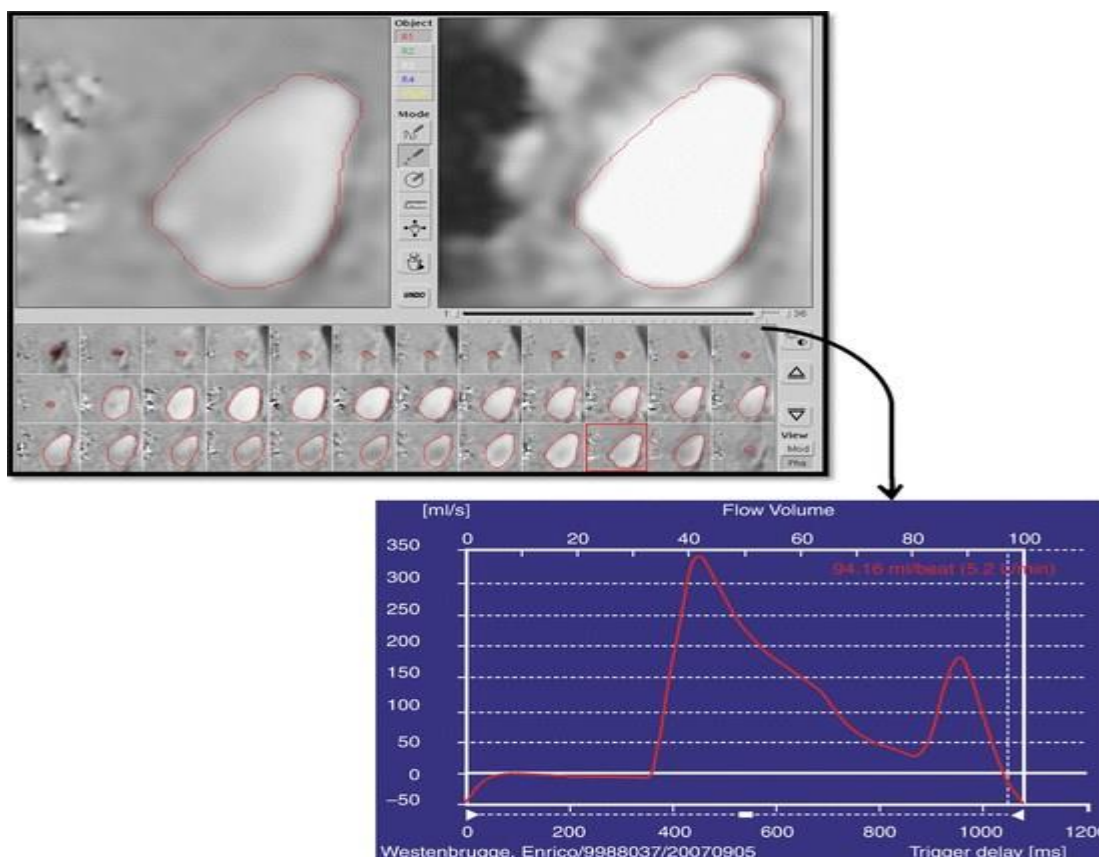
Tricuspid regurge in Ebstein’s anomaly:

In normal hearts, the septal and posterior leaflets are displaced downward in relation to the anterior mitral valve leaflet, but displacement is less than 8 mm/m²[21]. In Ebstein’s anomaly, the displacement of the

septal and posterior leaflets (> 8 mm/m²) ranges from very minimal to severe. That’s why in Ebstein’s anomaly TR found in this study severely affected 75% of patients (15 of 20) while only one patient (5%) suffered of mild regurge and four patients (20%) suffered of moderate regurge which is very close to results done by echo patients who had mild to moderate TR (44%) and (54.5%) severe TR **(9)**

The TV regurgitant volume is calculated by subtracting forward stroke volume, as measured by velocity mapping of pulmonary artery, from total RV stroke volume measured on the cine images.

Regurgitant fraction can then be calculated by dividing this regurgitant volume by RV stroke volume from the cine images. (6)



Post processing analysis of through plane phase-contrast velocity mapping images across the tricuspid valve using ARGUS program, red contours drawn around the tricuspid valve through the whole cardiac cycle that delivers a time flow curve of tricuspid valve flow

Associated anomaly of Ebstein's anomaly:

ASD: It is the most common associated anomaly found in Ebstein's as it is found in 90 % of patients in our study (18 out of 20 patients) with only 35% had right to left shunt and 20% with left to right shunt.(9) Pulmonary stenosis was not demonstrated in our study because it is a rare finding usually found in Type C (according to Carprteiner classification) (9) and most of the cases included in our study were found

to be type B(55%), while type C was shown in 20% of patients. As in type C The anterior leaflet is restricted in movement. The RV is small with a large atrialized component.

Late gadolinium enhancement (LGE) and regional motion abnormality:

Myocardial late enhancement contrast image has the ability to precisely delineate myocardial scar associated with fibrosis. In the EA scene this is an important tool to

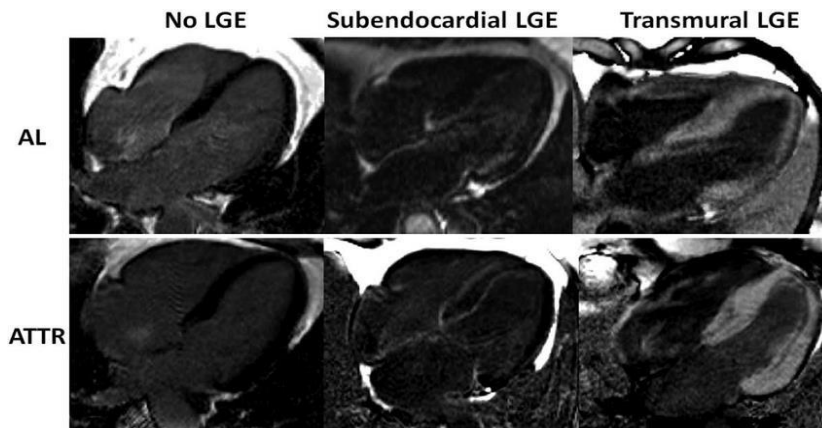
recognize areas of dysplasia of right ventricle.

The protocol consisted of stacks of balanced steady-state free-precession (bSSFP) cine images acquired in the three long-axis (two-, three-, and four-chamber) views, consecutive short-axis views covering the LV from base to apex (TR/TE 3.4 ms /1.3 ms, flip angle 50°, FOV 300 × 340 mm, matrix size 256 × 144, slice thickness 8 mm) and consecutive axial cine bSSFP images covering the whole heart extending from the pulmonary bifurcation to just below the diaphragm. LGE images were acquired using a T1-weighted inversion recovery turboflash sequence 10 to 20 min after

bolus contrast injection (Gadopentetate dimeglumine, 0.3/kg).

LGE was found in 2 (10 %) patients. Typical LGE in Ebstein's anomaly was located in the endocardium of the septum within the right ventricle (RV).this low percentage may be due to the quality of patients undergone this technique which most of them are relatively of fair to good ventricular function , in comparison to patients have LGE .

This proves that fibrosis is usually associated with the severity of EBstein anomaly. (Evidence of myocardial enhancement)



Conclusion

The diagnosis of Ebstein's anomaly is usually based on echocardiographic findings; however, cardiac magnetic resonance imaging (CMR) can add useful information enabling a detailed visualization of cardiac abnormality, as

well as a method of accurate physiological evaluation. CMR, in conjunction with echocardiography, offers a comprehensive non-invasive evaluation either for surgical management or ongoing follow-up of these patients.

References:

1. Sakai K, Nakamura K, Satomi G, Kondo M, Hirose K. Evaluation of tricuspid regurgitation by blood flow pattern in the hepatic vein using pulsed Doppler technique. *Am Heart J* 1984; 108:516– 523
2. Liu Xi, Zhang Qin, Yang Zhi-gang ,Y Guo, K Shi, H Xu (2016). Morphologic and Functional Abnormalities in Patients with Ebstein's anomaly with Cardiac Magnetic Resonance Imaging: Correlation with Tricuspid Regurgitation. *European Journal of Radiology* 1601–1606.
3. Watts Jubal R., Kumar Sushil K. Sonavane , SP Singh (2013). Pictorial Review of Multidetector CT Imaging of the Preoperative Evaluation of Congenital Heart Disease. 2013 *Curr Probl Diagn Radiol*; 42:40-56..
4. Topilsky Y, Tribouilloy C, Michelena HI, S Pislaru. Pathophysiology of tricuspid regurgitation: quantitative Doppler echocardiographic assessment of respiratory dependence. *Circulation* 2010; 122:1505–1513
5. Dearani JA, Mora BN, Nelson TJ, Haile DT and O'Leary PW (2015): Ebstein anomaly review: what's now, what's next?, *Expert Review of Cardiovascular Therapy*
6. Patrick J. Goleski a, Florence H. Sheehan a, Sylvia S.M. Chen b, Philip J. Kilner b, Michael A. Gatzoulis The shape and function of the left ventricle in Ebstein's anomaly, *International journal of cardiology* (september 2013).
7. Dan Yang, Xiao Li , Jia-Yu Sun, Wei Cheng, Tian-Jing Zhan, *Journal of Cardiovascular Magnetic Resonance* volume 20, Article number: 69 (2018).
8. Cawley PJ, Maki JH and Otto CM. Cardiovascular magnetic resonance imaging for valvular heart disease: technique and validation. *Circulation*. 2009;119:468-78.
9. Kilner PJ, Geva T, Kaemmerer H, Trindade PT, Schwitzer J and Webb GD. Recommendations for cardiovascular magnetic resonance in adults with congenital heart disease from the respective working groups of the European Society of Cardiology. *Eur Heart J*. 2010;31:794-805

To cite this article: Eman Ibrahim, Yasser Abdelhady, Ibrahim Helmy, Medhat Refaat , Mary Mahrous. Role of Magnetic Resonance Imaging in Ebstein's Anomaly, *BMFJ* 2022; 39 (Radiology): 37-54. DOI: 10.21608/bmfj.2021.17048.1063

