

SUBACUTE HISTOPATHOLOGICAL EFFECTS OF ALPHACYPERMETHRIN TECHNICAL AND ITS FORMULATION SUPER ALFA 10% EC ON LIVER, KIDNEY AND THYROID IN MALE ALBINO RATS

RIZK ALLA, M. M., M.M. TALHA AND G.A. ABD EL RAHEIM

Central Agricultural Pesticides Laboratory, ARC, Dokki, Giza

(Manuscript received 6 May 2010)

Abstract

In the present study four groups of experimental rats were treated with two different doses of technical alphacypermethrin 96% (10.5, 5.25 ppm represent 1/10, 1/20 of determined LD50) and two other doses of its formulation Super Alfa 10% EC (1.2, 0.6 ppm represent 1/10, 1/20 of determined LD50) orally for 28 consecutive days. Then samples of livers, kidneys and thyroid glands of all groups were taken and histopathologically examined. The results showed more adverse effects of technical alphacypermethrin on the liver tissue than the EC formulation, where both used doses of them produced bleeding and cirrhosis in parts of liver tissue and increasing the division of some cells. Also more effects on kidney tissues by the technical than the EC formulation and with the high doses were produced. Most kidney damages were congestion of capillaries and blood vessels and the presence of bleeding and fibrosis. The technical produced atrophy in a large number of vesicles in the thyroid tissue by the high dose, where in case of EC formulation the examination showed the glue absence in some cells of the thyroid by the high dose only.

INTRODUCTION

Pyrethroids represent a new class of insecticides which showed excellent insecticidal properties with considerable biodegradability and they are highly active insecticides when applied at lower quantities compared to other insecticides (Sauyri and Haellinger, 1983). Some of pyrethroids were found to induce histopathological alterations in the rat liver (Yavasoglu et al 2006), kidney, lung, heart, stomach and testis (Manna et al 2005, Grewall et al 2009) and mice liver and kidney (Luty et al 2000, Inayat et al 2007, Gary et al 1992), also skin effects were investigated in rats (Luty et al 1998). The present study investigate some histopathological effects of two alphacypermethrin forms in the liver, kidney and thyroid in male rats after subacute exposure at laboratory conditions.

MATERIALS AND METHODS

Chemicals:- Alphacypermethrin ((R)- cyano(3-phenoxyphenyl)methyl (1s,3s)-rel-3-(2,2-dichloroethenyl)-2,2-dimethylcyclopropanecarboxylate)technical grade 96%and its

E.C formulation 10%(super alfa) were obtained from El-Help Co. (Egypt)and used in this study.

Experimental animals: - Adult male albino rats (Wister strain) weighting 120-150g were used in this study. Animals were acclimatized for 2 weeks prior to study under normal health conditions in the animal house of the Mammalian Toxicology Department, Central Agriculture Pesticides Laboratory, were fed on a normal commercial diet and were allowed free excess of water.

Experimental design: - 25 animals were randomly divided to five groups of equal five rats each. The groups were treated as follows:

Group 1:- The animals were administrated the dose level10.5mg/kg b.w.

(1/10determined LD50) of the technical alphacypermethrin as a high dose.

Group 2:-The animals were administrated the dose level 5.25mg/kg b.w.

(1/20determined LD50) of the technical alphacypermethrin as a low dose.

Group 3:- The animals were administrated the dose level 1.2mg/kg b.w.

(1/10determined LD50) of the formulation as a high dose.

Group 4:- The animals were administrated the dose level 0.6mg/kg b.w.

(1/20determined LD50) of the formulation as a low dose.

Group 5:- The animals were received distilled water to be used as control.

All groups were treated orally by metallic stomach tube for 28 consecutive days.

Histopathological examination: - At the end of treatment period tissue specimens were taken in 10% formalin solution from the different groups of animals during the post-mortem examination and were fixed in 10% formal saline. The fixed tissues were washed in tap water, dehydrated in a series of alcohol, cleared in xylene then embedded in paraffin. Five microns paraffin sections were obtained and stained with Hematoxylin and eosin stain as mentioned by Carleton et al (1967) for histopathological examination.

RESULTS AND DISCUSSION

The histopathological examination to liver tissues of animals treated with technical alphacypermethrin 96% showed the presence of bleeding in some parts as well as fibrosis in another parts in case of both used doses. Also treatment was increased cells divisions and inflammation in the portal vein by the high dose. Kupffer cells proliferation and oedema in the portal vein area and bile duct by the low dose was noticed. In animals treated with the alphacypermethrin super alfa, showed enlargement and hyperemia in some blood vessels by the high dose and hyperemia in central veins area associated with severe inflammation and changes in kubffer cells by the low dose. These results reflected more liver tissue damages by the technical grade

than the 10% EC formulation. Manna et al, (2004) found congestion and hemorrhages in rat livers by a single oral dose of 145ppm alphacypermethrin 99%. Also, in mice, Luty et al, (2000) noticed subacute histopathological and ultrastructural changes in the liver tissue by alphacypermethrin. Cypermethrin insecticide also was induced subacute histopathological liver changes in rats treated with 150,300ppm such as vacuolar degeneration, enlargement of the sinusoids, degeneration in hepatic cords and hepatocytes, vacuole formation in hepatocytes, pleomorphism in nucleus and congestion (Yavasoglu et al, 2006).

In case of kidney tissues; the examination showed that the technical grade of alphacypermethrin produced hyperemia in some capillaries and bleeding in some parts of the tissue by the two used doses. Also some fibrosis was produced in some capillaries by the high dose only. The 10% EC formulation Super Alfa produced hyperemia and inflammation which were more obvious by the high dose than the low one (dose response relationship). Luty et al, (2000) reported that the subacute orally treatment of Swiss mice by alphacypermethrin produced a few infiltration of mononuclear cells between the proximal tubules and an increase in the number and size of autophagous vacuoles as well as a considerable accumulation of the electron dense bodies, in addition a clear widening of the golgi structures. Also subacute kidney congestion of the blood vessels in rats treated by deltamethrin was noticed by Manna et al, (2005).

The examination of the thyroid tissues showed atrophy in a large number of follicles by the high dose of the technical grade. In case of the 10% EC formulation Super Alfa some of the acini were showed with absence of the colloid in their lumens by the high dose, while no changes were noticed by the low dose.




Fig. 1- Liver from animal treated with the high dose of technical alphacypermethrin.



Fig. 3- Kidney from animal treated with the high dose of technical alphacypermethrin.




Fig. 2- Liver from animal treated with the low dose of technical alphacypermethrin.




Fig. 4- Kidney from animal treated with the low dose of technical alphacypermethrin.

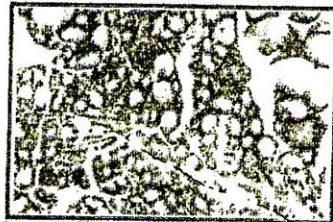


Fig. 5- Thyroid from animal treated with the high dose of technical alphacypermethrin.

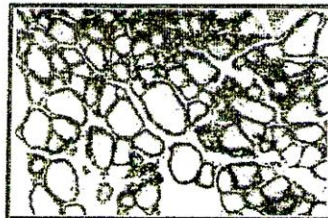


Fig. 6- Thyroid from animal treated with the low dose of technical alphacypermethrin.




Fig. 7- Liver from animal treated with the high dose of super alfa 10% EC.



Fig. 8- Liver from animal treated with the low dose of super alfa 10% EC.




Fig. 9- Kidney from animal treated with the high dose of super alfa 10% EC.




Fig. 10- Kidney from animal treated with the low dose of super alfa 10% EC.

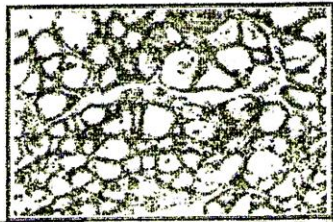


Fig. 11- Thyroid from animal treated with the high dose of super alfa 10% EC.

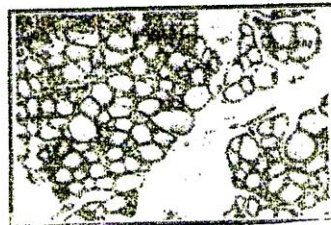


Fig. 12- Thyroid from animal treated with the low dose of super alfa 10% EC.

REFERENCES

1. Carleton H.M., R.A.B. Drury and E.A. Willington. 1967. Carleton's Histological Technique 4th Ed. Oxford Univ. Press, N.Y.
2. Gary S.K., S.K. Rastogi, V.K. Gupta and C. Varshneya. 1992. Toxicological profile of Fluvalinate-A synthetic pyrethroid. *Indian J. Pharm.* V.24, 154-157.
3. Grewal G., P.K. Verma, V.J. Dhar and A.K.Srivastava. 2009. Toxicity of subacute oral administration of cypermethrin in rats with special reference to histopathological changes. *International J. Green Pharm.* V.3 (4), 293-299.
4. Inayat Q., M. Ilahi and J. Khan. 2007. A morphometric and histological study of the kidney of mice after dermal application of cypermethrin. *J. pak. Med. Assoc.*, V.57, N.12, 587-591.
5. Luty S., J. Latuszynska, D. Obuchowska-Przebirowska, M. Tokarska and A. Haratym-Mai. 2000. Subacute toxicity of orally applied alpha-cypermethrin in Swiss mice. *Ann. Agric. Environ. Med.* V.7 (1), 33-41.
6. Luty S., J. Latuszynska, J.Halliop, A. Tochman and D. Obuchowska. 1998. Toxicity of dermally applied Alpha-cypermethrin in rats. *Ann. Agric. Environ. Med.* V.5, 109-115.
7. Manna S., D. Bhattacharyya, D.K. Basak and T.K. Mandal. 2004. Single oral dose toxicity study of α -cypermethrin in rats. *Indian J. Pharm.* V.36 (1), 25-28.
8. Manna S., D. Bhattacharyya, T.K. Mandal and S. Das. 2005. Repeated dose toxicity of deltamethrin in rats. *Indian J. Pharm.* V.37 (3), 160-164.
9. Souyri F. and H. Hoellinger. 1983. Neurotoxicity of pyrethrins in warm blooded animals. *Toxicol. Eur. Res.*, V.5, 103-112.
10. Yavasoglu A., F. Sayim, Y. Uyanikgil, M. Turgut and N.U. Karaloy-yavasoglu. 2006. The pyrethroid cypermethrin induced biochemical and histological alterations in rat liver. *J. Health Sci.*, V.52 (6), 774-780.

التأثيرات الموضعية النسيجية تحت الحادة لمبيد الفاسبيرمثرين الخام ومستحضر سوبر الفا ١٠% في ذكور الفئران البيضاء

ماجد منصور رزق الله ، مديحة محمد طلحة ، غريب عبد المبدى عبد الرحيم

قسم بحوث سمية المبيدات للثدييات والاحياء المائية- المعمل المركزى للمبيدات-مركز البحوث
الزراعية - الدقى - جيزة .

عوملت فى هذه الدراسة ٤ مجموعات من ذكور فئران التجارب البيضاء بتركيزين مختلفين من خام الفاسبيرمثرين ٩٦% (١٠،٥، ٢٥، ٥٠مجم/كجم وزن جسم وتمثل ١/١٠ او ٢٠/١٠ من قيمة الجرعة القاتلة النصفية المقدره) وتركيزين آخرين من المستحضر سوبر الفا ١٠% (٢، ٦، ١٠، ٢٠مجم/كجم وزن جسم وتمثل ١/١٠ او ٢٠/١٠ من قيمة الجرعة القاتلة النصفية المقدره) عن طريق التجريب الفمى ولمدة ٢٨ يوم متواصلة ثم أخذت عينات من الكبد والكلى والغدة الدرقية من كل المجموعات وفحصت هستوباثولوجيا. و أظهرت النتائج تأثيرات ضارة أكثر لخام الالفاسبيرمثرين على نسيج الكبد عن المستحضر حيث أحدث كلا التركيزين المستخدمين منهما نزيف دموى وتليف لبعض اجزاء النسيج الكبدى وتزايد فى انقسام بعض الخلايا. أيضا زادت تأثيرات الخام عن المستحضر على أنسجة الكلى وزاد كذلك التأثير بواسطة التركيز المرتفع عن المنخفض فى كلا الحالتين وتركز ضرر النسيج الكلوى فى أحتقان الشعيرات والاوعية الدموية ووجود نزيف دموى ويؤثر تليف . أحدث كذلك خام الالفاسبيرمثرين ضمور فى عدد كبير من الحويصلات المكونة لنسيج الغدة الدرقية بواسطة التركيز المرتفع وفى عدد اقل بواسطة التركيز المنخفض أما فى حالة المستحضر فقد أظهر الفحص خلوس بعض خلايا نسيج الغدة الدرقية من المادة الغروية فى حالة المعاملة بالتركيز العالى فقط .