

Experimental and clinical evaluation of a new intra-lingual suture pattern for management of lingual wounds in farm animals

Aiman M. Seddek¹, Mohammed H. Elrashidy¹, Sayed F. El-Hawari^{1*}

¹Department of Surgery, Anesthesiology, and Radiology, Faculty of Veterinary Medicine, Sohag University, 82524 Sohag, Egypt.

Abstract

A pre-clinical experimental study was used to evaluate a new intralingual suture pattern, for treating farm animal's tongue-wounds. Experimental section was performed on 36 fresh goat's tongue-samples, to compare the new suture pattern with the traditionally used two patterns (double rows simple interrupted pattern; and tension relieve vertical mattress with deep row simple interrupted pattern that is followed by superficial opposing vertical mattress). Comparison involved the required stitches number, duration of suturing, and pattern's tensile strength. The main clinical study was carried out on recent lingual wounds of variable depths which involved 30-50% of tongue width in one horse, one camel, one buffalo-calf, and three donkeys. In addition to three donkeys had old lacerations which failed to heal by first intension. Wounds sutured by the new pattern were covered by one row of cruciate mattress to oppose the mucosa. Results revealed that the new pattern required fewer stitches numbers, consume lesser time, had higher tensile strength, it could be easily applied, achieved proper apposition of both the muscular layer and mucosa, and it induced minimal scar formation and deformity. The technique is widely acceptable by the owners than the other traditional methods. The technique is advised to be used as an alternative suture pattern for the repair of lingual wounds in farm animals.

Keywords:

Equine, Healing, Suture pattern, Tongue, Wounds.

DOI: 10.21608/svu.2021.75493.1126

Received: May 9, 2021 Accepted: July 31, 2021 Published: September 4, 2021

*Corresponding Authors: Sayed F. El-Hawari E-mail: sayed_elhawari@vet.sohag.edu.eg

Citation: Seddek et al., Experimental and clinical evaluation of a new intra-lingual suture pattern for management of lingual wounds in farm animals. SVU-IJVS 2021, 4 (3): 38-50.

Copyright: © Seddek et al. This is an open access article distributed under the terms of the creative common attribution license, which permits unrestricted use, distribution and reproduction in any medium provided the original author and source are created.

Competing interest: The authors have declared that no competing interest exists.



Introduction

Tongue wounds are not uncommon; usually they involve the anterior free part of the tongue and more frequently transversely oriented across the dorsal surface and extend variable distances into the tongue's musculature (Adams and Becht, 1978; White and Hoffman, 1980; Mohammed et al., 1991; Barber, 2005; Barber and Stashak, 2008; Gerard, 2009; Dixon and Gerard, 2012; Lang et al., 2014; Mata et al., 2015; Jena et al., 2017).

The most predominant causes of lacerations include inappropriate use of bits, foreign bodies, accidental trauma, blows to head, iatrogenic during intra oral procedures, injury during recovery from anesthesia, or self-inflicted bites (Mohammed et al., 1991; Hague and Honnas, 1998; Barber, 2005; Pusterla et al., 2006; Fuller and Abutarbush, 2007; Barber and Stashak, 2008; Gerard, 2009; Farr et al., 2010; Dwivedi et al., 2013; Lang et al., 2014; Mata et al., 2015; Aher et al., 2018).

Fortunately, oral tissues have extraordinary rich blood supply, regenerative capacity and marked tendency for spontaneous healing (Howard and Stashak, 1993; Barber, 2005; Barber and Stashak, 2008), consequently many superficial wounds heal properly with minimal need for surgical intervention (Barber and Stashak, 2008; Carmalt, 2012). Moreover, equine tongue does not play a crucial role in the prehension like ruminants, as they count on lips more than tongue, and amputation back to the junction of the frenulum caused no functional abnormalities controversial to cattle, and this explains why tongue amputation after laceration caused greater morbidity in cattle than horses (Mohammed et al., 1991; Barber and Stashak, 2008; Ali et al., 2017; Ducharme et al., 2017; Jena et al., 2017; Sadan, 2017).

Veterinary surgeon should be aware that the management of lingual injuries requires proper understanding of the

unique needs of these wounds as well as quick-precise surgical interference. Although surgical techniques were enhanced over the last decades and despite the high regeneration capacity of the tongue, lingual wounds still represent a challenge as a result of the largely confusing anecdotal literatures (Das and Gadicherla, 2008) in addition to the difficulties experienced after suturing; as the sutures may be lost shortly after surgery due to chewing on the stitches (Lamell et al., 1999; Michelle et al., 2018); the wound may come apart due to lingual mobility; in addition to the contaminated wet oral environment that may break down sutures and predispose the wound to infection (Silver et al., 2016).

In both veterinary and human-surgery, management of lingual wounds is categorized into three main options; glossectomy depending on the severity, duration, and location of the injury; second intention healing; or tongue primary closure (Mohammed et al., 1991; Barber, 2005; Lang et al., 2014). Partial glossectomy, which can be used for complicated cases, but it has high potential risk of infection and inflammation, unacceptable by many owners, and when surgeons are obliged to use it in cattle, as much as possible of the tongue should be preserved (Ducharme et al., 2017). The second option is leaving the tongue to heal by second-intention by using daily mouth lavage and systemic antibiotics as well as by feeding a soft diet, especially when there is chronic less-extensive laceration and wound involves less than 30% of tongue thickness or economic constraints preclude surgical repair (Dixon and Gerard, 2012). Regrettably, this method predisposes to grooves formation at the tongue's surface, and scars may form in the lingual tissues leading to long-term problems as the tongue may not remain straight between the dental arcades and injured by the teeth (Barber and Stashak,

2008; Dixon and Gerard, 2012; Ducharme et al., 2017).

The available third option is primary wound closure for lacerations involving more than 30% of the tongue thickness, especially when unacceptability-constraint precludes the use of the other two options (Barber, 2005; Barber and Stashak, 2008; Dwivedi et al., 2013; Sadan, 2017; Aher et al., 2018). The primary wound closure aims at; preserving the normal lingual anatomical features; avoiding deformity of the tongue conformation; and minimizing scarring (Mohammed et al., 1991; Barber, 2005; Dixon and Gerard, 2012), and despite it should be attempted in the light of severity of the wound, its duration, and its location, many lacerations can be sutured regardless of the duration as a result of the lingual high regenerative ability and copious vasculature (Barber and Stashak, 2008).

For applying primary closure, few numbers of suture patterns and materials were used like single or double rows of simple interrupted pattern by absorbable mono or multi-filament suture materials (Patel et al., 2013; Sreenu et al., 2014; Valentine et al., 2014; Aher et al., 2018); single row of vertical mattress pattern by catgut or polyglactin suture materials (Dwivedi et al., 2013; Ali et al., 2017; Jena et al., 2017); or a popular multi-layers suture pattern by synthetic absorbable mono or multi-filament suture materials, applied in the form of deeply placed tension-relieving vertical mattress suture, a buried row of simple interrupted pattern, and finally a more superficial simple interrupted or vertical mattress pattern to oppose the mucosa (Adams and Becht, 1978; White and Hoffman, 1980; Howard and Stashak, 1993; Barber and Stashak, 2008; Gerard, 2009; Greet and Ramzan 2011; Carmalt, 2012; Dixon and Gerard 2012; Archer, 2013).

Regrettably, the available literatures are perplexing and add more confusion to the critical situation of lingual wounds that

exist in wet contaminated environment and can't be immobilized, in comparison to other wounds. Perplexing results are engendered because the researchers used paradoxical suture patterns and materials; on few numbers of clinical cases; and they relied on results gleaned from their own clinical experiences; and obviated to point out postoperative complications of these suture patterns (Barnett, 2016; Silver et al., 2016). Therefore, it is important to perform a study to evaluate the suitable suture pattern, rather than relying on results gleaned from clinical experiences without scientific reasoning and explanation. Accordingly, the current study was designed to evaluate experimentally and clinically, a new suture pattern for the management of lingual lacerations, compared to the commonly used other two patterns.

Materials and methods

The clinical study was approved and supervised by the IACUC (Institutional Animal Care and Use Committee) of Sohag University and Faculty of Veterinary Medicine ethics review committee, Egypt. The experimental study did not subject to review by the University IACUC board because no live subjects were studied.

1. *Experimental study:*

It was carried out on 36 samples of recently slaughtered goats. Tongues were subjected to full-thickness resection of half of its width (equal length in all samples), at the middle of the free lingual part. Samples were randomly divided into two groups (I and II). Each group was divided into three sub-groups; A, B and C (each of 6 samples), and one surgeon was asked to suture all groups; the first group was sutured by polyglactin 910 No. 4/0 in three manners; the first pattern (subgroup IA) is double rows of simple interrupted suture; the second pattern (subgroup IB) is tension relieve vertical mattress with deep row of

simple interrupted suture followed by superficial vertical mattress; and the third pattern (subgroup IC) is the new suture pattern. The number of required stitches and duration of the wounds suturing were recorded for the three sub-groups. While the second group was treated in the same manner with application of standardized pulling force to secure the knots (500 gms = 4.90 newton) then they were subjected to variable pulling forces for 5 seconds to evaluate the holding strength of the suture pattern. The mean weight in grams, that were required to induce at least 1 mm wound laceration at knots bites. This is modified method previously described by Silver et al. (2016) and the obtained results of both groups were statistically analyzed

1.1. Technique of the new suture pattern:

A straight 6-cm needle was introduced through the wound, close to the wound commissure, into the muscular layer, between the upper and middle third of the tongue thickness, and advanced caudally-obliquely-upwards, parallel to the longitudinal axis of the tongue, till it exited 2-3 cm caudal to the wound edge. Then it was re-inserted 2 mm caudally, perpendicular to the dorsal mucosa, till it exited from the ventral mucosa, then reinserted 2 mm rostrally, and advanced rostrally-obliquely- upwards, parallel to the long axis of the tongue, to exit in the muscular layer inside the wound, between the lower and middle third of the tongue thickness. The needle was inserted in the wound, between the lower and middle third of the tongue thickness, advanced cranially-obliquely-downwards, parallel to the long axis of the tongue till it exited from ventral mucosa 2-3 cm rostral to the wound, re-inserted 2 mm rostrally and perpendicularly on the ventral mucosa till it exited the dorsal mucosa, then re-inserted 2 mm caudally and advanced caudally-obliquely-downwards, parallel to the tongue to exit inside the wound, between the upper and middle third of tongue thickness through a point opposite

to the start point, then the knot was secured and buried in the depth of the wound. The remaining stitches were applied in the same manner lateral to the first one, leaving 1-cm distance between each two stitches according to animal size, and the last stitch was applied at the lateral border of the tongue. Following application of this suture pattern, one row of cross mattress pattern was applied to oppose the wound edges and to hide the buried knots of the new pattern, by polyglactin 910 No. 4-0. (Fig. 1).

2. Clinical study:

It was performed on 3 donkeys, 1 horse, 1 camel and 1 buffalo-calf had recent cutting or lacerated lingual wounds, rostral to the lingual frenulum, and involved 30-50% of the tongue width with depths varied from 30% to full thickness, while another 3 donkeys had old lingual lacerations that previously sutured and underwent dehiscence of stitches, on the way to heal by second intention, and either had excessive granulation or scarring and deformity.

Following animals examination, the recent cases were prepared for aseptic surgery; equines were narcotized by chloral hydrate 4-5 gm/ 50 kg b.wt. 10% solution intravenously; while ruminants were sedated by intra-muscular xylazine HCl 2%, 0.15 mg/ kg b.wt in buffalo calf and 0.25 mg/kg b.wt in camel. The animals were secured in with the lingual wound facing dorsally and gentle traction was applied to the base of the tongue, for better visualization of the wound and application of a plastic tourniquet, then a local block by 2% lidocaine HCl was performed at the base of the tongue. The wound was cleaned by vigorous lavage to remove clotted blood and food residues, swapped with diluted povidone iodine, and subjected to debridement of devitalized tissues. Then the new suture-pattern was applied to the wound, sagittally and parallel to the long axis of the tongue, started from the wound commissure

medially, in the form of 2-3 interrupted stitches according to the width of the wound, by using polyglactin 910 No. 0. The distance between stitches was about 1 cm. Finally, the tourniquet was removed.

The other three donkeys that had old wounds and tongue deformities were managed in the same manner after minimal resection and trimming of the scar tissue.

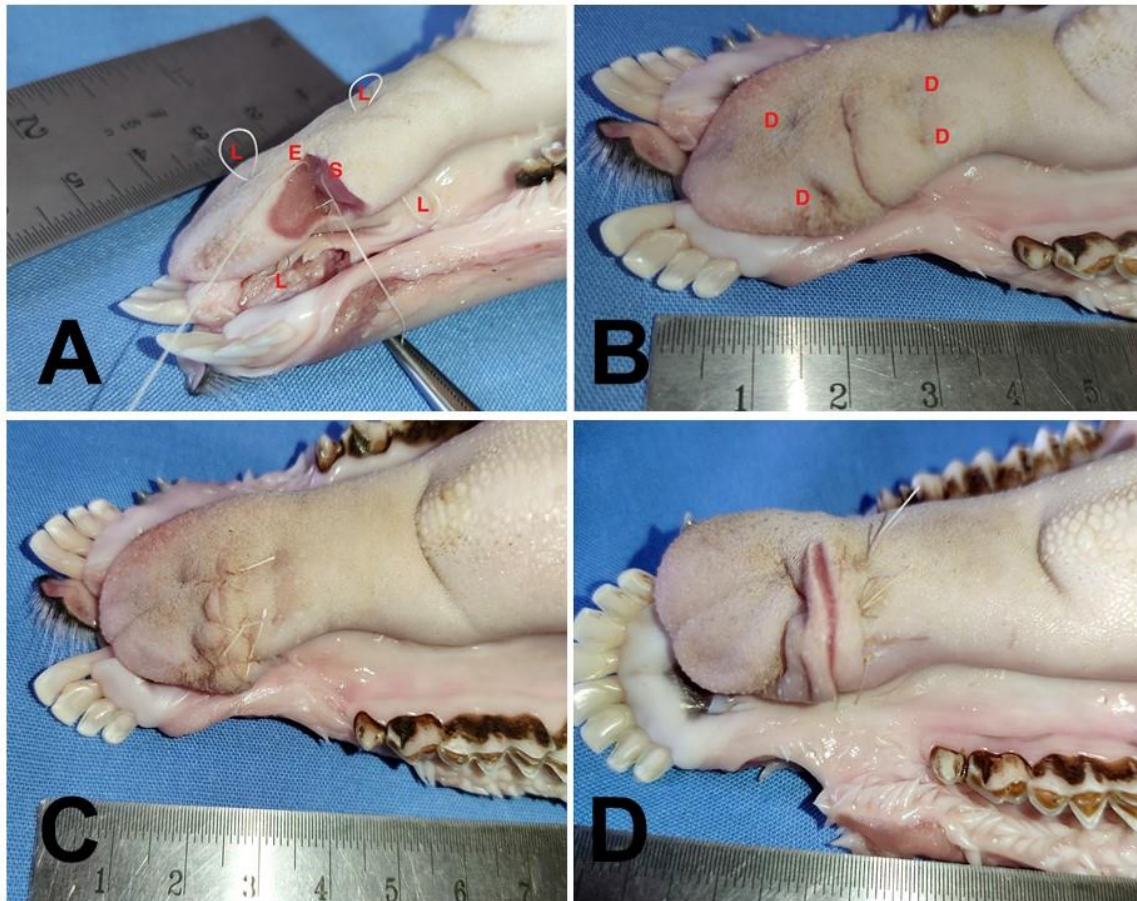


Fig.1. Representative image of the experimental suturing technique of lingual wounds in goats shows (A): Complete stitch of the new suturing pattern (stitch's pass of the suturing material in the tongue), S; Start point of the stitch inside the lingual wound, between upper and middle thirds of lingual thickness, E; End point, and L; loops formed when the needle exited the mucosa and re-inserted. **(B):** The tongue after application of two stitches of the new suturing pattern. D; Dimples formed at the points where the suture material form loops when the needle exited and re-inserted into the lingual mucosa. **(C):** The tongue after application of two buried new pattern stitches and application of two cross mattress stitches on the dorsal lingual surface and one cross mattress stitch at the lateral border of the tongue. **(D):** The old suture pattern of subgroup (I B); 5 tension relieve vertical mattress, with deep row of 5 simple interrupted pattern followed by 5 superficial vertical mattress patterns.

2.1. Post-operative follow-up:

Post-surgical aftercare included injection with anti-tetanic sera (for equines), daily antibiotic, multi-vitamins, and the owners were advised to feed the animals with soft foods like wetted bran mashes and green food during the first few days, and to flush the oral cavity by diluted povidone iodine after meals, also they were asked to observe the animals for comfortable prehension, inflammatory signs, mastication and any pathological changes in the tongue. All cases were followed up each 15 days for 6 months postoperatively. During the follow up period we care about animal self-traumatization for the tongue, stitch dehiscence and the opposition of the muscles and mucosa. However, owners were asked about the animal's appetite, food prehension, and mastication.

3. Statistical analysis:

Statistical analysis was carried out using the Statistical Package for the Social Sciences software program (Stata ® 16). Differences between the mean values of groups were evaluated by using analysis of

variance test (one-way ANOVA) with application of Tukey HSD as a post hoc test. All data in the present study were expressed as mean \pm standard deviation and P value \leq 0.05 was considered significance.

Results

Regarding to experimental study, the number of required stitches were greater in other patterns than the new one. The mean time required to close the wound was significantly lesser in the new pattern than second sub-group ($p= 0.0001$) and was nearly the same as first sub-group as well ($p= 0.2199$) (Table 1). Furthermore, the mean force in newton, that were required to induce at least 1 mm wound dehiscence or laceration at knots bites, was significantly greater in the third sub-group than the 1st sub group ($p= 0.0006$) and the 2nd subgroup ($p= 0.0226$) (Table 1). However, the mean weight in grams, that were required to induce at least 1 mm wound laceration at knots bites, was significantly greater in the third sub-group than the 1st ($p= 0.0008$) and 2nd ($p= 0.013$) subgroups.

Table 1: The required suturing time and number of stitches for the lingual defect in subgroups of group (I) and the required tension force in newton and grams to induce \geq 1 mm laceration at stitches bites or separation of wound lips, in subgroups of group (II)

Group I	¹ Sub-group IA	² Sub-group IB	³ Sub-group IC
Duration of suturing in seconds (Mean \pm SD)	456 \pm 11.79 ^b	857 \pm 4.58 ^a	468.33 \pm 5.51 ^b
Required stitches No.	10	15	7
Group II	¹ Sub-group IIA	² Sub-group IIB	³ Sub-group IIC
Tension force in Newton (Mean \pm SD)	4.90 \pm 0.49 ^b	6.86 \pm 0.49 ^a	8.66 \pm 0.74 ^c
Tension force in grams (Mean \pm SD)	500 \pm 50 ^b	683.33 \pm 57.74 ^a	883.33 \pm 76.38 ^c

Different letters in the same row indicates significant differences between groups ($p \leq 0.05$). (1): Sub-group A was treated by double rows of simple interrupted pattern (one deep layer covered by on superficial layer), (2): Sub-group B was treated by tension relieve vertical mattress, deep row of simple interrupted pattern followed by superficial vertical mattress pattern, (3): Sub-group C was treated by the new intra-lingual pattern. SD means standard deviation.

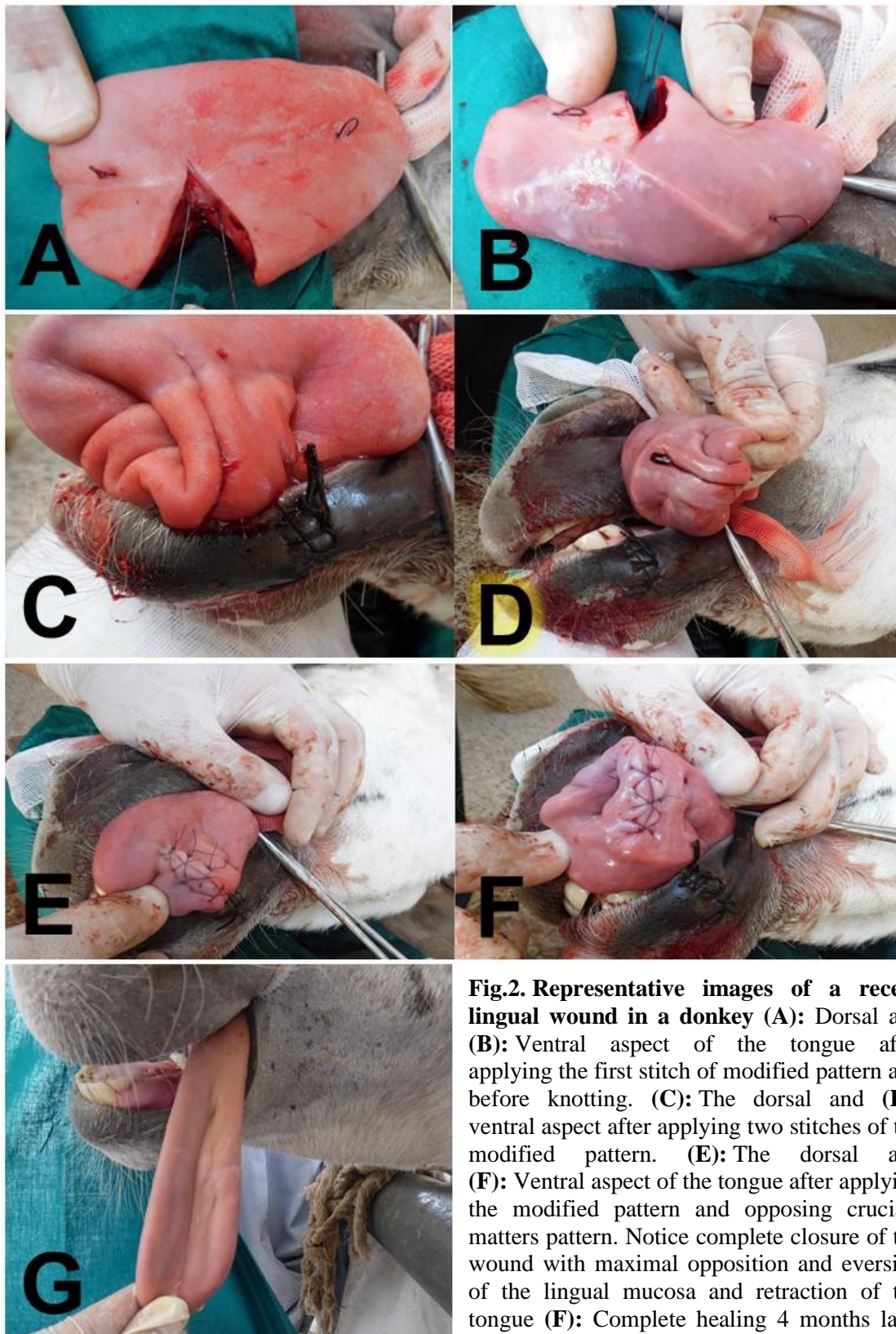


Fig.2. Representative images of a recent lingual wound in a donkey (A): Dorsal and (B): Ventral aspect of the tongue after applying the first stitch of modified pattern and before knotting. (C): The dorsal and (D): ventral aspect after applying two stitches of the modified pattern. (E): The dorsal and (F): Ventral aspect of the tongue after applying the modified pattern and opposing cruciate matters pattern. Notice complete closure of the wound with maximal opposition and eversion of the lingual mucosa and retraction of the tongue (F): Complete healing 4 months later after suturing.

Regarding to clinical study, the technique could be easily applied, the required stiches were fewer than the traditional technique, the knots were buried and protected inside the wound and covered by one row of cross mattress pattern, with lower possibility of untying or dehiscence. During postoperative follow up; the tongue contracted at the sutured half of the tongue with lower possibility of self-traumatization by teeth, and a very little number of suture materials exposed to the oral environment. The new pattern ensured complete obliteration of the dead space with maximal opposition of the muscles and mucosa and induced slight inverting of the mucosa on both sides of the wound (Fig. 2). Mild swelling and redness were noticed in all clinical cases for 3-5 days postoperatively. The main complaint of owners was reduction of appetite and difficulty in prehension and mastication during the first week post-surgery, but all animals returned to normal eating by the second week.

One-month post-suturing, all treated animals showed complete healing of the wounds with minimal scarring and distortion of the tongue, and all of them had normal lingual mobility and sensation when tested by needle pinching. Neither suture material could be observed in the suture line, nor dehiscence of the wound stitches occurred, and the cosmetic appearance of the tongue was better in recent cases than in old ones (Fig.2.G). Although the owners of the old cases were satisfied by the results in comparison with the pre-surgical status of the animals (Fig.3.A&E).

Discussion

Experimentally, the new technique proved to be advantageous to the other popular methods of suturing the tongue as it required fewer numbers of stitches, consumed shorter time, and used lesser

number of suture materials and knots in the wound, accordingly it avoided entrapping of foreign bodies in the wound which may cause infection, and delay healing (Silver et al., 2016). The new suture pattern is covered by a layer of one row of cross mattress pattern and the stitch knots were hidden inside the surgical wound. However, in other two suture pattern the surgical knots were outside the surgical wound which may be irritating and cause slight laceration to adjacent structures (DeRowe and Woodson, 2000).

From clinical point of view, deep lingual lacerations are complex-issues and require more intensive care than that applied for minor superficial wounds which can be left to heal by second intention because of the high lingual vascularity and high regenerative ability (Barber and Stashak, 2008). Their management is guided by location, duration, and depth of the wound; their suturing is encouraged by the deep location of lingual artery and the high regenerative ability; and their suturing mainly aims at preservation of the normal lingual architecture (Dixon and Gerard 2012).

Unfortunately, there is a scarcity of the veterinary literatures discussing the suitable suture patterns on scientific base; the knot security and its relation to the suture pattern and suture materials; or the ideal protocols for management of these lacerations, furthermore the management principles, even in human-surgery, are based on clinical experiences with little scientific reasoning (Barnett, 2016; Silver et al., 2016).

The used simple interrupted suture pattern in some studies (Patel et al., 2013; Sreenu et al., 2014; Valentine et al., 2014; Sadan, 2017; Aher et al., 2018) has single bite on both sides of the wound controversial to vertical mattress pattern which has double bites, consequently the later has better holding strength (Hickman et al., 1995) and this may explain its popularity among researchers (Howard and

Stashak, 1993; Barber and Stashak, 2008; Greet and Ramzan 2011; Dixon and Gerard 2012; Carmalt, 2012; Dwivedi et al., 2013; Ali et al., 2017; Jena et al., 2017). Along the same lines, the new suture pattern has 2 double bites on both sides of the wound, with long distance between them and consequently a higher holding ability that was proved experimentally and manifested clinically by satisfactory healing without dehiscence or complications.

The use of traditional suture patterns for that playable organ, the wet contaminated oral environment, and securing the knots (which is the weakest link in a surgical seal) on the surface of the tongue (Tera and Aberg, 1977), predispose the knots to be soaked continuously in saliva and expose them to frequent friction against the palate and the food with subsequent higher incidence of untying or dehiscence (Lamell et al., 1999; Silver et al., 2016) that finally may lead to healing by second intention with excessive scarring and lingual deformity (Valentine et al., 2014). Unfortunately, few researchers recorded the incidence of dehiscence after using these suture patterns (Dixon and Gerard, 2012; Valentine et al., 2014), and the animal samples in most studies were very small to rely on the results obtained from these studies.

The new suture pattern has many advantages over the traditionally used ones as it buries the thread and the knots intra-lingual; and the second row of cross mattress pattern opposes the mucosa and hides the buried knots and prevents it from coming in contact with saliva, accordingly the complications mentioned in some literatures (Gerard, 2009; Dixon and Gerard, 2012; Valentine et al., 2014) didn't observed in the current study. At the same time, the current technique is advantageous over the suture patterns frequently used by many researches (Greet and Ramzan 2011; Dixon and Gerard, 2012; Jena et al., 2017; Ali et al., 2017; Aher et al., 2018) as the

number of the required stitches is fewer, subsequently it avoids using of excessive number of suture materials and knots than the required in the wound which offer no mechanical advantage and represents more foreign bodies in the wound that may damage host defenses and resistance to infection, and delay healing (Silver et al., 2016). Moreover, it has better obliteration ability of the dead space, opposes both of the muscular layer and the mucosa, and oriented in the same direction of the blood supply like the traditionally used patterns, consequently it minimally interferes with the healing, the same as vertical mattress (Céleste and Stashak, 2008), but it is advantageous over the later as it causes no eversion of the mucosa. One more point that should be noted that this pattern induces retraction of the tongue at the wounded half, which may lose nerve supply and has paralysis as a result of deep injury involving full thickness. Such wound retraction prevents self-traumatization of the retracted tongue by teeth.

Conclusion

frequent complications; the better opposing of lingual muscles and mucosa and subsequent noted preservation of normal lingual anatomical features with minimal deformity of the tongue conformation, make this pattern advantageous over the other traditionally used patterns, and it is advised to be used for repair of lingual lacerations on the scientific base. Further investigation using histopathological evaluation is required to assess the quality of healing pattern.

The recorded shorter time of application of this suture pattern; the fewer number of required stitches; the proved stronger holding ability and the higher tension-relieving capability with higher ability of dead space obliteration; the lesser number of suture materials and knots in the wound; the retraction of the paralyzed sutured side of the tongue that minimized self-traumatization by teeth; the less

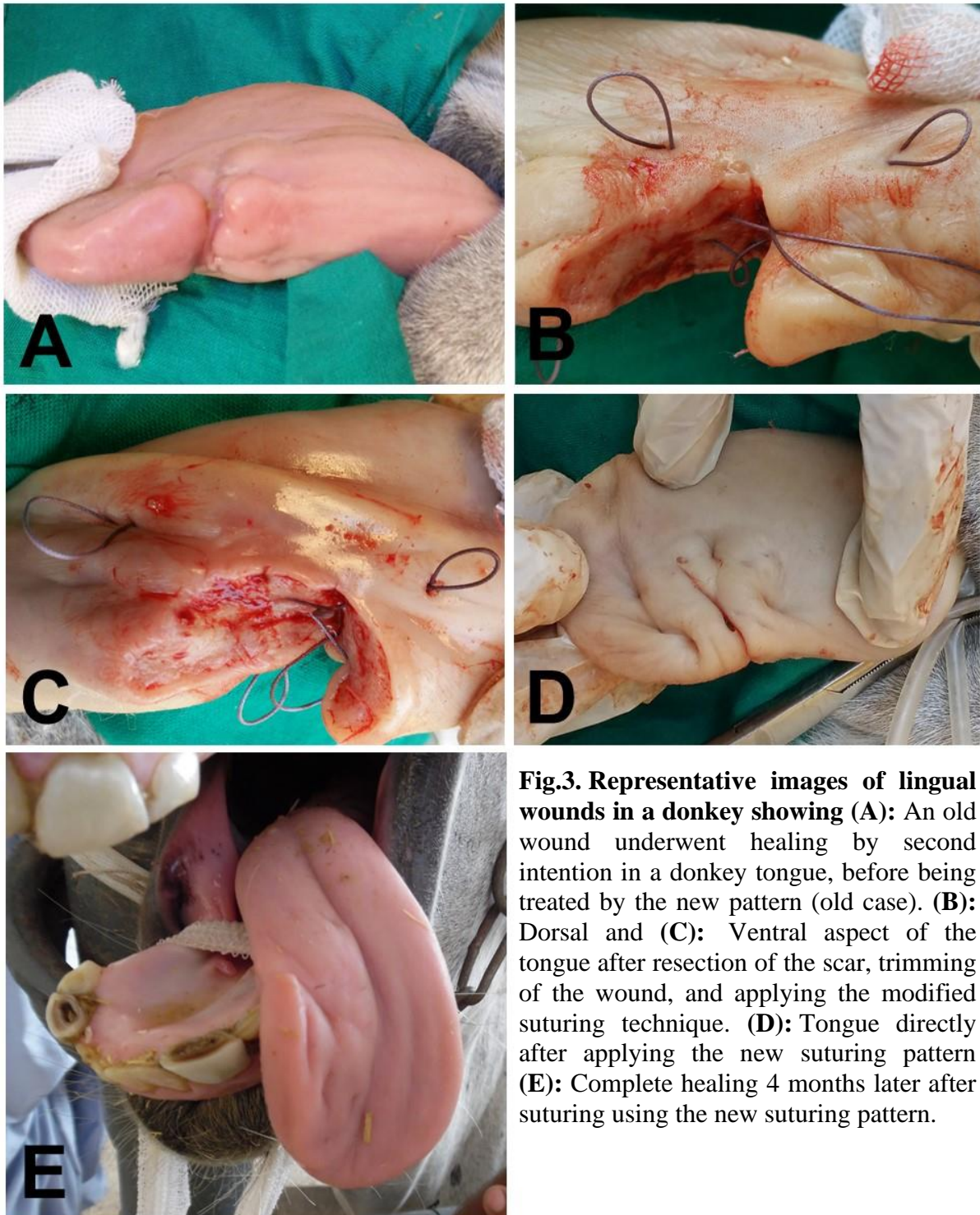


Fig.3. Representative images of lingual wounds in a donkey showing (A): An old wound underwent healing by second intention in a donkey tongue, before being treated by the new pattern (old case). **(B):** Dorsal and **(C):** Ventral aspect of the tongue after resection of the scar, trimming of the wound, and applying the modified suturing technique. **(D):** Tongue directly after applying the new suturing pattern **(E):** Complete healing 4 months later after suturing using the new suturing pattern.

Conflict of interests

All authors declare that there is no conflict of interests.

Financial disclosures

This work was not supported by any financial support.

References

- Adams SB, Becht JL (1978). Surgical repair of a severe laceration in a horse's tongue. *Veterinary Medicine Small Animal Clinic*, 73(11): 1394-1395.
- Aher VD, Dhage GP, Balage PR, Lokhande, DS (2018). Surgical management of deep lacerated tongue in a red kandhari cow calf. *International Journal of Veterinary Sciences and Animal Husbandry*, 3(2): 14-15.
- Ali S, Hamza A, Aslam A, Hussain R, Maan MK, Khosa AN, Bangulzai N, Umer M (2017). Surgical Correction of Lacerated Tongue in Cattle (Case Study). *Lasbela, U. Journal of Science Technology*, 6: 47-48.
- Archer DC (2013). Oral and gastrointestinal emergencies. Chapter 4 In: *Handbook of equine emergency*. Elsevier, Saunders, St Louis, pp 59-84.
- Barber S and Stashak TS (2008). Management of Wounds of the Head. Chapter 6 In Stashak, T.S., Theoret, C. (eds): *Equine wound management*. 2nd edn. Wiley-Blackwell, Ames, IA, pp 273-332.
- Barber SM (2005). Management of neck and head injuries. *Veterinary Clinical Equine*, 21: 191-215.
- Barnett TP (2016). What is the best way to deal with trauma of the oral cavity? *Equine Veterinary Education*, 28(4): 232-233.
- Carmalt JL (2012). Oral soft tissue trauma: Tongue and oral mucosa In Wilson, D.A., et al., (eds): *Clinical veterinary advisor: The horse*. Elsevier, Saunders, St. Louis, Missouri, pp. 411-412.
- Céleste C and Stashak TS (2008). Selection of Suture Materials, Suture Patterns, and Drains for Wound Closure. Chapter 4.2. In Stashak, T.S., Theoret, C. (eds): *Equine wound management*. 2nd edn. Wiley-Blackwell, Ames, IA, pp. 193-224.
- Das UM and Gadicherla P (2008). Lacerated Tongue Injury in Children. *International journal of clinical Pediatric dentistry*, 1(1): 39-41.
- DeRowe A and Woodson TB (2000). A minimally invasive technique for tongue-based stabilization in obstructive sleep apnea. *Operative Techniques in Otolaryngology-Head and Neck Surgery*, 11(1): 41-46.
- Dixon PM, Gerard MP (2012). Oral cavity and salivary glands. Chapter 30 In Auer, J.A., Stick, J.A. (eds): *Equine Surgery*. 4th edn. Elsevier-Saunders, St. Louis, pp 339-366.
- Ducharme NG, Desrochers A, Fubini SL, Pease AP, Mizer LA, Walker W, Trent AM, Roy J, Rousseau M, Radcliffe RM, Steiner A (2017). Surgery of the Bovine Digestive System. Chapter 14 In Ducharme, N.G., Fubini, S.L., (eds): *Farm Animal Surgery*. 2nd edn. Elsevier, St. Louis, Missouri, pp. 223-343.
- Dwivedi DK, Gupta AK, Kushwaha RB, Gupta P, Sharma A (2013). Surgical repair of traumatic laceration of tongue in a pony. *Indian Journal of Veterinary Surgery*, 34(2): 148.

- Farr AC, Hawkins JF, Baird DK, Moore GE (2010). Wooden, metallic, hair, bone, and plant foreign bodies in horses: 37 cases (1990-2005). *Journal of the American Veterinary Medical Association*, 237(10): 1173-1179.
- Fuller MC and Abutarbush SM (2007). Glossitis and tongue trauma subsequent to administration of an oral medication, using an udder infusion cannula, in a horse. *Canadian Veterinary Journal*, 48: 845-847.
- Gerard MP (2009). Management of tongue injuries. Chapter 76 In Robinson, N.E., Spryberry, K.A. (eds): *Current therapy in equine medicine*. 6th edn. Saunders, an imprint of Elsevier Inc, pp. 345-347.
- Greet TR, Ramzan PH (2011). Head and dental trauma. Chapter 9 In Easley, J.A., Dixon, P.M., Schumacher, J. (eds): *Equine Dentistry*. 3rd edn. Saunders, Elsevier, Edinburgh, pp. 115-127.
- Hague BA, Honnas CM (1998). Traumatic dental disease and soft tissue injuries of the oral cavity. *Veterinary Clinical North American Equine Practice*, 14 (2): 333-347.
- Hickman J, Houlton JE, Edwards B (1995). General surgical principles. Section 1. In: *An atlas of veterinary surgery*. Blackwell Science, pp. 1-26.
- Howard RD, Stashak TS (1993). Reconstructive surgery of selected injuries of the head. *Veterinary Clinical North American Equine Practice*, 9(1): 185-198.
- Jena B, Sahoo S, Mahalik S, Padhan A, Nath S (2017). Surgical repair of traumatic laceration of tongue in a cow. *Journal of Livestock Sciences*, 8: 131-133.
- Lamell CW, Fraone G, Casamassimo PS, Wilson S (1999). Presenting characteristics and treatment outcomes for tongue lacerations in children. *Pediatric Dent.*, 21(1): 34-38.
- Lang HM, Panizzi L, Smyth TT, Plaxton AE, Lohmann KL, Barber SM (2014). Management and long-term outcome of partial glossectomy in 2 horses. *Canadian Veterinary Journal*, 55: 263-267.
- Mata F, Johnson C, Bishop C (2015). A cross-sectional epidemiological study of prevalence and severity of bit-induced oral trauma in polo ponies and racehorses. *Journal of Applied Animal Welfare and Science*, 18 (3): 259-268.
- Michelle S, Letiziaa MS, Georga S, Clemens S (2018). Tongue lacerations in children: to suture or not. *Schweizerische medizinische Wochenschrift (Swiss Medical Weekly)* 148(43): 1-5.
- Mohammed A, Ribadu AY, Hassan SU (1991). Partial glossectomy in a stallion. *Veterinary Record*, 28(15): 355-356.
- Patel JB, Patel PB, Avasthi HA (2013). Surgical Management of Tongue trauma in Mare. *Intas Polivet*, 14(I): 167-168.
- Pusterla N, Latson KM, Wilson WD, Whitcomb MB (2006). Metallic foreign bodies in the tongues of 16 horses. *Veterinary Record*, 159(15): 485-488.
- Sadan MA (2017). Surgical Treatment of Some Tongue Affections in Camels (*Camelus Dromedarius*). *Journal of Agricultural and Veterinary Sciences*, 10: 19-25.
- Silver E, Wu R, Grady J, Song L (2016). Knot security - how is it affected by suture technique, material, size, and number of throws? *Journal of Oral Maxillofacial Surgery*, 74(7): 1304-1312.

Sreenu M, Sravanthi P, Goud KS (2014). Management of tongue laceration in a buffalo. *Indo-American Journal of Agriculture and Veterinary Sciences*, 2(3): 74-76.

Tera H, Aberg C (1977). Strength of knots in surgery in relation to type of knot, type of suture material and dimension of suture thread. *Acta Chirurgica Scandinavica*, 143(2): 75-83.

Valentine BA, Bildfell RJ, Dunn AJ (2014). Distinctive tumour of the tongue in 3 horses. *Equine Veterinary Education*, 26(6): 328-330.

White NA, Hoffman PE (1980). Surgical repair of equine lingual lacerations. *Equine Practice*, 2(2): 37-42.