

بعض المشاهدات التشريحية على طبوغرافية وتوزيع الأوعية والعقد اللمفية الموجودة على معدة الجاموس في مصر

د . عبد المنعم صالح و د . ابراهيم صائح ابراهيم

الملخص

أجرى هذا البحث على عشرة معدات للجاموس وعدد مماثل لمعدات العجول الصغيرة ، يتراوح سنها بين (٤٠ - ٦٠ يوما) وعشرة أجنة كاملة النمو .

لقد درست أشكال وأعداد والتوزيع الطبوغرافي في العقد اللمفية وكذلك الأوعية الداخلة والخارجة منها ونوقشت النتائج مع ما قد تم الحصول عليه من مراجع .

لقد وجد أن العقد اللمفية للمعدة هي :

١ - العقد البهوية للكرش : التي خلالها تتجمع الأوعية اللمفية الداخلة من البهو الكرشى وبية أوعية عقد المعدة ، بينما تخرج منها أوعية تتجمع مع بعض مكونة الوعاء المعدي العام .

٢ - العقد اليمينية واليسارية والقحافية للكرش التي توجد في الميزاب اليميني واليسارى والقحافى وخلالها تتجمع الأوعية اللمفية من المناطق المجاورة وتدخل هذه العقد ، بينما الأوعية اللمفية الخارجة منها تدخل العقد البهوية للكرش .

٣ - العقد الشبكية وتنقسم الى جزءين :

أ - عقد توجد على الجزء العلوى من الشبكية .

ب - عقد توجد على الجزء السفلى المتصق بالانفحة (العقد الشبكية الانفحيه) .

٤ - العقد الورقية : التي خلالها تتجمع الأوعية اللمفية من الورقية ، بينما الأوعية اللمفية الخارجة تذهب الى العقد البهوية للكرش .

٥ - العقد الظهرية والبطنية للانفحة : التي خلالها تتجمع الأوعية اللمفية الداخلة من المناطق المجاورة من الانفحة بينما الأوعية اللمفية الخارجة تذهب الى العقد الورقية .

Head of Department : Prof. Dr. A.N. George

SOME ANATOMICAL OBSERVATIONS ON THE TOPOGRAPHY AND MACROSCOPIC DISTRIBUTION OF THE LYMPH VESSELS AND NODES OF THE STOMACH OF BUFFALO IN EGYPT (*Bos, bubalis*, L.)

(with 1 figure)

by

A.M. Saleh and I.S. Ibrahim

(Received at 16/11/1974)

SUMMARY

Ten stomach of adult buffaloes, similar number of calves stomach ranging from 40—60 days old and 10 full term buffalo foetuses were used for studying the gastric lymph nodes and their vessels.

The shape, number and position of the following gastric lymph nodes with their lymph vessels were described :

1. Atrial
2. Right, left and cranial ruminal
3. Reticular
4. Omasal
5. Reticulo-abomasal
6. Dorsal and ventral abomasal

INTRODUCTION

Several authors as BAUM (1912), OSTERTAG (1934), GLAGOLEF and EPOLITOVA (1962), HABEL (1964 & 1965), RAGHAVAN (1964), AKAIIVSKY (1968), SISSON & GROSSMAN (1968), and KOCH & BERG (1970), studied the anatomy of the gastric lymph nodes and their vessels. Most of these workers found that the gastric lymph nodes in ox were right, left and cranial ruminal ; reticular, omasal, reticulo-omasal, reticulo-abomasal ; dorsal and ventral abomasal ; atrial and rumino-abomasal lymph nodes. KOCH & BERG neglected the presence of the rumino-abomasal lymph nodes. THORNTON (1970) stated that the gastric lymph nodes of the ox are numerous and difficult to group satisfactorily. They form a chain along the right and left longitudinal grooves of the rumen..

TAHER (1962) gave a detailed description of the gastric lymph nodes in the camel and grouped them as dorsal and right ruminal, and dorsal and ventral omaso-abomasal lymph nodes. MOFSECIAN & MANFELIAN (1950) gave some morphological features of the anatomy of lymph nodes of buffalo and ox. EL-GENDI (1971) described the shape and position of the gastric lymph nodes in buffalo. He considered that the gastric lymph nodes belong to the coeliac lymph center. They are large in number, scattered along the main blood vessels over the different compartments of the stomach.

The present investigation aims to add some anatomical features to what have been recorded on this animal.

MATERIAL AND METHODS

Inspection of the lymph nodes, their number and distribution on the stomach of buffalo have been carried on ten adult normal stomach brought from Cairo slaughter house. The lymph vessels have been studied on the same number of calves ranging between 40-60 days and 10 suck calves. They have been thoroughly cleaned and fixed in 10% neutral formalin and 4% phenol and 2% glycerine. The technique of TAHER (1965) was used to follow the lymph vessels. An injection of serum colored with indian ink have been carried in fresh specimens under the serous membrane after warming to 37°C. in normal saline.

RESULTS AND DISCUSSION

The terminology used in this work is that of Nomina Anatomica Veterinaria (1968). The lymph vessels of the stomach of buffalo as well as the lymph nodes are subject to wide variation in their number, distribution and location. The lymph nodes are considerably large in size and number. Their general form is bean-shaped or oval, greyish in colour, with smooth surfaces and firm consistency. They are grouped along the course of the blood vessels, embedded in fat and covered by the visceral layer of the peritoneum. Similar findings obtained by MOFSECIAN & MANFELIAN (1950). The gastric lymph nodes are grouped in the following manner (Fig. 1),

The atrial lymph nodes (Lnn. atriales) (Fig. 1/1) : Are 4 in number mainly found on the right surface of the Atrium ventriculi, caudal to the cardia. They measure 2.5-3 Cm. long, 2.5 Cm. wide and 0.3-4cm. thick. The afferent vessels come from the atrium ventriculi; the neighboring part

of the rumen and reticulum and from the spleen. The efferent vessels of the right ruminal, cranial ruminal, accessory right ruminal, reticular, omasal lymph nodes join the atrial lymph nodes. The efferent vessels of the latter nodes unite to form the gastric trunk (truncus gastricus). The latter may join the lymphocentrum celiacum or cisterna chyli. Similar observations were obtained in the ox by AKAIIVSKY (1968), SISSON and GROSSMAN (1968) and KOCH & BERG (1970).

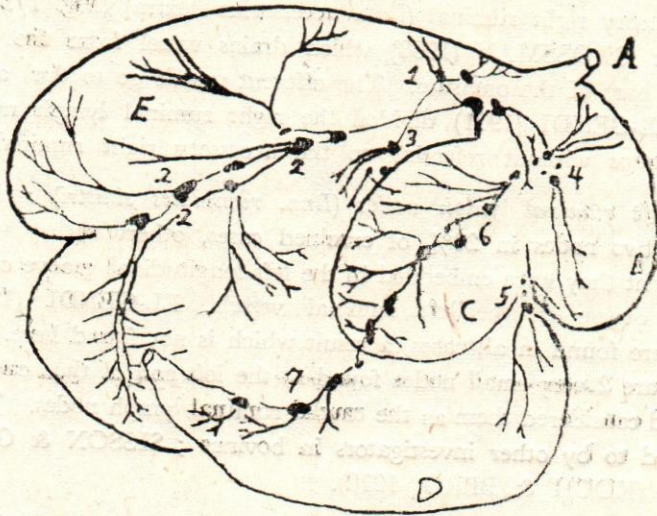


Fig. 1. Right surface of stomach of buffalo showing the arrangement of lymph nodes and lymph vessels.

A.—Oesophagus B.—Reticulum C.—Omasum D.—Abomasum
E.—Rumen

1. Lnn. atriales.
2. Lnn. ruminales dextri
3. Lnn. ruminales dextri accessorii
4. Lnn. reticulares.
5. Lnn. reticuloabomasiales
6. Lnn. omasiales
7. Lnn. abomasiales dorsales.

The right ruminal lymph nodes (Lnn. ruminales dextri) (Fig. 1/2) : These are 4-6 in number, measuring from 2-3.5 Cm in length, 1 Cm. in width; and 0.4 Cm. in thickness. They are embedded in fat along the course of the right ruminal vessels as they pass in the right longitudinal ruminal groove. The afferent vessels come mainly from the upper and lower parts of the right ruminal surface. The efferent vessels of the cranial part of the group go to the atrial lymph nodes, sometimes to the common gastric trunk. In 50% of the examined cases, there were 2-3 small lymph nodes near the adjacent part of the rumen facing to the omasum. This group of lymph nodes known as the accessory right ruminal (Lnn. accessorius dextra) (Fig. 1/3), given by SISSON & GROSSMAN (1968) which drains vessel from the rumen and the nearest part of the omasum. The efferent vessels go to the atrial lymph nodes. EL-GENDI (1971) divided the right ruminal lymph nodes into 3 isolated groups without referring to the accessory right ruminal.

The left ruminal lymph nodes (Lnn. ruminales sinistri) : Represented by one or two nodes in 20% of examined cases, otherwise they were absent. When present they were embedded in the left longitudinal groove of the rumen along the course of the left ruminal vessels. EL-GENDI (1971) stated that they are found in all cases, a result which is not found here. He added that there are 2 very small nodes found at the left end of the caudal ruminal groove and considered them as the caudal ruminal lymph nodes. The latter is not referred to by other investigators in bovines ; SISSON & GROSSMAN 1968, and (KOCH & BERG, 1970).

The cranial ruminal lymph nodes (Lnn. ruminales craniales) : Are embedded deeply in the cranial ruminal groove. Their average number ranges from 3-6; their length 2 Cm. The afferent vessels come from the adjacent part of the rumen, and from the left ruminal lymph nodes (if they are present). The efferent lymph vessels go to the right ruminal and atrial lymph nodes.

The reticular lymph nodes (Lnn. reticulares) (Fig. 1/4) : These were grouped along the reticulum in two sets, an upper group 3-5 in number was found on the upper part of the reticulum and a lower one 2-4 in number known as the reticulo-abomasal (Lnn. reticuloabomasiales Fig. 1/5) located in the reticuloabomasal groove. Each measures about 2 cm. in length, 2 cm. in width and 1 cm. in thickness. The afferent vessels mainly come from the reticulum, and adjacent part of the omasum, and the fundic part of the abomasum. The efferent vessels go mainly to the atrial lymph nodes. The present findings agree with that of EL-GENDI (1971) concerning the arrangement of the reticular lymph nodes. In addition he have not referred to the retitulo-abomasal lymph nodes.

The omasal lymph nodes (Lnn. omasiales) (Fig. 1/6) : Their number vary from 6-12, each measures about 3 cm. in length, 0.5 cm. in width and 0.5 cm. in thickness. They were located along the course of the dorsal omaso-abomasal vessels on the omasum. Their afferents come from both surfaces of the omasum and the efferents passed mainly to the atrial lymph nodes. TAHER (1962) did not refer to the omasal lymph nodes in the camel. AKAIVSKY (1968), SISSON & GROSSMAN (1968), and KOCH & BERG (1970) given similar results in the ox.

The dorsal abomasal lymph nodes (Lnn. abomasiales dorsales) (Fig. 1/7) : They were represented by 3-5 nodes, located along the course of the dorsal omaso-abomasal vessels at the lesser curvature of the abomasum. The measurements were in succession, 2-3 cm., 1-2 cm. and one cm. for the length, width and thickness. The afferent vessels come from the lesser curvature and both sides of the abomasum, the initial part of the duodenum, and the ventral part of the omasum. The efferent vessels pass mainly in the lesser omentum to the hepatic lymph nodes but some from the cranial part of the series go to the omasal and reticular lymph nodes. The number given by EL-GENDI (1971) was 10-15 nodes of globular or ovoid outline measuring 0.5-2 cm. in diameter.

The ventral abomasal lymph nodes (Lnn. abomasiales ventrales) : In 25% of the cases examined they were represented by one or two nodes otherwise, they were absent. When present they measure 2.5-3 cm. in length, 1.5 cm. width and 0.5 cm. thickness embedded in the omental fat at the greater curvature of the pyloric part of the abomasum. In well nourished animals these nodes are difficult to demonstrate, being masked by omental fat. The afferent vessels come from the abomasum and the duodenum and the efferent vessels ended in the hepatic lymph nodes. EL-GENDI (1971) stated that the ventral abomasal lymph nodes are 12-13 in number showing

the same shapes and dimensions to the dorsal abomasal lymph nodes. TAHER (1962) in the camel stated similar group. The same observations were obtained by AKAIVSKY (1968), SISSON & GROSSMAN (1968) and KOCH & BERG (1970) in the ox.

REFERENCES

- Akaivsky, A.I.** (1968). Anatomy of the domestic animals, 2nd. Ed. Kolus, Moscow. P. 443-445.
- Baum, H.** (1912). Das Lymphgefäc system des Rindes, Berlin, 11-53.
- El-Genoi, E.M.M.** (1971). Studies on the lymph nodes of the buffalo in Egypt. Thesis, Faculty of Vet. Med. Cairo University.
- Glagolev, V.A. and Epolitova, E.** (1962). Anatomy of farm animals with principals of histology and embryology. 2nd Ed. Agriculture Publishing House, Moscow. P. 384-386.
- Habel, R.E.** (1964). Guide to the dissection of domestic animals. Ann. Arbor. Edwards.
- Habel, R.E.** (1965). Anatomical and Histological Nomenclature of the ruminant stomach "in physiology of digestion in the ruminant". R.W. Doughery, ed., Butter Worth, London, and Washington, D.C.
- Koch, T. and Berg, R.** (1970). Lehrbuch der Veterinar-Anatomie. Band III Die grossen versorgungs- und Steuerungssysteme Vep Gustav Fisher Verlag Jena.
- Mofsecian, T.B. and Manfelian, M.P.** (1950). Some characteristics of macro and micro-morphology of lymph nodes of buffalo and Ox. in Book of Irevancky Zooveterinary Institute: Trude. Vol- 12, Irevan P. 121-136.
- Nomina Anatomica Veterinaria** (1968). Vienna World Association of Veterinary Anatomists. Printed in Austria by Adolf Holzhausen's Successors, Vienna, P. 103.
- Ostertag, R.V.** (1934). Textbook of meat inspection English Ed. Bailliere, Tindal and Cox London. P. 52-85.
- Sisson, S. and Grossman, D.I.** (1968). Anatomy of the Domestic Animals. 4th Ed. Saunder Co. Philadelphia, London p. 748-750.
- Raghavan, O** (1964). Anatomy of the ox (ICAR) Chief Editor, Indian Council of Agrcultural Research. New-Delhi. P. 595.
- Taher, S.M.** (1962). Study of the lymph nodes of the camel. Thesis, Fac. of Vet. Med. Cairo University.
- Taher, El, S.** (1965). Zur Technik der Lymphgefäc darstellung. Sonderdruck aus, Zentralblatt furr veterinärmedizin. Reihe A. Band 12, Heft 5. Verlag paul, Berlin und Hamburg. P. 501-508.
- Thornton, H.** (1970). Text Book of meat inspection 5th Ed. Bailliere Tindall and Cassell London P. 99.

Author's address : Department of Anatomy, Histology and Embryology Faculty of Veterinary Medicine, Cairo University.