


دراسة هستوكيميائية لجلد الجمل

المخلص

الدكتورى . م . شاهين والدكتور م . ي . فهمى والدكتور س . م . الشافعى

درس التوزيع الهستوكيميائى لانزيمات سكسنيك ديهيدروجنتيميز وانزيم الفوسفاتيز الحامض والقاعدى كذلك حامض الريبونيوكليك والديزوكسى ريبونيوكليك والميوكوبولى سكاريدز الحامضية والمتعادلة والدهون المتعادلة فى جلد الجمل . وقورنت النتائج بمثيلتها فى الثدييات الاخرى .



Dept. of Histology, Fac. of Vet. Medic. Cairo University.
Head of Dept. : Prof. Dr. M.N. Gorgie

A HISTOCHEMICAL STUDY OF THE SKIN OF THE CAMEL (*Camelus Dromedarius*)

(With 8 figures)

By

Y.M. Shahien, M.F. Fahmy and S.M. El-Shafei

(Received at 20/3/1974)

SUMMARY

The occurrence of succinic dehydrogenase, acid and alkaline phosphatase, adenosine-triphosphatase enzymes, RNA and DNA, neutral and acid mucopolysaccharides and neutral fat in the skin of camel have been studied histo-chemically. The results obtained are compared with similar findings in other mammals.

INTRODUCTION

The production of a wide variety of enzymes and other chemical compounds in the skin of mammals, including the hair follicles, sebaceous and sweat glands, has been studied extensively (MONTAGNA, 1950; SHIBAEVA, 1970; MORETTI, RAMPINI, BERTAMINO and MARKS, 1970; HELWIG and MOSTOFI, 1971 and MARKS, 1972). The same work is lacking in the skin of the camel with regard to the available literature. FORAKER and WINGO (1955) found strong activity of succinic dehydrogenase (SDH) in the basal and malpighian layers, less prominent in the granular layer, and was absent in the keratinized cells of the human epidermis. LOBITZ, HOLYOKE and BROPHY (1955) observed that succinic dehydrogenase activity was much more marked in the cells of the eccrine sweat duct than in those of the secretory portion in human skin.

The alkaline phosphatase activity was present in the endothelium of blood capillaries which surround the sweat glands and in the epithelium of apocrine sweat glands and in hair papilla (KOPF, 1957). According to BARATOV, (1970) the alkaline phosphatase was localized in the basal layer of sheep epidermis and also in cells of sebaceous and sweat glands and in hair papilla.

According to HELWIG and MOSTOFI (1971) the intense activity of acid phosphatase was found in the upper stratum spinosum, granular layer, stratum corneum, about the hair, in the upper pilary canal in the so-called secretory granules of apocrine glands, melanocytes and in fibrocytes. Moderate activity was observed in sebaceous glands and eccrine sweat glands. Mild to minimal activity was detected in other epithelial cells. Collagen, arrectors pilorum muscle and blood vessels were essentially negative.

PIETRZYKOWSKA and KONECKI (1967) studied the nucleic acids content in human epidermis and found that the RNA content in the epidermis, is greater than that of DNA. SONTAGNA, CHASE and LOBITZ (1953) found that RNA was distributed as minute granules in the cytoplasm of the secretory cells of human apocrine sweat glands.

SHIBAEVA (1970) stated that the quantity of lipids declines slightly from basal to horny stratum in human epidermis. Selective location of lipids may be noted in the zones of intercellular boundaries. The intercellular granules of lipids appears in stratum corneum only at the opening of sweat glands.

The present investigation describes the histochemical features of the skin of *Camelus dromedarius*.

MATERIAL and METHODS

The material examined was taken from 25 normal healthy camels (*Camelus dromedarius*) slaughtered at Cairo abattoir. Skin specimens were taken from both sexes with an average ages 5-9 years old, and from four body areas (Neck, thorax, abdomen and tail).

Material was either fixed in 10% neutral formalin, calcium-formol, Carnoy's fluid and Bouin's fluid. It was processed for paraffin sections at a thickness of 5-7 microns, or frozen in dry ice and cut in a freezing microtome at a thickness of 20-30 microns.

The following chemical compounds and enzyme activities were investigated by various methods :

1. Succinic dehydrogenase (SDH).

Sections of fresh-frozen tissue were examined. Control sections were incubated in solutions without substrates.

2. Acid phosphatase.
The lead nitrate method (after GOMORI).
3. Alkaline phosphatase.
The calcium cobalt method (after GOMORI).
4. Adenosine - triphosphatase.
The calcium method (PADYKULA and HERMAN).
5. For the ribonucleic acid (RNA).
The methyl green-pyronin and ribonuclease (after BRACHET).
6. For the DNA.
Feulgen reaction (FEULGEN and ROSSENBECK).
7. For the nucleic acids.
The gallocyanin - chromalum method (EINARSON).
8. Mucopolysaccharides.
 - a) Alcian blue (MOWRY).
 - b) PAS - technique (LILLIE).
9. For the examination of glycogen.
Best's Carmine.
10. For the examination of neutral fat.
Sudan black B.
All the previous methods are outlined by Pearse (1968).

RESULTS

Succinic dehydrogenase (SDH)

The deposition of black granules (diformazan) in the cytoplasm of the cells is an indication of the presence of SDH. The more marked activity was in the basal cell layer and lower layers of stratum spinosum. The coiled sweat glands and their ducts showed marked cytoplasmic evidence of dehydrogenase activity (Figs. 1 and 2).

While the peripheral cells of the sebaceous glands showed marked evidence of dehydrogenase activity, the cytoplasm of cells in the central part of the gland showed a weak activity. The ducts showed maximal evidence of dehydrogenase activity in cells of the basal layer, diminishing toward the lumen.

The cells of the external root sheath showed strong activity of SDH, but the internal root sheath was less active. The germinal matrix of hair follicles showed more activity of dehydrogenase. There is no activity in the hair shaft (Fig. 2).

The endothelial cells of small blood vessels, fibrocytes, lymphocytes and arrectors pilorum muscle showed slight degree of dehydrogenase activity.

Acid phosphatase

Positive and marked activity of this enzyme was observed in the cells of the basal layer and decreased in the cells of the upper layers and the internal root sheath of hair follicle. High activity of this enzyme was found in the lower part of hair bulb and in the wall of large blood vessels, while moderate activity was seen in sebaceous and sweat glands.

Alkaline phosphatase

The activity of this enzyme appeared in the endothelial cells of the blood vessels, the dermal hair papilla and the connective tissue sheath about the hair bulb. The sebaceous and sweat glands showed intense reaction of this enzyme (Fig. 3).

Adenosine-triphosphatase

The cytoplasm of the epidermal cells and the dendritic cells showed more marked activity. The sebaceous gland and its duct, the hair follicles especially in the outer root sheath and the arrectors pilorum muscles were strongly positive (Fig. 4). In the cytoplasm of the sweat gland, a fine granular localization of the reaction product could be seen. The nuclei, the basement membranes and the connective tissue capsule were intensely coloured (Fig. 4 and 5). The endothelium of blood vessels and the muscular layer were clearly coloured. Fibroblasts, histiocytes and the collagenic fibers were slightly stained.

Ribonucleic acid (RNA)

The site of RNA was the cytoplasm and nucleoli. High pyroninophilic reaction was observed in the epidermal cells, hair follicles, hair bulb, erector pili muscles, peripheral cells of sebaceous and cells of sweat glands. The RNA could not be observed in the central cells of sebaceous glands.

Deoxyribonucleic acid (DNA)

Nuclei of the cells of basal layer of epidermis, lower parts of hair bulb, peripheral cells of sebaceous glands and cells of sweat glands were strongly stained with methyl green, Feulgen preparations and gallocyanin. The content of DNA decreases from the basal to the horny layer of the epidermis. In gallocyanin or Feulgen preparations, the nuclei were stained diffusely, seldom showing distinct chromatin particles (Fig. 6).

Mucopolysaccharides

At the dermoepidermal junction, PAS - positive material was observed. The peripheral cells of sebaceous glands had numerous amount of this material. High activity was found in the sweat glands. Positive reaction with alcian blue was observed in the hair bulb, sweat glands (Fig. 7) and mast cells. The collagenous fibres were slightly reacted.

Neutral fat

Sudan black B showed an intense reaction in the stratum corneum. Lipid droplets were found in the epidermal cells and also in the intercellular bridges. The large central cells of the sebaceous glands and its outlets showed strong positive reaction but the peripheral cells of this glands did not react (Fig. 8).

DISCUSSION

In the present investigation, succinic dehydrogenase was found to be abundant in the basal cells of epidermis, sebaceous glands, external root sheath of hair follicle and sweat glands. PADYKULA (1952) suggested that this oxidative enzyme is present in greatest concentration within portions of tissues which show high metabolic activity or are engaged in absorptive or secretory activities. Succinic dehydrogenase have also shown relationship to sites of cell growth (FORAKER and WINGO, 1955). The

enzyme could not be demonstrated in regions which are considered to be less active metabolically e.g. The outer layer of stratified squamous epithelia (PADYKULA, 1952). Our investigation with this concept is agreement.

Acid phosphatase is important in energy transfer through high energy phosphate compounds, so the occurrence of a strongly positive reaction for this enzyme would be likely in an actively secreting cells and gland (WIGHT *et al.*, 1971). Nonspecific acid phosphatase shows the granular localization typical of lysosomal enzymes. It is of interest to note that the results of these studies of the acid and alkaline phosphatase in camel skin are in accord with the results obtained by BARATOV (1970) in the skin of sheep and cat, and HEIWIG and MOSTOFI (1971) in the human skin.

In our investigation, there was a lack of alkaline phosphatase activity in the epidermis. The sebaceous and sweat glands and blood vessels showed intense reaction. Except for the artiodactyl swine, most of the animals showed a lack of alkaline phosphatase activity in the epidermis. In the sebaceous glands, alkaline phosphatase activity varied somewhat even in families of the same order, e.g. in insectivora, and markedly in carnivora. Considerable activity was more often seen in the apocrine sweat glands than in the sebaceous glands, especially in perissodactyla and caprine and bovine artiodactyla (MORETTI *et al.*, 1970).

The strong pyroninophilia observed in the cytoplasm of the epithelial cells of epidermis denoted the abundance of ribosomes (BARATOV, 1970 and GELWIG and MOSTOFI, 1971). These results were also in support of the concept of ACTHEN, (1959) that the epidermis is concerned with the synthesis of protein during keratinization. The RNA content in the epidermis was greater than that of DNA. The content of both nucleic acids decreased from the basal to the horny layer (ACTHEN, 1957; HODGSON, 1962 and MONTES *et al.*, 1961). According to autoradiographic researches of FUKUYAMA and BERNSTEIN (1961), (1963) the active DNA was mainly present in the basal layer and RNA in the whole epidermis.

Neutral fat had been demonstrated in the stratum corneum, epidermal cells, intercellular bridges and the sebaceous glands, this is in agreement with the results on other mammals mentioned by MONTAGNA, (1950). DUPRE (1953) and PRUNIERAS (1957) found, lipids in the intercellular bridges of the epidermis. The first author found that the intercellular bridges containing glycolipid complex, were not only positive with sudan black B stain but also positive with PAS - reaction for polysaccharides.

REFERENCES

- Athen, G. (1957) : Acide ribonucléique et synthèse protéinique dans le développement de la peau de l'embryon humain. *Arch-belg. Derm.*, 13 : 140.
- Athen, G. (1959) : Recherches sur la keratinisation de la cellule épidermique chez l'homme et le rat. *Arch. Biol.*, 70 : 1-119.
- Paratov, Y.A. (1970) : Histochemical and electron microscopical investigations on epidermis and its derivatives of sheep and cat. Thesis, Moscow, Veterinary Acad.
- Dupré, A. (1953) : Cited by Shibaeva, S.M. (1970) : Epidermal lipids, *Arch. Anat. Hist. and Embryo. Medicine, Leningrad.*, 8 (2) : 71-75.
- Forker, A.G. and Wingo, W.J. (1955) : Histochemical studies of skin ;
 I. Localization of dehydrogenase activity.
 II. Protein — Bound sulfhydryl and Disulfide groups. *Arch. Dermat.*, 72 : 1-6.
- Fukuyama, K. and Bernstein, I.A. (1961) : Autoradiographic studies of the incorporation of thymidine — H³ into deoxyribonucleic acid in the skin of young rats. *Invest. Derm.*, 36 : 321-324.
- Fukuyama, K. and Bernstein, I.A. (1963) : Site of synthesis of ribonucleic acid in mammalian epidermis. *J. Invest. Derm.*, 41 : 47-49.
- Helwig, E.B. and Mostofi, F.K. (1971) : "The skin". International academy of Pathology monograph. The Williams and Wilkins company FAITINCRE.
- Hodgson, C. (1962) : Nucleic acids and their decomposition products in normal and pathological horny layers. *J. Invest. Derm.*, 39 : 69-72.
- Kopf, A.W. (1957) : The distribution of alkaline phosphatase in normal and pathologic human skin. *Arch. Derm.*, 75 : 1-37.
- Lobitz, W.C., Holyoke, J.B. and Brophy, D. (1955) : Histochemical evidence for human eccrine sweat duct activity. *Arch. Dermat.* 72 : 229-236.
- Marks, R. (1972) : Histochemical applications of skin surface biopsy. *Brit. J. Derm.*, 86 (1) 20-26.
- Montagna, W. (1950) : Perinuclear sudanophil bodies in mammalian epidermis. *Quart. J. Microscop. Sci.*, 91 : 205-208.
- Montagna, W., Chase, M.B. and Lobitz, W.C. (1953) : Histology and cytochemistry-human skin ; IV. The eccrine sweat glands. *J. Invest. Derm.*, 20 : 415-523.
- Montes, L.F., Curtis, A.C. and Block, W.D. (1961) : Nucleic acids in normal and pathological skin. *Dermat.*, 123 : 129-144.
- Moretti, G., Rampini, E. and Bertamio, R. (1970) : Alkaline phosphatase in the skin of mammals *Derm. Clin., Med. Sch., Univ. Genoa-Ital. Gen. Rev. Derm.*, 10 (3) : 15-23
- Padykula, H.A. (1952) : The localization of succinic dehydrogenase in tissue sections of the rat. *Am. J. Anat.* 91 : 107-145.
- Pears, A.G. (1968) : Histochemistry, theoretical and applied 2nd ed. Edinburgh churchill living stone.
- Pietrzykowska, A. and Konecki, J. (1967) : The nucleic acids content in human epidermis in relation to age *Dermat.*, 135 : 472-476.
- Prunieras, M. (1957) : Cited by Shibaeva (1970) : Epidermal lipids. *Arch. Ant. Hist. and Embryo., Medicine, Leningrad*, 8 (2) : 71-75.
- Shibaeva, S.M. (1970) : Epidermal lipids. *Arch. Anat. Hist. and Embryo., Medicine, Leningrad*, 8 (2) 71-75.
- Wight, P.A., Mackenzie, G.M., Rathwell, B. and Burns, R.B. (1971) : The barderian glands of the domestic fowl. I. Histochemistry *J. Anatomy.* 110 (3) : 323-333.

Authors address : Dr. Y. M. Shahien Dept. of Histology, Fac. of Vet. Medic. Cairo University.

1912

Dear Sir,

I have the honor to acknowledge the receipt of your letter of the 10th inst. in relation to the above mentioned matter.

I am sorry to hear that you are unable to attend the meeting on the 15th inst. I am sure that your presence would have been most valuable.

I am, Sir, very respectfully,
Yours truly,
Wm. H. ...

Very truly yours,
Wm. H. ...

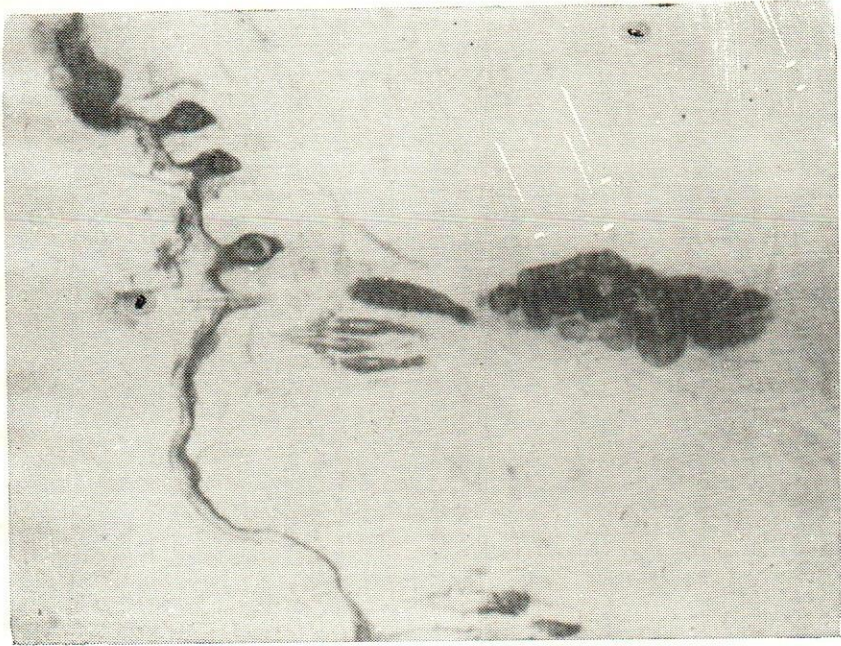


Fig. 1.—Succinic dehydrogenase activity are seen in the epidermis and hair follicles, sebaceous and sweat gland. $\times 20$).

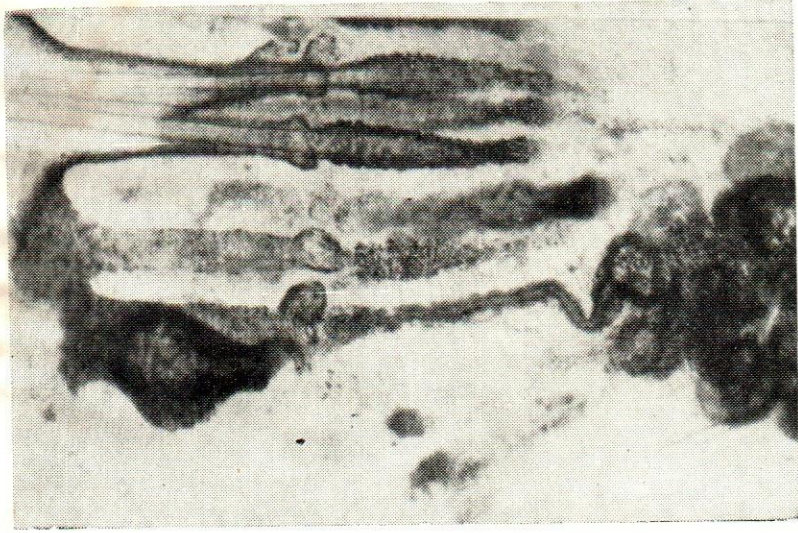



Fig. 2.—Succinic dehydrogenase activity are seen in the epidermis and hair follicles, sebaceous and sweat glands. $\times 60$).



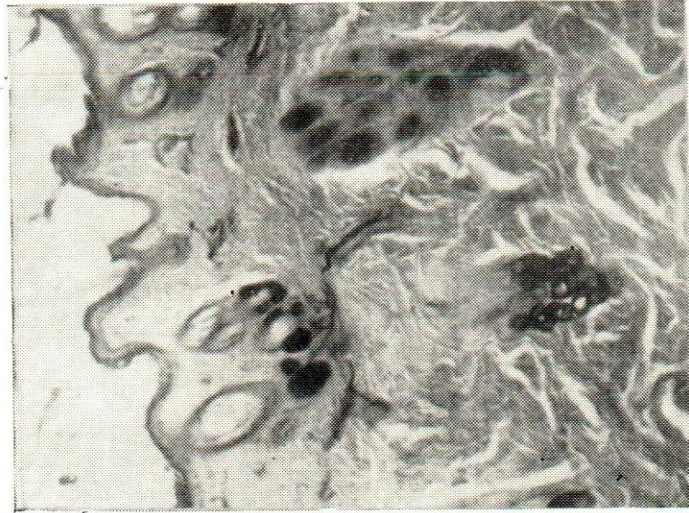



Fig. 3.—Distribution of alkaline phosphatase activity in blood vessels, sebaceous and sweat gland and hair papilla. $\times 20$.

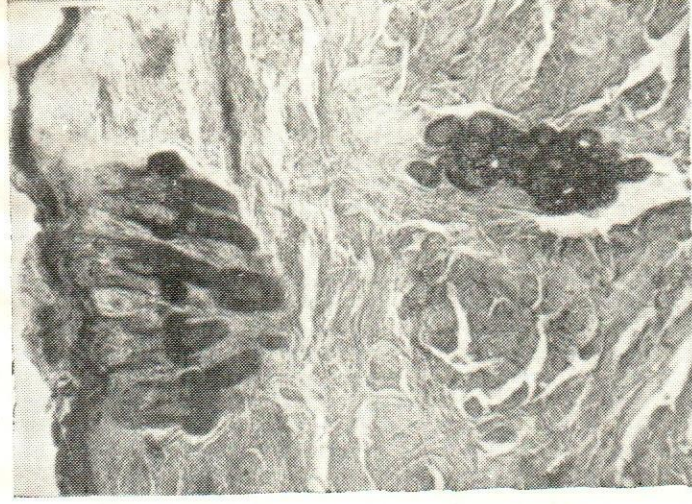

Fig. 4.—Distribution of adenosine-triphosphatase activity in epidermis, hair follicles, sebaceous and sweat glands. $\times 35$.



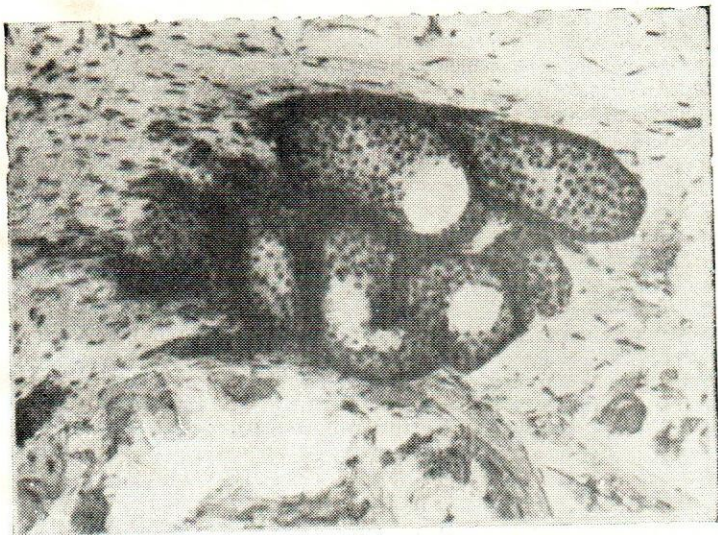



Fig. 5.—High level of adenosine-triphosphatase activity is seen in the sweat gland. ($\times 100$).

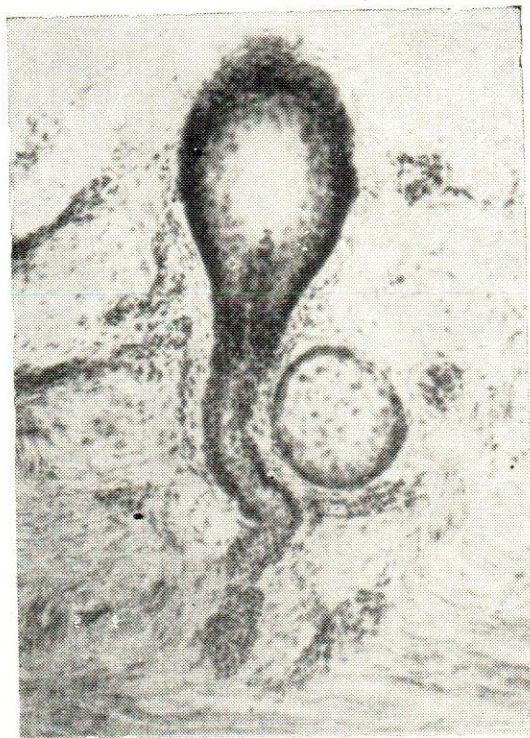
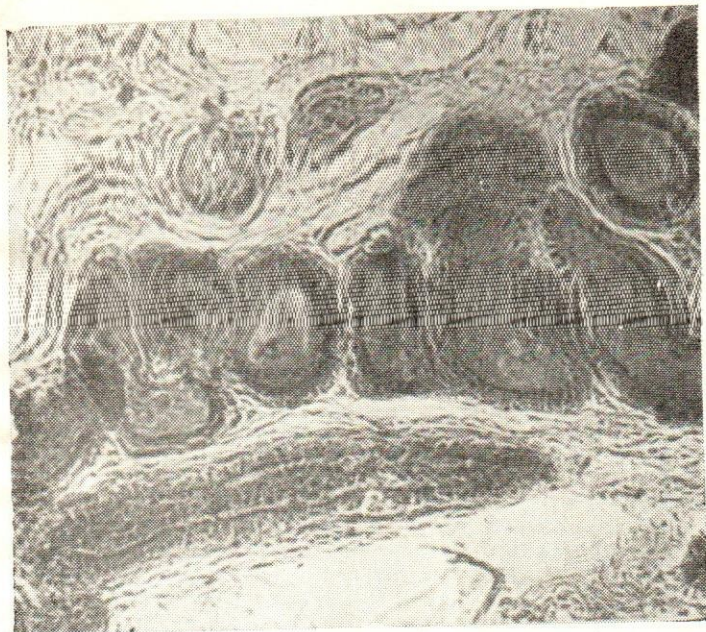
Fig. 6.—Distribution of Nucleic acid in hair follicle, duct of sweat gland and sebaceous gland. ($\times 250$).






7.—Alcian blue reaction for acid mucopolysaccharides in sweat glands
($\times 5250$).

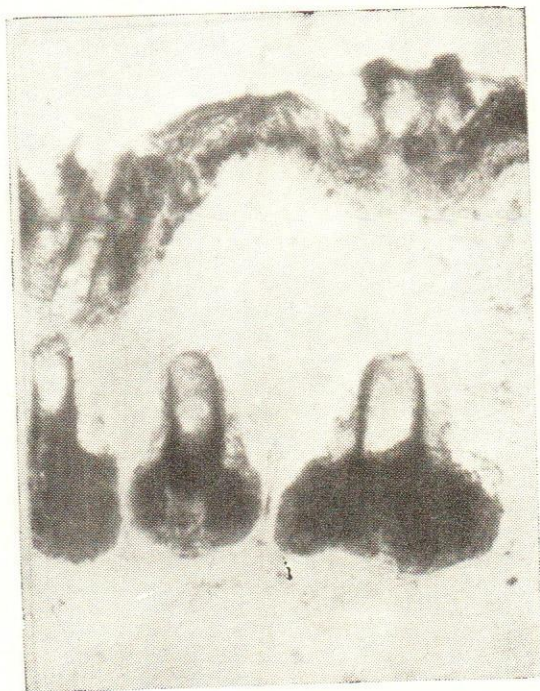

Fig. 8.—Fat droplets demonstrated in the epidermis and
sebaceous glands. ($\times 100$).



Copyright © 1900 by the American Book Company
New York, N. Y.



Copyright © 1900 by the American Book Company
New York, N. Y.