

**Diagnostic Role of Ultrasonography Compared to Magnetic Resonance Imaging in Ankle Pain****Abdelrahman Amer Bakir Ali<sup>a</sup>, Ahmed Okasha<sup>a</sup>, Ghada M. Abdelrazeq<sup>a</sup>**<sup>a</sup>Department of Diagnostic Radiology, Faculty of Medicine, South Valley University, Qena, Egypt**Abstract**

**Background:** Ankle pain is common in clinical practice. Various lesions including trauma, impingement syndromes, inflammatory arthritis, soft tissue, and bony lesions affect the ankle joint. Imaging is crucial in the determination of the pain cause and management.

**Objectives:** This study aimed to evaluate the role of high-resolution musculoskeletal ultrasonography (MSK US) compared to the role of magnetic resonance imaging (MRI) in ankle pain.

**Patients and Methods:** This study conducted on 29 patients who presented with ankle pain during the period from September 2018 until September 2019 at Qena University Hospitals, South Valley University, Egypt and evaluated by plain radiographs, US and MRI. Comparative analysis was done between MRI and US.

**Results:** The US was able to detect various lesions affecting the ankle ( tendinous and ligamentous injury, plantar fasciitis, joint effusion, bursitis, ganglion cysts, tarsal tunnel syndrome) with sensitivity and specificity of 100% regarding tendons pathology and sensitivity 80 %, specificity 100 % regarding ligamentous injuries with overall accuracy 95 % compared to MRI. US was negative in all MRI positive bony lesions.

**Conclusion:** The US is a useful imaging modality in identifying a large spectrum of causes of ankle pain and should be considered a first step diagnostic tool when an osseous lesion is not suspected.

**Keywords:** Ankle Pain, Musculoskeletal Ultrasonography, Ankle MRI

**Introduction**

Ankle pain is commonly encountered in clinical practice due to ankle injury in trauma, overuse syndromes, or inflammatory processes. In addition to physical examination, different imaging modalities are used in the assessment of the ankle including, radiographs, ultrasonography (US), computed tomography (CT), and magnetic resonance imaging (MRI) (Shalaby et al., 2016).

In fact, magnetic resonance imaging (MRI) is more frequently performed for musculoskeletal (MSK) lesions than US, yet both of them have pros and cons and can be considered complementary to each other (Lento & Primack, 2008).

Recently, the use of high-frequency (high-resolution) US has been increasing and has shown promising utility in many areas of medicine. However, the utility of MSK US for ankle complaints has not been widely investigated.(Delzell et al., 2017).

While MRI is considered the gold standard in tendons and ligaments assessment with the ability to show associated intra-articular abnormalities, joint effusion, and bone marrow edema, high resolution MSK US has become a preliminary important tool in the assessment of ligaments and tendons around the ankle, not only because of its low cost, availability, and safety (free of ionizing radiation),

**Copyright:** © Ali et al. (2021) Immediate open access to its content on the principle that making research freely available to the public supports a greater global exchange of knowledge. Users have the right to Read, download, copy, distribute, print or share link to the full texts under a [Creative Commons BY-NC-SA 4.0 International License](https://creativecommons.org/licenses/by-nc-sa/4.0/).

but also it provides a detailed depiction of normal anatomy and is effective for evaluating ligaments integrity (Sconfienza et al., 2015).

In addition, US allow dynamic examination contributing to the detection of instability disorders in ligamentous injuries. It can facilitate accurate identification, localization, and differentiation between different pathological entities in the adjacent anatomical structures (Sconfienza, et al., 2015; Van Rijn, et al., 2008).

Furthermore, US detects different peripheral nerve abnormalities and their relationship to adjacent anatomical structures such as in tarsal tunnel syndrome (Causeret et al., 2018). This study aimed to prospectively evaluate the role of the high-resolution US of the ankle joint in cases of ankle pain compared to MRI, concerning the lesion types.

#### Patients and Methods

**Study Population:** This study was conducted on 29 patients ranging in age from 5-65 years with a mean age of 38 years who complained of ankle pain and were referred by Emergency departments or outpatient clinics to the Radiodiagnosis Department in Qena University Hospitals, Egypt during the period from September 2018 until September 2019.

#### Inclusion criteria:

- Patients complaining of acute or chronic ankle pain (post-traumatic or non-traumatic).
- No age or sex predilection.

#### Exclusion criteria:

- Previous ankle surgery, interventional intra-articular procedures (previous arthroscopy, injections), fractures

**Methods:** All patients were subjected to history taking and clinical examination. They underwent plain X-ray, real-time high-resolution ultrasonography, and MRI for the affected ankle joint. Prospective comparative analysis of US and MRI results was done.

#### A- Plain Radiography :

All patients underwent plain radiograph in AP and lateral views to exclude any fractures

#### B- US Examination :

Standard ultrasonography examination of the ankle was conducted using high-frequency linear probes (7-12 MHz), LOGIQ P6, and LOGIQ P5 (GE Healthcare, USA)

No special preparation was needed. Following European Society of Musculoskeletal Radiology (ESSR) technical guidelines in ankle examination (Martinoli, 2010), the ankle was examined in a compartmental way with the examination of different related anatomical structures. The examination was done with the patient lying in a supine position with knee flexed 45° so that the plantar surface of the foot lies flat on the table. Approach to different ankle compartments was accomplished by manipulation of the foot and ankle in different positions.

Anteriorly, tibialis anterior (TA), extensor hallucis longus (EHL), and extensor digitorum longus (EDL) tendons were examined in both longitudinal and short axis from myotendinous junction to insertion. In addition, anterior talofibular (ATFL), anterior tibiofibular (ATiFL), and calcaneofibular (CFL) ligaments were examined. Joint effusion was assessed in anterior joint recess.

Laterally, peroneal longus (PL) and peroneal brevis (PB) tendons were examined.

Medially, the Tibialis posterior (TP), flexor digitorum longus (FDL), and flexor hallucis longus (FHL) were examined as well as the deltoid ligament. The tibial nerve was assessed for nerve entrapment.

Posteriorly, the Achilles tendon was examined from the myotendinous junction until its insertion in both short and longitudinal axis. In addition, retro-calcaneal and retro-calcaneal bursae checked for bursitis. The plantar fascia assessed for plantar fasciitis.

### C- MRI Examination

All patients subjected to MR imaging of the affected ankle(s) on a high field-strength scanner. MRI performed using Philips Achieva (1.5 T) (The Netherlands). A dedicated extremity coil used in all cases.

#### Technique:

##### • Positioning

Every patient examined in a supine position with the ankle and foot in a neutral position with plantar flexion of 20–30 degrees for reducing the “magic angle” artifact. The ankle supported using pads.

##### • Imaging Protocol

Routine ankle MR imaging performed in the axial, coronal, and sagittal planes parallel to the tabletop. The foot was imaged in the oblique axial plane (i.e., parallel to the long axis of the metatarsal bones), oblique coronal plane (i.e., perpendicular to the long axis of the metatarsals), and oblique sagittal plane.

T1-weighted (repetition time msec/echo time msec = 600/20) and T2-weighted (2,000/20,80) MR images are obtained with a 12–16-cm field of view, a 256 x 192–512 acquisition matrix, 1–2 signals acquired, and a 3–5-mm section thickness with 1-mm intervals. Marrow abnormalities were evaluated with fat suppression techniques such as fat-suppressed proton-density-weighted (PDW) imaging or with short tau inversion recovery (STIR) sequences (1500/20; inversion time recovery msec = 100 - 150).

Sagittal T1WIs, axial T1WIs T2WIs, and proton density images, coronal T1WIs as well as Sagittal or coronal STIR images obtained.

#### Statistical Analysis

Analysis of data was done using Statistical Package for Social Sciences (SPSS) as follows:

- Description of quantitative variables as mean, SD, and range.
- Description of qualitative variables as number and percentage.
- Fisher exact test was used to compare qualitative variables.

Validity parameters: Sensitivity, specificity, PPV (positive predictive value), NPV (negative predictive value) and accuracy. P value > 0.05 insignificant.

P < 0.05 significant. P < 0.001 highly significant (Knapp & Miller, 1992).

#### Ethical Considerations:

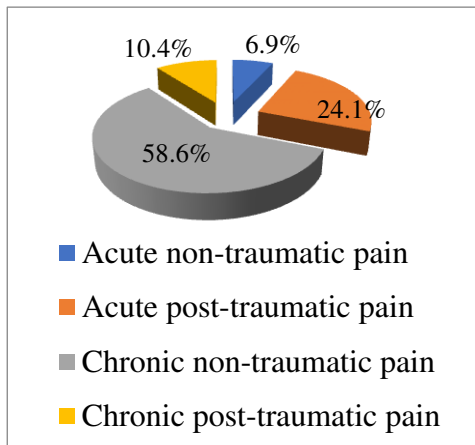
Approval of the ethical committee in the Faculty of Medicine, South Valley University was taken to start the research. Informed written consent was taken from the patients or the relatives in South Valley University Hospitals.

#### Results:

Our study included twenty-nine patients who complained of ankle pain, acute or chronic, traumatic or non-traumatic. No age restriction or sex specification. Table (1) summarizes the patients' clinical data. The majority of patients were referred for chronic ankle pain. Figure.1 represents the percentage of each complaint.

**Table1: patients' clinical data**

		Number	%
Age (mean ± SD)		38.8±17.8	
Sex	Male	13	44.8%
	Female	16	55.2%
Affected side	Right	15	51.7%
	Left	13	44.8%
	Both	1	3.5%
Complaint	Acute non-traumatic pain	2	6.9%
	Acute post-traumatic pain	7	24.1%
	Chronic non-traumatic pain	17	58.6%
	Chronic post-traumatic pain	3	10.4%
Co-morbidities	None	19	59.4%
	DM	6	18.7%
	Hypertension	3	9.4%
	Rheumatoid arthritis	2	6.3%
	Hyperlipidemia	1	3.1%
	Varicose veins	1	3.1%



**Fig 1: Complaint Distribution**

Tendinous lesions were seen in 12 patients representing about 42 % of all study sample. Achilles tendon was the most affected and seen in six patients representing (50%) of all tendons injuries. A comparative study between MRI and US (Table.2) showed similar results with sensitivity, specificity, PPV, NPV, and accuracy 100 %.

Ligamentous injuries were found in five patients, with the ATFL was the most affected and seen in three patients.

A comparative study between MRI and US (Table.3) showed 80 % sensitivity, 100 % specificity, 100 % PPV, 96 % NPV, and 96.5 overall accuracy

Various conditions were encountered in 12 patients as masses (2 ganglion cysts, 1 lipoma), 1 retro-Achilles bursitis, 1 joint effusion, 2 bony lesions (1 osteochondritis dissecans, 1 bone marrow edema), 1 subcutaneous foreign body, 1 tarsal tunnel syndrome, 1 sinus tarsi, and 2 plantar fasciitis. Sensitivity and specificity for soft tissue masses were 100 %

### Illustrative Cases:

**Case 1:** 19-year-old male patient presented with chronic post-traumatic left ankle pain after trauma to the posterior ankle 3 months ago. By clinical examination, there is a tenderness of the AT. US and MRI revealed partial AT tear (figure 2).

**Case 2:** 46-year-old female patient presented with chronic medial right ankle pain and swelling of 3 months duration. There is tenderness posterior to

the medial malleolus on examination. US and MRI revealed FHL tenosynovitis (figure 3).

### Discussion:

The ankle joint is considered the most injured joint in the body. It is commonly affected due to trauma, overuse syndromes, inflammatory arthritis, and infection. Imaging is considered a cornerstone in the management of injured painful ankle and various imaging modalities have been used to evaluate the ankle including radiographs, computed tomography, and magnetic resonance imaging (Bartoniček, 2003). Traditionally, a radiograph is the first and most used imaging modality in the assessment of the ankle, but recently using MRI in imaging the ankle has increased as a problem-solving tool because of its superior soft tissue resolution and ability to visualize the osseous structures, cartilage, and soft tissues of the ankle (Campbell, 2006).

Ultrasound imaging is a cheap, irradiation-free, and readily available tool with high resolution of the soft tissue and has a growing importance in ankle and foot imaging (Rogers & Cianca, 2010).

This study aimed to evaluate the role of the US compared to the MRI in ankle pain regarding the different pathology.

Our study included 29 patients who complained of ankle pain; acute, chronic, traumatic, and non-traumatic pain. Patients ranged in age from five to 65 years with a median age was 38 years. Females represented the majority of the patients, 16 patients (55%). The most affected side was the right side seen in 15 cases (52%). Chronic ankle pain was the most encountered symptom and seen in 20 patients (69%). History of trauma was present in 10 patients (35%).

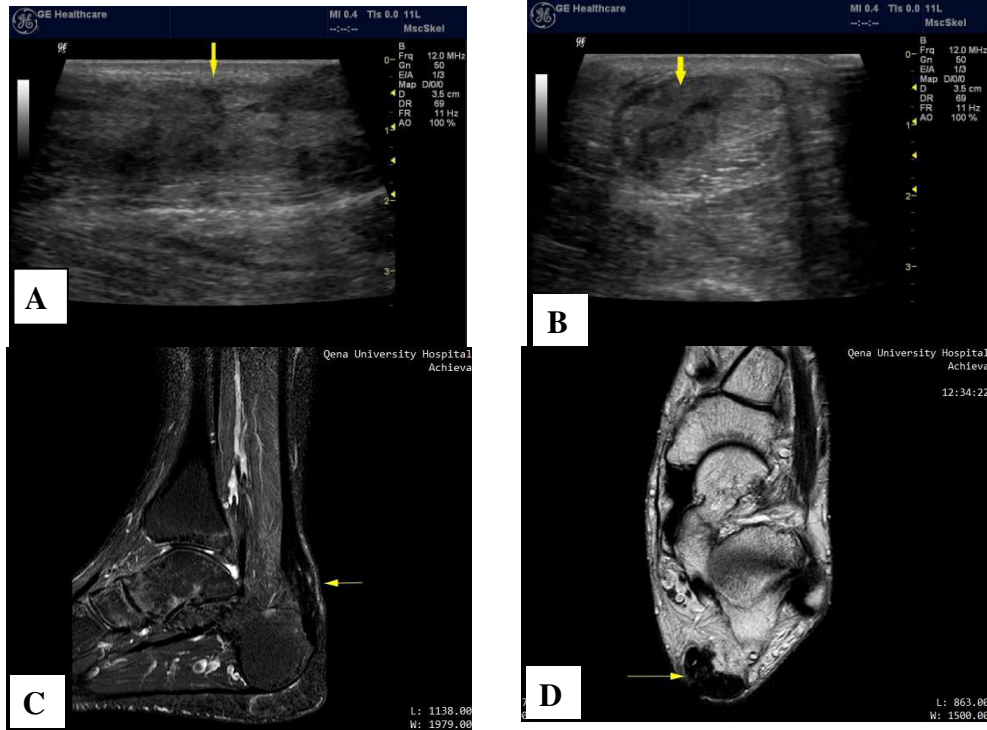
In our study, tendon injuries were encountered in 12 patients (42%). The Achilles tendon was the most affected and seen in six patients (50 % of affected tendons). Various pathologies of the Achilles tendon were seen including tendinosis (1), paratenosynovitis (1), partial tear (1), and complete tear (2), and Achilles xanthoma (1). This agreed with (El-Liethy & Kamal, 2016) study where Achilles tendon injuries represented about 52% of tendon injuries. Although it is considered the strongest tendon in the body, literature agrees that it is the most com-

monly injured tendon in the ankle and mostly at a site two to six centimeter from its insertion. (Hartgerink et al., 2001).

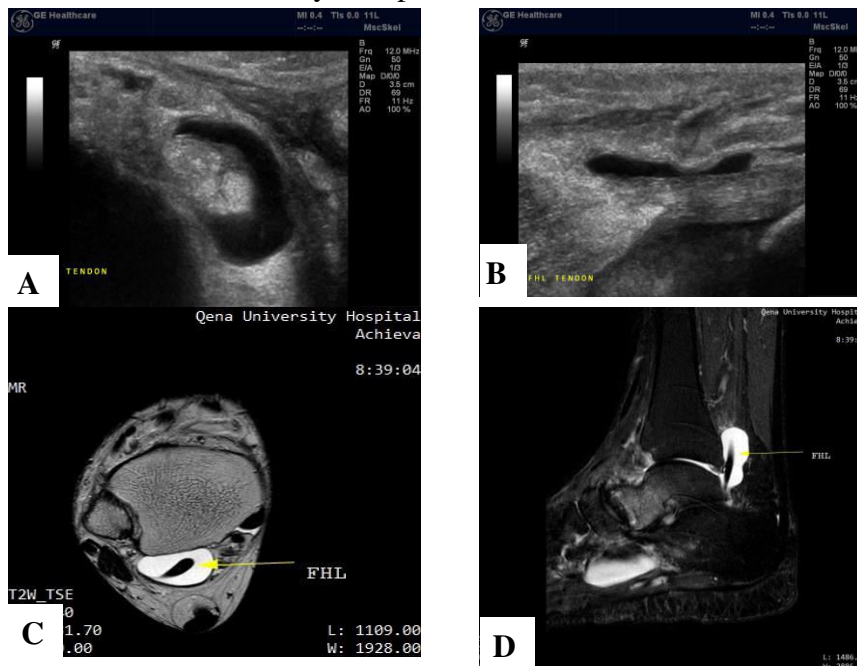
Complete tears of the Achilles tendon were found in two diabetic female cases aged 53 and 56 years respectively. This coincides with (Liffen, 2014) who reported that Achilles tendon rupture

affecting middle-aged individuals with abnormal tendons.

In our study, the US results regarding Achilles tendon lesions coincided with MRI results in all cases (100% sensitivity), which was similar (Hartgerink et al., 2001) who reported ultrasound was



**Figure 2:** Partial AT tear. Longitudinal (A) and transverse (B) US images showing thickening of AT with heterogeneous echopattern and loss of fibrillary echopattern at the anteromedial side. Sagittal STIR (C) and axial T2WI (D) MR image of the same patient showing thickening of the AT with intra-substance high signal intensity with partial loss of the fibrillary echopattern at its anteromedial side



**Figure 3:** FHL tenosynovitis. Transverse(A) and longitudinal(B) US image showing anechoic fluid distending the FHL tendon sheath that seen thickened. Axial T2WI (C) and Sagittal STIR MR images showing high signal fluid intensity distending FHL tendon sheath.

**Table 2: Comparative statistical analysis between US and MRI in the evaluation of tendon pathology**

	US re- sults	MRI results			US Diagnostic Accuracy				
		-ve	+ve	p-value	Sens.	Spec.	PPV	NPV	Acc.
<b>Achilles tendi- nosis</b>	-ve	28 (100%)	0 (0%)	.003*	100%	100%	100%	100%	100%
	+ve	0 (0%)	1 (100%)						
	Total	28 (96.6%)	1 (3.4%)						
<b>TA tendinosis</b>	-ve	28 (100%)	0 (0%)	.003*	100%	100%	100%	100%	100%
	+ve	0 (0%)	1 (100%)						
	Total	28 (96.6%)	1 (3.4%)						
<b>PB tendinosis</b>	-ve	27 (100%)	0 (0%)	.001*	100%	100%	100%	100%	100%
	+ve	0 (0%)	2 (100%)						
	Total	27 (93.1%)	2 (6.9%)						
<b>Achilles Para tendinitis</b>	-ve	28 (100%)	0 (0%)	.003*	100%	100%	100%	100%	100%
	+ve	0 (0%)	1 (100%)						
	Total	28 (96.6%)	1 (3.4%)						
<b>Peroneal Te- nosynovitis</b>	-ve	28 (100%)	0 (0%)	.003*	100%	100%	100%	100%	100%
	+ve	0 (0%)	1 (100%)						
	Total	28 (96.6%)	1 (3.4%)						
<b>FHL Teno- synovitis</b>	-ve	28 (100%)	0 (0%)	.003*	100%	100%	100%	100%	100%
	+ve	0 (0%)	1 (100%)						
	Total	28 (96.6%)	1 (3.4%)						
<b>Achilles par- tial tear</b>	-ve	28 (100%)	0 (0%)	.003*	100%	100%	100%	100%	100%
	+ve	0 (0%)	1 (100%)						
	Total	28 (96.6%)	1 (3.4%)						
<b>TA partial tear</b>	-ve	28 (100%)	0 (0%)	.003*	100%	100%	100%	100%	100%
	+ve	0 (0%)	1 (100%)						
	Total	28 (96.6%)	1 (3.4%)						
<b>Achilles com- plete tear</b>	-ve	27 (100%)	0 (0%)	.001*	100%	100%	100%	100%	100%
	+ve	0 (0%)	2 (100%)						
	Total	27 (93.1%)	2 (6.9%)						
<b>Achilles xan- thoma</b>	-ve	28 (100%)	0 (0%)	.003*	100%	100%	100%	100%	100%
	+ve	0 (0%)	1 (100%)						
	Total	28 (96.6%)	1 (3.4%)						
<b>Total</b>	-ve	17	0	.001	100%	100%	100%	100%	100%
	+ve	0	12						
	Total	17	12						

\*Significant p-value < 0.05

TA=Tibialis Anterior  
PB= Peroneus Brevis

**Table 3: Comparative statistical analysis between US and MRI in the evaluation of ligament pathology**

	US re- sults	MRI results			US Diagnostic Accuracy				
		-ve	+ve	p-value	Sens.	Spec.	PPV	NPV	Acc.
<b>ATFL sprain</b>	-ve	28 (100%)	0 (0%)	.003*	100%	100%	100%	100%	100%
	+ve	0 (0%)	1 (100%)						
	Total	28 (96.6%)	1 (3.4%)						
<b>CFL sprain</b>	-ve	28 (100%)	1 (100%)	0%	100%	0%	96.6%	96.6%	
	+ve	0 (0%)	0 (0%)						
	Total	28 (96.6%)	1 (3.4%)						
<b>ATiFL sprain</b>	-ve	28 (100%)	0 (0%)	.003*	100%	100%	100%	100%	100%
	+ve	0 (0%)	1 (100%)						
	Total	28 (96.6%)	1 (3.4%)						
<b>ATFL tear</b>	-ve	27 (93.1%)	0 (0%)	.001*	100%	100%	100%	100%	100%
	+ve	0 (0%)	2 (6.9%)						
	Total	27 (93.1%)	2 (6.9%)						
<b>Total</b>	-ve	24 (82.8)	1 (3.4%)	0.001*	80%	100%	100%	96%	96.5 %
	+ve	0 (0%)	4 (13.8)						
	Total	24(82.8%)	5(17.2%)						

ATFL=Anterior talo-fibular ligament

CFL=Calcaneo-fibular ligament

\*Significant p-value < 0.05

100 % sensitive in detecting 26 surgically proved Achilles tendon injuries. In addition, US characterization of different Achilles injuries was similar to MRI.

In this study, tendinosis was the most common tendon pathology. It was found in five cases (38 % of affected tendons), 2 Achilles tendons, 2PB, and 1TA. This set in line with (El-Liethy & Kamal, 2016) who found tendinosis in seven (33%) cases out of 21 total tendons' pathology with the Achilles is the most affected tendon.

In our study, we encountered five cases of ligamentous injuries. ATFL injuries were found in three cases (60% of ligamentous lesions). That agreed

with (Cheng et al., 2014) who stated that ATFL was the most injured ankle ligament. US showed ATFL injuries in all cases similar to MRI.

That agreed with (Margetic et al., 2009) that yield 100% sensitivity of US compared to MRI in the detection of ligamentous injuries.

In our study, six soft tissue lesions were encountered, 2 cases of plantar fasciitis, 1 case of retrocalcaneal bursitis, 2 ganglion cysts, and 1 subcutaneous lipoma. US and MRI showed the same results in soft tissue lesions. This agrees with (Fessel et al., 1998) and (Teefey et al., 2004) that

reported the accuracy of ultrasonography in the estimation of size and localization of the ganglion was similar to MRI.

In our study, two cases of bony lesions were encountered and only found by MRI, one with osteochondritis desiccans of the talar dome and one with bone marrow edema of the talus. In agreement with (Bianchi & Martinoli, 2007) they stated that ultrasound is not useful in assessing osteochondral injuries except in stage 4 lesions which may be detected as intraarticular loose bodies, and reported that MR imaging can properly identify osteochondral injuries at its different stages.

Tarsal tunnel syndrome was encountered as the only case of nerve entrapment around the ankle in our study. The cause of entrapment was diagnosed by US and MRI to be due to dilated veins in a patient with varicose veins. This is agreed with (Choufani et al., 2016) who stated that the most common ankle entrapment neuropathy is tarsal tunnel syndrome which is mostly due to soft tissue masses within the tarsal tunnel.

In this study, we encountered various lesions causing ankle pain. Although the study sample was not enough to demonstrate all the causes of ankle pain, the US was able to diagnose most of the cases with similar results to MRI.

Although it remains operator dependent, yet the implementation of standardized protocols will minimize this pitfall and allow the presence of professional ultrasonographers. In comparison to other imaging modalities especially MRI, it is cheap, rapid, less invasive, and with no risk of ionizing radiation if compared to plain radiography and CT. It still can help in management when guided biopsies and aspirations are required.

### Conclusion:

A large spectrum of abnormalities was demonstrated with ultrasound in this study despite the small sample size. This has shown the utility of ultrasound as a useful imaging modality when evaluating patients with ankle pain. As a cheap and easily available tool, it could replace expensive cross-sectional methods in a resource-limited setting where they are not readily available. In view of specificity, sensitivity, and ability to demonstrate a large spectrum of abnormalities, ultrasound should be recommended as the initial imaging modality in patients with ankle pain.

tional methods in a resource-limited setting where they are not readily available. In view of specificity, sensitivity, and ability to demonstrate a large spectrum of abnormalities, ultrasound should be recommended as the initial imaging modality in patients with ankle pain.

### References:

- **Bartoníček.(2003).** Anatomy of the tibiofibular syndesmosis and its clinical relevance. *Surgical and Radiologic anatomy*, 25: 379-86.
- **Bianchi S, Delmi M, Molini L. (2010).** Ultrasound of peroneal tendons. *Semin Musculoskeletal Radiol.*, 14: 292–306.
- **Bianchi S, Martinoli C.(2007).** Ankle. In: S. Bianchi & C. Martinoli. *Ultrasound of musculoskeletal system*. Berlin: Springer, 773-835.
- **Campbell SE.(2006).** MRI of Sports Injuries of the Ankle. *Clin Sports Med*, 25: 727–762.
- **Causeret A, Ract I, Jouan J, Dreano T, Ropars M, Guillin R. (2018).** Review of main anatomical and sonographic features of subcutaneous nerve injuries related to orthopedic surgery. *Skeletal Radiol.*, 47: 1051–1068
- **Cheng Y, Cai Y, Wang Y.(2014).** Value of ultrasonography for detecting chronic injury of the lateral ligaments of the ankle joint compared with ultrasonography findings. *British Journal of Radiology*, 87: 1-6.
- **Choufani E, Gavanier B, Gross J. (2016).** Tarsal tunnel syndrome: Does etiology matter?. *Médecine et chirurgie du pied*, 32: 72-76.
- **Delzell PB, Tritle BA, Bullen JA, Chiunda S, Forney MC. (2017).** Clinical Utility of High-Frequency Musculoskeletal Ultrasonography in Foot and Ankle Pathology: How Ultrasound Imaging



Influences Diagnosis and Management. The Journal of foot and ankle surgery, 56: 735-739.

- **El-Liethy N, Kamal H. (2016).** High-resolution ultrasonography and magnetic resonance imaging in the evaluation of tendino-ligamentous injuries around ankle joint. The Egyptian Journal of Radiology and Nuclear Medicine, 47(II), 543-555.
- **Fessel D, Vanderschueren GM, Jacobson JA.(1998).** Ankle ultrasound: technique, anatomy, and diagnosis of pathologic conditions. Radiographics, 18: 325–332.
- **Hartgerink P, Fessel DP, Jacobson JA, et al., (2001).** Full- versus partial-thickness Achilles tendon tears: sonographic accuracy and characterization in 26 cases with surgical correlation. Radiology, 220: 406–412.
- **Knapp RG, Miller MC. (1992).** Biology statistics. In: R. G. Knapp & M. C. Miller. Clinical epidemiology and biostatistics 3rd ed. Maryland: Williams & Wilkins, 255–274.
- **Lento PH, Primack S.(2008).** Advances and utility of diagnostic US in musculoskeletal medicine. Curr Rev Musculoskeletal Med, 1(1): 24–31.
- **Liffen N. (2014).** Achilles tendon diagnostic ultrasound examination: A locally designed protocol and audit. International Musculoskeletal Medicine, 36: 1-12.
- **Margetic P, Salaj M, Lubina IZ.(2009).** The Value of Ultrasound in Acute Ankle Injury: Comparison With MR. Eur J Trauma Emerg Surg, 35: 141–146.
- **Martinoli C. (2010).** Musculoskeletal ultrasound: technical guidelines. Insights Imaging, 1(3):99-141
- **Rogers CJ, Cianca J.(2010).** Musculoskeletal ultrasound of the ankle and foot. Phys Med Rehabil Clin N Am, 21: 549–557.
- **Sconfienza LM, Orlandi D, Lacelli F, Serafini G, Silvestri E. (2015).** Dynamic High-Resolution US of Ankle and Midfoot Ligaments: Normal Anatomic Structure and Imaging Technique. Radiographics, 35: 164-178.
- **Shalaby MH, Sharara SM, Abdelbary HM.(2016).** High-resolution ultrasonography in ankle joint pain: Where does it stand?. The Egyptian Journal of Radiology and Nuclear Medicine, 48: 645 - 652.
- **Teefey SA, Rubin DA, Middleton WD, et al.(2004).** Detection and quantification of rotator cuff tears: a comparison of ultrasound, MRI, and arthroscopic findings in seventy-one consecutive cases. J Bone Joint Surg Am, 86: 708– 16.
- **Van Rijn RM, van Os AG, Bernsen R, Luijsterburg PA, Koes W, Bierma-Zeinstra SM. (2008).** What is the clinical course of acute ankle sprains? A systematic literature review. Am J Med, 121: 324–31.