



**ORIGINAL ARTICLE**

## Bivalent Human Papilloma Virus Vaccine (Cervarix) in the Treatment of Cutaneous Warts

Samia Ali Ibrahim<sup>1</sup>, Shima Maher Hamed Ahmed<sup>1\*</sup>, Howyda Mohamed Ebrahim<sup>1\*</sup>, Hala Mohamed Morsy<sup>1\*</sup>

<sup>1</sup>Dermatology Department, Faculty of Medicine, Zagazig University, Zagazig, Egypt

**Corresponding author:**

Shima Maher Hamed Ahmed

**Email :**

[shimaanegm19@gmail.com](mailto:shimaanegm19@gmail.com)

Submit Date 2021-08-20

Revise Date 2021-09-14

Accept Date 2021-09-22



**ABSTRACT**

**Background:** Bivalent human papilloma virus (HPV) vaccine has a successful effect in therapy of recalcitrant cutaneous warts. The purpose of this study was to assess the efficacy and safety of intralesional (IL) injection of bivalent HPV vaccine (cervarix) versus IL saline in therapy of recalcitrant cutaneous warts.

**Methods:** Forty-four patients with resistant warts to therapy were classified into 2 groups; 22 patients in each group. Group A was received Cervarix vaccine 0.1ml into the biggest wart 2-weeks apart and group B (control) was received IL saline. The patients in both groups received sessions until the patients achieved complete clearance or for a five sessions.

**Results:** One month after the treatment, 86.4% of patients achieved complete response in group A (IL cervarix vaccine) versus to 4.2 % of the control (group B) with a highly significant difference ( $P < 0.0001$ ). No recurrence was reported in patients with complete response. The side effects were mild tolerated pain during the injection.

**Conclusion:** IL cervarix vaccine can be used as a safe treatment modality for the therapy of resistant warts.

**Keywords:** Cervarix (Bivalent) HPV vaccine, Intralesional therapy, Recalcitrant cutaneous warts.

### INTRODUCTION

Viral warts are one of the commonest dermatologic diseases. Warts affect about 3.5 % of adults and 33 % of children. Warts are hyperkeratotic benign papillomas results from infection of the skin with human papilloma virus (HPV) [1,2]. Therapy of warts is representing a great therapeutic difficulty particularly in recalcitrant types. There is no specific definition for recalcitrance of warts but are those which persist or recurrent following several months of 2 or more standard treatments [2-5]. Intralesional immunotherapy can help the immune system to know specific viral or fungal antigens and is consider an option for multiple recalcitrant warts [3,4]. T cell mediated immune responses play an essential role in clearance of HPV

infection. Hence, in the immunosuppressed patients warts are increase with time and difficult to treat. It was reported that the host T cell immune responses are needed to eradicate HPV infection [5-7]. The currently available HPV vaccines are differing in the number of HPV genotypes they contain. The bivalent vaccine (Cervarix) contains virus-like-particles (VLPs) of HPV types 16 and 18. Cervarix has been used for immunization against HPV types 16 and 18 and also in prevention of cervical cancer. It was reported that bivalent HPV vaccine (cervarix) has been successfully used in therapy of recalcitrant warts [7,8]. The aim of this study is to evaluate the efficacy and safety of intralesional (IL) injection of HPV vaccine (cervarix) in the therapy of

recalcitrant cutaneous warts versus IL saline as a control group.

**METHODS**

A randomized and controlled study was performed at the Zagazig University Hospitals, Dermatology, Venereology and Andrology department from September 2019 to October 2020. Written informed consent was obtained from all participants, the study was approved by the research ethical committee of Faculty of Medicine, Zagazig University(number of #5590).The study was performed according to Helsinki declaration of human studies after taking A written consent from all patients. This study included patients (both males and females, with ranged from 18-53years) with recalcitrant cutaneous warts (warts of duration more than two years and not respond to two or more therapeutic modalities) at any sites, sizes and have or haven't distant warts. Diabetic or immunosuppressed patients, Pregnancy or lactation, skin infections, chronic illness, taking any treatment or vaccinations for warts during the last month before inclusion in the study were excluded.

**Procedure:**

Complete history taking, also the history of systemic diseases and any previous treatment. General and dermatological examination. Patients were classified into two groups:

**Group A:** twenty-two patients who were directly injected with 0.1 up to 0.3ml of IL Bivalent HPV (Cervarix) vaccine (GlaxoSmithKline (GSK), Cairo, Egypt) into the biggest wart 2-weeks apart until the patients achieved complete clearance or for a 5 sessions.

**Group B:** twenty-two patients treated with IL saline into the biggest wart.

The clinical response was assessed by a decrease in wart size and or number and was divided into: complete response means complete warts disappearance, Partial; means the warts have

decreased in size or number (by 55–99%) while no response; decrease in wart size or number was less than fifty percent (9). Photos were taken at the start of the study, before each visit, the end of treatment and one month after the last session.

- The side effects were also reported after each session. A pain scale was used to assess the pain during injection as( mild, moderate or severe). Follow-up was done for 6 months.

**Statistical Analysis**

The data were analyzed using SPSS program version 18.0. Chi square test was used and P-values of <0.05 refers to significance of the results.

**RESULTS**

There were no statistical significance differences between both groups in age, sex type of warts or previous therapy (Table 1). Statistically significant differences was found between groupA and control in number or size of warts after the treatment (P <0.0001) (Table 2). One month after the treatment, complete response occurred in 19/22 patients (86.4%), partial response (4.5%) in 1 patient and no response (9.2%) in 2 patients. The control group (IL saline) showed partial response in 2 (4.2%) patients (P <0.0001) (Table 3) (Figure1 and 2). According to size of warts there was a statistical highly significant decrease in the size of warts in group A before ( $\leq 0.5$  mm in 45.5% &  $> 0.5$ mm in 55.5%) and after treatment (0 in 86.4 %) compared to the control group (P <0.0001). There was no relation between the clinical response and other clinical parameters as age, sex, type and duration of warts.

**Side effects**

Regarding the side effects, 81.4% patients compared to 68.2% of the controls reported mild tolerable pain during the injection in the controls whole in group A, pain was of moderate type. 9.1% of group A suffered from pain and edema which was resolved in 1 hour without any treatment.

**Table (1):** Baseline characteristic of the studied groups

Variable		Group I (Intralesional) (n=22)	Group II (Intralesional saline) (n=22)	t	P
Age: (years)	Mean ± SD	30.91 ± 8.92	30.55 ± 8.29	0.14	0.89
	Range	20 - 53	18 - 47		
Duration: (months)	Mean ± SD	31.32 ± 5.59	32.23 ± 6.5	0.50	0.62
	Range	25 - 48	25 - 48		

Variable		No	%	No	%	$\chi^2$	P
Sex:	Female	13	59.1	11	50	0.38	0.55 NS
	Male	9	40.9	11	50		
Type:	Palmer	4	18.2	7	31.8	5.38	0.37 NS
	Plain	0	0	1	4.5		
	Planter	6	27.3	8	36.3		
	Common	8	36.4	3	13.6		
	Filiform	1	4.5	0	0		
	Mixed	3	13.6	3	13.6		
Previous therapy:	Cryo & surgery	4	18.2	4	18.2	5.85	0.56 NS
	Cryo & immune	3	13.6	5	22.7		
	Cryo & keratolytics	9	40.9	8	36.3		
	Cryo & electro	1	4.5	0	0		
	Surgery & electro	1	4.5	0	0		
	Surgery & keratolytic	1	4.5	0	0		
	electro & keratolytic	2	9.1	5	22.7		
	Immuno & systemic	1	4.5	0	0		

SD: Stander deviation, t: Independent t test,  $\chi^2$ : Chai square test. NS: Non significant (P>0.05)

**Table (2):** Number & size of warts before and after ttt among the studied groups

Variable		Group I (Intralesional) (n=22)		Group II (intralesional saline) (n=22)		MW	P
Number before:	Mean ± SD	5.91 ± 2.47		5.45 ± 2.35		0.64	0.52 NS
	Median	5.5		5			
	Range	3 - 11		3 - 10			
Number after:	Mean ± SD	0.59 ± 1.65		5.45 ± 2.35		0.80	0.0001**
	Median	0		5			
	Range	0 - 6		3 - 10			
P#		<0.001**		<0.001**			
Variable		No	%	No	%	$\chi^2$	p
Size: before	≤ 0.5 mm	10	45.5	11	50	0.09	0.76 NS
	> 0.5 mm	12	54.5	11	50		
Size after:	0	19	86.4	0	0	2.11	0.0001**
	≤ 0.5 mm	0	0	0	0		
	> 0.5 mm	3	13.6	2	9.1		
P!		<0.001**					

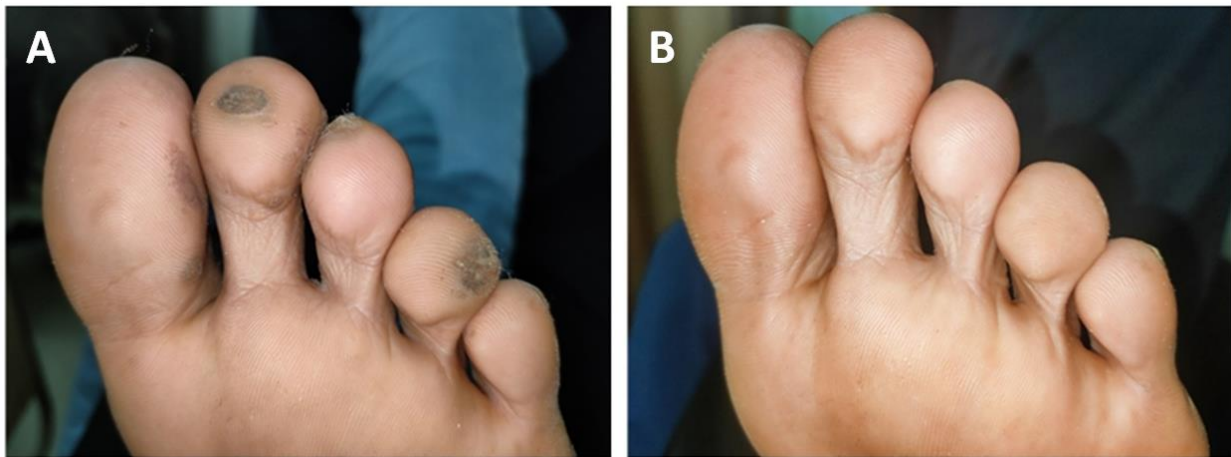
SD: Stander deviation, MW: Mann Whitney test,  $\chi^2$ : Chai square test. NS: Non significant (P>0.05) \*\*: Highly Significant (P<0.01)

**Table 3:** Therapeutic response among the studied patients

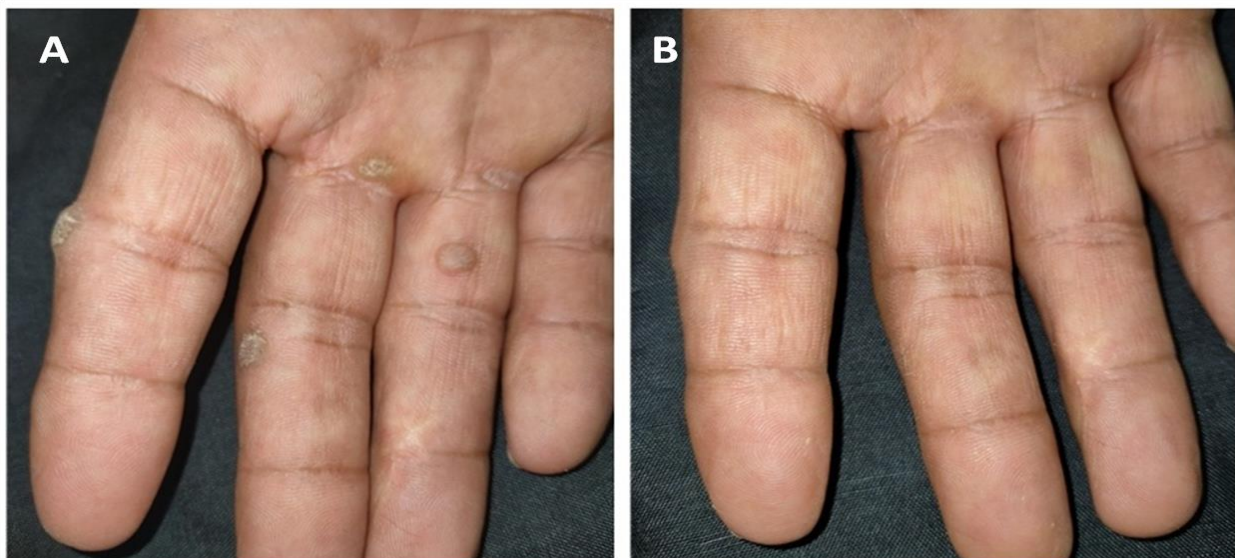
Variable		Group A (Intralesional) (n=22)		Group B ( control ) (n=22)		$\chi^2$	P
		No	%	No	%		
Response:	No	2	9.1	20	90.9	0.78	P < 0.0001**
	Partial	1	4.5	1	4.5		
	Complete	19	86.4	1	4.2		

Variable		Group A (Intralesional) (n=22)		Group B ( control ) (n=22)		$\chi^2$	P
		No	%	No	%		
Side effect:	No	0	0	7	31.8	1.06	0.30
	Pain	18	81.8	15	68.2		
	Pain &Edema	4	9.1	0			
Pain score:	Mean $\pm$ SD Range	6.09 $\pm$ 1.19 4 - 8		1.27 $\pm$ 0.42 1 - 5		17.9	P <0.0001**
Recurrence		(n=19)					
	No N(%) Yes N(%)	19 0	(100%) (0%)				

SD: Stander deviation, t: Independent t test,  $\chi^2$ : Chai square test. NS: Non significant (P>0.05) \*\*: Highly significant (P<0.01)



**Figure 1:** Plantar warts on the right foot, (A) before. (B) After therapy with II cervarix vaccine showing complete improvement after 5 sessions.



**Figure 2:** Palmar warts on the right hand, (A) before. (B) After therapy with II cervarix vaccine showing complete improvement after 4 sessions.

## DISCUSSION

Our results showed a remarkable improvement of recalcitrant cutaneous warts in group A (IL cervarix vaccine); 86.4% achieved complete response versus to 4.2 % of the control with highly significant difference ( $P < 0.0001$ ). Cervarix is a bivalent HPV vaccine. The vaccine contains (VLPs) of types 16 and 18 of HPV. The vaccine formed of L1 proteins which is the antigen specific for each type of HPV. The mechanisms of action of HPV vaccines are depend on (VLPs) which are not infectious since they didn't contain the viral DNA. So, they are similar to the natural virus and hence stimulate antibodies formation to both the VLPs and natural virus. The aim was to assess the efficacy and tolerability of IL cervarix versus IL injection of saline as a control group in the therapy of resistant cutaneous warts. HPV vaccine has been used to protect against specific types of HPV that may lead to genital warts or cancer [10-12]. The outcome of this study in group A are slightly better than a study used IL Cervarix vaccine in treatment of 22 patients with common warts versus another group that were injected by intramuscular injection (IM). Their IL groups showed complete response in 18 patients (82%) versus to (86.4%) in our study. This slight difference in the outcome may be due to that our study included different types of cutaneous warts not only common warts as their study and also the difference in the number of sessions [8]. Other study successfully used another HPV vaccine; quadrivalent HPV(QHPV) in therapy of resistant cutaneous warts in an adult patient[12]. Similarly, complete eradication of warts was reported in a six children after the IM injection of QHPV vaccine. Martin et al. study revealed complete resolution of HPV infection after IM injection of HPV vaccines. Five patients (four of them received cervarix vaccine, and one treated with Q HPV vaccine)[13]. On the other hand, complete clearance in this study (86.4%, IL group) was better than a study used QHPV vaccine in thirty patients with recalcitrant cutaneous warts in which complete resolution occurred in (46.67%) of their patients [14]. The superior results and absence of recurrence in our study may be belonged to the efficacy of Cervarix which possess higher immunogenicity in comparison to Q HPV vaccine [14]. Ayman et al. divided 40 patients with recalcitrant warts into 2 groups; group I received IL Candida antigen (CA) and group II received both of IL cervarix vaccine and CA. (40%) of the patients in first group achieved complete clearance of warts versus to (70%) in the second group. They concluded

that the combination of cervarix and candidal antigen is effective in recalcitrant warts [15]. Comparing the IL bivalent vaccine versus other IL immunotherapy we found that cervarix had significantly a better response; previous study utilized IL injection of (Measles, Mumps and Rubella) MMR vaccine for treatment of twenty- two patients suffered from warts. Complete remission occurred in (60%) of the patients versus to (86.4%) in our study [16,17]. Our result is better than study used IL purified protein derivative (PPD) for the therapy of 52 patients. Complete remission occurred in (78.8%) patients versus (86.4%) of this study [18]. The side effects in our study were few; pain was noticed during the procedure which was mild in the saline injection group and moderate in the group B which was resolved without any treatment. 81.4% of the patients in group A reported moderate pain compared to 68.2% of the controls (group A) reported mild tolerable pain during the injection. Pain was with edema was reported in 9.1% of group A which was resolved in 1 hour without any treatment. Also, Nofal et al. reported that all patients of the IL group showed mild pain at the site of injection and in addition to itching localized in the injected warts occurred in most of their patients (90.9%). Other studies reported no or few side effects after Cervarix or Gardasil vaccine injection for the therapy of various warts' type [19,20]. In our study, no recurrence was reported. Absence of recurrence represents the effectiveness of Cervarix over other treatment modalities in the therapy of warts, particularly the resistant ones. We recommend a wide spread use of IL cervarix vaccine in the therapy of various warts' type. Further prospective controlled studies on larger population and in comparison with other traditional therapeutic modalities are also recommended.

## Conclusion

IL Cervarix vaccine is an effective and safe treatment for the multiple, resistant cutaneous warts.

## REFERENCES

1. DevendraJ. Cutaneous Warts and its Treatment: A Literature Review IJSR 2015; 4(9):87-89.
2. Boull C, Groth D. Update treatment of cutaneous viral warts in children. *Pediatr Dermatol* 2011; 28(3): 217-229.
3. Lynch MD, Cliffe J, Morris-Jones R. Management of cutaneous viral warts. *BMJ*2014; 348: 3339.

4. El-Khalawany M, Shaaban D, Aboeldahab S. Immunotherapy of viral warts: myth and reality. *ESDV* 2015; 35(1): 1-13.
5. Stanley M. Immunobiology of HPV and HPV vaccines. *Gynecol Oncol* 2008; 109(2): S15-S21.
6. Ashrafi GH, Salman NA. Pathogenesis of human papillomavirus – immunological responses to HPV infection. *Intech Open* 2016; 243-253.
7. Black AP, Ardern-Jones MR, Kasprowicz V, Paul B, Louise J, et al. Human keratinocyte induction of rapid effector function in antigen-specific memory CD4+ and CD8+ T cells. *Eur J Immunol* 2007; 37(6): 1485-1493.
8. Ahmad N, Ayman M, Al-Shimaa M I, Eman N, Manal N. Intralesional versus intramuscular bivalent human papillomavirus vaccine in the treatment of recalcitrant common warts. *J Am Acad Dermatol.* 2020;82(1):94-100. DOI: 10.1016/j.jaad.2019.07.070.
9. Gamil HD, Nasr MM, Khattab FM and Ibrahim AM. Combined therapy of plantar warts with topical bleomycin and microneedling: a comparative controlled study. *J Dermatolog Treat* 2019; 1-6.
10. D'Addario M, Redmond S, Scott P, Egli-Gany D, Riveros B, Ana Maria HR et al. Two dose schedules for human papillomavirus vaccine: Systematic review and meta-analysis. *Vaccine* 2017; 35(22):2892-2901.
11. Dobson SR, McNeil S, Dionne M, Dawar M, Ogilvie G, Kraiden M, et al. Immunogenicity of 2 doses of HPV vaccine in younger adolescents vs 3 doses in young women: a randomized clinical trial. *JAMA* 2013; 309(17): 1793-1802.
12. Donegan K, Beau-Lejdstrom R, King B, Suzie S, Andrew T, Philip B. Bivalent human papillomavirus vaccine and the risk of fatigue syndromes in girls in the UK. *Vaccine* 2013; 31: 4961-4967.
13. Venugopal SS, Murrell DF. Recalcitrant cutaneous warts treated with recombinant quadrivalent human papillomavirus vaccine (types 6, 11, 16, and 18) in a developmentally delayed, 31-year-old white man. *Arch J Dermatol* 2010; 146(5): 475-477.
14. Ayman Marei, Ahmad Nofal, Rania Alakad and Amina Abdel-Hady. Combined bivalent human papillomavirus vaccine and Candida antigen versus Candida antigen alone in the treatment of recalcitrant warts. *J Cosmet Dermatol* 2019; 00:1–5. DOI: 10.1111/jocd.13077.
15. Fania ZM, Esther RC, Mauricio TP, Paula AB, Susana BC, María EHR et al. Intralesional Candida Antigen Immunotherapy for the Treatment of Recalcitrant and Multiple Warts in Children. *Pediatr Dermatol* 2015; 32 (6): 797–801.
16. Rahul NJ, Anil PG, Ravindranath BC, Ashok KK, Sharad M. Effect of intralesional measles mumps rubella immunotherapy in cutaneous viral warts. *Int J Res Dermatol* 2019; 6(3): 347-351.
17. Choudhary D, Piya S. Treatment of warts by immunotherapy using purified protein. *Birat J Health Sci* 2018; 3(6): 463-467.
18. Yang MY, Son JH, Kim GW, Hoon-SK, Hyun CH, Moon BK et al. Quadrivalent human papillomas virus vaccine for the treatment of multiple warts: a retrospective analysis of 30 patients. *J Dermatol Treat* 2018; 23: 1-5.
19. Abeck D, Fölster H R. Quadrivalent human papillomavirus vaccination: A promising treatment for recalcitrant cutaneous warts in children. *Acta Dermato Venereologica* 2015; 95(8): 1017– 1019.

## TO Cite :

Ibrahim, S., Hamed, S., Ibrahim, H., Morsi, H. Bivalent Human Papilloma Virus Vaccine (Cervarix) in the treatment of cutaneous warts. *Zagazig University Medical Journal*, 2024; (570-575): -. doi: 10.21608/zumj.2021.91611.2321