

# KIRSCHNER WIRES VERSUS HERBERT SCREW FIXATION WITH BONE GRAFT IN CASE OF NONUNITED SCAPHOID WAIST FRACTURE

By

**Ammar Ahmed, Ahmed Badawy and Galal Hegazy**

Department of Orthopedic Surgery, Faculty of Medicine, Al-Azhar University

**Corresponding Author:** Ammar Ahmed,

**E-mail:** [ammar\\_ahmed993@gmail.com](mailto:ammar_ahmed993@gmail.com)

## ABSTRACT

**Background:** Scaphoid nonunion is challenging to manage because of the geometry of the scaphoid, the direction and type of fracture, and the vascular pattern of the blood supply to the scaphoid. Fracture proximal to the perforating vessels on the dorso-radial surface of the scaphoid can cause significant bone ischemia of the proximal pole.

**Objective:** To compare the impact of the Kirschner wires versus Herbert screw fixation with iliac bone graft on the rate of union, time to union, correction of deformity, and clinical outcome in adults with nonunited scaphoid waist fracture without avascular necrosis.

**Patients and Methods:** We prospectively randomized 40 patients to undergo corticocancellous iliac bone grafting and internal fixation either with multiple Kirschner wires or Herbert screw. This study was conducted in the Department of Orthopedic surgery at Al-Hussien University Hospital, Faculty of Medicine, Al-Azhar University during the period from February 2018 to April 2020. Radiographs, clinical outcome measures (pain, range of motion, and grip strength) were done pre- and post-operatively.

**Results:** No significant difference detected between the two groups with respect to the time to union, rate of union, deformity correction, pain analysis, range of motion, grip strength, and complications.

**Conclusion:** Combination of impaction of iliac bone graft, and internal fixation with k-wire or Herbert's screw provided a good option for treatment of scaphoid nonunion. However, because of kirschner wires has a shorter operative time, lower cost and easy application as compared with the Herbert screw, so k wire may be a good alternative to Herbert screw.

**Keywords:** Scaphoid, Nonunion, Scaphoid nonunion, DISI, Herbert screw, Kirschner wire, Scaphoid waist fracture

## INTRODUCTION

The scaphoid is the most commonly fractured carpal bone and account for 60% of all carpal fractures (*Kawamura and Chung, 2010*). Approximately about 10% of displaced scaphoid fractures fail to unite despite appropriate immobilization (*Patrick, 2010*).

The natural history of the untreated scaphoid waist fracture nonunion often involves apex dorsal angulation with bone loss and collapse (hump- back or flexion) deformity (*Hernández-Ramajo et al., 2014*).

The conventional treatment of scaphoid waist fracture nonunion with humpback deformity typically involves

the use of bone graft and internal fixation. The goal of surgery is first adequately to reduce the scaphoid, thereby restoring the carpal height and alignment. *Fernandez (2010)* described a method of fixation using a volar wedge bone graft secured with Kirschner wires. However, *Herbert and Fisher (2010)* described the use of Herbert screw fixation.

**The aim of the present study was to** compare the impact of the Kirschner wires versus Herbert screw fixation with iliac bone graft on the rate of union, time to union, correction of deformity, and clinical outcome in adults with nonunited scaphoid waist fracture without avascular necrosis.

## MATERIALS AND METHODS

This study was conducted at the Department of Orthopedic Surgery in Al-Hussien University Hospital, Faculty of Medicine, Al-Azhar University during the period from February 2018 to April 2020. IRB approval was obtained from the ethical committees of the Faculty of Medicine, Al-Azhar University. At the time of the enrolment, a written informed consent was obtained from the participants with consideration to declaration of Helsinki. The inclusion criteria were patients between the ages of 18 and 60 years with non-united scaphoid waist fractures that had not healed six months after the initial injury.

**The exclusion criteria** were bilateral scaphoid fractures, history of open fractures, trans-scaphoid perilunate or lunate dislocations, associated fractures in the hand or upper extremities, previous surgical treatment, stage II or higher scaphoid nonunion advanced collapse

(SNAC), and scaphoid non-unions with avascular necrosis (AVN). Seventy-five patients with scaphoid waist fracture nonunion were evaluated to participate in the study.

Diagnosis of the scaphoid waist fracture non-unions was based on the posteroanterior and lateral radiographs of the wrist, CT scan of the wrist along the longitudinal axis of the scaphoid, and MRI of the wrist to exclude AVN. Patients who did not meet the entry criteria were 28 patients (seven patients were less than 16 years old, five presented less than six months after the initial injury, five had trans-scaphoid perilunate dislocation, four had proximal pole nonunion with AVN, four had stage II SNAC, and three had stage III SNAC wrist). Forty four patients with scaphoid waist fracture nonunion were divided into 2 equal groups: Group received Kirschner wires fixation (K-wire group), and group received Herbert screw fixation (Herbert group). Two patients discontinued the intervention and two were lost to follow up after four weeks. Finally, 40 patients (K-wire group [n = 20] and Herbert group [n = 20) were analyzed. The standard posteroanterior and lateral radiographic views evaluated both pre-and post-operative scapholunate angle, radiolunate angle and the lateral intrascaphoid angle was measured pre- and post- operatively on the sagittal CT scan of the wrist along the longitudinal axis of the scaphoid (De Carli et al., 2017).

### Statistical analysis:

Data were collected, revised, coded and entered to the Statistical Package for the Social Science (IBM SPSS) version 20. The quantitative data were presented

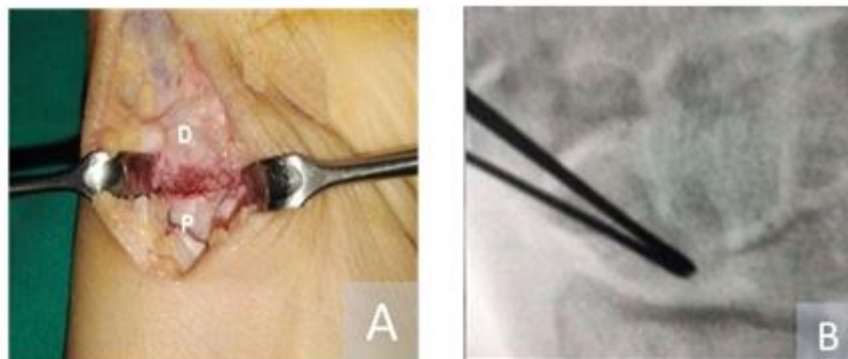
as mean, standard deviations and ranges. Also qualitative variables were presented as number and percentages. Chi-square test was done for comparison between groups regarding qualitative data. Independent t-test was done for comparison between two independent groups with quantitative data and parametric distribution. The confidence interval was set to 95% and the margin of error accepted was set to 5%. So, the p-value < 0.05 was considered significant. Radio lunate angle was tested using Mann-Whitney U test.

### Surgical technique:

With supine position and supinated forearm Surgery was performed under general anesthesia with upper arm tourniquet control inflated only to 150 mm Hg above systolic blood pressure. FCR tendon and tuberosity of the scaphoid was palpated and the scaphoid approached through a 4-cm longitudinal volar incision centered over the tuberosity of the scaphoid lateral to the flexor carpi radialis (FCR) tendon. The bed of the FCR was incised in line with the skin incision, and the radioscapocapitate ligament was incised longitudinally to expose the

fracture. The scaphoid was inspected, and the fibrous tissue and sclerotic bone resected up to the normal looking bone. Curettage of each scaphoid pole was essential to expose the healthy bleeding cancellous bone and prepare an adequate cavity to accept the graft (Fig.1). The scaphoid reduced, and its length restored by introducing a lamina spreader in the gap. Acortiocancellous wedge graft was harvested from the ipsilateral iliac crest and packed into the prepared cavity. Satisfactory scaphoid and lunate alignment confirmed by a C-arm image intensifier. In patients randomized for K-wires fixation, the scaphoid was fixed with 0.045-in K-wires under image intensify guidance in a retrograde manner with convergent K-wire placement (**Figure 1**).

In patients randomized for Herbert screw fixation, the scaphoid was fixed with Herbert bone screw 3 mm in a retrograde manner. The final screw position was checked and confirmed with the use of an image intensifier. Finally, the capsule and radioscapocapitate ligament were repaired and the skin was sutured.



**Figure (1):** Generous curettage of each scaphoid pole to prepare an adequate cavity to accept the graft. P proximal pole and D distal pole. **A**, Fluoroscopic PA view of the wrist shows the K-wires inserted in a convergent direction. **B**.

**Follow up:**

Postoperative X-rays were examined for fracture reduction and K-wire as well as Herbert screw position. Four radiographic views of the wrist (standard PA, lateral, 45° pronation oblique, and PA with ulnar deviation) were obtained at two week intervals to detect union or complications such as arthritis, nonunion or carpal malalignment. The skin sutures were removed two weeks after surgery, and a short arm thumb spica cast had to be worn for an additional six weeks and then a short arm removable splint until the radiographic union. In the K-wire group, the wires were removed after radiographic union. Patients commenced hand physiotherapy sessions under the

supervision of a specialized hand physiotherapist with gentle hand and wrist exercises followed by aggressive wrist exercises, and heavy activities were allowed after scaphoid union. Gradual return to an office job was allowed within the confines of the cast but manual work was allowed after scaphoid union and within the limits of pain. Full return to work and recreational activities were allowed after union and pain relief. The time of immobilization of both groups, the date of bony union, the rate of union and the complications were recorded. Serial clinical examination till time of union and at the last follow up for evaluation of the functional outcome using Mayo modified wrist score (**Megerle et al., 2012**).

## RESULTS

No differences were found between the K-wire group and Herbert group with respect to age, sex, hand dominance, side

of injury, mechanism of injury, occupation, fracture classification (**Table 1**).

**Table (1): Data distribution**

Parameters	Herbert screw Group (No.=20)		K-wire wires Group (No.=20)		P value
	Mean	SD	Mean	SD	
Age	26.35	3.558	30.40	6.676	0.022
Range	25 – 27		29 - 33		
<b>Gender</b>					>0.05
M/F	15/5		17/3		
<b>Habits</b>					>0.05
Smoking/No smoking	10 / 10		14 / 6		
<b>Side</b>					>0.05
Rt	14 / 20		12 / 20		
Lt	6 / 20		8 / 20		
	<b>N</b>	<b>%</b>	<b>N</b>	<b>%</b>	
<b>Non-union type</b>					>0.05
Type D2	14	70%	16	80%	
Type D3	6	30%	4	20%	
<b>Mode of trauma</b>					>0.05
FOOSH	15	75%	12	60%	
Athletic activity	5	25%	6	30%	
motorcycle accident	0	0%	2	10%	
<b>Occupation</b>					>0.05
Skilled	12	60%	11	55%	
Heavy manual	3	15%	2	10%	
Light manual	5	25%	7	35%	
<b>Previous treatment</b>					>0.05
Plaster of Paris	15	75%	17	85%	
Physiotherapy	5	25%	3	15%	

Both groups were similar in terms of pre-operative clinical and radiographic parameters. No statistically significant differences were found between the two groups regarding the post-operative

clinical and radiographic outcomes. There was significant improvement in the clinical and radiographic outcome measures pre- to post-operative for both groups (**Tables 2, 3**).

**Table (2): The results of preoperative and postoperative outcome according to Mayo score**

Score		Groups		Herbert screw Group		Kirschner wires Group		P value
		Fair	Bad	N	%	N	%	
Preoperative	Fair	7	35%	8	40%	>0.05		
	Bad	13	65%	12	60%			
Postoperative	Excellent	9	45%	13	65%			
	Good	7	35%	4	20%			
	Fair	2	10%	2	10%			
	Poor	2	10%	1	5%			

**Table (3): Comparisons between Preoperative and postoperative radiographic**

Parameters	Preoperative			Postoperative			P value
	Mean	SD	Range	Mean	SD	Range	
<b>Herbert</b>							
Scapholunate angle	80°	5.426	66°-87°	52°	7.412	41°-59°	<0.001
Radiolunate angle	29°	7.883	22°-28°	10°	1.680	8°-14°	<0.001
Carpal height index	0.441	0.024	0.48-0.58	0.482	0.0163	0.46-0.53	<0.001
Lateral intrascaphoid angle	67°	4.864	60°-74°	36°	5.832	34°-47°	<0.001
<b>K-wire</b>							
Scapholunate angle	80°	4.732	66°-87°	51°	5.231	42°-60°	<0.001
Radiolunate angle	28°	3.423	22°-30°	13°	2.626	8°-16°	<0.003
Carpal height index	0.441	0.021	0.48-0.58	0.482	0.022	0.46-0.53	<0.041
Lateral intrascaphoid angle	67°	5.432	58°-75°	37°	6.413	32°-48°	<0.001

## DISCUSSION

Combination of impaction of iliac bone graft, and internal fixation with K-wire or Herbert's screw provides a good option for treatment of scaphoid nonunion to achieve bony union, restore scaphoid anatomy, improve wrist function, and prevent arthritis. The common sites of bone graft harvesting for scaphoid nonunion are the distal radius and iliac crest. Iliac crest graft permits greater retrieval of marrow and more osteogenic cells (*Jarrett et al., 2011*). Therefore, iliac crest graft can provide superior osteogenic properties compared with distal radius bone graft. Although several studies (*Kirkham & Millar, 2012* and *Park et al., 2013*) reported earlier union rate in some instance of unstable scaphoid nonunion

with the use of cancellous iliac bone graft. Our preference was to use corticocancellous graft, as this may be more appropriate in the setting of large intercalary defects causing significant carpal collapse. There are three fixation methods used in the treatment of scaphoid fracture nonunion (Kirschner wires, screw, plate) but there is no study in the current literature directly compares these methods. The Herbert screw was significantly stronger in resisting bending forces as compared to paired parallel Kirschner wires but is unable to withstand cyclical multi axis loading or rotation (*Luria et al., 2010*). Our follow-up protocol was to continue immobilization until radiographic union achieved. A meta-analysis reported that bone graft

with screw fixation achieved 94% union, and wedge graft with Kirschner wires achieved 77% union with the average time to union as 20 weeks (*Merrell et al., 2012*).

In our study, the rate of union in case of kirshner wires was 90% versus Herbert screw was 80% and the mean time to union was 14 and 15 weeks respectively. The explanation of this result might relate to the use of Kirschner wires in a convergent direction to fix the scaphoid. This allowed the K-wires to pass through more surface area of the scaphoid and allowed for a more targeted placement into the proximal pole, thus increasing the fracture reduction stability and accelerating the union. *Meisel et al. (2017)* used the same fixation technique and reported 100% union rate with cancellous iliac bone grafting in the treatment of scaphoid nonunion. Moreover, our reported result regarding the union rate was consistent with *Reigstad et al. (2010)*, and found that in the K-wire analysis, there was a higher union rate as compared to the groups fixed with screws. The K-wire group had a higher estimated incidence of union than the screw group (91% versus 88%, respectively), a difference that persisted when used with vascularized grafts (K-wire 94% versus screw 87%).

## CONCLUSION

There were no differences in the impact of one method on the time to union, rate of union, deformity correction, and the clinical outcomes. Herbert screw fixation was technically more demanding in terms of technique than K-wires, and the incidence of technical errors may play an eminent role in the occurrence of

nonunion. However, because of easy application of Kirschner wires, and low cost, especially in developing countries, it may be a good alternative to Herbert screw. The limitation of the study includes its single center nature that limits its external validity.

## REFERENCES

1. **De Carli P, Donndorff AG, Torres MT, Boretto JG and Gallucci GL. (2017):** Combined Tenodesis–Capsulodesis for Scapholunate Instability: Minimum 2-Year Follow-Up. *J Wrist Surg.*, 6(1): 11–21.
2. **Fernandez DL (2010):** A technique for anterior wedge-shaped grafts for scaphoid nonunions with carpal instability. *J Hand Surg Am.*, 9: 733–737.
3. **Herbert TJ and Fisher WE (2010):** Management of the fractured scaphoid using a new bone screw. *J Bone Joint Surg Br.*, 66:114–123.
4. **Hernández-Ramajo R, Martín-Ferrero MA, Simón-Pérez C and Muñoz-Moreno MF. (2014):** Results of surgical treatment of carpal scaphoid pseudoarthrosis using the Fisk-Fernández technique. *Revista Española de Cirugía Ortopédica y Traumatología (English Edition)*, 58(4): 229-236.
5. **Jarrett P, Kinzel V and Stoffel K (2011):** A biomechanical comparison of scaphoid fixation with bone grafting using iliac bone or distal radius bone. *J Hand Surg Am.*, 32:1367–1373.
6. **Kawamura K and Chung KC (2010):** Treatment of scaphoid fractures and nonunions. *J Hand Surg Am.*, 33:988–997.
7. **Kirkham SG and Millar MJ (2012):** Cancellous bone graft and Kirschner wire fixation as a treatment for cavitary-type scaphoid nonunions exhibiting DISI. *Hand*, 7:86–93.
8. **Luria S, Hoch S, Liebergall M, Mosheiff R and Peleg E (2010):** Optimal fixation of acute scaphoid fractures: finite element analysis. *J Hand Surg.*, 35:1246–1250.

9. Megerle K, Keutgen X, Mueller M, Germann G and Sauerbier M. (2012): Treatment of scaphoid non-unions of the proximal third with conventional bone grafting and mini-Herbert screws: an analysis of clinical and radiological results. *Journal of Hand Surgery (European Volume)*, 33(2): 179-185.
10. Meisel E, Seal A, Yao CA, Ghiassi A and Stevanovic M (2017): Management of scaphoid nonunion with iliac crest bone graft and K-wire fixation. *Eur J Orthop Surg Traumatol.*, 27:23–31.
11. Merrell GA, Wolfe SW and Slade JF (2012): Treatment of scaphoid nonunions: quantitative meta-analysis of the literature. *J Hand Surg Am.*, 27:685–691.
12. Park H, Yoon J, Jeon I, Chung H and Kim J (2013): A comparison of the rates of union after cancellous iliac crest bone graft and Kirschner-wire fixation in the treatment of stable and unstable scaphoid nonunion. *Bone Joint J.*, 95:809–814.
13. Patrick CN. (2010): Diagnosis and treatment of scaphoid fractures. *Radiologic Technology*, 82(2): 161-178.
14. Reigstad O, Thorkildsen R, Grimsgaard C, Reigstad A and Rokkum M (2010): Healing of ununited scaphoid fractures by Kirschner wires and autologous structural bone grafts. *Scand J Plast Reconstr Surg Hand Surg.*, 44:106 – 111.



## مقارنة بين تثبيت كسر وسط العظمة الزورقية غير الملتئم بواسطة أسلاك معدنية أو مسمار هربرت ورقعة عظمية

عمار أحمد، أحمد بدوي، جلال حجازي

قسم جراحة العظام، كلية الطب، جامعة الأزهر

**خلفية البحث:** عدم التئام العظمة الزورقية يمثل تحديًا في التعامل معه نظرًا لهندسة العظمة، واتجاه ونوع الكسر، ونمط الأوعية الدموية لإمداد الدم إلى القطب القريب. يمكن أن يسبب الكسر القريب للأوعية المثقبة الموجودة على السطح الظهري الشعيري للسطح الخلفي نقص كبير في عظم القطب القريب. لا يزال علاج عدم التئام العظمة الزورقية يشكل تحديًا كبيرًا لكل جراحى العظام، خاصةً عندما يكون مرتبطًا بضعف الأوعية الدموية للقطب القريب.

**الهدف من البحث:** مقارنة استخدام مسمار هيربرت مقابل أسلاك كيرشمر في علاج عدم التئام وسط العظمة الزورقية.

**المرضى وطرق البحث:** هذه دراسة مستقبلية تقارن استخدام مسمار هربرت مقابل أسلاك كيرشمر في علاج المرضى الذين يعانون من كسر وسط العظمة الزورقية غير المتلتئمة باستخدام الرقعة العظمية من عظام الحرقفة. وقد تمت المعالجة في قسم جراحة العظام في الفترة من فبراير 2018 حتى أبريل 2020 في مستشفى الحسين الجامعي.

**نتائج البحث:** لا توجد فروق ذات دلالة إحصائية في نتائج المرضى الذين خضعوا لأسلاك كيرشمر والذين خضعوا للتثبيت بواسطة مسمار هربرت كطريقة للتثبيت الداخلي فيما يتعلق بوقت الالتئام ومعدل الالتئام وتصحيح اعوجاج العظمة الزورقية، وتقليل الألم، والتحسين في مدى الحركة وقوة القبضة كما أنه لا توجد فروق ذات دلالة إحصائية في

المضاعفات ومعدلات تدرّج مايو لقياس نتائج المرضى بعد إجراء الجراحة.

**الاستنتاج:** الجمع بين الرقعة العظمية من عظم الحرقفه، والتثبيت الداخلي مع أسلاك كيرشندر، ومسمار هربرت يوفر خيارًا جيدًا لعلاج عدم التئام وسط العظمة الزورقية. ومع ذلك، نظرًا لأن أسلاك كيرشندر ذات تكلفة أقل وسهولة في الاستخدام واقصر وقتًا في إجراء التثبيت الداخلي مقارنة بمسمار هربرت، لذلك قد يكون سالك كيرشندر بديلًا جيدًا لمسمار هربرت.

**الكلمات الدالة:** سكاويد، عدم التئام العظمة الزورقية، مسمار هربرت، سالك كيرشندر، كسر وسط العظمة الزورقية.