



Ameliorative Effect of Zinc Oxide Nanoparticles and vitamin E on some Biochemical and Histological changes in Irradiated Albino Rats



Hanan A. Abd Elmonem[#], Amal H. Mahmoud, Manal M. Abbas

Biological Applications Department, Nuclear Research Center, Atomic Energy Authority, Cairo, Box 13759, Egypt.

THE CURRENT study was conducted to investigate the possible ameliorative effect of zinc oxide nanoparticles (ZnO-NPs) separately or in combination with Vitamin E on γ -radiation induced-oxidative stress in rats. Thirty-two Albino Rats were equally divided into four groups. Group (1) rats were injected with the saline (i.p). Group (2) rats were exposed to a single total body γ -radiation dose of (6Gy), Group (3) rats were daily i.p. injected with 10mg/kg b.w ZnO-NPs five days a week for two weeks after 24hrs of irradiation. Group (4) rats were treated as in group 3 in addition to oral administration of (100mg/kg b.w) of vitamin E for five days a week for two weeks. Data from the present study showed that γ -irradiation induced degenerative changes in the periportal hepatocytes, disruption of the renal vasculature and atrophy of the splenic lymphoid follicles. These histological changes were accompanied with significant elevation in liver, kidney and spleen tissue malondialdehyde (MDA) and a significant decline in glutathione (GSH) content. Data also demonstrated increased levels of plasma ALT, AST and ALP. There was a negative impact of exposure to γ -radiation on the renal function manifested by significant rise of plasma uric acid, urea and creatinine. Administration of ZnO-NPs prominently restructured the radiation-induced hepatic, renal and spleen damage. It also induced significant regularization of radiation-induced biochemical abnormalities. Co-administration of vitamin E with ZnO-NPs has potentiated its antioxidant effect.

In conclusion, administration of ZnO-NPs helps improving the hepatic, renal and spleen damage inflicted by exposure to γ -radiation and this is enhanced by the co-administration of vitamin E.

Keywords: Gamma radiation, Kidney, Liver, Rats, Spleen, Zinc oxide nanoparticles.

Introduction:

Radiation has been used as a therapy for different types of cancer, but it has a negative impact on normal tissues that limits efficiency of the therapy (Barber et al., 2000). Reactive oxygen species (ROS) such as superoxide anion ($O_2^{\cdot-}$), hydroxyl radical (OH^{\cdot}), and hydrogen peroxide (H_2O_2) are produced by ionizing radiation which leads to disruption in oxidant/antioxidant balance in different tissues resulting in damage to DNA, protein, lipids and carbohydrates and change in their functions. Therefore, ROS induce injury to the tissues (Koc et al., 2003).

Zinc is an important trace element needed in the structure and function of over 300 metalloenzymes, as well as protein metabolism, and membrane integrity (McCall et al., 2000). It plays a chief role in regulating cellular glutathione that is energetic to the defence of cellular antioxidants, also it enters in the structure of cellular superoxide dismutase enzyme (SOD) (Prasad, 2014).

Nanoparticles can quickly enter the bloodstream and spread in different organs by circulating in the blood; they have a various use in biological systems (Salata, 2004; Babadi et al., 2012). ZnO-NPs are characterized by a wide surface area and

[#]Corresponding author e-mail: hananabdallah2007@yahoo.com

Received 17/02/2021; Accepted 23/09/2021

DOI: 10.21608/ejrsa.2021.63788.1116

©2021 National Information and Documentation Center (NIDOC)

highly catalytic activity (Shoeb et al., 2013). In addition, ZnO-NPs are considered antibacterials, antioxidants, anti-cancer, antidiabetic agents, anti-inflammatory in commercial and biomedical uses (Osmond & McCall, 2010; Badkoobeh et al., 2013; Jiang et al., 2018). Badkoobeh et al. (2013) showed that through their antioxidant potential, ZnO-NPs exhibited a protective effect against male rats gonadotoxicity produced by doxorubicin. Afifi & Abdelazim (2015) reported that by elevating levels of mRNA expression for superoxide dismutase, glutathione reductase, glutathione peroxidase and catalase and declined malondialdehyde expression, ZnO-NPs improved oxidative stress in diabetic rats. Furthermore, various studies indicated that ZnO-NPs at a high dose such as 50, 150, 300 and 350 mg/kg induced toxic effect in mice testicular cells (Talebi et al., 2013; Moridian et al., 2015). However, small doses of ZnO NPs (5mg/kg) have certain positive properties on the reproduction of male rats (Morsi, 2015). Ibraheem & Ibrahim (2016) have demonstrated that the use of low-dose nanoparticles (20µg/kg bw) can have a defensive influence via antioxidant mechanisms, but at high-dose levels (150µg/kg bw) they have several unsafe properties.

On the other hand, vitamin E functions as a free-radical scavenger that helps in protecting the cell from lipid peroxidation and keeping the integrity of cell membranes from oxidative stress (Packer, 1991).

Consequently, the aim of this study is to estimate the potential ameliorative effect of low dose of zinc oxide nanoparticles alone or combined with vitamin E on some biochemical and histological alteration of liver, kidney and spleen caused by γ -radiation in rats.

Materials and Methods

Chemicals

ZnO-NPs (CAS Number 1314-13-2) were purchased in dispersion form (Sigma-Aldrich_Germany) with an average nanoparticle size of ~35nm and a concentration of 50 wt% water. According to Torabi et al. (2013) ZnO -NPs is suspended in saline (0.9%) prior to use and dispersed by ultrasonication to prevent particle aggregation. The suspension was sonicated in a bath sonicator for 20min (Branson Model No. 2510) and was put on magnetic sterile until finishing administration.

Vitamin E, α -Tocopherol, capsule (each capsule contain 400mg vitamin E) was purchased from Pharco-Pharmaceutical Company. Vitamin E capsules were cut, open, and emptied in clean container. To prepare a suspension of 40mg of vitamin E in 1mL, corn oil was added.

Animals

Thirty-two male adult albino rats weighing 180-200g were taken from the experimental animal house of the Biological Applications Department at the Nuclear Research Center. Animals were maintained under normal conditions and free access was permitted to a standard diet and water *ad.Libitum* requirement. Animals have been preserving under regulated illumination conditions (light: dark, 13hrs: 11hrs). The animal treatment protocol has been accepted following NIH guidelines by the animal care committee of the National Center for Radiation Research and Technology, Cairo, Egypt.

Irradiation

At the Atomic Energy Authority, Cairo, Egypt, whole -body γ -irradiation was conducted using a Gamma Cell-40 Carloirradiator, a source of cesium 137. Animals were irradiated at a single acute dose level (6Gy) at a dose rate of 0.648rad/sec

Experimental design

Thirty-two rats were divided to equal four groups.

Group 1: Rats were included in the negative control group and intraperitoneal injection (i.p.) by 1ml saline (0.9%) and 1ml of corn oil by gastric tube for 2 weeks.

Group 2: All rats in this group were irradiated with whole body γ -irradiation at a single dose of 6Gy.

Group 3: Rats were irradiated and treated after 24hrs of irradiation with i.p. injection by freshly prepared 10mg/kg body weight zinc oxide nanoparticles (Bashandy et al., 2017) five days in week for two weeks.

Group 4: Rats were irradiated and treated after 24hrs of irradiation with i.p. injection by freshly prepared 10mg/kg body weight zinc oxide nanoparticles and oral administration of vitamin E (100mg/kg b.w) for five days in week for two weeks.

Histological methods

For histopathological studies, liver, kidney and spleen samples were taken from animals after being sacrificed and put in 10% neutral formalin, dehydrated in an ascending sequence of ethanol, cleared in xylol, and then embedded in paraffin. Sections of six microns thickness were prepared and stained with haematoxylin and eosin (Drury & Wallington, 1980).

Biochemical analysis

The animals were anaesthetized by diethyl ether after 15 days. Blood samples were gathered into heparin-treated tubes by cardiac puncture. Plasma was obtained at 3000rpm for 10min by centrifugation and used for determination of biochemical parameters. Immediately after the animals were killed, liver, kidney and spleen organs of each animal were quickly excised, weighed and washed with 0.9% saline and were ready for homogenization at phosphate buffered saline (PBS buffer) for the measurement of activity of GSH and levels of MDA in the homogenates of liver, kidney and spleen which were estimated by the methods of Beutler et al. (1963) and Ohkawa et al. (1979), respectively, and by means of colorimetric enzymatic methods (Biodiagnostic kits).

Plasma alanine aminotransferase (ALT), aspartate aminotransferase (AST), alkaline phosphatase (ALP), total bilirubin, total protein (TP), albumin (Alb), globulin (Glob) urea, uric acid, creatinine were assessed colorimetrically using spectrophotometer (Milton Roy Spectronic 1201) and commercial kits bought from Biodiagnostic reagent kits, Dokki, Giza, Egypt. The concentration of globulin was determined by subtracting albumin values from the corresponding total protein values.

Statistical analyses

The data were expressed as means \pm standard deviations. One-way analysis of variance (ANOVA) was performed among the mean values of the groups followed by Duncan's multiple range test, whenever necessary. The statistical difference was considered significant at $P < 0.05$. All statistical analyses were performed using the computer program: COSTAT. Program 3.03, 198.

Results

Histopathological observations

Sections from liver, kidney and spleen were observed accurately to demonstrate structural

alteration between the studied groups. Normal configuration was observed with the liver section of the control rat (Fig. 1A). Furthermore, liver sections of irradiated rats (6Gy), revealed congestion in the hepatoportal blood vessel with vacuolar degeneration in the periportal hepatocytes (Fig. 1B). Treatment of irradiated rats by ZnO-NP alone in group 3 or combined with vitamin E in group 4, showed normal hepatic parenchyma with normal hepatocytes, blood sinusoids (Fig. 1C & 1D).

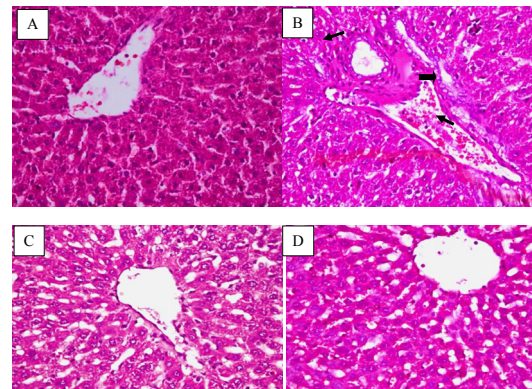


Fig. 1. A, Liver from control negative group showing normal hepatic parenchyma with normal hepatocytes, blood sinusoids, and portal area. B, irradiated group shows congestion in the hepatoportal blood vessel (arrow head) with vascular degeneration in the periportal hepatocytes (arrows). C, liver from irradiated rats treated by ZnO NPs showing normal hepatic parenchyma with normal hepatocytes, blood sinusoids, and portal area. D, liver from irradiated rats treated by ZnO NPs plus Vit E showing normal hepatic parenchyma with normal hepatocytes, blood sinusoids, and portal area [H&E X 400]

Histological structure of kidney of the control rats displayed normal structure (Fig. 2A), while, kidney section of rats exposure to irradiation (6Gy), showed dilatation of the interstitial blood vessel with perivascular edema and hemorrhage (Fig. 2B). Rats treated with zinc oxide alone after irradiation, kidney sections demonstrated normal renal parenchyma with normal glomeruli and renal tubules (Fig. 2C). Figure 2D illustrates that the treatment of the irradiated rats by ZnO-NP plus Vit.E shows apparently healthy renal parenchyma with slightly vacuolated glomerular epithelium.

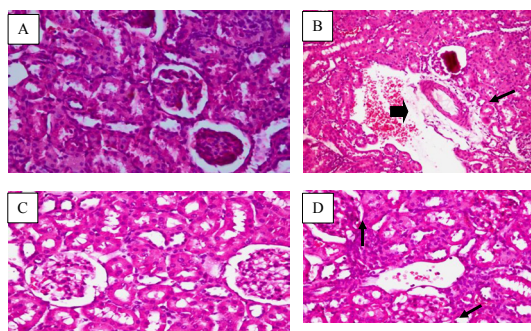


Fig. 2. A, Kidneys from control negative group showing normal renal parenchyma with normal glomeruli and renal tubules. B, Kidneys from irradiated group showing dilatation of the interstitial blood vessel (arrow) with perivascular edema and haemorrhage (arrow head). C, Kidneys from irradiated rats treated by ZnO NPs showing normal renal parenchyma with normal glomeruli and renal tubules. D, Kidneys from irradiated rats treated by ZnO NPs plus Vit.E showing apparently healthy renal parenchyma with slightly vacuolated glomerular epithelium (arrows), [H&E X 400]

Splenic histological sections were investigated to estimate structural alterations and damage caused by irradiation and the role of ZnO-NP alone or combined with Vit.E in treatment. The results of the spleen histopathological finding are shown in Fig. 3, A-D. The control rats showed normal splenic lymphoid follicles (Fig. 3A), while, spleen section of the irradiated rats, showed atrophied lymphoid follicles and congestion in the red pulps (Fig. 3B). Spleen section in groups (3&4) treated with ZnO-NP alone or combined with vitamin E after radiation showed normal lymphoid follicle with congestion in red pulp (Fig. 3C-D), respectively.

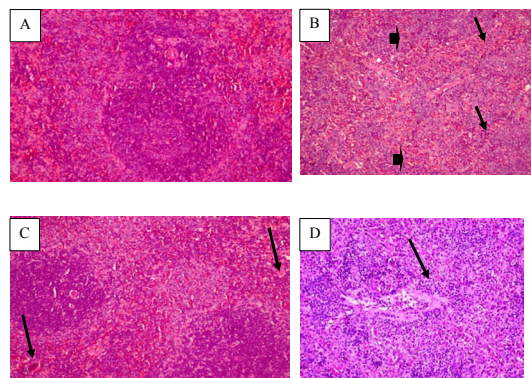


Fig. 3. A, Spleen from control negative group showing normal splenic lymphoid follicles

(H&E X 200). B, spleen from irradiated rats showing atrophied lymphoid follicles (arrow heads) and congestion in the red pulps (arrows). C, Spleen from irradiated rats treated by ZnO NPs showing congestion in the red pulp (arrows). D, Spleen from irradiated rats treated by ZnO NPs plus Vit.E showing congestion in the red pulp (arrows) [H&E X 200]

Biochemical data

The data in Table 1 indicates that (6Gy) γ -irradiation in group 2 caused reduction in liver functions, as shown by a significant increase ($P < 0.05$) in plasma ALT, AST, ALP, total bilirubin and decrease AST/ALT ratio compared to control group. However, all these parameters were decreased in the irradiated group supplemented with zinc oxide nanoparticles separately or combined with vitamin E in comparison with those obtained in the irradiated group, but not returned to the normal values. The best correction in all liver function tests were recorded in the rats treated with both ZnO-NP and Vit E.

In addition, Table 1 shows the levels of TP, Alb and Glob for all tested group. The significant elevation in the levels of TP and Glo and decrease in Alb. at $P < 0.05$ were observed in the irradiated group (G2) compared with the control group. These alternations were nearly reverted to normalcy in the rats treated by ZnO-NP alone or on combined with Vit E.

The results show significant ($P < 0.05$) increase in creatinine, urea and uric acid in the irradiated group (G2) compared with the control group (Table 2). Moreover, treatment by ZnO-NP alone or combined with Vit E normalizes these alternations.

There was significant decline in GSH content and elevation in MAD levels in liver, kidney and spleen tissues after exposure to irradiation (6Gy) compared with the control group (Table 3), while treatment of irradiated rats by ZnO-NP separately or combined with Vit E successfully ameliorated GSH and MAD in liver, kidney and spleen tissues compared with irradiated group, and the best result was shown in group4 which was treated with both ZnO-NP and Vit E.

TABLE 1. Influence of zinc oxide nanoparticles separately or combined with vitamin E on plasma liver function parameters and protein content in all tested groups

Parameters	Groups		Radiation	
	Control	Radiation	ZnO NPs	ZnO NPs + Vit E
ALT (U/L)	30.13±0.92 ^d	113.6±3.61 ^a	82.0±2.37 ^b	42.67±2.25 ^c
% of Change		277.0	172.15	41.62
AST (U/L)	62.67±2.73 ^d	142.0±1.79 ^a	95.33±3.14 ^b	68.0±1.78 ^c
% of Change		126.5	52.11	8.50
ALP (U/L)	153.3±2.58 ^b	209.3±8.06 ^a	109.4±5.39 ^c	91.1±3.22 ^d
% of Change		36.53	-28.64	-40.57
Bilirubin (mg/dl)	0.36±0.04 ^d	0.64±0.03 ^a	0.47±0.02 ^b	0.43±0.01 ^c
% of Change		77.77	30.56	19.44
TP (mg/dl)	5.5±0.14 ^b	7.13±0.25 ^a	5.87±0.10 ^b	5.73±0.31 ^b
% of Change		29.6	6.72	4.18
Alb. (mg/dl)	3.1±0.14 ^a	2.9±0.15 ^b	3.57±0.09 ^a	3.63±0.27 ^a
% of Change		-6.45	15.16	17.09
Glob. (mg/dl)	2.3±0.23 ^b	4.23±0.41 ^a	2.37±0.14 ^b	2.10±0.32 ^b
% of Change		83.91	3.04	-8.69

The values are shown as means ± SD of n= 8.

Small letter values in rows have been shown to be significantly different and identical letters are not significantly different (P< 0.05) in various groups.

TABLE 2. Influence of zinc oxide nanoparticles separately or combined with vitamin E on kidney function test in all tested groups

Parameters	Groups		Radiation	
	Control	Radiation	ZnO NPs	ZnO NPs + VitE
Creatinine (mg/dl)	0.60±0.04 ^b	0.70±0.02 ^a	0.58±0.03 ^b	0.61±0.02 ^b
% of Change		16.67	-3.33	1.67
Uric acid (mg/dl/L)	3.21±0.23 ^d	6.53±0.19 ^a	3.7±0.17 ^c	4.1±0.24 ^b
% of Change		103.4	15.26	27.73
Urea (mg/dl)	22.0±1.79 ^c	28.76±1.03 ^a	25.67±1.87 ^b	24.67±2.25 ^b
% of Change		30.73	16.68	12.14

The values are shown as means ± SD of n = 8.

Small letter values in rows have been shown to be significantly different and identical letters are not significantly different (P< 0.05) in various groups.

TABLE 3. Influence of zinc oxide nanoparticles separately or combined with vitamin E on liver and kidney MAD and GSH in all tested groups

Parameters	Groups	Radiation		Radiation	
		Control	Radiation	ZnO NPs	ZnO NPs + VitE
Liver	GSH (mg/g tissue)	28.6 ±1.27 ^b	15.87± 1.85 ^c	28.21±1.78 ^b	32.32±2.65 ^a
	% of Change		-44.63	-1.57	12.77
	MAD (nmol/g tissue)	23.2±2.12 ^b	45.1±6.28 ^a	27.23±3.28 ^b	22.79±2.27 ^b
	% of Change		93.65	16.92	-2.14
Kidney	GSH (mg/g tissue)	21.3±2.36 ^b	12.63±1.26 ^c	22.3±3.16 ^b	27.07±3.18 ^a
	% of Change		-40.82	4.49	26.85
	MAD (nmol/g tissue)	20.1±2.7 ^b	33.7±3.58 ^a	20.58±3.61 ^b	21.03±4.48 ^b
	% of Change		67.25	2.13	4.36
Spleen	GSH (mg/g tissue)	12.3±1.9 ^a	6.14±1.2.28 ^d	8.86±2.18 ^c	10.0±2.27 ^b
	% of Change		-50.08	-27.97	-18.69
	MAD (nmol/g tissue)	16.6±2.12 ^c	35.23±6.28 ^a	20.98±3.28 ^b	19.79±2.27 ^b
	% of Change		111.59	26.01	18.86

The values are shown as means ± SD of n= 8.

Small letter values in rows have been shown to be significantly different and identical letters are not significantly different (P< 0.05) in various groups.

Discussion

Radiotherapy has been implicated in cancer management for many decades as it has been used to eliminate cancer and as a palliative to alleviate pain associated with metastases. Despite its selective deleterious effect on tumor cells, radiation produces numerous biological unfavourable consequences on normal cells. Normal cell toxicity minimizes the radiation doses needed to achieve an effective treatment. For this reason, tactics have approached to manipulate the balance between eliminating cancer cells and preserving metabolic pathways and redox state mounting to harmful tissue oxidative damage. Antioxidants have been accorded as effective therapeutic and prophylactic agents for free radicle-induced radiation damage (Akanji et al., 2020). Limitations of antioxidants delivery to tissues due to reduced permeability, poor solubility or instability have been greatly overcome by amalgamation with nanotechnology to produce nanoparticles functionally termed nano-antioxidants (Date et al., 2016). In the present study, the authors tried to ameliorate the negative impact of oxidative stress imposed by total body irradiation of albino rats by two antioxidants. One antioxidant has been modified by nanoparticulation to offer a better functional modality

Exposure to a single dose of γ -radiation (6Gy) induced significant rise in the activities of plasma ALT, AST, ALP and the levels of bilirubin. These enzyme activity changes mirrored the histological alternation in the liver architecture. Congestion of the hepatoportal vessels are expected to hinder the bile flow and increase the plasma ALP activity. A degenerative change in the periportal hepatocytes justifies plasma liver enzyme changes (Fig. 1-B). Radiation-induced free radical release also leads to histologically unrecognized hepatic cell membranes damage, which in turn leads to an increase in cell membrane permeability and promotes the movement of cytoplasmic enzymes outside the cells, leading to an increase in the activity of ALT in blood serum (Cihan et al., 2013). Similar results have been reported by Abdelhafez & Kandeal (2018). The histobiochemical changes observed in the liver of the irradiated animals are consistent with Nakajima et al. (2016) findings. In addition, Makhlof & Makhlof (2012) reported an elevation of liver enzymes activities (ASAT, ALAT, ALP and GGT) in serum of rats exposed to

(2 and 4Gy) of gamma radiation, while Eshak & Osman (2013), El-Desouky et al. (2014) observed raise in ALAT, ASAT and ALP in sera of irradiated albino rats to (4 & 6Gy). The latter, correlated their biochemical data with the degree of degeneration of liver cells, lymphocytic infiltration and hepatic tissues necrosis. Long term negative impact of irradiation on the liver has been found to affect its ability to synthesize albumin (Lima & Campos, 2018).

Radiation-induced histo-renal damage engaged a dilatation of the interstitial blood vessels with perivascular edema and minute haemorrhages (Fig. 2). These changes were accompanied with impairment of excretory function of the kidney and imaged by significant rise in plasma urea, creatinine and uric acid comparison to non-irradiated control (Table 2). These data were consistent with the findings of Hanafy & Kandile (2010) who showed that the plasma creatinine, uric acid and urea levels were significantly increased in response to whole-body irradiation of albino rats by a similar dose.

Data of the present study demonstrated that irradiated rats (6Gy, single dose) experienced a significant elevation lipid peroxidation products (MDA) in liver and kidney associated with a remarkable decline in GSH concentration when compared with normal control (Table 3). This may be attributed to free radicals which were produced from ionizing radiation that can attack cell membranes and cause peroxidation of their lipid constituents leading to an increase in MAD concentration as an end product. The decline in GSH concentration in the tissues of irradiated groups may be related to GSH consumed for scavenging free radicals to neutralize them in the body; it also donates hydrogen to damage molecules and maintained thiol group in protein molecules in reduced state (Galano & Rau'l Alvarez-Idaboy, 2011). The results obtained from the present study are in line with those of Ozcelik et al. (2018), El-Gazzar et al. (2016) who documented a significant decline in GSH and elevation in MAD in various tissues (liver, brain, kidney) of rats after exposure to γ -radiation.

Total body irradiation of rats caused opposite changes of spleen cells MDA and GSH enzyme activity. MDA is formed in response to membrane lipid peroxidation, and according to specific cellular metabolic circumstances and repair

capacities, the cells may survive or die out. Under physiological or low lipid peroxidation rates (subtoxic conditions), the cells stimulate their maintenance and survival through constitutive antioxidants. Spleen cell membrane interaction with free radicals was responsible for the increase in MDA level and a reduction in GSH of spleen. Splenic tissue also underwent structural changes in response to gamma irradiation in the form of congestion of follicles and atrophy red pulp. The present data are parallel with those of Mansoub (2011), who studied the effect of γ -radiation on spleen tissue (5, 7.5 and 12Gy) and reported diffuse necrosis of the spleen. In the meantime, Abdou & Osman (2008) demonstrated that spleen of γ -irradiated rats (4Gy) displayed marked dilation and congestion of splenic blood vessels, additionally to multiple megakaryocytes.

The histological and biochemical abnormalities encountered in the irradiated groups liver, kidney and spleen were very much remodelled by the treatment with ZnO-NP. The exact mechanism of ZnO-NPs-induced amelioration of radiation-induced damage in the liver, kidney and spleen has not been resolved in the present study. One possible mechanism is that dissociation of ZnO-NPs with subsequent increase in the tissue Zn concentration offered a potent antioxidant. Zn is a good antioxidant metal well known to be the central component of antioxidant enzymes such as SOD and a recognised defender of sulfhydryl groups. It is also considered to inhibit lipid peroxidation by displacement transition metals for example iron and copper from catalytic sites (Bray & Bettger, 1990). The antioxidant and anti-inflammatory properties of ZnO-NPs were also observed by Soren et al. (2018). ZnO-NPs have been shown to be able to preserve the integrity of the cell membrane against oxidative stress damage, raise the levels of antioxidant enzymes, and diminish the level of MDA (Dawei et al., 2009). The present results are in line with those of Bashandy et al. (2018) who showed that ZnO-NPs reversed hepato-renal damage imposed by thioacetamide intoxication. Thioacetamide induces hepato-renal toxicity mainly through oxidative stress. ZnO-NPs induced and elevation of the antioxidant activity and reducing free radicals' levels. The efficacy of ZnO-NPs activity as antioxidant has also been investigated utilizing doxorubicin-induced genotoxicity by El-Maddawya & Abd El Naby (2019). Doxorubicin is anti-neoplastic

drug that acts by inflicting oxidative stress on tumor cells. They reported that the treatment by ZnO-NPs at a dose of (3mg/kg bw) improved the testicular toxicity through its antioxidant activity. In meantime, Atef et al. (2016) reported that ZnO-NPs shield rabbit hepatocytes from the toxic effects induced by aflatoxicosis in comparison with curcumin through scavenging of free radicals, or by enhancing antioxidant activity.

During the trial to overcome the negative impact of ionizing radiation on hepato-renal and splenic architecture and function by ZnO-NPs, the authors tried to boost its anti-oxidant potential by co-administration of vitamin E, α -tocopherol. Vitamin E is a well-known antioxidant with many clinical uses. It acts as an antioxidant protecting cells against free radicals adverse effects with cell membranes. One mechanism of its antioxidant effect is termination of lipid peroxidation by donate a hydrogen atom to unstable lipid radicals, producing stable lipids and a relatively stable vitamin E radical (Yin et al., 2011). Data from the present study implicated that addition of vitamin E to ZnO-NPs has potentiated its ability to counteract the oxidative damage caused by exposure to total body irradiation. The enhancing effect of vitamin E on the antioxidant activity of ZnO-NPs may assume that it acts through a different mechanism.

Conclusion

The present study heralds a therapeutic potential of ZnO-NP in minimizing oxidative damage caused by exposure to ionizing radiation. The rationale of its use is justified by histological and biochemical evidences. It also signifies a possible potentiating role of vitamin E to ZnO-NPs antioxidant activity.

Acknowledgements: The authors would like to thank Prof. Dr. Mohsen Ismail Mohamed for reading and reviewing the final manuscript. Also, the authors thank Prof. Dr. Sherein Saied Abdelgayed, Professor of Pathology, Faculty of Veterinary Medicine, Cairo University, for doing the histopathological analysis of the current work.

Disclosure statement: The authors report no conflicts of interest. The authors alone are responsible for the content and writing of paper.

References

- Abdelhafez, H.M., Kandeal, H.A.M. (2018) Histological and histochemical changes in liver of gamma-irradiated rats and the possible protective role of Aphanizomenon flos-aquae (AFA). *Journal of Bioscience and Applied Research*, **4**(1), 1-21.
- Abdou, M.I., Osman, H.F. (2008) The modulation effect of melatonin against gamma irradiation in biochemical and histopathological studies on male rats. *Isotope and Radiation Research*, **40**(1), 147-160.
- Afifi, M., Abdelazim, A.M. (2015) Ameliorative effect of zinc oxide and silver nanoparticles on antioxidant system in the brain of diabetic rats. *Asian Pacific Journal of Tropical Biomedicine*, **5**(10), 874-877.
- Akanji, M.A., Fatinukun, D., Rotimi, E., Afolabi, B.L. (2020) The two sides of dietary antioxidants in cancer therapy, In: "*Antioxidants*", Publisher: Intech Open. DOI: 10.5772/intechopen.94988
- Atef, H.A., Mansour, M.K., Ibrahim, E.M., Sayed El-Ahl, R.M.H., Al-Kalamawey, N.M., El Kattan, Y.A., Ali, M.A. (2016) Efficacy of zinc oxide nanoparticles and curcumin in amelioration the toxic effects in aflatoxicated rabbits. *International Journal of Current Microbiology and Applied Sciences*, **5**(12), 795- 818.
- Babadi, V.Y., Najafi, L., Najafi, A et al. (2012) Evaluation of iron oxide nanoparticles effects on tissue and enzymes of liver in rats. *Journal of Pharmaceutical and Biomedical Sciences*, **23**, 1-4, Pubmed ID: 16616095.
- Badkoobeh, P., Parivar, K., Kalantar, S.M., Hosseini, S.D., Salabat, A., (2013) Effect of nano-zinc oxide on doxorubicin-induced oxidative stress and sperm disorders in adult male Wistar rats. *Iranian Journal of Reproductive Medicine*, **11**(5), 353-364. PMID:24639766.
- Barber, J.B., Burrill, W., Spreadborough, A.R., Levine, E., Warren, C., Kiltie, A.E., Scott, D. (2000) Relationship between in vitro chromosomal radiosensitivity of peripheral blood lymphocytes and the expression of normal tissue damage following radiotherapy for breast cancer. *Radiotherapy and Oncology*, **55**(2), 179-186.
- Bashandy, S.A.E., Alaamer, A., Moussa, S.A.A., Omara, E.A. (2017) Role of zinc oxide nanoparticles in alleviating hepatic fibrosis and nephrotoxicity induced by thioacetamide in rats. *Canadian Journal of Physiology and Pharmacology*, **69**, 1-36.
- Bashandy, S.A. E., Alaamer, A., Moussa, S.A.A., Enayat, A., Omara, E.A. (2018) Role of zinc oxide nanoparticles in alleviating hepatic fibrosis and nephrotoxicity induced by thioacetamide in rats. *Canadian Journal of Physiology and Pharmacology*, **96**, 337-344.
- Date, A.A., Hanes, J., Ensign, L.M. (2016) Nanoparticles for oral delivery; design, evaluation and state of the art, *Journal of Controlled Release*, **28**;240:504-526.
- Beutler, E., Duron, O., Kefly, B.M. (1963) Improved method for the determination of blood glutathione. *Journal of Laboratory and Clinical Medicine*, **61**, 882-888.
- Bray, T.M., Bettger, W.J. (1990) The physiological role of zinc as an antioxidant. *Free Radical Biology and Medicine*, **8**, 281-291.
- Cihan, Y.B., Ozturk, A., Gokalp, S.S. (2013) Protective role of royal jelly against radiation-induced oxidative stress in rats. *International Journal of Hematology and Oncology*, **2**, 79-87.
- Dawei, A.I., Zhisheng, W., Angu, Z. (2009) Protective effects of nano-ZnO on the primary culture mice intestinal epithelial cells in vitro against oxidative injury. *International Journal of Nanotechnology and Applications*, **3**,1-6.
- Drury, R.A., Wallington, E.A. (1980) Carleton's "*Histological Techniques*", 5th ed., Oxford University Press, New York., 195p.
- El-Desouky, W.I., Abd El-Aleem, I.M., Saleh, E.S. (2014) Effect of ethanolic ziziphus (*Ziziphus mauritiana Lam.*) leaves extract as radioprotector on some biochemical parameters of γ -irradiated male albino rats. *International Journal of Advanced Research*, **2**(4), 1046-1057.
- El-Gazzar, M.G., Zaher, N.H., El-Hossary, E.M., Ismail, A.F.M. (2016) Radio-protective effect of some new curcumin analogues. *Journal of Photochemistry and Photobiology B*, **162**, 694-702
- El-Maddawya, Z.K., Abd El Naby, W.S.H. (2019) Protective effects of zinc oxide nanoparticles

- against doxorubicin induced testicular toxicity and DNA damage in male rats. *Toxicology Research*, **8**, 654–662.
- Eshak, M.G., Osman, H.F. (2013) Role of *Moringaoleifera* leaves on biochemical and genetical alterations in irradiated male rats. *Middle-East Journal of Scientific Research*, **16**(10), 1303-1315.
- Galano, A., Rau'l Alvarez-Idaboy, J. (2011) Glutathione: mechanism and kinetics of its non-enzymatic defense action against free radicals Annia. *RSC Advances*, **1**(9), 1763–1771.
- Hanafy, N., Kandil, E.I. (2010) Evaluation of coenzyme Q10 role in reducing kidney damage in rats induced by acetaminophen and gamma radiation exposure. *Isotope and Radiation Research*, **42**(3), 587–607.
- Ibraheem, S.R., Ibrahim, M.R. (2016) Physiological and histological effect of (zinc and iron) oxide nanoparticles on some fertility parameters in female mice. *AL-Mustansiriyah Journal of Science*, **27**(5),1–10.
- Jiang, J., Pi, J., Cai, J. (2018) The Advancing of zinc oxide nanoparticles for biomedical applications. *Bioinorganic Chemistry and Applications*, **96**(4), 337-344.
- Koc, M., Taysi, S., Buyukokuroglu, M.E., Bakan, N. (2003) Melatonin protects rat liver against irradiation-induced oxidative injury. *Journal of Radiation Research*, **44**, 211-215
- Lima, C.V., Campos, T.PI. (2018) Radiation-induced changes in the electrophoretic profile of serum albumin. *Brazilian Archives of Biology and Technology*, **60**, 1-11
- Makhlouf, R., Makhlouf, I. (2012) Evaluation of the effect of *Spirulina* against Gamma irradiation induced oxidative stress and tissue injury in rats. *Int J. Appl. Sci. Engine.Res.*, **1**(2), 152-164
- Mansoub, N.H. (2011) Pathological investigation of cobalt radiation on the liver and spleen of rat. *Annals of Biological Research*, **2**(6), 399-402.
- McCall, K.A., Huang, C., Fierke, C.A. (2000) Function and Mechanism of Zinc Metalloenzymes. *The Journal of Nutrition*, **130**(5), 1437S–1446S.
- Moridian, M., Khorsandi, L., Talebi, A.R. (2015) Morphometric and stereological assessment of the effects of zinc oxide nanoparticles on the mouse testicular tissue. *Bratislavske Lekarske Listy*, **116**(5), 321–325.
- Morsi, M.H. (2015) Physiological effects of Nano-zinc on Reproductive performance and Immunity of Male Rat, *Thesis (PhD)*, Faculty of Veterinary Medicine, Alexandria University, Egypt.
- Nakajima, T., Vares, G., Wang, B., Neno, M. (2016) Chronic intake of Japanese sake mediates radiation-induced metabolic alterations in mouse liver. *PLoS one*, **11**(1), 1-18.
- Ohkawa, H., Ohishi, N., Yagi, K. (1979) Assay for lipid peroxides in animal tissues by thiobarbituric acid reaction. *Analytical Biochemistry*, **95**, 351-358.
- Osmond, M.J., McCall, M.J. (2010) Zinc oxide nanoparticles in modern sunscreens: an analysis of potential exposure and hazard. *Nanotoxicology*, **4**(1), 15–41.
- Ozcelik, M., Erişir, M., Guler, O., Baykara, M., Kirman, E. (2018) The effect of curcumin on lipid peroxidation and selected antioxidants in irradiated rats. *Acta Veterinaria Brno*, **87**, 379–385
- Packer, L. (1991) Protective role of vitamin E in biological systems. *American Journal of Clinical Nutrition*, **53**(4), 1050S-1055S.
- Powell, S.R., (2000) The antioxidant properties of zinc. *Journal of Nutrition*, **130**, 1447S–1454S.
- Prasad, A.S. (2014) Zinc: An antioxidant and anti-inflammatory agent: Role of zinc in degenerative disorders of aging. *Journal of Trace Elements in Medicine and Biology*, **28**, 364–371.
- Salata, O., (2004) Applications of nanoparticles in biology and medicine. *Journal of Nanobiotechnology*, **2**, 1-6.
- Shoeb, M., Braj, R.S., Javed, A.K., Wasi, K., Brahma, N.S. et al. (2013) ROS dependent anticandidal activity of zinc oxide nanoparticles synthesized by using egg albumen as a biotemplate. *Advances in Natural Sciences: Nanoscience and Nanotechnology*, **4**, 035015.
- Soren, S., Kumar, S., Mishra, S., Jena, P.K., Verma, S.K., Parhi, P., (2018) Evaluation of antibacterial

and antioxidant potential of the zinc oxide nanoparticles synthesized by aqueous and polyol method. *Microbial Pathogenesis*, **119**, 145-151.

Talebi, A.R., Khorsandi, L., Moridian, M. (2013) The effect of zinc oxide nanoparticles on mouse spermatogenesis. *Journal of Assisted Reproduction and Genetics*, **30**(9), 1203–1209.

Torabi, M., Kesmati, M., Harooni, H.E. and Varzi, H.N., (2013) Effects of nano and conventional Zinc Oxide on anxiety-like behavior in male rats. *Indian Journal of Pharmacology*, **45**(5), 508–512.

Yin, H., Xu, L., Porter, N.A. (2011) Free radical lipid peroxidation: mechanisms and analysis. *Chemical Reviews*, **111**(10), 5944–5972.