

Online ISSN: 2682-2628  
Print ISSN: 2682-261X

# IJC CBR

INTERNATIONAL JOURNAL OF  
CANCER AND BIOMEDICAL RESEARCH

<https://jcbr.journals.ekb.eg>

Editor-in-chief

Prof. Mohamed Labib Salem, PhD

**Matrix metalloproteinase-9 expression in fetal membranes and maternal serum in cases of premature rupture of membranes: Impact of subclinical chorioamnionitis**

Heba F. Harras, Esraa A. Mohamed, Hashem A. Lotfy and  
Daren A. Mohamed



PUBLISHED BY

**EACR** EGYPTIAN ASSOCIATION  
FOR CANCER RESEARCH

Since 2014

# Matrix metalloproteinase-9 expression in fetal membranes and maternal serum in cases of premature rupture of membranes: Impact of subclinical chorioamnionitis

Heba F. Harras<sup>1</sup>, Esraa A. Mohamed<sup>2</sup>, Hashem A. Lotfy<sup>3</sup> and Dareen A. Mohamed<sup>1</sup>

<sup>1</sup>Department of Pathology, Tanta University, Egypt

<sup>2</sup>Department of Medical Microbiology and Immunology, Faculty of Medicine, Tanta University, Egypt

<sup>3</sup>Department of Obstetrics and Gynecology, Tanta University, Egypt

## ABSTRACT

**Background:** Matrix metalloproteinase-9 (MMP-9) is the most active MMPs in the fetomaternal membranes. It plays an important role in the breakdown and remodeling of these membranes. Thus, increased knowledge of its expression in cases of premature rupture of membranes (PROM) with and without chorioamnionitis (CA) is essential for developing effective treatment strategies.

**Patients and Methods:** expression of MMP-9 in fetomaternal membranes and maternal serum were performed in 70 full-term pregnant women; 20 cases were with intact membranes (group I), 35 with PROM (group IIA) and 15 with PROM and CA (group IIB). **Results:** A significant difference in MMP-9 expression was detected between the studied groups. The highest MMP-9 expression was reached in women with PROM accompanied by histological (subclinical) CA followed by women with PROM without CA, compared to the control group (with intact membranes) at the time of delivery. Immunohistochemical expression was associated with a concomitant increase in serum MMP-9. **Conclusion:** MMP-9 could predict women liable for premature rupture of membranes, and the determination of its serum level may be an effective tool for PROM detection.

**Keywords:** Chorioamnionitis, MMP-9, premature rupture of membrane

Editor-in-Chief: Prof. M.L. Salem, PhD - Article DOI: 10.21608/jcbr.2021.70155.1197

## ARTICLE INFO



### Article history

Received: March 29, 2021

Revised: May 20, 2021

Accepted: May 21, 2021

### Correspondence to:

Dr. Heba F. Harras, MD  
Department of Pathology,  
Faculty of Medicine,  
Tanta University, Egypt  
Tel.: +2 01112989139  
Email:  
heba.harras@med.tanta.edu.eg

## INTRODUCTION

Fetal membranes are composed of the innermost layer (amnion) and fetal tissue connected to maternal decidua (chorion) linked by extracellular matrix (ECM) rich in collagen and mesenchymal cells (Richardson et al., 2017). ECM, made of fibrous proteins and submerged in a polysaccharide gel accompanying different types of collagen, form the architectural framework of the fetomaternal membranes (Menon et al., 2019). Amnion and chorion work together as a single unit to protect and maintain fetoplacental growth during pregnancy (Menon et al., 2016).

Interstitial collagen is the crucial structural component of the fetomaternal membranes

which provides most of its tensile strength. Collagen types I and III in conjunction with

smaller amounts of types V, VI and VII are present in the compact layer underneath the amniotic basement membrane. Type IV collagen is the major constituent of the basement membrane and is located in the reticular and spongy layers of fetomaternal membranes. It gives a scaffold for the assembly of other basement membrane components; laminin, entactin/nidogen and heparan sulphate proteoglycan (Malak et al., 1993).

Matrix metalloproteinase-9 (MMP-9) is the most active and powerful MMP in amnion gelatinolytic activity. It has a role in the degradation of type IV collagen (Ernita et al., 2019). It increases significantly in the amniotic

membranes after the start of uterine contractions and is considered as the main MMP involved in normal and pathological delivery (Weiss et al., 2007).

Premature rupture of the membranes (PROM) is the spontaneous rupture of the fetal membranes in the absence of regular uterine contractions. If it occurred before 37 weeks, it is defined as preterm PROM and if at 37 weeks or more it is called at term PROM (Okeke et al., 2014).

Chorioamnionitis (CA) is prevalent in patients with PROM (Matrisian, 1990). The acute symptomatic condition which often presents with fever, tachycardia, vaginal discharge, uterine tenderness and evidence of fetal infection is termed clinical chorioamnionitis (CCA) while cases without the typical microbiological or clinical findings associated with acute infection are termed histological or subclinical chorioamnionitis (Sagay, 2016).

Histologic chorioamnionitis (HCA) complicates about 30–80% of preterm births with preterm labor or premature rupture of membranes and is considered a risk factor for unfavourable neonatal and maternal outcomes, including early gestational age at delivery and neonatal lung and brain injuries (Kim et al., 2015).

This study aimed to determine MMP-9 immunohistochemical expression in fetomaternal membranes as well as measuring its maternal serum level in infection-associated premature rupture of membranes. That is to throw more light on its clinical significance.

## PATIENTS AND METHODS

The study was conducted on 70 pregnant women attending the department of Obstetrics and Gynecology, Tanta University hospital at the time of labor. The study was done in the period from January 2019 to January 2021. Their age ranged from 20-35 years old.

**Inclusion criteria:** The patients were primigravida or multigravida with gestational age  $\geq 37$  weeks, singleton pregnancy, normal presentation, premature rupture of membranes with clear amniotic fluid and mode of delivery was cesarean section. **Exclusion criteria:** General maternal infections or inflammation,

medical disorders with pregnancy as diabetes mellitus, cardiac disease, renal disease, severe anemia, hypertension, pre-eclampsia, placenta previa, bleeding per vagina and normal labor. Written consent was taken from the mother for the research.

Subjects under study were classified into 2 groups; Control Group: 20 pregnant women with intact membranes and study Group: 50 pregnant women with premature rupture of membranes. All women were subjected to full clinical history, general examination, abdominal and pelvic examination. Abdominal examination: abdominal palpation including fundal level, fundal grip, pelvic grip to evaluate fetal lie presentation and position, particular emphasis on uterine activity and auscultation of fetal heart sound. Local pelvic examination: vaginal examination was performed to assess cervix position, effacement, and dilatation.

A sample of fluid was taken from the posterior vaginal fornix using a sterile cotton-tipped applicator. Diagnosis of amniotic fluid was done by using Nitrazine paper test and Fern test. Abdominal U/S was done to assess the duration of pregnancy, placental site, amniotic Fluid Index (AFI) and fetal weight. Laboratory investigation was done to assess CBC, Rh group, blood sugar, renal and liver function tests, urine analysis and C-reactive protein by latex serology test.

Venous blood samples were collected after the ultrasound examination. Sera were obtained by centrifugation and stored frozen at  $-20^{\circ}\text{C}$  until analysis was performed. The concentration of MMP-9 in maternal serum was determined by ELISA kits (Birkedal-Hansen, 1995). The kit uses a double-antibody sandwich enzyme-linked immunosorbent assay (ELISA) to assay the level of Human Matrix metalloproteinase 9 (MMP-9).

All studied cases had been delivered by caesarean section. After delivery, we took a sample from fetal membranes at the site of rupture. Paraffin blocks were formed from formalin fixed fetal membranes tissue and subjected to Hematoxylin and Eosin staining for histopathological examination and immunostaining with MMP-9 antibody for immunohistochemical study.

The diagnosis of chorioamnionitis (CA) was made when neutrophilic infiltration into the chorionic trophoblast layer or chorioamniotic connective tissue was observed. The severity of CA was scored based upon two parameters.

The stage of inflammation and severity of inflammation (Hecht et al., 2008). Stages of inflammation were classified as Stage 0: no inflammation, Stage I: indicated neutrophils collecting in the subchorionic space, Stage II: indicated neutrophils infiltrating into the chorionic plate, and Stage III: indicated neutrophils infiltrating up to the amniotic epithelium. The severity of inflammation was divided into Grade I (less than 10 neutrophils/20 field), Grade II (10 to 19 neutrophils/20 field) and Grade III (more than 20 neutrophils/20 field) with formation of micro abscess.

Sections of 10 to 15 um of paraffin-embedded fetal membranes were processed for immunohistochemical staining using mouse monoclonal antibodies (Anti-MMP-9 antibody [2C3] (ab270246) MMP-9 antibodies were used at a 1:50 dilution. The binding of primary antibodies was detected using the avidin-biotinylated peroxidase technique and biotinylated horse anti-mouse IgG (Vector, Burlingame, CA). Tissue sections were counterstained with Mayer's hematoxylin and cover-slipped for evaluation of MMP-9 by light microscopy. The MMP-9 was considered positive when brownish staining in the cytoplasm of the cells was seen. The intensity of MMP-9 staining was evaluated by the following categories (Zaga-Clavellina et al., 2011); 0 (no staining), +1 (weak staining), +2 (moderate staining), +3 (strong staining).

**Statistical presentation and analysis** was conducted, using a student t-test to compare the means of two groups, standard deviation, one-way Anova test (f test) to test the degree of difference between more than two groups that result from factor of interest, Chi-square test for comparison between independent variable or for testing relationships between categorical variable and Turkey's test which is a single multiple comparison procedure used to find means that are significantly different from each other by SPSS V.20.

## RESULTS

The study was done on 70 women that were classified into two major groups: Control group (group I) including 20 pregnant women full term with intact membranes and a study group (group II) including 50 pregnant women full term with premature rupture of membranes.

The control cases were 7 primigravida (35%) and 13 multigravida (65%) with singleton pregnancy while the study group cases were 19 primigravida (38%) and 31 multigravida cases (62%). The ages of the control group cases ranged from 20-35 years old with a mean value of 28.5 years. while the ages of the study group cases ranged from 20-30 years old with a mean value of 26.8 years. U\S examination of control group cases were done to assess the duration of pregnancy which varied from 37 to 40 weeks, with a mean value of 38 weeks and in study group cases were of the same age. The placental sites in control group cases were fundal anterior position in 15 cases (75%) and fundal posterior position in 5 cases (25%), while in study group cases there were fundal anterior position in 30 cases (60%), and fundal posterior position in 20 cases (40%). The mean fetal weight was 2.700 Kg in the control group ranging from 2.500Kg-3.500Kg while in study group cases, the mean fetal weight was 2.900Kg ranging from 2.500Kg-3.800Kg (Table1).

### Histopathological results

Hematoxylin and Eosin staining for histopathological examination revealed that Group I: 20 cases (control group) showed amnion layer consisting of a single layer of cuboidal epithelium overlying the basement membrane, and a collagen layer. The fibrous chorion lies deep to the amnion and consists of a sparsely cellular collagen layer. The fibrous chorion rests on a layer of intermediate trophoblast cells (clear to eosinophilic cytoplasm). Decidua is present deep to the intermediate trophoblast layer (Figure 1A). Group II (study group) was subdivided after histopathological examination according to the presence of histological chorioamnionitis into PROM without chorioamnionitis (group II A) and PROM with chorioamnionitis (group II B). Group IIA: 35 cases (PROM without chorioamnionitis) showed slight oedema between amnion and

chorionic plate (Figure 1B). Group IIB: 15 cases (PROM with chorioamnionitis) which were furtherly categorized according to extent of inflammation into: 6 cases stage I (Figure 1C), 6 cases stage II, and 3 cases stage III. And according to the severity of inflammation into 4 cases grade I (Figure 1D), 5 cases grade II and 6 cases grade III (Figure 1E).

### Immunohistochemical results

After immunostaining with MMP-9 antibody, the examination revealed that: Group I: all the 20 cases (100%) showed mild cytoplasmic localization of MMP-9 mainly to amnion epithelia, chorion trophoblast, decidua layer (Figure 2A). Group IIA: 15 cases out of 35 (42.86%) showed strong cytoplasmic expression of MMP-9 (Figure 2B) and 20 out of 35 cases (57.14%) showed moderate cytoplasmic expression of MMP-9 (Figure 2C) Group IIB: all the 15 cases (100%) showed strong cytoplasmic expression of MMP-9. Besides, there was MMP-9 positive expression in inflammatory cells of chorioamnionitis (Figure 2D). By comparing group IIA and group IIB (two subgroups of the PROM) with Group I (control group), it was found that p-value is 0.001 which is statistically significant and by comparing group IIA (PROM without chorioamnionitis) with group IIB (PROM with chorioamnionitis), it was found that P-value is 0.001 which is statistically significant too (Table 2).

### Serum MMP-9 expression

The mean MMP-9 maternal serum level was  $570.000 \pm 54.248$  ng/ml in group I which increased in group IIA to reach  $842.000 \pm 61.77$  ng/ml and its serum level markedly increased in group IIB to reach  $1537.000 \pm 748.948$  ng/ml. Statistically, there was a significant difference between the control and studied groups as the p-value was  $<0.05$  (Table 3).

### Serum C- reactive protein (CRP) level

In group I, all cases were negative while in group IIA, 22 cases were negative, and 13 cases were positive. All cases in group IIB showed positive serum expression of CRP. When comparing positive CRP in groups I, IIA, IIB with negative CRP in the same groups as P-value was  $<0.05$  which is statistically significant (Table 4).

## DISCUSSION

Rupture of the fetal membranes is a necessary part of pregnancy-associated with extensive degeneration of collagen (Shi et al., 2020). Premature rupture of membranes (PROM) is a significant public health problem, occurring in

10% of all pregnancies. It accounts for 70% and 40% of neonatal morbidity and mortality, respectively (Azria, 2018).

Matrix metalloproteinases are a family of powerful enzymes that degrade the extracellular matrix macromolecules, including collagen (Ernita et al., 2019). Collagen IV is important for most fetal membranes strength as it forms the backbone onto which other basement membrane elements are anchored (Shi et al., 2020). The role of MMPs in human labor and PROM has been studied previously but conflicting results were obtained up till now.

Histopathological studies demonstrate that PROM is frequently preceded by infection and inflammation of the intra-amniotic cavity and the fetal membranes. Moreover, these inflammatory changes are usually observed near the reported site of membrane rupture (Olgun and Reznik, 2010). In this study, we tried to find the relation between MMP-9 level in maternal serum and its expression in the fetomaternal membranes in cases of PROM at term and determine the histopathological changes of membranes with or without histological chorioamnionitis.

The cases enrolled in this study were divided into; control group with intact membranes (group I), study group of PROM (group II) which was subdivided into PROM without chorioamnionitis (group IIA) and PROM associated with chorioamnionitis (group IIB) after the histopathological examination which revealed subclinical chorioamnionitis in some cases. Concerning the demographic data, we found that there is no significant difference between the control and study groups. They were matched with each other as regard the mother's age, parity, and gestational age at recruitment. This coincides with the data of Ernita et al., (2019) who documented that the incidence of PROM is not influenced by gestational age. Regarding the parity, (Menon et

**Table 1.** Comparison between control and study group according to parity, age, duration of pregnancy, fetal weight, and placental site.

	Control Group (Group I) N= 20	Study Group (Group II) N= 50	P-Value
<b>No of Pregnancy</b>			
Primigravida	7	19	0.247
Multigravida	13	31	> 0.05
<b>Mean age</b>	28.5 years old	26.8years old	0.09
			> 0.05
<b>Mean duration of pregnancy</b>	38 weeks	38 weeks	0.421
			> 0.05
<b>Mean fetal weight</b>	2.700Kg	2.900Kg	0.392
			> 0.05
<b>Placental site</b>			
Fundal anterior	15	30	0.095
Fundal posterior	5	20	> 0.05

**Table 2.** Comparison between the control and studied groups according to the cytoplasmic expression of matrix metalloproteinase- 9.

MMP-9		Control	Study		Total
		Group I	Group IIA	Group IIB	
Mild	N	20	0	0	20
	%	100%	0%	0%	28.57%
Moderate	N	0	20	0	20
	%	0%	57.14%	0%	28.57%
Strong	N	0	15	15	30
	%	0%	42.86%	100%	42.86%
Total	N	20	35	15	70
	%	100%	100%	100%	100%
Chi-square*	X <sup>2</sup>	50.0			
	P-value*	0.001*			
Chi-square*	X <sup>2</sup>	10.502			
	P-value*	0.001*			

MMP-9: matrix metalloproteinase- 9, \* Significant (p&lt; 0.05)

**Table 3.** Serum level of matrix metalloproteinase- 9 (ng/ml) in the studied groups.

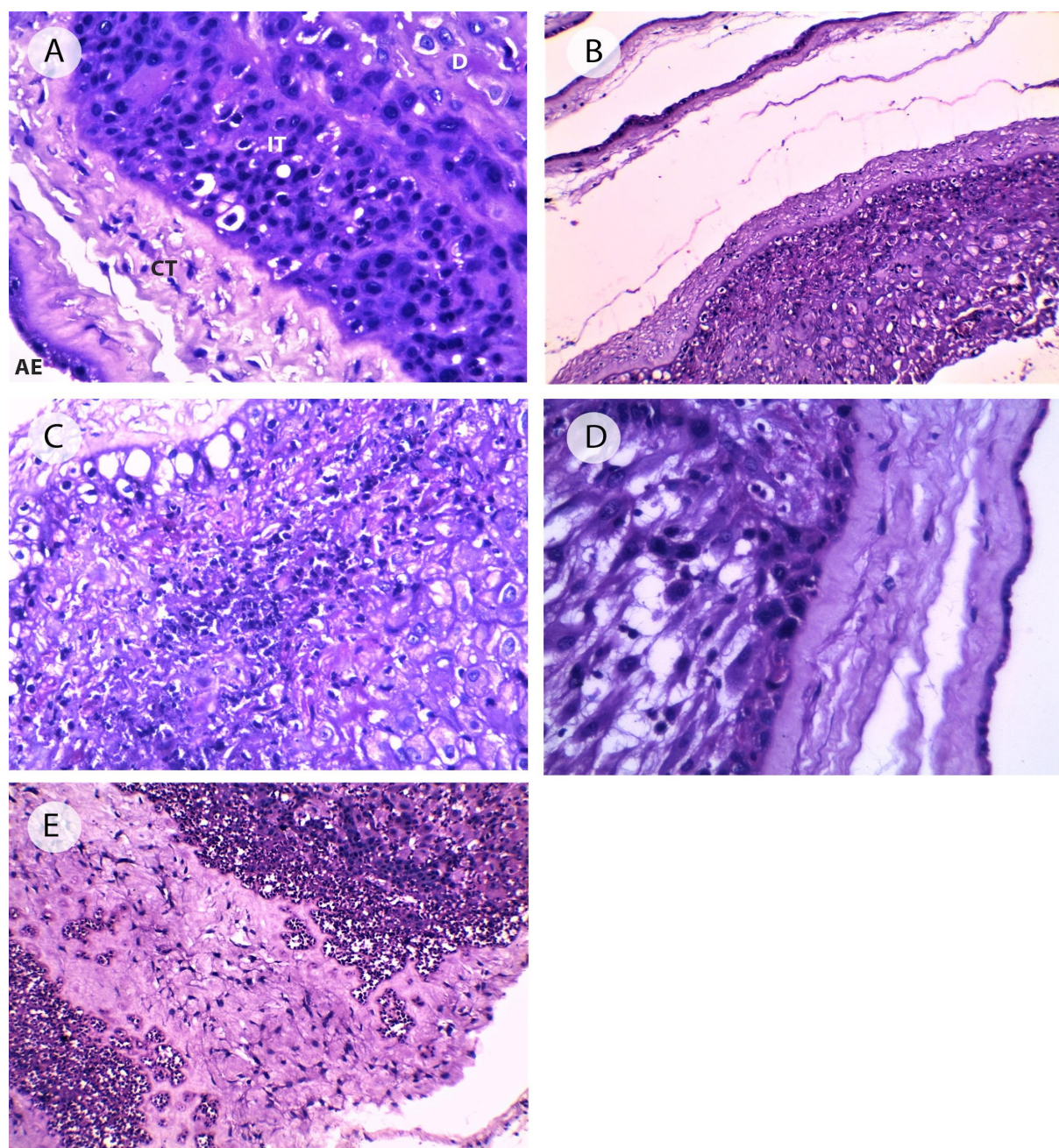
Groups	MMP-9						ANOVA	
	Range			Mean	±	SD	F	P-value
Group I	500	-	640	570.000	±	54.248	26.195	<0.001*
Group IIA	650	-	910	842.000	±	61.779		
Group IIB	950	-	2730	1537.000	±	748.948		
<b>TUKEY'S Test</b>								
I&IIA			I&IIB			IIA&IIB		
0.041*			<0.001*			<0.001*		

MMP-9: matrix metalloproteinase- 9, \* Significant (p&lt; 0.05)

**Table 4.** Serum level of C- reactive protein in the studied groups.

CRP		Group I	Group IIA	Group IIB	Total
Negative	N	20	22	0	42
	%	28.57	31.42	0.00	60
Positive	N	0	13	15	28
	%	0.00	18.57	21.43	40
Chi-square	X <sup>2</sup>	25.552			
	P-value	<0.001*			

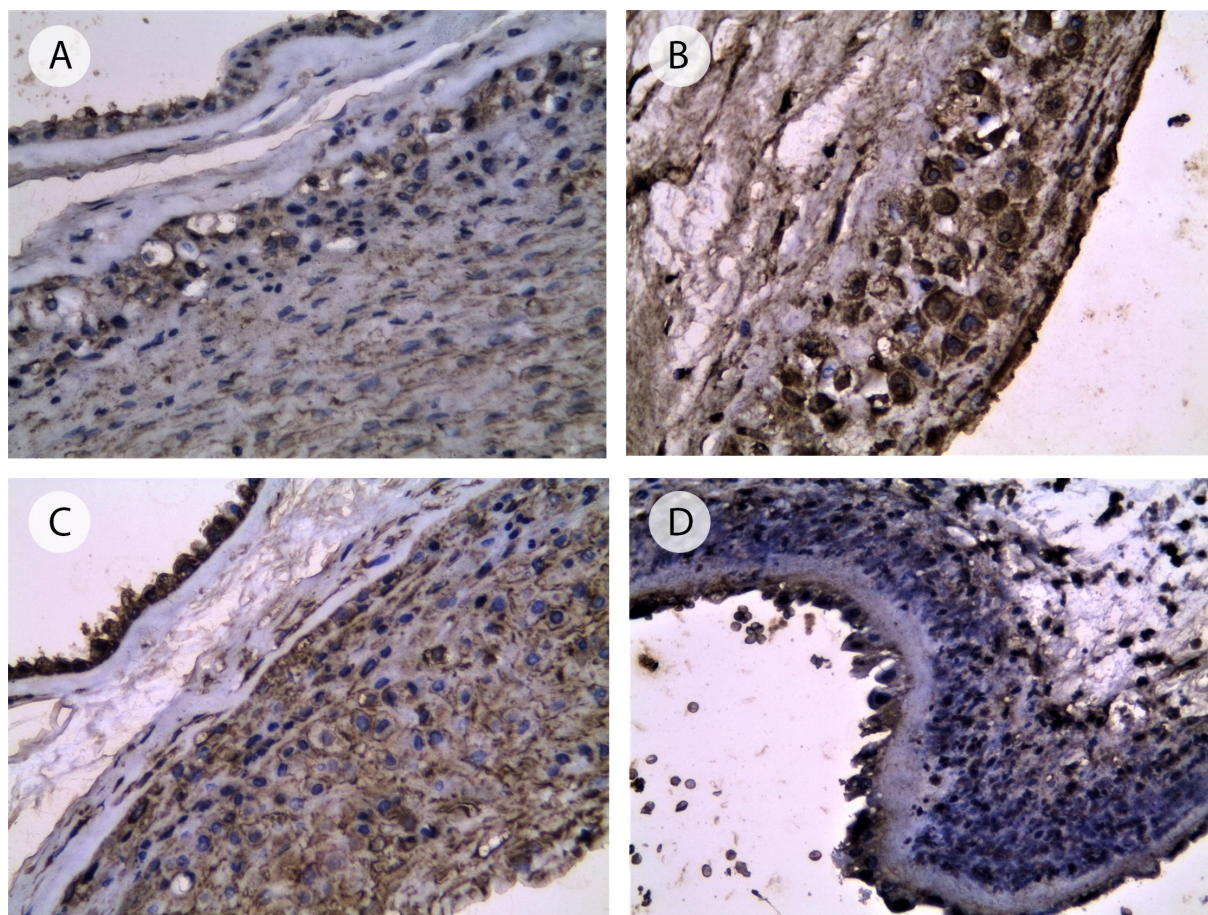
CRP: c- reactive protein, \* Significant (p&lt; 0.05)



**Figure 1.** Hematoxylin and eosin staining of the fetal membrane of the studied cases. A: fetal membrane of a control group case with normal structure. (AE: amniotic epithelium, CT: connective tissue layer of chorion, IT: intermediate trophoblasts of chorion, D: decidua) (x400). B: fetal membrane with PROM showed slight oedema between amnion and chorionic plate (x 100). C: a case of PROM with stage I chorioamnionitis showing diffuse neutrophilic infiltration in the subchorionic plate (x 400). D: a case of PROM with grade I chorioamnionitis showing neutrophilic infiltration less than 10 cells (x400). E: a case of PROM with grade III chorioamnionitis showing neutrophilic infiltration of more than 20 cells up to the formation of microabscess (x200).

al., 2006) coincided with the data of our study as there was no significant difference between the parity and occurrence of PROM. In the present study, we found that the average maternal serum MMP-9 level and its immunohistochemical expression in fetomaternal membranes in at term PROM

were significantly higher than that in normal pregnancy. The results of this study demonstrated mild expression of MMP-9 in 100% of fetal membranes tissues of control group I with intact membranes. There was no clinical or histological chorioamnionitis with negative results in CRP.



**Figure 2.** Immunohistochemical expression of matrix metalloproteinase-9 in the fetal membrane of the studied cases. A: mild cytoplasmic expression of MMP-9 (amnion, chorionic trophoblasts, and decidua) in a control group case (x200). B: a case of PROM showing strong cytoplasmic expression of MMP-9 (x400). C: a case of PROM showing moderate cytoplasmic expression of MMP-9 (x200). D: a case of PROM with chorioamnionitis showing strong cytoplasmic expression of MMP-9. Some inflammatory cells showed positive expression of MMP-9 (x200).

We suggest that this mild expression of MMP-9 in the third trimester of the control group is a normal sequence of remodeling events in fetal membranes preparing for delivery. This is in accordance with (Bourboulia and Stetler-Stevenson, 2010) who proved that change in the extracellular matrix and fetomaternal membranes composition is partially moderated by the action of matrix collagenases, especially MMP family members, zinc containing metalloenzymes that act on specific substrates, including the fibrillar and basement membrane collagens. Group IIA (PROM without CA) showed that there were 20 cases (57.14%) with a moderate cytoplasmic expression of MMP-9 and 15 cases (42.86%) with a strong cytoplasmic expression of MMP-9. On comparing group IIA with group I regarding the serum level and immunohistochemical expression of MMP-9, there was a significant difference between the two groups. These results denote higher

bioavailability of MMP-9 leading to the associated statistically significant rise of serum MMP-9. Our results are in agreement with Bourboulia and Stetler-Stevenson, (2010), who proved that this rise is required to degrade the extracellular matrix associated with PROM.

On the contrary, different results were obtained by Ernita et al., (2019) who documented that the average serum MMP-9 in normal pregnancy is higher than in at term PROM. They explained that the effect of some considerations like diseases affecting pregnant women and that is not detected by the researcher could affect the MMP-9 levels in their study including hypertension, cardiovascular diseases, and systemic infection. These factors were included in the exclusion criteria of our study.

In group IIA, there was no histologic or clinical evidence of chorioamnionitis, and CRP was negative in 22 cases and positive in 13 cases



only. The positive cases showed a mild increase in CRP (maximum +12) which may indicate a nonspecific cause. In Group IIB, the immunostaining of MMP-9 was stronger than group IIA and MMP-9 showed expression in inflammatory cells in all cases (100%). This strong expression comes in concomitant with a statistically significant rise of serum MMP-9. In this group, there was histological chorioamnionitis with no clinical evidence of chorioamnionitis. The CRP was positive in all cases and significantly higher than that in group IIA that reached +24 in some cases, denoting occurrence of infection.

The expression of MMP-9 in inflammatory cells can be explained by an infection which stimulates resident macrophages to produce proinflammatory cytokines as mentioned by (Romero et al., 2011), which sequentially could stimulate MMP-9 gene expression and conduct secretion and activation of this enzyme and degradation of extracellular matrix collagen IV.

Our results coincide with (Vanderhoeven et al., 2014) who observed that women with PROM accompanied by infection had a three-fold higher mean concentration of serum MMP-9 than those without infection.

The higher increase of MMP-9 in relation to infection was previously detected by (Zhang et al., 2015) who stated that infection may have an extra role in PROM and this may be explained by protease produced by bacteria which may lower the membrane strength and elasticity resulting in PROM. In addition, they concluded that PROM is a multifactorial process, but infection is considered a vital factor that may be involved in it either as a result or as a cause.

Recently, on studying MMP-9 gene polymorphism (Pandey and Awasthi, 2020) suggested that the MMP-9 has a crucial role in promoting preterm labor events and so it could be considered as a useful tool in diagnosis during pregnancy. On the other hand, (Mennella et al., 2021) found that the mean concentration of MMP-9 and its inhibitors do not differ in preterm PROM cases compared to normal controls. This difference could be due to the different sample sizes or the method of detection. The identification of MMP-9 and other MMPs as potential biological or

pathological mediators in the degradation of connective tissue raises the possibility of the direct inhibition of these enzymes, resulting in a therapeutic target in the management of PROM (Vadillo-Ortega and Estrada-Gutiérrez, 2005). Several specific and non-specific MMP inhibitors are now available and are undergoing clinical testing in treating some diseases. Recent advances and techniques are used in developing novel metalloproteinase inhibitors and MMP responsive drug delivery tools (Raeeszadeh-Sarmazdeh et al., 2020).

## CONCLUSION

Increased levels of MMP-9 could predict the risk for the development of PROM as it may reflect the presence of histological chorioamnionitis. Moreover, the measurement of serum level of MMP-9 may be used as a non-invasive method for detection of such cases].

## CONFLICTS OF INTEREST

All authors have approved this article and declare no conflicts of interest.

## FUND

No fund was received for this work.

## References

- Azria E (2018). [Antenatal management in case of preterm premature rupture of membranes before fetal viability: CNGOF Preterm Premature Rupture of Membranes Guidelines]. *Gynécologie Obstétrique Fertilité & Sénologie - Journal*, 46(12): 1076-1088.
- Birkedal-Hansen H (1995). Proteolytic remodeling of extracellular matrix. *Current Opinion in Cell Biology Journal*, 7(5): 728-735.
- Bourboulia D, Stetler-Stevenson WG (2010). Matrix metalloproteinases (MMPs) and tissue inhibitors of metalloproteinases (TIMPs): Positive and negative regulators in tumor cell adhesion. *Seminars in Cancer Biology Journal*, 20(3): 161-168.
- Ernita L, Nasrul E, Friadi A (2019). The Difference of Zinc And Matrix Levels of Metalloproteinase-9 Serum Between Premature Rupture Of Membrane Aterm And Normal Pregnancy. 2019, 4(1): 11.
- Hecht JL, Onderdonk A, Delaney M, Allred EN, Kliman HJ, Zambrano E, Pflueger SM, Livasy CA, Bhan I, Leviton A (2008). Characterization of chorioamnionitis in 2nd-trimester C-section placentas and correlation with microorganism

- recovery from subamniotic tissues. *Pediatric and Developmental Pathology Journal*, 11(1): 15-22.
- Kim CJ, Romero R, Chaemsaitong P, Chaiyasit N, Yoon BH, Kim Y M (2015). Acute chorioamnionitis and funisitis: definition, pathologic features, and clinical significance. *American Journal of Obstetrics & Gynecology Journals*, 213(4 Suppl): S29-52.
- Malak TM, Ockleford C D, Bell SC, Dalgleish R, Bright N, Macvicar J (1993). Confocal immunofluorescence localization of collagen types I, III, IV, V and VI and their ultrastructural organization in term human fetal membranes. *Placenta*, 14(4): 385-406.
- Matrisian LM (1990). Metalloproteinases and their inhibitors in matrix remodeling. *Trends Genetics Journal*, 6(4): 121-125.
- Mennella JM, Underhill LA, Collis S, Lambert-Messerlian GM, Tucker R, Lechner BE (2021). Serum Decorin, Biglycan, and Extracellular Matrix Component Expression in Preterm Birth. *Reproductive Sciences Journal*, 28(1): 228-236.
- Menon R, Bonney EA, Condon J, Mesiano S, Taylor RN (2016). Novel concepts on pregnancy clocks and alarms: redundancy and synergy in human parturition. *Human Reproduction Update*, 22(5): 535-560.
- Menon R, McIntyre JO, Matrisian LM, Fortunato SJ (2006). Salivary proteinase activity: a potential biomarker for preterm premature rupture of the membranes. *American Journal of Obstetrics and Gynecology*, 194(6): 1609-1615;
- Menon R, Richardson LS, Lappas M (2019). Fetal membrane architecture, aging and inflammation in pregnancy and parturition. *Placenta*, 79: 40-45.
- Okeke T, Jo E, Okoro O, Adiri C, Ezugwu E, Agu U (2014). The Incidence and Management Outcome of Preterm Premature Rupture of Membranes (PPROM) in a Tertiary Hospital in Nigeria. *American Journal of Clinical Medicine Research*, 2: 14-17.
- Olgun NS, Reznik SE (2010). The matrix metalloproteinases and endothelin-1 in infection-associated preterm birth. *Obstetrics and Gynecology International Journal*, 2010.
- Pandey M, Awasthi S (2020). Role of MMP-1, MMP-8 and MMP-9 gene polymorphisms in preterm birth. *Journal of Genetics*, 99.
- Raezszadeh-Sarmazdeh M, Do LD, Hritz BG (2020). Metalloproteinases and Their Inhibitors: Potential for the Development of New Therapeutics. *Cells*, 9(5): 1313.
- Richardson L, Vargas G, Brown T, Ochoa L, Trivedi J, Kacerovsky M, Lappas M, Menon R (2017). Redefining 3Dimensional placental membrane microarchitecture using multiphoton microscopy and optical clearing. *Placenta*, 53: 66-75.
- Romero R, Chaiworapongsa T, Alpay Savasan Z, Xu Y, Hussein Y, Dong Z, Kusanovic JP, Kim CJ, Hassan SS (2011). Damage-associated molecular patterns (DAMPs) in preterm labor with intact membranes and preterm PROM: a study of the alarmin HMGB1. *The Journal of Maternal-Fetal & Neonatal Medicine*, 24(12): 1444-1455.
- Sagay A S (2016). Histological Chorioamnionitis. *Journal of the West African College of Surgeons*, 6(3): x-xiii.
- Shi JW, Lai ZZ, Yang HL, Yang SL, Wang CJ, Ao D, Ruan LY, Shen HH, Zhou WJ, Mei J, Fu Q, Li M Q (2020). Collagen at the maternal-fetal interface in human pregnancy. *International Journal of Biological Sciences*, 16(12): 2220-2234.
- Vadillo-Ortega F, Estrada-Gutiérrez G (2005). Role of matrix metalloproteinases in preterm labour. *BIOG*, 112(Suppl 1): 19-22.
- Vanderhoeven JP, Bierle CJ, Kapur RP, McAdams RM, Beyer RP, Bammler TK, Farin FM, Bansal A, Spencer M, Deng M, Gravett MG, Rubens CE, Rajagopal L, Adams Waldorf KM (2014). Group B streptococcal infection of the choriodecidua induces dysfunction of the cytokeratin network in amniotic epithelium: a pathway to membrane weakening. *PLoS Pathogens*, 10(3): e1003920.
- Weiss A, Goldman S, Shalev E (2007). The matrix metalloproteinases (MMPS) in the decidua and fetal membranes. *Frontiers in Bioscience*, 12: 649-659.
- Zaga-Clavellina V, Garcia-Lopez G, Flores-Pliego A, Merchant-Larios H, Vadillo-Ortega F (2011). In vitro secretion and activity profiles of matrix metalloproteinases, MMP-9 and MMP-2, in human term extra-placental membranes after exposure to *Escherichia coli*. *Reproductive Biology and Endocrinology*, 9(1): 13.
- Zhang YZ, Ran LY, Li CY, Chen XL (2015). Diversity, Structures, and Collagen-Degrading Mechanisms of Bacterial Collagenolytic Proteases. *Applied and Environmental Microbiology Journal*, 81(18): 6098-6107.